American Board of Surgery In-Training Examination

THE JOHNS HOPKINS

ABSITE Review Manual



SECOND EDITION

Robert A. Meguid
Kyle J. Van Arendonk
Pamela A. Lipsett

Johns Hopkins University School of Medicine, Department of Surgery

INCLUDES
ONLINE ACCESS TO AN INTERACTIVE QUESTION BANK

- Two full-length practice exams with 225 questions each
- Based on actual key words from recent ABSITEs
- **Online access to practice exams**
- High-quality questions and discussions by leaders in their fields
- Includes key figures and tables with up-to-date cancer staging and treatment algorithms for many of the questions

Wolters Kluwer Health | Lippincott Williams & Wilkins

JOHNS HOPKINS MEDICINE SCHOOL OF MEDICINE

www.myuptodate.com

راهنمای نصب آخرین نسخه آپتودیت آفلاین

۱. برای نصب اپلیکشین درگوشی آیفون، برنامه App Store و درگوشی اندروید Play Store را اجرا کرده سپس عبارت Mehrsys medical library را جستجو کنید و برنامه را نصب کنید.

۲. بعد از نصب و اجرای اپلیکیشن در صفحه اول برنامه **برای دریافت** Username و Password به **به تلگرام پشتیبانی و فروش که در زیر تصویر اشاره شده است پیغام دهید.**

@MehrsysSupport

۳. در مرحله بعد حساب کاربری خود را بسازید.

۴. بعد از ورود به برنامه در قسمت یا منوی Download روی آیکون سه نقطه آبی رنگ که رو به روی UpToDate قرار دارد کلیک کنید و گزینه دانلود Download را انتخاب کنید با این عمل می توانید دانلود را به آسانی از طریق اینترنت انجام دهید.

قابلیتهای برنامه

- دسترسی به آخرین نسخه آپتودیت آفلاین با قابلیت بروز رسانی
- امکان جستجو بسیار سریع مطالب بدون نیاز به اینترنت
- امکان مشاهده **abstract** رفرنسهای داخل مقالات آپتودیت
- قابل نصب بر روی گوشی و کامپیوتر
- دسترسی به دیگر منابع پزشکی و دارویی به صورت رایگان
- امکان انتخاب متون، کپی و ارسال آن به برنامه های دیگر
- هایلایت کردن متون در برنامه به رنگهای مختلف
- ذخیره کردن مقالات و عکسهای آپتودیت
- تولید شده توسط شرکت معتبر نرم افزاری و مورد تایید نظام صنفی رایانه ای کشور و شورای عالی انفورماتیک

دریافت آخرین نسخه آپتودیت آفلاین www.myuptodate.com ۰۲۱-۶۶۱۹۸۵۱۴

American Board of Surgery In-Training Examination

THE JOHNS HOPKINS ABSITE Review Manual



SECOND EDITION

EDITORS

Robert A. Meguid, MD, MPH
Assistant Professor of Surgery
Division of Cardiothoracic Surgery
Department of Surgery
University of Colorado
School of Medicine
Aurora, Colorado

Kyle J. Van Arendonk, MD, PhD
Halsted Resident
Department of Surgery
Johns Hopkins University
School of Medicine
Baltimore, Maryland

Pamela A. Lipsett, MD, MHPE, FACS, FCCM
Professor of Surgery, Anesthesia and Critical Care Medicine, and Nursing
General Surgery and Surgical Critical Care Program Director
Co-Director of the Surgical Intensive Care Units
Department of Surgery
Johns Hopkins University
Schools of Medicine and Nursing
Baltimore, Maryland

Wolters Kluwer Health | Lippincott Williams & Wilkins
Philadelphia • Baltimore • New York • London
Buenos Aires • Hong Kong • Sydney • Tokyo

JOHNS HOPKINS MEDICINE
SCHOOL OF MEDICINE

۰۲۱-۶۶۱۹۸۵۱۴ www.myuptodate.com دریافت آخرین نسخه آپتودیت آفلاین

Acquisitions Editor: Keith Donnellan
Product Manager: Brendan Huffman
Production Project Manager: David Orzechowski
Senior Manufacturing Coordinator: Beth Welsh
Design Coordinator: Stephen Druding
Production Service: Aptara, Inc.

© 2014 by LIPPINCOTT WILLIAMS & WILKINS, a Wolters Kluwer business

Two Commerce Square
2001 Market Street
Philadelphia, PA 19103 USA
LWW.com

First edition © 2009 by LIPPINCOTT WILLIAMS & WILKINS, a Wolters Kluwer business

All rights reserved. This book is protected by copyright. No part of this book may be reproduced in any form by any means, including photocopying, or utilized by any information storage and retrieval system without written permission from the copyright owner, except for brief quotations embodied in critical articles and reviews. Materials appearing in this book prepared by individuals as part of their official duties as U.S. government employees are not covered by the above-mentioned copyright.

Printed in China

Library of Congress Cataloging-in-Publication Data

The Johns Hopkins ABSITE review manual / editors, Robert A. Meguid, Kyle J. Van Arendonk, Pamela A. Lipsett. – Second edition.
p. ; cm.
ABSITE review manual
Includes bibliographical references and index.
ISBN 978-1-4511-7332-1 (paperback : alk. paper)
I. Meguid, Robert A., editor. II. Van Arendonk, Kyle J., editor. III. Lipsett, Pamela A., editor. IV. Title: ABSITE review manual.
[DNLM: 1. Surgical Procedures, Operative–Examination Questions. 2. Clinical Medicine–Examination Questions. 3. Specialty Boards. WO 18.2]
RD82.3
617.9076–dc23
2013034795

Care has been taken to confirm the accuracy of the information presented and to describe generally accepted practices. However, the authors, editors, and publisher are not responsible for errors or omissions or for any consequences from application of the information in this book and make no warranty, expressed or implied, with respect to the currency, completeness, or accuracy of the contents of the publication. Application of the information in a particular situation remains the professional responsibility of the practitioner.

The authors, editors, and publisher have exerted every effort to ensure that drug selection and dosage set forth in this text are in accordance with current recommendations and practice at the time of publication. However, in view of ongoing research, changes in government regulations, and the constant flow of information relating to drug therapy and drug reactions, the reader is urged to check the package insert for each drug for any change in indications and dosage and for added warnings and precautions. This is particularly important when the recommended agent is a new or infrequently employed drug.

Some drugs and medical devices presented in the publication have Food and Drug Administration (FDA) clearance for limited use in restricted research settings. It is the responsibility of the health care provider to ascertain the FDA status of each drug or device planned for use in their clinical practice.

To purchase additional copies of this book, call our customer service department at (800) 638-3030 or fax orders to (301) 223-2320. International customers should call (301) 223-2300.

Visit Lippincott Williams & Wilkins on the Internet: at LWW.com. Lippincott Williams & Wilkins customer service representatives are available from 8:30 am to 6 pm, EST.

10 9 8 7 6 5 4 3 2 1

۰۲۱-۶۶۱۹۸۵۱۴ www.myuptodate.com دریافت آخرین نسخه آپتودیت آفلاین

DEDICATION

To my family, my mentors, and to all surgical residents of past, present, and future, for their continued inspiration.

–R.A.M.

To my family for all their love and support, and to all those who make the Halsted surgical residency what it is.

–K.J.V.A.

To all current Halsted residents and to the inspiration of all those who have come before.

–P.A.L.

۰۲۱-۶۶۱۹۸۵۱۴ www.myuptodate.com دریافت آخرین نسخه آپتودیت آفلاین

دریافت آخرین نسخه آپتودیت آفلاین www.myuptodate.com ۰۲۱-۶۶۱۹۸۵۱۴

CONTRIBUTING AUTHORS

Said C. Azoury, MD
Halsted Resident
Department of Surgery
Johns Hopkins University
School of Medicine
Baltimore, Maryland

Nikiforos Ballian, MBBS
General Surgeon
Department of Surgery
Mitera Hospital
Athens, Greece
Former Halsted Intern

Jens U. Berli, MD
Plastic Surgery Resident
Department of Plastic and Reconstructive Surgery
Johns Hopkins University
School of Medicine
Baltimore, Maryland

Benjamin S. Brooke, MD, PhD
Assistant Professor
Division of Vascular Surgery
Department of Surgery
University of Utah
School of Medicine
Salt Lake City, Utah
Former Halsted Resident

Andrew P. Dhanasopon, MD
Halsted Resident
Department of Surgery
Johns Hopkins University
School of Medicine
Baltimore, Maryland

Trevor A. Ellison, MD, MBA
Halsted Resident
Department of Surgery
Johns Hopkins University
School of Medicine
Baltimore, Maryland

Jonathan A. Forbes, MD
Chief Resident
Department of Neurosurgery
Vanderbilt University Medical Center
Nashville, Tennessee
Former Halsted Intern

Jacqueline Garonzik-Wang, MD, PhD
Halsted Resident
Department of Surgery
Johns Hopkins University
School of Medicine
Baltimore, Maryland

Timothy J. George, MD
Halsted Resident
Department of Surgery
Johns Hopkins University
School of Medicine
Baltimore, Maryland

Seth D. Goldstein, MD
Halsted Resident
Department of Surgery
Johns Hopkins University
School of Medicine
Baltimore, Maryland

Joshua C. Grimm, MD
Halsted Resident
Department of Surgery
Johns Hopkins University
School of Medicine
Baltimore, Maryland

Isaac Howley, MD
Halsted Resident
Department of Surgery
Johns Hopkins University
School of Medicine
Baltimore, Maryland

Sunil S. Karhadkar, MD
Fellow
Division of Transplant Surgery
Department of Surgery
University of Maryland
School of Medicine
Baltimore, Maryland
Former Halsted Intern

Clinton D. Kemp, MD
Cardiothoracic Surgery Fellow
Department of Surgery
Johns Hopkins University
School of Medicine
Baltimore, Maryland
Former Halsted Resident

Betsy King, MD
Halsted Resident
Department of Surgery
Johns Hopkins University
School of Medicine
Baltimore, Maryland

Lisa M. Kodadek, MD
Halsted Resident
Department of Surgery
Johns Hopkins University
School of Medicine
Baltimore, Maryland

۰۲۱-۶۶۱۹۸۵۱۴ www.myuptodate.com دریافت آخرین نسخه آپتودیت آفلاین

Jayme E. Locke, MD, MPH
Assistant Professor of Surgery
Division of Transplantation
University of Alabama at Birmingham
School of Medicine
Birmingham, Alabama
Former Halsted Resident

Bonnie E. Lonze, MD, PhD
Fellow in Transplant Surgery
Department of Surgery
Johns Hopkins University
School of Medicine
Baltimore, Maryland
Former Halsted Resident

Ying Wei Lum, MD
Assistant Professor
Division of Vascular Surgery & Endovascular Therapy
Johns Hopkins University
School of Medicine
Baltimore, Maryland
Section Director for Anatomy
Perdana University
Graduate of Medicine
Serdang, Malaysia
Former Halsted Resident

Konstantinos I. Makris, MD
Clinical Fellow
Section of Endocrine Surgery
Department of Surgery
Johns Hopkins University
School of Medicine
Baltimore, Maryland

Michele A. Manahan, MD
Assistant Professor
Department of Plastic and Reconstructive Surgery
Johns Hopkins University
School of Medicine
Baltimore, Maryland
Former Halsted Resident

Justin B. Maxhimer, MD
Department of Plastic and Reconstructive Surgery
UCLA Medical Center
Los Angeles, California
Former Halsted Resident

Robert A. Meguid, MD, MPH
Assistant Professor of Surgery
Division of Cardiothoracic Surgery
Department of Surgery
University of Colorado
School of Medicine
Aurora, Colorado
Former Halsted Resident

Raja Mohan, MD
Plastic Surgery Resident
Department of Plastic and Reconstructive Surgery
Johns Hopkins University
School of Medicine
Baltimore, Maryland

Susanna M. Nazarian, MD, PhD
Assistant Professor
Division of Transplant Surgery
Department of Surgery
University of Washington Medical Center
Seattle, Washington
Former Halsted Resident

Kelly Olino, MD
Surgical Oncology Fellow
Department of Surgery
Memorial Sloan-Kettering Cancer Center
New York, New York
Former Halsted Resident

Babak J. Orandi, MD, MSc
Halsted Resident
Department of Surgery
Johns Hopkins University
School of Medicine
Baltimore, Maryland

Emmanouil Pappou, MD
Halsted Resident
Department of Surgery
Johns Hopkins University
School of Medicine
Baltimore, Maryland

Jose H. Salazar, MD
Postdoctoral Fellow
Division of Pediatric Surgery
Department of Surgery
Johns Hopkins University
School of Medicine
Baltimore, Maryland
Former Halsted Resident

Ibrahim Sultan, MD
Cardiothoracic Surgery Fellow
Division of Cardiac Surgery
Department of Surgery
Hospital of the University of Pennsylvania
Philadelphia, Pennsylvania
Former Halsted Resident

۰۲۱-۶۶۱۹۸۵۱۴ www.myuptodate.com دریافت آخرین نسخه آپتودیت آفلاین

Vicente Valero III, MD
Halsted Resident
Department of Surgery
Johns Hopkins University
School of Medicine
Baltimore, Maryland

Kyle J. Van Arendonk, MD, PhD
Halsted Resident
Department of Surgery
Johns Hopkins University
School of Medicine
Baltimore, Maryland

Eric S. Weiss, MD, MPH
Attending Staff Surgeon
Department of Cardiac Surgery
Advanced Fellow
Department of Transplantation and Mechanical Circulatory Support
Columbia University
New York Presbyterian Hospital
New York, New York
Former Halsted Resident

Matthew J. Weiss, MD
Assistant Professor of Surgery
Section of Hepato-Pancreato-Biliary Surgery
Division of Surgical Oncology
Department of Surgery
Johns Hopkins University
School of Medicine
Baltimore, Maryland
Former Halsted Resident

Jordan M. Winter, MD
Assistant Professor of Surgery
Division of Surgical Oncology
Department of Surgery
Thomas Jefferson University
Philadelphia, Pennsylvania
Former Halsted Resident

Joshua H. Wolf, MD
Halsted Resident
Department of Surgery
Johns Hopkins University
School of Medicine
Baltimore, Maryland

Kashif A. Zuberi, MBBCh, MRCSI
Fellow in Minimally Invasive Surgery
General and Gastrointestinal Surgery
Johns Hopkins University
School of Medicine
Baltimore, Maryland
Former Halsted Resident

۰۲۱-۶۶۱۹۸۵۱۴ www.myuptodate.com دریافت آخرین نسخه آپتودیت آفلاین

SECTION EDITORS

Body as a Whole

Andrew P. Dhanasopon, MD
Halsted Resident
Department of Surgery
Johns Hopkins University
School of Medicine
Baltimore, Maryland

Emmanouil Pappou, MD
Halsted Resident
Department of Surgery
Johns Hopkins University
School of Medicine
Baltimore, Maryland

Endocrine, Hematic, Lymphatic, and Breast

Brenessa M. Lindeman, MD
Halsted Resident
Department of Surgery
Johns Hopkins University
School of Medicine
Baltimore, Maryland

Joshua H. Wolf, MD
Halsted Resident
Department of Surgery
Johns Hopkins University
School of Medicine
Baltimore, Maryland

Genitourinary, Head and Neck, Skin, Muscle, and Nervous System

Jacqueline Garonzik-Wang, MD, PhD
Halsted Resident
Department of Surgery
Johns Hopkins University
School of Medicine
Baltimore, Maryland

Seth D. Goldstein, MD
Halsted Resident
Department of Surgery
Johns Hopkins University
School of Medicine
Baltimore, Maryland

Cardiovascular and Respiratory

Clinton D. Kemp, MD
Cardiothoracic Surgery Fellow
Department of Surgery
Johns Hopkins University
School of Medicine
Baltimore, Maryland
Former Halsted Resident

Babak J. Orandi, MD, MSc
Halsted Resident
Department of Surgery
Johns Hopkins University
School of Medicine
Baltimore, Maryland

Gastrointestinal

Trevor A. Ellison, MD, MBA
Halsted Resident
Department of Surgery
Johns Hopkins University
School of Medicine
Baltimore, Maryland

Kelly Olino, MD
Surgical Oncology Fellow
Department of Surgery
Memorial Sloan-Kettering Cancer Center
New York, New York
Former Halsted Resident

۰۲۱-۶۶۱۹۸۵۱۴ www.myuptodate.com دریافت آخرین نسخه آپتودیت آفلاین

CONTRIBUTING EDITORS

Christopher J. Abularrage, MD
Assistant Professor of Surgery
Division of Vascular Surgery and Endovascular Therapy
Department of Surgery
Johns Hopkins University
School of Medicine
Baltimore, Maryland

Mohamad E. Allaf, MD
Associate Professor of Urology and Oncology
Director
Minimally Invasive and Robotic Surgery
Department of Urology
Johns Hopkins University
School of Medicine
Baltimore, Maryland
Former Halsted Resident

Pablo A. Baltodano, MD
Postdoctoral Research Fellow
Department of Plastic and Reconstructive Surgery
Johns Hopkins University
School of Medicine
Baltimore, Maryland

William A. Baumgartner, MD
The Vincent L. Gott Professor of Cardiac Surgery
Vice Dean for Clinical Affairs
Johns Hopkins Medicine
Baltimore, Maryland

Arthur L. Burnett, MD, MBA, FACS
Patrick C. Walsh Distinguished Professor of Urology
Department of Urology
Johns Hopkins Medical Institutions
Baltimore, Maryland

Andrew M. Cameron, MD, PhD
Associate Professor of Surgery
The Comprehensive Transplant Center
Department of Surgery
Johns Hopkins University
School of Medicine
Baltimore, Maryland

Duke E. Cameron, MD
Cardiac Surgeon-in-Charge
James T. Dresher Sr. Professor of Surgery
Chief, Division of Cardiac Surgery
Director, Pediatric Cardiac Surgery
Director, Dana and Albert "Cubby" Broccoli Aortic Surgery Center
Department of Surgery
Johns Hopkins University
School of Medicine
Baltimore, Maryland
Former Halsted Resident

Nicole M. Chandler, MD
Assistant Professor of Surgery
Division of Pediatric Surgery
Department of Surgery
All Children's Hospital
Johns Hopkins University
School of Medicine
St. Petersburg, Florida

Albert Chi, MD
Assistant Professor of Surgery
Division of Acute Care Surgery and Adult Trauma Surgery
Department of Surgery
Johns Hopkins University
School of Medicine
Baltimore, Maryland

Michael A. Choti, MD, MBA
Jacob C. Handelsman Professor of Surgery
Department of Surgery
Johns Hopkins University
School of Medicine
Baltimore, Maryland

Alan P.B. Dackiw, MD, PhD, BSc, BSc(Med), FACS, FRCSC
Associate Professor of Surgery
Associate Professor of Oncology
Division of Endocrine Surgery
Department of Surgery
Johns Hopkins University
School of Medicine
Baltimore, Maryland

Mark D. Duncan, MD, FACS
Associate Professor of Surgery
Associate Professor of Oncology
Division of Surgery and Oncology
Vice Chair
Department of Surgery
Johns Hopkins University
School of Medicine
Baltimore, Maryland

Frederick E. Eckhauser, MD, FACS
Professor of Surgery
Department of Surgery
Johns Hopkins University
School of Medicine
Baltimore, Maryland
Former Halsted Resident

Barish H. Edil, MD, FACS
Associate Professor of Surgery
Department of Surgery
University of Colorado
School of Medicine
Aurora, Colorado
Former Halsted Resident

۰۲۱-۶۶۱۹۸۵۱۴ www.myuptodate.com دریافت آخرین نسخه آپتودیت آفلاین

David T. Efron, MD, FACS
Associate Professor of Surgery
Associate Professor of Anesthesiology and Critical Care Medicine
Director of Trauma, The Johns Hopkins University School of Medicine
Chief, Division of Trauma and Surgical Critical Care
Department of Surgery
Johns Hopkins University
School of Medicine
Baltimore, Maryland
Former Halsted Resident

Jonathan E. Efron, MD
Associate Professor of Surgery
Department of Surgery
Johns Hopkins University
School of Medicine
Baltimore, Maryland

Frank J. Frassica, MD
Professor of Orthopedics and Oncology
F. J. Frassica Professor of Orthopedic Surgery
Department of Orthopedic Surgery
Johns Hopkins University
School of Medicine
Baltimore, Maryland

Julie A. Freischlag, MD
The William Stewart Halsted Professor
Surgeon-in-Chief
Department of Surgery
Johns Hopkins Medical Institutions
Baltimore, Maryland

Susan L. Gearhart, MD
Associate Professor
Division of Colorectal Surgery
Department of Surgery
Johns Hopkins University
School of Medicine
Baltimore, Maryland
Former Halsted Resident

Mehran Habibi, MD, MBA
Assistant Professor of Surgery
Division of Surgical Oncology
Department of Surgery
Johns Hopkins University
School of Medicine
Baltimore, Maryland

Elliott R. Haut, MD, FACS
Associate Professor of Surgery
Associate Professor of Anesthesiology and Critical Care Medicine
Associate Professor of Emergency Medicine
Division of Acute Care Surgery and Adult Trauma
Department of Surgery
Johns Hopkins University
School of Medicine
Baltimore, Maryland

Kenzo Hirose, MD, FACS
Assistant Professor of Surgery
Associate Program Director
Halsted Surgical Residency
Johns Hopkins University
School of Medicine
Baltimore, Maryland

Lisa K. Jacobs, MD
Associate Professor of Surgery
Associate Professor of Oncology
Division of Surgical Oncology
Department of Surgery
Johns Hopkins University
School of Medicine
Baltimore, Maryland

Asad Latif, MBBS, MPH
Assistant Professor of Anesthesiology and Critical Care Medicine
Johns Hopkins University
School of Medicine
Baltimore, Maryland

Anne O. Lidor, MD, MPH
Associate Professor of Surgery
Department of Surgery
Johns Hopkins University
School of Medicine
Baltimore, Maryland
Former Halsted Resident

Pamela A. Lipsett, MD, MHPE, FACS, FCCM
Professor of Surgery, Anesthesia and Critical Care Medicine, and Nursing
General Surgery and Surgical Critical Care Program Director
Co-Director of the Surgical Intensive Care Units
Department of Surgery
Johns Hopkins University
Schools of Medicine and Nursing
Baltimore, Maryland
Former Halsted Resident

۰۲۱-۶۶۱۹۸۵۱۴ www.myuptodate.com دریافت آخرین نسخه آپتودیت آفلاین

Ying Wei Lum, MD
Assistant Professor of Surgery
Division of Vascular Surgery & Endovascular Therapy
Johns Hopkins University
School of Medicine
Baltimore, Maryland
Section Director for Anatomy
Perdana University
Graduate of Medicine
Serdang, Malaysia
Former Halsted Resident

Martin A. Makary, MD, MPH
Associate Professor of Surgery and Health Policy & Management
Department of Surgery
Johns Hopkins University
School of Medicine
Director of Pancreas Islet Transplant Center
Director of Surgical Quality and Safety
Johns Hopkins University
School of Medicine
Baltimore, Maryland
Former Halsted Resident

Konstantinos I. Makris, MD
Clinical Fellow
Section of Endocrine Surgery
Department of Surgery
Johns Hopkins University
School of Medicine
Baltimore, Maryland

Michele A. Manahan, MD
Assistant Professor of Surgery
Department of Plastic and Reconstructive Surgery
Johns Hopkins University
School of Medicine
Baltimore, Maryland
Former Halsted Resident

Robert A. Meguid, MD, MPH
Assistant Professor of Surgery
Division of Cardiothoracic Surgery
Department of Surgery
University of Colorado
School of Medicine
Aurora, Colorado
Former Halsted Resident

Gedge D. Rosson, MD
Associate Professor of Surgery
Department of Plastic and Reconstructive Surgery
Johns Hopkins University
School of Medicine
Baltimore, Maryland
Former Halsted Resident

Richard D. Schulick, MD, MBA, FACS
The Aragón/Gonzalez-Gíustí Chair
Professor and Chair of the Department of Surgery
University of Colorado
School of Medicine
Aurora, Colorado
Former Halsted Resident

Christopher M. Sciortino, MD, PhD
Assistant Professor of Surgery
Division of Cardiac Surgery
Department of Surgery
Johns Hopkins University
School of Medicine
Baltimore, Maryland
Former Halsted Resident

Dorry L. Segev, MD, PhD
Associate Professor of Surgery
Division of Transplantation Surgery
Department of Surgery
Johns Hopkins University
School of Medicine
Baltimore, Maryland
Former Halsted Resident

Kent A. Stevens, MD, MPH
Assistant Professor of Surgery
Department of Surgery
Division of Acute Care Surgery and Adult Trauma Surgery
Johns Hopkins Medical Institutions
Baltimore, Maryland

F. Dylan Stewart, MD, FACS
Assistant Professor of Surgery
Director of Pediatric Trauma
Division of Pediatric Surgery
Johns Hopkins University
School of Medicine
Baltimore, Maryland
Former Halsted Resident

Anne J.W. Tong, MBBS
Postdoctoral Research Fellow
Johns Hopkins University
School of Medicine
Baltimore, Maryland

Anthony P. Tufaro, DDS, MD, FACS
Associate Professor of Surgery
Associate Professor of Oncology
Vice Chief of Plastic and Reconstructive Surgery
Departments of Plastic Surgery and Oncology
Johns Hopkins University
School of Medicine
Baltimore, Maryland
Former Halsted Resident

۰۲۱-۶۶۱۹۸۵۱۴ www.myuptodate.com دریافت آخرین نسخه آپتودیت آفلاین

Matthew J. Weiss, MD
Assistant Professor of Surgery
Section of Hepato-Pancreato-Biliary Surgery
Division of Surgical Oncology
Department of Surgery
Johns Hopkins University
School of Medicine
Baltimore, Maryland
Former Halsted Resident

Glenn J.R. Whitman, MD
Associate Professor of Surgery
Director of Cardiovascular Surgical Intensive Care Unit
Division of Cardiac Surgery
Department of Surgery
Johns Hopkins University
School of Medicine
Baltimore, Maryland

Elizabeth C. Wick, MD
Assistant Professor of Surgery
Department of Surgery
Johns Hopkins University
School of Medicine
Baltimore, Maryland

Bradford D. Winters, MD, PhD
Associate Professor of Anesthesiology and Critical Care Medicine
Assistant Professor of Neurological Surgery
Assistant Professor of Neurology
Assistant Professor of Surgery
Departments of Anesthesiology and Critical Care Medicine and Surgery
Johns Hopkins University
School of Medicine
Baltimore, Maryland

Stephen C. Yang, MD, FACS, FCCP
The Arthur B. and Patricia B. Modell Professor in Thoracic Surgery
Professor of Oncology
Division of Thoracic Surgery
Associate Vice Chair
Department of Surgery
Johns Hopkins University
School of Medicine
Baltimore, Maryland

Martha A. Zeiger, MD, FACS
Professor of Surgery, Oncology, Cellular and Molecular Medicine
Chief
Endocrine Surgery
Associate Vice Chair of Research
Department of Surgery
Johns Hopkins University
School of Medicine
Baltimore, Maryland

۰۲۱-۶۶۱۹۸۵۱۴ www.myuptodate.com دریافت آخرین نسخه آپتودیت آفلاین

PRIOR EDITORS

Charles M. Balch, MD, FACS
Professor of Surgery
Division of Surgical Oncology
Department of Surgery
University of Texas
Southwestern Medical Center
Dallas, Texas

James H. Black III, MD, FACS
The Bertram M. Bernheim, MD Associate Professor of Surgery
Division of Vascular Surgery and Endovascular Therapy
Johns Hopkins University
School of Medicine
Baltimore, Maryland
Former Halsted Resident

Malcolm V. Brock, MD, FACS
Associate Professor of Surgery
Associate Professor of Oncology
Division of Thoracic Surgery
Department of Surgery
Johns Hopkins University
School of Medicine
Baltimore, Maryland
Former Halsted Resident

Stephen M. Cattaneo II, MD
Assistant Professor of Surgery
Johns Hopkins University
School of Medicine
Baltimore, Maryland
Chief
Thoracic Surgery Division
Director
Surgical Oncology
The Anne Arundel Medical Center
Annapolis, Maryland
Former Halsted Resident

Edward E. Cornwell III, MD, FACS, WACS, FCCM
The LaSalle D. Leffall, Jr. Professor and Chairman of Surgery
Surgeon-in-Chief
College of Medicine
Howard University Hospital
Washington, DC

Julie R. Lange, MD, ScM, FACS
Associate Professor of Surgery
Associate Professor of Dermatology
Associate Professor of Oncology
Division of Surgical Oncology
Department of Surgery
Johns Hopkins University
School of Medicine
Baltimore, Maryland

Thomas H. Magnuson MD
Associate Professor of Surgery
Chief of General Surgery
Johns Hopkins Bayview Medical Center
Department of Surgery
Johns Hopkins University
School of Medicine
Baltimore, Maryland
Former Halsted Resident

Paul N. Manson, MD, FACS
Professor of Plastic and Reconstructive Surgery
Department of Plastic and Reconstructive Surgery
Johns Hopkins University
School of Medicine
Baltimore, Maryland

Robert A. Montgomery, MD, DPhil, FACS
Professor of Surgery
Chief, Division of Transplantation Surgery
Department of Surgery
Johns Hopkins University
School of Medicine
Baltimore, Maryland
Former Halsted Resident

Timothy M. Pawlik, MD, MPH, PhD
Professor of Surgery and Oncology
John L. Cameron M.D. Professor of Alimentary Tract Diseases
Chief
Division of Surgical Oncology
Director
Johns Hopkins Medicine Liver Tumor Center
Multi-Disciplinary Clinic
Johns Hopkins University
School of Medicine
Baltimore, Maryland

۰۲۱-۶۶۱۹۸۵۱۴ www.myuptodate.com دریافت آخرین نسخه آپتودیت آفلاین

Theodore N. Tsangaris, MD
Associate Professor of Surgery
Division of Surgical Oncology
Department of Surgery
Yale School of Medicine
New Haven, Connecticut

G. Melville Williams, MD, FACS
Professor of Surgery, Retired
Division of Vascular Surgery and Endovascular Therapy
Department of Surgery
Johns Hopkins University
School of Medicine
Baltimore, Maryland

Christopher L. Wolfgang, MD, PhD
Associate Professor of Surgery
Department of Pathology and Oncology
Chief
Department of Hepatobiliary and Pancreatic Surgery
Johns Hopkins University
School of Medicine
Baltimore, Maryland
Former Halsted Resident

۰۲۱-۶۶۱۹۸۵۱۴ www.myuptodate.com دریافت آخرین نسخه آپتودیت آفلاین

FOREWORD

The American Board of Surgery offers an annual In-Training Examination (ABSITE), a multiple-choice examination that measures the progress of residents in terms of their knowledge of applied science and management of clinical problems. The purpose of the Johns Hopkins ABSITE Review Manual is to provide, in a single text, a comprehensive review of the field of general surgery tailored to the busy surgical resident. This is the second edition of a collective work of many Johns Hopkins (Halsted) residents which has been reviewed by their surgical faculty. In addition to providing a review of current general surgical principles, it is also a practice tool for the examination itself. Not only can this manual be used to review for the ABSITE, but also for the general surgery qualifying examination or for review of topics presented in a concise fashion.

The first edition was published in 2009 and contained a full-length 225 question practice examination with detailed answers written by former Johns Hopkins surgery residents and reviewed by the Hopkins faculty. It was well received both nationally and internationally as a study aid. For the second edition, the authors and editors have completely revised and updated the 225 original questions, and have added a second full-length 225 question examination. This ABSITE review book will be the only one on the market with two full-length, comprehensive, expert faculty-reviewed examinations. Key figures and tables have been included for many of the questions, as well as up-to-date cancer staging and treatment algorithms.

It is indeed fitting that this manual is published by the surgical residents and faculty of the Johns Hopkins University. The most famous surgical resident and faculty member to emanate from the Johns Hopkins Department of Surgery is Dr. John L. Cameron, who also served as Chair and helped to train thousands of surgeons. He is also responsible for disseminating dozens of other Chairs of Surgery around the country.

In many presentations and publications, I have heard him say that until the opening of the Johns Hopkins Hospital in 1889, there was no formal system to train surgeons in the United States. All surgeons were self-trained or learned by way of an apprenticeship, and few spent more than one or two years in a hospital setting. Dr. William Stewart Halsted was named as the first Chair of Surgery at Johns Hopkins and introduced a system in which medical school graduates entered a university-sponsored, hospital-based surgical training program. Over a several-year period of increasing responsibility, these young surgeons became well versed in surgery, anatomy, pathology, bacteriology, and physiology. The training program culminated in a final period of near-total independence and autonomous activity. This training system eventually spread throughout the entire country.

Surgical residents will find this manual extremely helpful in preparation for the ABSITE. The editors and authors have put together a valuable tool and comprehensive review of general surgery for the benefit of surgical residents. It follows in the footsteps of Halsted, Cameron, and other accomplished surgical educators hailing from the Johns Hopkins University.

"Before anything else, preparation is the key to success."—Alexander Graham Bell

Richard D. Schulick, MD, MBA, FACS
The Aragón/Gonzalez-Gíustí Chair
Professor and Chair of the Department of Surgery
University of Colorado School of Medicine
Aurora, Colorado

Halsted Resident, 1989–1997
Johns Hopkins Surgery Faculty, 1999–2012

September 2013

۰۲۱-۶۶۱۹۸۵۱۴ www.myuptodate.com دریافت آخرین نسخه آپتودیت آفلاین

دریافت آخرین نسخه آپتودیت آفلاین www.myuptodate.com ۰۲۱-۶۶۱۹۸۵۱۴

PREFACE

The first edition of this text emanated from the need for a readily available, full-length practice examination for the annual American Board of Surgery In-Training Examination © (ABSITE). The germinal seed was the formation of a curriculum of study for the Halsted Residents in General Surgery at the Johns Hopkins University School of Medicine.

This second edition has been expanded to include two full-length practice examinations: A revised version of the practice examination included in the first edition and a completely new full-length practice examination. Questions in the first practice examination have been revised based upon feedback from faculty and residents from across the country and updated to reflect changes in patient management and surgical science since the first edition was published in 2009.

While two separate examinations were administered for junior (PGY 1 and 2) and senior (PGY 3 to 5) residents starting in 2006, the American Board of Surgery has now resumed administration of a single examination for all general surgery trainees. Therefore, this text is aimed at all surgical residents, irrespective of year of training.

Questions and accompanying explanations were written by Johns Hopkins Halsted surgical residents and edited by faculty members of the Johns Hopkins University School of Medicine (or other institutions as needed). Questions were generated from key words provided by the American Board of Surgery from recent ABSITEs. The distribution of questions is comparable to the ABSITE in both subject content and balance between clinical and basic science emphasis. Explanations are referenced to popular surgical textbooks, journal articles, and websites. The questions are intentionally difficult, designed to challenge students of surgery.

Aside from the key words themselves, none of the information presented in this text was obtained from the American Board of Surgery. Any similarities to actual questions presented in prior ABSITEs are purely coincidental. It is the senior editors' intention that this text be used in conjunction with a structured, regular reading schedule for the education of surgical residents. While we have intended the questions to represent the broad areas of study for the general surgery resident, the text does not serve as a complete survey of the general surgery field.

It is through extensive resident and faculty collaboration that this text has made it to press and into your hands, and we wish to express our deep gratitude to all its contributors. We hope that this text proves useful to surgical residents as they prepare for the ABSITE and seek to master the field of general surgery.

Good luck.

R.A.M., K.J.V.A., P.A.L.

۰۲۱-۶۶۱۹۸۵۱۴ www.myuptodate.com دریافت آخرین نسخه آپتودیت آفلاین

دریافت آخرین نسخه آپتودیت آفلاین www.myuptodate.com ۰۲۱-۶۶۱۹۸۵۱۴

CONTENTS

Contributing Authors v
Section Editors viii
Contributing Editors ix
Prior Editors xiii
Foreword xv
Preface xvii

SECTION I. Full-Length Practice Examination 1 1

Answer Key for Practice Examination 1 47

SECTION II. Questions with Answers and Explanations for Practice Examination 1 . . 51

1. Body as a Whole 53
2. Gastrointestinal 105
3. Cardiovascular and Respiratory 165
4. Miscellaneous (Genitourinary, Head and Neck, Skin, Muscle, and Nervous System). . . 201
5. Endocrine, Hematic, Lymphatic, and Breast 227

SECTION III. Full-Length Practice Examination 2 257

Answer Key for Practice Examination 2 307

SECTION IV. Questions with Answers and Explanations for Practice Examination 2. . 311

1. Body as a Whole 313
2. Gastrointestinal 383
3. Cardiovascular and Respiratory 421
4. Miscellaneous (Genitourinary, Head and Neck, Skin, Muscle, and Nervous System). . . 445
5. Endocrine, Hematic, Lymphatic, and Breast 473

Index by Key Word 497
Index 507

۰۲۱-۶۶۱۹۸۵۱۴ www.myuptodate.com دریافت آخرین نسخه آپتودیت آفلاین

دریافت آخرین نسخه آپتودیت آفلاین www.myuptodate.com ۰۲۱-۶۶۱۹۸۵۱۴

I
FULL-LENGTH PRACTICE EXAMINATION 1

This is the beginning of the first full-length practice examination.

To most closely simulate the actual examination, take this during an uninterrupted 5-hour block of time.

The answer key is located at the end of the examination.

۰۲۱-۶۶۱۹۸۵۱۴ www.myuptodate.com دریافت آخرین نسخه آپتودیت آفلاین

QUESTION 1-1

A 76-year-old dialysis-dependent woman with a history of multiple prior abdominal operations presents to the emergency room with worsening abdominal pain. Workup raises your suspicions for ischemic bowel. She last underwent hemodialysis 3 days prior, and is currently uremic. How will you best prepare the patient for emergent celiotomy?

(A) Administer conjugated estrogens

(B) Administer cryoprecipitate

(C) Administer desmopressin

(D) Arrange for dialysis

(E) Transfuse the patient with packed red blood cells (PRBC)

QUESTION 1-2

A 76-year-old man with aortoiliac occlusive disease undergoes percutaneous transluminal angioplasty of his left common iliac artery. What is the patency rate for patients who undergo angioplasty for iliac occlusive disease?

(A) 10% at 5 years

(B) 20% at 5 years

(C) 30% at 5 years

(D) 60% at 5 years

(E) 80% at 5 years

QUESTION 1-3

A 39-year-old female presents to the emergency department with complaints of watery diarrhea and upper abdominal pain for the past 2 weeks. On workup, she is found to have a small mass in the body of the pancreas on computed tomography scanning. Laboratory abnormalities include a hemoglobin of 8.7 mg/dL, white blood cell count of 10.1, hypokalemia, and a metabolic acidosis. She is subsequently scheduled to have an exploratory laparotomy. Intraoperatively, the mass is removed from her pancreas and multiple small nodules are found in her liver. Considering the most likely diagnosis, what are her best treatment options?

(A) 5-fluorouracil and interferon-alpha

(B) Intravenous steroids alone

(C) No further treatment is indicated

(D) Octreotide and glucocorticoids

(E) Repetitive embolization of the hepatic artery

QUESTION 1-4

A 46-year-old woman comes to the emergency department complaining of acute right lower quadrant pain. How could appendicitis be differentiated from acute ileitis?

(A) Colonoscopic biopsy

(B) Development of acute or subacute pain in the right lower quadrant

(C) Elevated white blood cell count

(D) Presence of diarrhea

(E) Thickened mesenteric lymph nodes on radiographic imaging

QUESTION 1-5

A 27-year-old male with idiopathic renal failure on hemodialysis is awaiting a kidney transplant. Multiple family members and friends have presented to the transplant center for evaluation of possible live donor transplantation. The recipient's brother volunteers to donate his kidney and is found to have a favorable human leukocyte antigen (HLA) match. Which of the following conditions is *least likely* to be considered a contraindication for live kidney donation?

(A) Current cocaine usage

(B) HIV infection

(C) Type II diabetes mellitus

(D) Uncontrollable hypertension

(E) Unilateral duplicated collecting system

QUESTION 1-6

A 39-year-old male is referred to your clinic for treatment of a cecal mass diagnosed by surveillance colonoscopy. His father, paternal grandmother, and paternal uncle all developed colon cancer by their fifth decade. Mutation of which of the following genes is associated with this man's disease?

(A) APC

(B) BRCA1

(C) BRCA2

(D) hMSH2

(E) K-Ras

۰۲۱-۶۶۱۹۸۵۱۴ www.myuptodate.com دریافت آخرین نسخه آپتودیت آفلاین

QUESTION 1-7

A 68-year-old man presents with pain in his left leg. Examination and workup confirm diagnosis of a popliteal aneurysm. What is the most common complication that would result in the patient's leg pain?

(A) Aortic aneurysm rupture
(B) Nerve impingement by the popliteal aneurysm
(C) Popliteal aneurysm rupture
(D) Thromboembolic events associated with the popliteal aneurysm
(E) Venous obstruction by the popliteal aneurysm

QUESTION 1-8

A 52-year-old woman presents to your clinic with a palpable thyroid nodule. Ultrasound shows a 3-cm lesion in the right thyroid lobe with solid and cystic components. Ultrasound-guided fine-needle aspiration (FNA) reveals a thyroid cancer. Which of the following is the most likely diagnosis?

(A) Anaplastic carcinoma
(B) Follicular carcinoma
(C) Medullary carcinoma
(D) Papillary carcinoma
(E) Parathyroid adenocarcinoma

QUESTION 1-9

A 60-year-old man who suffers from chronic alcoholism is admitted to the hospital with an episode of acute pancreatitis. He suffered similar episodes in the past—all of which have resolved without complications. On laboratory studies, he is found to have an elevated serum amylase level. A computed tomography (CT) scan is performed which demonstrates a 4-cm pancreatic pseudocyst. What would be the best subsequent treatment?

(A) Esophagogastroduodenoscopy
(B) Observation and serial CT scans
(C) Percutaneous drainage
(D) Puestow procedure
(E) Simple aspiration

QUESTION 1-10

Which of the following is a characteristic of Merkel cell carcinoma?

(A) Early distant metastases
(B) Frequently cured with wide local excision alone
(C) Histologically similar to squamous cell carcinoma
(D) Locally aggressive tumor with low chance of distant spread
(E) Slow growing, well-defined cutaneous lesion

QUESTION 1-11

A 70-year-old man with ascites secondary to cirrhosis presents for elective umbilical hernia repair. Should he be offered repair of his hernia?

(A) No, he should not be offered repair
(B) Yes, if he had a recent myocardial infarction
(C) Yes, if he is leaking ascites from the hernia
(D) Yes, if he is listed for liver transplant
(E) Yes, if it is significantly affecting his lifestyle

QUESTION 1-12

A 68-year-old man with atrial fibrillation presents to the emergency room with a cool, pulseless right foot. Sensation is intact. Duplex ultrasound of the right leg reveals multiple femoral stenoses and tibioperoneal thrombosis with poor tibial flow. What is the most appropriate management?

(A) Amputation
(B) Diagnostic angiography
(C) Intra-arterial site-directed thrombolysis
(D) Percutaneous embolectomy under local anesthesia
(E) Systemic anticoagulation only

۰۲۱-۶۶۱۹۸۵۱۴ www.myuptodate.com دریافت آخرین نسخه آپتودیت آفلاین

QUESTION 1-13

A 55-year-old woman presents to your clinic with the new diagnosis of tertiary hyperparathyroidism. Which of the following operations has she most likely previously undergone?

(A) Colectomy with resection of terminal ileum

(B) Parathyroidectomy

(C) Renal transplantation

(D) Right middle lung lobectomy

(E) Thyroidectomy

QUESTION 1-14

A 63-year-old man presents with a "gnawing" upper abdominal pain. He reports that he was diagnosed with a gastric ulcer years ago. Which of the following tests is most sensitive in diagnosing the patient with infection with *Helicobacter pylori*?

(A) Histologic examination of endoscopic antral biopsies

(B) Serum antibodies to *H. pylori*

(C) Upper GI radiographic series

(D) Urea breath test

(E) Urease test of endoscopic antral biopsies

QUESTION 1-15

Which of the following is a characteristic of a cutaneous lymphatic malformation?

(A) Bluish mass with overlying telangiectasias

(B) Cystic mass with overlying vesicles

(C) Firm, nodular mass

(D) Irregular mass fixed to the underlying tissues

(E) Pulsatile ballotable mass

QUESTION 1-16

The fundamental goal of the American College of Surgeons National Surgical Quality Improvement Program (NSQIP) is:

(A) To collect outcome data to measure and improve surgical care outcomes

(B) To identify those surgeons who deliver excellent surgical care

(C) To improve health care in underserved US populations

(D) To model systems for improved use of health care resources

(E) To monitor surgical costs in order to allocate health care

QUESTION 1-17

A 73-year-old man has developed a pulseless left lower leg 8 days after experiencing a myocardial infarction (MI) requiring cardiopulmonary resuscitation. On examination, he has diminished sensation in his left foot. What is the most appropriate definitive treatment?

(A) Amputation

(B) Anticoagulation using intravenous heparin

(C) Intra-arterial site-directed thrombolysis

(D) Percutaneous embolectomy under local anesthesia

(E) Surgical bypass

QUESTION 1-18

A 47-year-old woman presents with a rapidly enlarging 5-cm right breast mass without palpable axillary nodes. Fine-needle aspiration (FNA) is nondiagnostic. Core biopsy is performed and results are reported as equivocal, but suggestive of a phyllodes neoplasm. The appropriate next step in management is:

(A) Close follow-up

(B) Simple mastectomy

(C) Tumor enucleation

(D) Tumor excision with a 1-cm margin

(E) Tumor excision with a 2-cm margin and sentinel node biopsy

۰۲۱-۶۶۱۹۸۵۱۴ www.myuptodate.com دریافت آخرین نسخه آپتودیت آفلاین

QUESTION 1-19

A 72-year-old man undergoes percutaneous transhepatic cholangiography (PTC) and percutaneous biliary drainage (PBD) for obstructive jaundice secondary to pancreatic cancer. Following the PTC/PBD, he develops melena and bright red blood is seen in the biliary drain. Laboratory work reveals a drop in hematocrit and increase in his liver function tests. What is the definitive treatment for this change in his condition?

(A) Biliary stent placement

(B) Endoscopic epinephrine injection at the site of the bleeding vessel

(C) Hepatic resection

(D) Transarterial embolization

(E) Whipple procedure

QUESTION 1-20

During resection of a pelvic tumor, the left ureter is inadvertently transected below the level of the pelvic brim. The *immediate* treatment of this problem is:

(A) Delayed repair and percutaneous drainage of urinoma

(B) Diversion with ureteroenterostomy

(C) Primary repair

(D) Primary repair with ureteral stent

(E) Ureterocystostomy

QUESTION 1-21

Four weeks after a deceased donor kidney transplant, the recipient returns to the emergency department with bilateral lower-extremity edema. In spite of normal fluid intake, he reports that he has had minimal urine output over the past 18 hours. Serum creatinine is now elevated to 1.4 mg/dL from 1.0 mg/dL postoperatively. After failure to respond to a fluid challenge, an ultrasound is obtained. This reveals good perfusion, minimal hydronephrosis and, a 3- × 4- × 6-cm hypoechoic mass adjacent to the renal pelvis of the allograft. What is the most likely cause of the patient's oliguria?

(A) Compressive hematoma

(B) Lymphocele formation

(C) Renal artery stenosis

(D) Renal artery thrombosis

(E) Ureteroneocystostomy stenosis

QUESTION 1-22

Eighteen months after undergoing an aortobifemoral artery bypass, a 74-year-old man presents with a painful swelling in his left groin. Ultrasound demonstrates a pseudoaneurysm at the site of the distal anastomosis with surrounding fluid. What is the likely underlying cause of this finding?

(A) Atheroembolism

(B) Graft failure

(C) Graft infection

(D) Graft thrombosis

(E) Suture failure

QUESTION 1-23

A 38-year-old woman is referred to your clinic after an elevated 24-hour urine cortisol measurement. She is not on any steroids. What is the most likely cause of this patient's disease?

(A) Adrenal adenoma

(B) Adrenal carcinoma

(C) Factitious insulin use

(D) Ovarian cancer

(E) Pituitary adenoma

QUESTION 1-24

A 36-year-old woman underwent banding for an internal hemorrhoid 1 week ago. She contacts your office complaining of a small amount of blood on toilet paper after defecation, but denies pain or fever. The next step in her management is:

(A) Direct the patient to the emergency room

(B) Instruct the patient to apply cold compresses to the perineum

(C) Instruct the patient to take fiber supplementation and increase fluid intake

(D) Prescribe nifedipine ointment BID to the perianal region

(E) Tell the patient there is nothing to do

۰۲۱-۶۶۱۹۸۵۱۴ www.myuptodate.com دریافت آخرین نسخه آپتودیت آفلاین

QUESTION 1-25

A 32-year-old male is brought to the emergency department after his left leg was pinned between two cars. Upon examination, his left leg is swollen and tense below the knee and you suspect compartment syndrome. Which nerve is most commonly injured during fasciotomy of the lower leg?

(A) Deep peroneal nerve
(B) Lateral femoral cutaneous nerve
(C) Saphenous nerve
(D) Superficial peroneal nerve
(E) Tibial nerve

QUESTION 1-26

While visualizing the gallbladder during an elective laparoscopic cholecystectomy, the anesthesiologist informs you that the patient has a heart rate of 130, and a dropping blood pressure. What is the *FIRST* step in management?

(A) Decrease insufflation pressure
(B) Give inotropes for blood pressure
(C) Give IV fluids
(D) Position the patient in the left lateral decubitus position
(E) Stop insufflation

QUESTION 1-27

Eighteen months after undergoing an aortobifemoral artery bypass, a 69-year-old woman presents with a draining, cellulitic wound in her right groin, with exposed polytetrafluoroethylene (PTFE) graft. What is the most likely pathogen infecting this graft?

(A) *Enterobacter cloacae*
(B) *Klebsiella pneumoniae*
(C) *Pseudomonas aeruginosa*
(D) *Staphylococcus aureus*
(E) *Staphylococcus epidermidis*

QUESTION 1-28

A 40-year-old premenopausal woman is seen by her physician for evaluation of a breast nodule. Physical examination confirms the presence of a 1-cm movable mass; mammogram and ultrasound evaluation are both found to be consistent with a fibroadenoma. A core biopsy confirms this diagnosis. The lesion is excised at the patient's request. Pathology results reveal a fibroadenoma with a small area of lobular carcinoma in situ (LCIS) in the surrounding breast tissue, focally extending to one margin. The next step in management is:

(A) A partial mastectomy with sentinel lymph node biopsy
(B) Counsel the patient about their future breast cancer risk and screening options
(C) Remove further tissue from the positive margin side
(D) Remove further tissue from the positive margin side with axillary node dissection
(E) Sentinel lymph node biopsy alone

۰۲۱-۶۶۱۹۸۵۱۴ www.myuptodate.com دریافت آخرین نسخه آپتودیت آفلاین

QUESTION 1-29

A 56-year-old man 2 years status post left colectomy for stage IIA colon cancer is now found to have rising carcinoembryonic antigen (CEA) and two new lesions in the liver on follow-up CT scan (see scans below). There is no evidence of extrahepatic disease. How do you manage this patient?

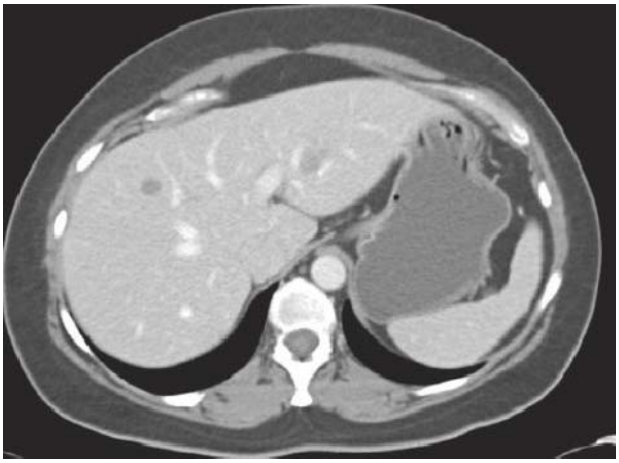



(A) Extended left hepatectomy

(B) Orthotopic liver transplantation

(C) Palliative chemotherapy

(D) Radiofrequency ablation of the two tumors

(E) Y-90 intra-arterial therapy

QUESTION 1-30

A 56-year-old man presents to your clinic with a 5-mm wide lesion confined to the middle of his lower lip. Biopsy confirms squamous cell carcinoma. What is the most appropriate management?

(A) Radiation therapy alone

(B) Radiation therapy followed by surgical resection with 5-mm margin and primary repair

(C) Surgical resection with 1-cm margin and primary repair

(D) Surgical resection with 1-cm margin and primary repair, followed by radiation therapy

(E) Surgical resection with 5-mm margin and primary repair

QUESTION 1-31

A 26-year-old male is undergoing a nerve block for an outpatient orthopedic procedure on his left ankle. During injection of the superficial fibular nerve with lidocaine, he complains of tingling around his mouth and lips. What other symptom would be consistent with lidocaine toxicity?

(A) Hallucinations

(B) High fever

(C) Muscle rigidity

(D) Peripheral paralysis

(E) Skin ischemia

QUESTION 1-32

A 64-year-old man undergoes endovascular repair of a 5.9-cm infrarenal abdominal aortic aneurysm with bilateral iliac artery involvement. The patient does well postprocedurally and is discharged home 4 days later. A 6-month follow-up CT reveals contrast extravasation into the aneurysm sac at the proximal aspect of the aneurysm and an interval increase in the aneurysm size to 6.3 cm. What type of endoleak is described, and what is the best management?

(A) Type I endoleak; observation

(B) Type I endoleak; urgent endovascular repair

(C) Type II endoleak; urgent open surgical repair

(D) Type III endoleak; observation

(E) Type III endoleak; urgent endovascular repair

۰۲۱-۶۶۱۹۸۵۱۴ www.myuptodate.com دریافت آخرین نسخه آپتودیت آفلاین

QUESTION 1-33

A 64-year-old postmenopausal woman with Estrogen Receptor Positive (ER+), stage I breast cancer presents following lumpectomy, and radiation therapy, now on therapy with tamoxifen. She asks about the risks of tamoxifen therapy. You tell her that:

(A) Tamoxifen decreases the likelihood of developing all types of cancer

(B) Tamoxifen has been linked to an increased risk of developing endometrial adenocarcinoma and uterine sarcoma

(C) Tamoxifen increases bone resorption, increasing risk of long bone and pelvic fractures due to osteoporosis

(D) Tamoxifen increases the likelihood of developing breast cancer in the contralateral breast

(E) Tamoxifen is associated with a modest, but significant increase in the risk of cardiovascular events seen in postmenopausal women with coronary artery disease

QUESTION 1-34

Workup for vomiting in a 46-year-old woman with Crohn disease reveals a stricture in the second portion of the duodenum. What is the best surgical management of this problem?

(A) Heineke–Mikulicz strictureplasty

(B) Pylorus-preserving pancreaticoduodenectomy (Whipple procedure)

(C) Resection of the affected segment with primary anastomosis

(D) Roux-en-Y duodenojejunostomy

(E) Side-to-side retrocolic gastrojejunostomy

QUESTION 1-35

A 17-year-old male presents to the emergency department after a right shoulder injury sustained while playing football. Plain radiographs reveal the humeral head displaced medial to the glenoid fossa. Which nerve is most likely injured in this type of dislocation?

(A) Axillary nerve

(B) Median nerve

(C) Radial nerve

(D) Suprascapular nerve

(E) Sural nerve

QUESTION 1-36

An obese woman who underwent a transabdominal hysterectomy 10 years ago presents for an elective ventral hernia repair. She undergoes hernia repair via a laparoscopic approach, to which she responds well initially. However, she develops a recurrent bulge 2 months later and presents to your office for counseling. What is the most common reason for recurrence after laparoscopic ventral hernia repair?

(A) Failure of suture material or tacks

(B) Inadequate dissection of the fascial defect

(C) Separation of the mesh from the abdominal wall

(D) Seroma formation

(E) Unrecognized defect

QUESTION 1-37

What is the most common cause of late death after heart transplant?

(A) Acute graft rejection

(B) Accelerated atherosclerosis

(C) Cytomegalovirus (CMV) infection

(D) Fungal infection

(E) Ventilator-associated pneumonia

QUESTION 1-38

A 48-year-old male presents with persistent peptic ulcers that have been refractory to proton-pump inhibitors. His workup includes a positive secretin stimulation test. His underlying tumor is:

(A) Associated with hypoglycemia

(B) Associated with MEN 2A

(C) Associated with Whipple triad

(D) Frequently located in the tail of the pancreas

(E) Likely to be sporadic

۰۲۱-۶۶۱۹۸۵۱۴ www.myuptodate.com دریافت آخرین نسخه آپتودیت آفلاین

QUESTION 1-39

A 38-year-old male presents to the emergency department after attempted suicide via ingestion of oven cleaner. Upon rigid esophagoscopy, you observe erythematous, friable, mucosa with superficial, noncircumferential white ulcerations in the mid-esophagus. What degree of injury is this lesion?

(A) Grade I
(B) Grade IIA
(C) Grade IIB
(D) Grade III
(E) Grade IV

QUESTION 1-40

A 32-year-old female requires a split-thickness skin graft after being involved in a car accident. A 12- × 6-cm site is harvested from her lateral thigh and is implanted on her scalp without complications. The healing rate at the donor site is most related to:

(A) Amount of moisture kept on the donor site
(B) Epithelial appendages and thickness of graft
(C) Epithelial appendages and width of the site
(D) Quality of semi-occlusive dressing
(E) Thickness of graft and moisture on donor site

QUESTION 1-41

A 21-year-old male is brought to the trauma bay after sustaining a superficial stab-wound to the left shoulder. He reports that he received his full series of shots as a child, and received his last tetanus booster shot when he was 15. What should he receive for his tetanus prophylaxis?

(A) Amoxicillin 500-mg PO TID
(B) Nothing
(C) Tetanus immune globulin (TIG) 250-units IM
(D) Tetanus toxoid (dT) 0.5-mL IM
(E) Tetanus toxoid (dT) 0.5-mL IM and TIG 250-units IM

QUESTION 1-42

A 72-year-old man is seen in clinic preoperatively to prepare for his upcoming femoral–tibial artery bypass for vascular insufficiency. The duplex scan demonstrates poor candidates for venous conduits, so the use of synthetic graft is anticipated. The long-term outcome for this patient could be improved by:

(A) Clopidogrel use for the first 3 months after surgery
(B) Daily use of 81-mg aspirin indefinitely
(C) Low-molecular-weight heparin injections for the first 6 weeks after surgery
(D) The use of support stockings
(E) Warfarin use with a goal International Normalization Ratio (INR) of 1.5

QUESTION 1-43

A 25-year-old male sustains a superficial gunshot wound to his left proximal, lateral thigh, near the anterior superior iliac spine. His initial neurologic examination in the emergency department reveals no motor deficits but numbness in the region of the left lateral cutaneous nerve of the thigh. When should surgery for repair of the suspected nerve injury be performed?

(A) 1 to 2 weeks
(B) 2 to 3 months
(C) 6 months to 1 year
(D) Immediately
(E) Never

QUESTION 1-44

A 40-year-old male former Australian lifeguard with a history of melanoma presents to the emergency department with a month-long history of abdominal pain, nausea, and vomiting. What is the most likely cause for his symptoms?

(A) Colonic obstruction
(B) Diverticulitis
(C) Duodenal adenocarcinoma
(D) Gastroenteritis
(E) Intussusception of the small bowel

۰۲۱-۶۶۱۹۸۵۱۴ www.myuptodate.com دریافت آخرین نسخه آپتودیت آفلاین

QUESTION 1-45

Which of the following characteristics is an advantage of full-thickness skin grafts (FTSGs) over split-thickness skin grafts (STSGs)?

(A) Appropriate for larger defects

(B) Better for contaminated tissue beds

(C) Better resistance to infection

(D) Less nutritional demand

(E) Lower incidence of contractures

QUESTION 1-46

A 56-year-old male is ventilator dependent due to an open abdomen secondary to trauma. On the third day following his injury, he develops hypoxemia and tachypnea requiring an increase of the fraction of inspired oxygen (FiO_2) and positive end-expiratory pressure (PEEP). His partial pressure of oxygen in arterial blood (PaO_2) increases minimally with these changes. Plain chest radiograph shows bilateral infiltrates and pulmonary artery occlusion pressure is 16 mm Hg. Which combination of features would support a diagnosis of acute respiratory distress syndrome (ARDS) over ventilator-associated pneumonia (VAP)?

(A) PaO_2/FiO_2 ratio <200 mm Hg

(B) Pulmonary artery occlusion pressure ≥18 mm Hg

(C) Temperature 38.3°C, WBC = 12, minimal pleural effusion, increased protein on bronchoalveolar lavage (BAL), infiltrates not seen on chest radiograph

(D) Temperature 38.5°C, WBC = 16, no effusions, increased protein on BAL

(E) Temperature 38.7°C, WBC = 14, pleural effusions, increased protein on BAL

QUESTION 1-47

A 28-year-old female professional violinist presents with headaches, neck pain, and hand clumsiness in her right hand. She also reports occasional numbness in the hand and right-sided chest pain. Which of the following is the likely cause of her symptoms?

(A) Carpal tunnel syndrome

(B) Coronary artery disease

(C) Osteoarthritis

(D) Paget–Schroetter syndrome

(E) Thoracic outlet syndrome (TOS)

QUESTION 1-48

A 72-year-old man with a history of diabetes and smoking presents with a 2-day history of excruciating pain in the right lower extremity. The patient states that the pain started while he was sitting in a chair, and that, unlike other pains he has had in the leg before, it was not relieved by elevation of the extremity. Physical examination shows a pale, cool, pulseless, and numb right foot and the calf is quite tender. No pedal Doppler signal is obtainable. The patient is taken to the operating room where on-table angiogram reveals occlusion of the superficial femoral artery. A right femoral below knee popliteal bypass is performed with restoration of the pulses. Postoperatively in the surgical intensive care unit, the resident notices severe swelling of the right lower extremity and loss of the dorsalis pedis pulse. The most likely etiology of the edema is:

(A) Acute bleed from anastomotic leak

(B) Acute popliteal venous occlusion

(C) Acute reperfusion injury

(D) Chronic venous occlusive disease

(E) Lymphocele

QUESTION 1-49

A 22-week pregnant, 31-year-old woman received 7 days of ampicillin for a urinary tract infection. The patient developed diarrhea on day 5 of therapy, and stool is positive for *Clostridium difficile* toxin. How would you treat the patient?

(A) Clindamycin 300-mg PO QID for 10 days

(B) Do nothing, this is usually self-limiting

(C) Metronidazole 500-mg PO QID for 10 days

(D) Vancomycin 500-mg PO QID for 10 days

(E) Vancomycin 500-mg PR QID for 10 to 14 days

۰۲۱-۶۶۱۹۸۵۱۴ www.myuptodate.com دریافت آخرین نسخه آپتودیت آفلاین

QUESTION 1-50

You are performing a laparoscopic cholecystectomy on a 64-year-old woman with a history of cholelithiasis and vague abdominal pain. As you insert the camera through the supraumbilical trocar, you are surprised to find white cake-like tumor spreading from the left pelvis across much of the large intestine. You should:

(A) Perform a biopsy, convert to an open procedure, and perform complete surgical staging

(B) Perform a biopsy, convert to an open procedure, and remove all involved organs

(C) Perform a left oophorectomy

(D) Take a biopsy of the tumor, close, and await the pathology report to plan open surgery

(E) Take a biopsy of the tumor, remove the gallbladder, and finish the case

QUESTION 1-51

A 2-year-old boy is brought to the emergency department by his mother. She reports that he has been inconsolable for the past 24 hours and has refused his feeds. Upon further questioning, the physician finds that the child has vomited twice and has not had a bowel movement. Examination reveals a slightly distended and diffusely tender abdomen, especially in the inguinal area, without signs of peritonitis. What should be your first step?

(A) Arrange for immediate groin exploration in the operating room without attempting manual reduction

(B) Elevation of the child's lower extremities with a pillow, followed by an attempt at manual reduction

(C) Emergent exploratory laparotomy

(D) Apply ice pack to the affected area

(E) Overnight inpatient observation

QUESTION 1-52

An 82-year-old man with a history of severe chronic obstructive pulmonary disease (COPD) presents with claudication and is found to have occlusive disease localized to the left common iliac artery. Which of the following procedures is the most appropriate for management of this patient's disease?

(A) Anticoagulation using intravenous heparin

(B) Aortobifemoral artery bypass with synthetic graft

(C) Conservative treatment

(D) Femoral to femoral artery bypass with venous autograft

(E) Percutaneous transluminal angioplasty (PTA) under local anesthesia

QUESTION 1-53

A 47-year-old woman undergoes core-needle biopsy of a lesion found on routine mammography in the lower, outer quadrant of her right breast. Pathology is read as atypical ductal hyperplasia (ADH) of the breast. What is the most appropriate next step in this patient's management?

(A) Axillary lymph node dissection

(B) Excisional biopsy with wire localization

(C) Follow-up mammography in 6 months

(D) Modified radical mastectomy

(E) Partial mastectomy with sentinel lymph node biopsy

QUESTION 1-54

A 43-year-old man presents to your clinic complaining of intermittent blood spotting on toilet paper for 2 weeks. Anoscopy reveals a 1-cm split in the anoderm posteriorly on the midline distal to the dentate line, lacking any hypertrophy or visible muscle fibers. What is the optimal management?

(A) Bisacodyl suppositories

(B) Initiate stool softeners

(C) Lateral internal anal sphincterotomy

(D) Observation only

(E) Resection of affected tissue

۰۲۱-۶۶۱۹۸۵۱۴ www.myuptodate.com دریافت آخرین نسخه آپتودیت آفلاین

QUESTION 1-55

A 22-year-old male (65 kg) is seen in the emergency department after a motorcycle accident that resulted in significant head and maxillofacial trauma. Following initial evaluation and stabilization, he is admitted to the intensive care unit with lactated Ringer (LR) solution running at 125 mL/hr. During the first 60 hours of his stay, his urine output gradually declines to 25 mL/hr and his serum sodium drops from 136 to 127 mEq/L. His vital signs remain stable. Urine osmolarity is found to be 548 mOsm/L. Which of the following is the next best intervention?

(A) Add demeclocycline 600 mg BID

(B) Convert his fluids from LR to 3% normal saline

(C) Increase his fluids to maintain urine output >0.5 mL/kg/hr

(D) Start fludrocortisone 0.1 mg QDay

(E) Stop his fluids entirely

QUESTION 1-56

A 45-year-old woman with a history of gallstones is admitted to the intensive care unit after diagnosis with acute pancreatitis with hemodynamic instability. Her admission laboratory values were remarkable for a number of abnormalities, including hyponatremia, hyperamylasemia, hyperlipasemia, and hyperlipidemia. What is the etiology of hyponatremia in pancreatitis?

(A) Hypoalbuminemia

(B) Pseudohyponatremia

(C) Renal failure

(D) Salt wasting

(E) Syndrome of inappropriate anti-diuretic hormone (SIADH)

QUESTION 1-57

A previously healthy 63-year-old woman began to complain of increased shortness of breath and chest pain while undergoing a root canal. After stopping the procedure, her symptoms resolved, and the oral surgeon resumed drilling. She began experiencing right facial pain and periorbital and neck swelling and subsequently complained of severe dyspnea. The patient's blood pressure then became undetectable. An emergent ECG showed nonspecific ST wave changes. Her pulse oximeter revealed an oxygen saturation of 89% to 90% throughout the procedure. *Immediate* action should be?

(A) Administration of intravenous fluids

(B) Bilateral tube thoracostomy placement

(C) Initiation of intravenous antibiotics

(D) Intravenous heparin therapy and/or thrombolytic therapy

(E) Position the patient in left lateral decubitus Trendelenburg position

QUESTION 1-58

A 34-year-old male Ukrainian immigrant is seen in clinic for a right-sided thyroid nodule, which shows no uptake on technetium scan. In 1986, he was living near the Chernobyl nuclear reactor during its melt-down. Given this history and probable etiology, what is the most likely diagnosis of his thyroid nodule?

(A) Anaplastic carcinoma

(B) Follicular carcinoma

(C) Hürthle cell carcinoma

(D) Medullary carcinoma

(E) Papillary carcinoma

۰۲۱-۶۶۱۹۸۵۱۴ www.myuptodate.com دریافت آخرین نسخه آپتودیت آفلاین

QUESTION 1-59

A 54-year-old alcoholic man presents to the emergency department with severe substernal and epigastric pain after vomiting while drinking earlier that evening. Gastrografin esophagogram shows perforation of the distal esophagus with drainage into the left pleural space. What is the most appropriate treatment?

(A) Emergent primary repair via left thoracotomy

(B) Esophageal stent placement

(C) Esophagectomy and delayed reconstruction with interposition graft

(D) Esophagostomy and placement of a feeding jejunostomy tube

(E) Nonoperative management with total parenteral nutrition and nasogastric decompression

QUESTION 1-60

The appropriate treatment for an 8-year-old with a completely displaced supracondylar fracture of the humerus (Gartland type III) is:

(A) Closed reduction and immobilization

(B) Closed reduction and internal fixation

(C) Elbow replacement

(D) Intramedullary rod placement

(E) Splinting and immobilization

QUESTION 1-61

A 42-year-old woman is in the intensive care unit immediately following removal of a left adrenal pheochromocytoma. Her blood pressure is 80/40 mm Hg. The most appropriate treatment of the patient's hypotension is:

(A) Epinephrine

(B) IV bolus of lactated Ringer solution

(C) Methylprednisolone

(D) Phenoxybenzamine

(E) Phenylephrine

QUESTION 1-62

A 24-year-old man presents to the emergency department after sustaining two gunshots through his chest. Which of the following would suggest that he has lost 30% to 40% of his blood volume?

(A) HR 90, normal blood pressure, normal or increased pulse pressure, urine output >30 mL/hr

(B) HR 110, normal blood pressure, increased pulse pressure, urine output >30 mL/hr

(C) HR 110, normal blood pressure, narrowed pulse pressure, urine output 20 to 30 mL/hr

(D) HR >120, decreased blood pressure, very decreased pulse pressure, respiratory rate 30 to 40, urine output 5 to 15 mL/hr

(E) HR >140, very decreased blood pressure, respiratory rate >35, negligible urine output

QUESTION 1-63

A 42-year-old woman presents with the presumed diagnosis of inflammatory carcinoma of her left breast. She is 8 weeks postpartum. What is the appropriate management?

(A) If the tumor does not respond to neoadjuvant chemotherapy, proceed to mastectomy

(B) If the tumor responds to an extended course of antibiotics, continue with local resection

(C) If the tumor responds to high-dose chemotherapy, continue with mastectomy, postoperative radiation, then possible further adjuvant therapy

(D) If the tumor responds to high-dose chemotherapy, continue with radiation therapy, followed by surgical resection, then chemotherapy

(E) If the tumor responds to neoadjuvant chemotherapy, proceed to local excision

۰۲۱-۶۶۱۹۸۵۱۴ www.myuptodate.com دریافت آخرین نسخه آپتودیت آفلاین

QUESTION 1-64

A 60-year-old man with a long history of smoking and heavy alcohol use undergoes a transhiatal esophagectomy for esophageal cancer. He does well and is discharged from the intensive care unit on the second postoperative day. However on the third day he develops a fever and malaise. A chest and neck CT scan demonstrates severe inflammation as indicated by stranding around, and wall thickening of, the gastric conduit but no intramural air. Which vascular supply to the stomach may have been compromised during the transhiatal esophagectomy?

(A) Gastroduodenal artery
(B) Left gastric artery
(C) Left gastroepiploic artery
(D) Right gastroepiploic artery
(E) Short gastric arteries

QUESTION 1-65

On initial assessment the most important predictor of return of function in a patient with a severe head injury is:

(A) Intracranial pressure greater than 15 mm Hg
(B) Overall Glasgow Coma Scale (GCS) score
(C) Poor eye opening score component of the GCS
(D) Poor motor score component of the GCS
(E) Poor verbal score component of the GCS

QUESTION 1-66

A 7-week-old boy is referred with a 3-day history of projectile nonbilious vomiting. He appears dehydrated and, on abdominal examination, an olive-shaped epigastric mass is palpable. The most appropriate initial IV fluid regimen for resuscitation is:

(A) 2% sodium chloride
(B) 5% dextrose
(C) Lactated Ringer
(D) Normal saline
(E) Normal saline + 20-mmol/L potassium chloride

QUESTION 1-67

A 67-year-old woman with long-standing diabetes presents to clinic stating that she has noticed some breakdown of the skin on the bottom of her right foot. Examination of the foot reveals a shallow ulcer overlying the area of the metatarsal heads with surrounding erythema. Radiograph of the foot reveals no bony involvement. How should you counsel her?

(A) She should be admitted to the hospital for aggressive wound care
(B) She should clean the wound with warm soaks and then put on clean socks
(C) She should obtain well-fitting shoes
(D) She will likely need a distal arterial bypass
(E) She will need a transmetatarsal amputation

QUESTION 1-68

A 65-year-old female complaining of weakness, fatigue, and easy bruising, is found to have guarding and distention of her upper abdomen. She reports a history of taking prednisone and weekly epoetin-α. She feels her symptoms have become worse in the past year. What procedure would this patient need for definitive management of this condition?

(A) Bone marrow biopsy
(B) Gastrectomy
(C) Laparoscopic adrenalectomy
(D) Laparoscopic splenectomy
(E) Patient requires no surgical management

۰۲۱-۶۶۱۹۸۵۱۴ www.myuptodate.com دریافت آخرین نسخه آپتودیت آفلاین

QUESTION 1-69

You are called by the Intensive Care Unit (ICU) regarding a 45-year-old man intubated for ARDS for the past 3 weeks. Over the past 48 hours, he has developed increased abdominal distension. His last bowel movement was 4 days ago, and the ICU staff has attempted multiple enemas without result. An abdominal plain film has revealed diffuse dilation of the colon consistent with ileus, without an identifiable transition point. Your physical examination demonstrates a critically ill man with a rotund abdomen. There is no fluid wave or shifting dullness, just diffuse tympany. There is no stool in the rectal vault. How should you proceed with treatment?

(A) Endoscopic decompression

(B) Manual disimpaction

(C) Nasogastric-tube decompression and serial examinations

(D) Neostigmine

(E) Therapeutic enteroclysis

QUESTION 1-70

For an oral squamous cell carcinoma with 4-mm depth of invasion without palpable lymph nodes, the appropriate surgical treatment entails:

(A) Excision plus supraomohyoid neck dissection

(B) Local excision alone

(C) Radiation therapy

(D) Radical neck dissection

(E) Sentinel lymph node biopsy using blue dye

QUESTION 1-71

A 45-year-old female is in the SICU 2 days postoperative from an orthotopic liver transplant for primary biliary cirrhosis. The patient's condition has rapidly deteriorated, with signs consistent with fulminant hepatic failure. Ultrasound of the graft is most likely to reveal which of the following?

(A) Hepatic artery thrombosis

(B) Hepatic vein thrombosis

(C) Inferior vena cava stenosis

(D) Portal vein stenosis

(E) Portal vein thrombosis

QUESTION 1-72

A 30-year-old man presents with facial swelling, engorged neck veins, and complaints of dizziness for the prior 3 months. Two years previously, he was diagnosed with unresectable malignant thymoma, but completed only two rounds of radiotherapy. How should you proceed with treatment?

(A) Balloon angioplasty and endovascular stenting of the superior vena cava (SVC)

(B) Exploratory thoracotomy

(C) Extra-anatomic bypass from the internal jugular to the femoral vein

(D) Inpatient heparinization until therapeutic on warfarin

(E) Internal jugular to right atrial bypass

QUESTION 1-73

A 42-year-old man presents with progressive fullness and abdominal cramping increasing in severity over the past 4 weeks. Computed tomography (CT) reveals a large intra-abdominal mass with multiple enlarged inguinal and cervical lymph nodes visible. Which of the following tests is diagnostic of this patient's possible intra-abdominal lymphoma?

(A) CT scan

(B) CT-guided needle biopsy

(C) Open biopsy

(D) Positron emission tomography (PET) scan

(E) T_2-weighted Magnetic Resonance Imaging (MRI)

QUESTION 1-74

An 88-year-old woman presents from a nursing home with altered mental status and abdominal distension. She has a history of gallstones and has never had abdominal surgery. On examination, she is febrile and tachycardic and has a distended, tender abdomen that is tympanitic to percussion. A plain abdominal film demonstrates dilated loops of small bowel with air in the biliary tree. What is your proposed management?

(A) A trial of nasogastric tube decompression, IV fluids, bowel rest

(B) ERCP and stent placement

(C) Exploratory laparotomy

(D) Family meeting and likely comfort care measures only given extremely poor prognosis

(E) Laparoscopic cholecystectomy

۰۲۱-۶۶۱۹۸۵۱۴ www.myuptodate.com دریافت آخرین نسخه آپتودیت آفلاین

QUESTION 1-75

The cerebral perfusion pressure (CPP) in a patient with head injury should ideally be greater than:

(A) 30 mm Hg

(B) 50 mm Hg

(C) 70 mm Hg

(D) 90 mm Hg

(E) 110 mm Hg

QUESTION 1-76

A 55-year-old man presents with a firm mass on his left thigh, which he noticed recently after bumping into a chair. The mass is painless, not discolored, and 5 cm in diameter. What is the next diagnostic test you should perform?

(A) Excisional biopsy

(B) Fine-needle aspiration

(C) Incisional biopsy

(D) Magnetic resonance imaging (MRI) scan

(E) Wide excision with 2-cm margins

QUESTION 1-77

A 45-year-old woman was found on physical examination to have a right thyroid nodule. Ultrasound of the thyroid demonstrated a 2.5-cm hypoechoic nodule, which was identified as papillary thyroid cancer on fine-needle aspiration (FNA). What is the best next step in the management of this patient?

(A) Obtain Computed Tomography (CT) scan of the neck

(B) Obtain Integrated Positron Emission Tomography and Computed Tomography (PET-CT) scan for complete staging

(C) Obtain ultrasound of the neck to evaluate for lymphadenopathy

(D) Proceed to surgery without other studies

(E) Repeat the FNA to confirm the diagnosis

QUESTION 1-78

A 35-year-old woman presents with complaint of a bloody discharge from the left nipple. Clinical breast examination confirms inducible discharge from a single duct in the left nipple and a small palpable mass near the inferior areolar margin. Bilateral mammogram and left ultrasound show a small density that appears to correspond to the palpable mass, which measures 8 mm by ultrasound and is solid. The lesion is amenable to ultrasound-guided core biopsy. Which of the following is correct?

(A) If a core biopsy confirms a benign papilloma, no further intervention is needed

(B) If core-needle biopsy confirms intraductal papilloma, then proceed to local excision with postoperative routine breast screening examination

(C) If local excision shows DCIS, the patient can return to routine breast screening with no further intervention needed

(D) This is most likely a benign process, does not need to be biopsied, and should be followed with clinical breast examination and mammogram every 6 months

(E) Unilateral bloody discharge is usually associated with a history of breast trauma

QUESTION 1-79

A 54-year-old woman comes to clinic 3 weeks after undergoing a common bile duct exploration for biliary stones refractory to endoscopic management. She was left with a T-tube in place, which has been reliably draining bile until 2 days ago. Over the past 48 hours, she has noted increased right upper quadrant pain that is similar to her preoperative pain. You order a tube cholangiogram, which demonstrates a retained stone lodged in the common bile duct. How should you proceed?

(A) Admit to the hospital, make NPO with IVF, provide analgesia and observe

(B) Endoscopic retrograde cholangiopancreatography (ERCP)

(C) Laparoscopic stone extraction

(D) Remove the T-tube and perform immediate choledochoscopy

(E) Repeat open common bile duct exploration

۰۲۱-۶۶۱۹۸۵۱۴ www.myuptodate.com دریافت آخرین نسخه آپتودیت آفلاین

QUESTION 1-80

A 78-year-old African American female with hypertension and diabetes mellitus falls in her kitchen and lacerates her right great toe. Three hours later, her family brings her to the emergency department because she has developed severe erythema migrating up her leg, fever to 40°C (104°F) and a marked change in her mental status. Examination of the wound reveals severe edema of the surrounding skin, marked erythema proceeding up the leg and crepitus to palpation. Her laboratory values show a lactate of 6.7 mmol/L. What is the most appropriate course of treatment?

(A) Gram-negative antibiotic coverage, IV fluid resuscitation, surgical debridement

(B) Gram-positive antibiotic coverage, IV fluid resuscitation, surgical debridement

(C) Immediate surgical debridement, IV fluid resuscitation, broad-spectrum antibiotics

(D) IV fluid resuscitation, broad-spectrum antibiotics, observation

(E) Observation, IV fluid resuscitation, surgical debridement after complete manifestation of disease (days)

QUESTION 1-81

A 42-year-old man with marked ascites is being treated with lactulose for hepatic encephalopathy secondary to alcoholic cirrhosis. What is the most likely acid–base abnormality found in this patient?

(A) Anion gap metabolic acidosis

(B) Metabolic alkalosis

(C) Normal anion gap metabolic acidosis

(D) Respiratory acidosis

(E) Respiratory alkalosis

QUESTION 1-82

A 52-year-old woman was found to have a single left thyroid nodule measuring 3 cm on ultrasound. She has no known risk factors for thyroid cancer and denies any compressive symptoms in the neck. Her thyroid function tests are normal and fine-needle aspiration (FNA) was performed. Cytology examination reported "follicular neoplasm" as the diagnosis. What is the next best step in the management of this patient?

(A) Obtain a core-needle biopsy of the suspicious nodule

(B) Obtain a radioactive iodine thyroid scan

(C) Perform left hemithyroidectomy

(D) Perform left hemithyroidectomy with intraoperative frozen section to decide on need for total thyroidectomy

(E) Repeat the FNA

QUESTION 1-83

A 40-year-old woman has been recently diagnosed with multiple endocrine neoplasia type IIa (MEN 2A). Her most recent laboratory studies are significant for elevated urinary metanephrines and hypercalcemia. A cold thyroid nodule has been identified on radioisotope imaging and computed tomography of the abdomen reveals a left adrenal mass. She has elected to undergo operative intervention and asks you which surgical procedure should be performed first. Based on current recommendations, you schedule her for the following procedure:

(A) Adrenalectomy

(B) Pituitary adenectomy

(C) Single-gland parathyroidectomy

(D) Thyroid lobectomy

(E) Total thyroidectomy alone

۰۲۱-۶۶۱۹۸۵۱۴ www.myuptodate.com دریافت آخرین نسخه آپتودیت آفلاین

QUESTION 1-84

A 65-year-old man presents with rectal pain, pencil-thin stools and occasional bright red blood per rectum. A rectal examination under anesthesia reveals a 1-cm raised lesion at the anal verge, and extending for 3 cm proximally. There are no palpable lymph nodes or signs of systemic disease. Biopsy demonstrates squamous cell carcinoma. Which of the following is the standard therapy for this disease?

(A) Abdominoperineal resection with permanent colostomy

(B) Abdominoperineal resection with total mesorectal excision and bilateral inguinal lymph node dissection

(C) Chemoradiation therapy with 5-fluorouracil and mitomycin C

(D) Chemotherapy with 5-fluorouracil and cisplatin

(E) Low anterior resection

QUESTION 1-85

A 59-year-old healthy female presents complaining of a palpable mass along the junction between the angle of her mandible and neck on the left side. A history and physical examination reveals no other symptoms. An ultrasound study shows a 2-cm mass in the superficial lobe of the parotid gland. A fine-needle aspiration biopsy is performed, which shows a mixture of epithelial and mesenchymal cells consistent with a diagnosis of benign pleomorphic adenoma. How should this parotid mass be managed?

(A) Close observation for change in size or development of symptoms

(B) Radiation therapy

(C) Simple enucleation of the mass

(D) Superficial parotidectomy with adjuvant radiation therapy

(E) Superficial parotidectomy with preservation of the facial nerve

QUESTION 1-86

A 76-year-old man presents with a lesion on the left forearm suspicious for melanoma. Biopsy confirms a melanoma of 0.6 mm thickness. What margin around the lesion do you need to take during excision to minimize the likelihood of recurrence?

(A) None

(B) 5 mm

(C) 1 cm

(D) 2 cm

(E) Greater than 2 cm

QUESTION 1-87

A 56-year-old man underwent a computed tomography (CT) scan of the abdomen for left lower quadrant abdominal pain. Mild diverticulitis was identified and antibiotic therapy was provided. Incidentally, a 3-cm right adrenal mass was seen on the CT scan. After recovery from diverticulitis, he is seen in the surgical clinic for evaluation of the adrenal mass. Which of the following tests should be included in the workup?

(A) Check plasma aldosterone and renin levels, plasma-free metanephrine and normetanephrine levels, and a serum vanillylmandelic acid level

(B) Perform a dexamethasone suppression test and check plasma aldosterone and renin levels, plasma-free metanephrine and normetanephrine levels, and a serum vanillylmandelic acid level

(C) Perform a dexamethasone suppression test and check plasma aldosterone and renin levels and plasma-free metanephrine and normetanephrine levels

(D) Perform a dexamethasone suppression test and check plasma aldosterone and renin levels and a serum vanillylmandelic acid level

(E) Perform a dexamethasone suppression test and check plasma-free metanephrine and normetanephrine levels and a serum vanillylmandelic acid level

۰۲۱-۶۶۱۹۸۵۱۴ www.myuptodate.com دریافت آخرین نسخه آپتودیت آفلاین

QUESTION 1-88

A 2-month-old male child is born to a mother with a Marfanoid habitus and a history of pheochromocytoma. He undergoes genetic testing and is found to have a mutation in the RET oncogene. What should be the initial goal in the management of this patient?

(A) Careful observation

(B) Computed tomography (CT) scanning to look for pheochromocytoma in retroperitoneal space

(C) Positron emission tomography (PET) scan to evaluate for other tumors

(D) Total parathyroidectomy with heterotopic autotransplantation by 5 years of age

(E) Total thyroidectomy with central lymph node dissection within the first 6 months of age

QUESTION 1-89

What is the most common etiology of common bile duct injury during laparoscopic cholecystectomy?

(A) Acute or chronic inflammation

(B) Bleeding

(C) Congenital anatomic anomalies

(D) Excess cephalad retraction of the gallbladder

(E) Obesity

QUESTION 1-90

A 57-year-old woman presents with a biopsy-proven 4.5-cm buccal mucosa squamous cell carcinoma (SCC) of her right cheek, with no lymph nodes palpable or visible on computed tomography. What is the most appropriate management?

(A) Local excision

(B) Radiation therapy

(C) Wide resection with modified radical neck dissection and postoperative radiation

(D) Wide resection with radical neck dissection

(E) Wide resection with supraomohyoid neck dissection

QUESTION 1-91

A 42-year-old diabetic woman presents to the emergency department complaining of nausea, vomiting, and abdominal pain. She had been in her usual state of health until the prior day when the symptoms began. Her temperature is 38°C and her white blood cell count is 17,000. Initial workup includes a right upper quadrant ultrasound that is negative for stones but is suggestive of air within the lumen of the gallbladder. The most appropriate initial antibiotic choice for this patient would be:

(A) Intravenous amikacin

(B) Intravenous ampicillin/sulbactam

(C) Intravenous cefazolin

(D) Intravenous clindamycin

(E) Intravenous piperacillin/tazobactam

QUESTION 1-92

During routine blood testing, a 52-year-old man is found to have a serum calcium level of 11 mg/dL (normal 8.5 to 10.5 mg/dL). His primary physician suspects hyperparathyroidism and checks a parathyroid hormone (PTH) level, which is 65 pg/mL (normal 10 to 65 pg/mL). He has no history of renal stones or bone fractures. Which of the following is an indication for this patient to undergo surgery?

(A) 24-hour urine calcium of 300 mg/dL

(B) Bone density suggestive of osteopenia (T-score –1.9)

(C) Diffuse musculoskeletal pains and irritability

(D) No surgery is indicated, since PTH is normal

(E) Serum creatinine of 1.5 mg/dL

۰۲۱-۶۶۱۹۸۵۱۴ www.myuptodate.com دریافت آخرین نسخه آپتودیت آفلاین

QUESTION 1-93

A sestamibi scan reveals a hyperfunctioning parathyroid adenoma in the superior right position in a 53-year-old woman with hypercalcemia. Preoperative parathyroid hormone (PTH) level is measured to be 200 pg/mL. After removal of the suspected parathyroid adenoma, a decrease in PTH to which of the following levels within the specified time frame would signify that the only hyperfunctioning gland had been successfully removed?

(A) 125 pg/mL in 10 minutes

(B) 132 pg/mL in 5 minutes

(C) 43 pg/mL in 30 minutes

(D) 65 pg/mL in 20 minutes

(E) 99 pg/mL in 10 minutes

QUESTION 1-94

A 76-year-old man undergoes exploratory laparotomy for a suspected bowel obstruction. During the operation, you discover a mass in the duodenum just proximal to the ligament of Treitz, with no palpable lymphadenopathy. Intraoperative pathology confirms adenocarcinoma. What is the best course of management for this patient?

(A) Gastrojejunostomy

(B) Local resection with primary repair

(C) Pancreaticoduodenectomy

(D) Surgical resection with duodenojejunostomy

(E) Surgical resection with intraoperative chemotherapy

QUESTION 1-95

A 58-year-old man presents with an asymptomatic right anterior neck mass in the thyroid region. What is the most appropriate diagnostic test for this man?

(A) Exploratory surgery

(B) Fine-needle aspiration (FNA)

(C) History and physical examination

(D) Scintigraphy

(E) Ultrasound

QUESTION 1-96

A 53-year-old man is brought into the emergency department after sustaining a gunshot wound to the left flank. You suspect a splenic injury with ongoing bleeding. The patient discloses that he is on warfarin, and his international normalized ratio (INR) is 3. What do you use to correct the coagulopathy en route to the operating room?

(A) Fresh frozen plasma (FFP) transfusion

(B) Packed red blood cell (PRBC) transfusion

(C) Protamine infusion

(D) Vitamin K intravenously

(E) Vitamin K orally

QUESTION 1-97

A 63-year-old woman undergoes fine-needle aspiration (FNA) of a 2-cm right thyroid nodule and is diagnosed with papillary thyroid cancer. On subsequent ultrasound of her neck, an enlarged right-sided lymph node is identified close to the jugular vein and is biopsied by FNA. Cytologic examination reveals metastatic papillary thyroid cancer. What is the recommended overall treatment plan for this patient?

(A) Total thyroidectomy with central and bilateral neck lymphadenectomy followed by external beam radiation

(B) Total thyroidectomy with central and bilateral neck lymphadenectomy

(C) Total thyroidectomy with central and right lateral neck lymphadenectomy followed by radioactive iodine therapy

(D) Total thyroidectomy with right lateral neck lymphadenectomy

(E) Total thyroidectomy with right lateral neck lymphadenectomy followed by external beam radiation

۰۲۱-۶۶۱۹۸۵۱۴ www.myuptodate.com دریافت آخرین نسخه آپتودیت آفلاین

QUESTION 1-98

On postoperative day 3, after undergoing an exploratory laparotomy, distal pancreatectomy, splenectomy, and fixation of a left femur fracture after a motor vehicle collision, a 46-year-old man is found to be lethargic, confused, and vomiting. His blood pressure is 90/40 mm Hg, serum glucose is 45 mg/dL, serum sodium is 121 mEq/L, serum potassium is 5.3 mEq/L, hemoglobin 11.2 mg/dL. Which of the following is the most likely cause accounting for his condition?

(A) Acute adrenal insufficiency

(B) Internal bleeding

(C) Pituitary infarction

(D) Pulmonary embolism

(E) Volume overload with lactated Ringer solution

QUESTION 1-99

Two days after undergoing an abdominoperineal resection, a 64-year-old man's colostomy stoma is dusky. On evaluation at the bedside on postoperative day 3, the dark bowel extends below the level of the abdominal wall fascia. What is the most appropriate management?

(A) Arteriography

(B) Bedside debridement

(C) Exploration and revision in the operating room

(D) Initiate wet-to-dry dressings to stoma

(E) Observation

QUESTION 1-100

A 58-year-old woman is experiencing bright red rectal bleeding after undergoing a lumbar laminectomy 3 days ago. She has been stable and was transferred out of the intensive care unit the morning following her surgery, but she continues to report a significant amount of back pain. What is the most likely etiology of her rectal bleeding?

(A) Constipation

(B) Injury to the median sacral artery during surgery

(C) Injury to the middle rectal artery during surgery

(D) Injury of the sacral plexus during surgery

(E) Rectal cancer

QUESTION 1-101

After a prolonged, open abdominal aortic aneurysm repair, requiring large volumes of fluid resuscitation, a 75-year-old man remains paralyzed and sedated, on full ventilatory support in the intensive care unit. While he is hemodynamically stable, his core body temperature is only 34°C. What would have been the most important way to maintain his core temperature intraoperatively?

(A) Keep the room temperature elevated

(B) Surround the patient with blankets

(C) Use forced-air warming devices

(D) Use of warmed intravenous fluids

(E) Warm intra-abdominal irrigation fluids

QUESTION 1-102

A 56-year-old man is admitted after recurrent episodes of confusion and loss of consciousness. His serum glucose is 45 mg/dL, raising the suspicion of insulinoma. Which of the following tests are *NOT* necessary for confirmation of the diagnosis?

(A) Pancreas protocol abdominal computed tomography (CT)

(B) Serum C peptide level

(C) Serum insulin level

(D) Serum proinsulin level

(E) Serum sulfonylurea level

QUESTION 1-103

An opera singer who recently underwent total thyroidectomy returns for her postoperative visit reporting voice fatigue and an inability to sing high notes. Her total calcium level is 9.1 mg/dL (normal 9.0 to 10.5 mg/dL). This complication could have been prevented by which of the following.

(A) It is unavoidable, symptoms are due to transient postoperative hypocalcemia and will resolve

(B) Ligation of individual branches of the superior thyroid artery at the level of the thyroid capsule

(C) Ligation of middle thyroid artery at its origin

(D) Performing a careful dissection to avoid injury to the parathyroid glands

(E) Use of an intraoperative functional nerve stimulator to localize the recurrent laryngeal nerve

۰۲۱-۶۶۱۹۸۵۱۴ www.myuptodate.com دریافت آخرین نسخه آپتودیت آفلاین

QUESTION 1-104

After undergoing resection of the right middle lobe of her lung, a 65-year-old woman complains of acute abdominal pain while eating breakfast in the morning. Her stomach is distended and tympanitic, she is bradycardic, hypotensive, tachypneic, and sweating profusely. What is the most appropriate next course of action?

(A) Emergency exploratory surgery
(B) Increase the patient's pain medication
(C) Obtain supine and erect abdominal x-rays
(D) Perform esophagogastroscopy
(E) Place a nasogastric tube

QUESTION 1-105

A 24-year-old male is brought to the emergency room after being stabbed in the right flank. Urine is grossly positive for blood, and computed tomography (CT) shows contrast extravasation from the superior pole of the right kidney. Operative exploration confirms cortical injury, but no injury is noted to the hilum or pelvis. How should this kidney be managed?

(A) Debride devitalized tissue and repair it primarily
(B) Divert the right ureter to the left ureter
(C) Perform a partial right nephrectomy
(D) Perform a right nephrectomy
(E) Washout and pack the right kidney

QUESTION 1-106

A 24-year-old HIV-positive man presents to the emergency room with acute-onset pain and redness in his scrotum, penis, and perineum. Upon examination, you feel crepitus over the erythematous area described, which emits a foul-smelling grey discharge. What is the most appropriate management for this patient's illness?

(A) Apply topical polymycin ointment
(B) Give hydrocortisone infusion
(C) Initiate highly active antiretroviral treatment (HAART)
(D) Initiate penicillin G infusion
(E) Surgical debridement of affected tissue

QUESTION 1-107

Following a motor vehicle collision, the 34-year-old male nonbelted driver complains of mild shortness of breath and has blood-tinged sputum. Admission chest radiograph appears normal except for a right fifth rib fracture and a left sixth rib fracture. Repeat chest radiograph after 4 hours reveals new onset of a patchy opacity in the middle of the lung fields bilaterally. Oxygen saturation is maintained at 94% on 2-L nasal cannula supplementation. Appropriate treatment includes which of the following?

(A) Immediate intubation and full ventilatory support
(B) Initiation of broad-spectrum antibiotics
(C) Placement of bilateral chest tubes
(D) Termination of intravenous fluid resuscitation and administration of diuretics
(E) Use of incentive spirometry

QUESTION 1-108

A 38-year-old woman undergoes left thyroid lobectomy for a palpable nodule with indeterminate pathology on preoperative fine-needle aspiration. The specimen is sent to pathology for examination. Which of the following factors paired with the appropriate diagnosis is associated with the poorest prognosis for this patient?

(A) 1.7-cm solitary nodule with medullary carcinoma
(B) Encapsulated, noncystic follicles with follicular carcinoma
(C) MEN 2B with medullary carcinoma
(D) Presence of lymph node disease with papillary carcinoma
(E) Psammoma bodies with anaplastic carcinoma

۰۲۱-۶۶۱۹۸۵۱۴ www.myuptodate.com دریافت آخرین نسخه آپتودیت آفلاین

QUESTION 1-109

A 48-year-old alcoholic man with painless jaundice appears to have intrahepatic biliary ductal dilation on computed tomography (CT) scan. The bilirubin is 12.6 with other liver function tests normal. On review of the CT scan, you can detect no obstructing mass. Magnetic resonance cholangiopancreatography (MRCP) demonstrates no stones in his biliary tree with dilation extending to the pancreas. The most likely cause of his ductal dilation is:

(A) Benign common bile duct stricture

(B) Gallbladder carcinoma

(C) Klatskin tumor

(D) Pancreatic cancer

(E) Pancreatic pseudocyst

QUESTION 1-110

A 24-year-old African American woman presents to your clinic for excision of a suspicious skin lesion on her chest. She reports a history of keloid formation, as evidenced by a hypertrophic midline incision for a cesarean section 6 months ago. Which of the following techniques has the most favorable results for inhibiting keloid formation?

(A) Intralesional steroid injection following keloid excision

(B) Radiotherapy following keloid excision

(C) Tissue necrosis factor-alpha (TNF-α) injection following keloid excision

(D) Tocopherol (Vitamin E) topical application following keloid excision

(E) Tretinoin ointment application following keloid excision

QUESTION 1-111

A 35-year-old former intravenous drug user with a history of Hepatitis C infection has developed cirrhosis and has recently been placed on the liver transplant waiting list. He would like to know how "sick" he must be, as assessed the model for end-staged liver disease score (MELD), before the benefits of liver transplantation outweigh the risks. What do you tell him his MELD score has to be greater than?

(A) 10

(B) 15

(C) 20

(D) 30

(E) 40

QUESTION 1-112

A 78-year-old female with a history of transient ischemic attacks and coronary disease presents to the emergency department complaining of pain in her distal right lower extremity. She describes the pain as a dull, aching sensation in her toes that is worse at night when she lies flat in bed, and therefore she often sleeps in a chair. A careful inspection of the extremity does not reveal any signs of necrosis or gangrene. The forefoot is purple-red when the foot is down while seated and very white when the foot is elevated. To assess the severity of this patient's disease, an ankle–brachial index (ABI) is performed at the bedside. What is the most likely ABI value range to be found in this patient?

(A) Between 0.1 and 0.2

(B) Between 0.3 and 0.4

(C) Between 0.5 and 0.6

(D) Between 0.6 and 0.7

(E) Between 0.7 and 0.9

۰۲۱-۶۶۱۹۸۵۱۴ www.myuptodate.com دریافت آخرین نسخه آپتودیت آفلاین

QUESTION 1-113

A 62-year-old woman with a serum calcium level of 11.4 mg/dL, elevated intact parathyroid hormone level (iPTH), and a recent history of kidney stones underwent a bilateral neck exploration. Two normal parathyroid glands were identified on the right side, and one normal superior parathyroid gland was identified posterior to the superior pole of the left thyroid lobe. The thymus and the side of the neck with the missing gland were thoroughly explored but no abnormal masses were found. What should the surgeon do next?

(A) Biopsy each of the glands since visual inspection is a poor indicator of abnormal pathology

(B) End the operation and perform noninvasive imaging to localize the abnormal parathyroid tissue

(C) Perform a left thyroid lobectomy

(D) Remove the identified parathyroid glands one at a time, until the iPTH level drops to half the baseline level.

(E) Remove the three identified glands, and autotransplant one of them into the nondominant forearm

QUESTION 1-114

You perform an uncomplicated laparoscopic cholecystectomy on a 50-year-old woman for symptomatic cholelithiasis. One week later, the surgical pathologist calls you to say that the specimen contains adenocarcinoma of the gallbladder wall. The cancer is limited to the muscular layer of the gallbladder and the cystic duct margin is negative. In your subsequent discussion with the patient, what should you recommend as the treatment plan?

(A) Extended right hepatectomy, portal lymphadenectomy and resection/reconstruction of the extrahepatic biliary tree

(B) No further treatment is needed

(C) Radiation and chemotherapy with 5-fluorouracil and mitomycin C

(D) Resection of the gallbladder fossa and portal lymphadenectomy

(E) Resection of the laparoscopic trocar sites and chemotherapy with 5-fluorouracil and mitomycin C

QUESTION 1-115

A 23-year-old male pedestrian is brought to the emergency department after he was pinned between a truck and a telephone pole. He complains of infraumbilical, pelvic, and hip pain. Pelvic plain radiographs reveal an open-book fracture with bilateral sacroiliac dislocation. Which of the following is the most appropriate initial management of this patient?

(A) External fixation of the pelvis when he becomes hemodynamically unstable

(B) Immediate open reduction and internal fixation while he is hemodynamically stable

(C) Immediate placement of two 16-gauge peripheral IVs

(D) Nonoperative management of the pelvic fracture, with extended bed rest while he is hemodynamically stable

(E) Placement of a pneumatic antishock garment when he becomes hemodynamically unstable

QUESTION 1-116

A 67-year-old man with a medical history of hypertension and insulin-dependent diabetes mellitus presents for preoperative counseling before an open abdominal aortic aneurysm repair scheduled 3 weeks from now. He has never had a cerebrovascular accident (CVA) or a myocardial infarction and denies symptoms of angina or heart failure. His preoperative laboratory values are unremarkable except for a creatinine of 2.2 mg/dL. The patient also reports that he is unable to walk up two flights of stairs before tiring. An electrocardiogram reveals normal sinus rhythm. Which of the following measures is appropriate given his current level of cardiac risk?

(A) He should have a coronary angiogram and be considered for coronary revascularization before surgery

(B) He should receive perioperative beta blockade, but noninvasive stress testing is not mandated

(C) He should undergo coronary revascularization before repair of his abdominal aortic aneurysm

(D) He should undergo noninvasive stress testing (i.e., exercise stress testing, dipyridamole thallium imaging) and if negative for high-risk features should receive perioperative beta blockade

(E) There is no indication for noninvasive stress testing or perioperative beta blockade

۰۲۱-۶۶۱۹۸۵۱۴ www.myuptodate.com دریافت آخرین نسخه آپتودیت آفلاین

QUESTION 1-117

A 45-year-old man is admitted to the intensive care unit with presumed sepsis. After the patient is stabilized, the decision is made to place a central venous catheter. The patient's platelets, INR, and PTT ratio are within normal limits. He is breathing at a rate of 20 on room air with an oxygen saturation of 99%. He has no other significant past medical history. The preferred location for central venous access is:

(A) Left femoral vein

(B) Left internal jugular vein

(C) Left subclavian vein

(D) Right femoral vein

(E) Right internal jugular vein

QUESTION 1-118

A 45-year-old man undergoes endoscopic ultrasonography to further localize a 3-cm insulinoma in the head of the pancreas. This solitary insulinoma is determined to be adjacent to the pancreatic duct. Which of the following procedures should be used to remove the tumor?

(A) Catheter-directed chemoembolization

(B) Laparoscopic total pancreatectomy

(C) Laparotomy with cryoablation

(D) Laparotomy with enucleation

(E) Laparotomy with pancreaticoduodenectomy

QUESTION 1-119

You are called to the emergency department to see a 68-year-old woman who has undergone a barium enema for ileocolic intussusception. The films show that the intussusception has been only partly reduced. What is your next step?

(A) Colonoscopic reduction

(B) Laparotomy for manual reduction

(C) Observation

(D) Pneumatic reduction

(E) Repeat barium enema

QUESTION 1-120

Current guidelines for prophylaxis against venous thromboembolism call for risk stratification before determining a prophylaxis strategy for a particular patient. The group of patients with the highest risk for venous thromboembolism includes those undergoing hip arthroplasty, major trauma, spinal cord injury, and those with a history of prior venous thromboembolism. What is the approximate incidence of deep venous thrombosis (DVT) in this group of patients?

(A) 1% to 10%

(B) 10% to 20%

(C) 40% to 50%

(D) 50% to 60%

(E) 70% to 80%

QUESTION 1-121

A 50-year-old man is in the intensive care unit with necrotizing pancreatitis. He is struggling to wean from the ventilator. As he has been maintained on total parenteral nutrition (TPN), you are suspicious of an overfeeding syndrome and elect to perform indirect calorimetry. Which of the following values for the respiratory quotient (RQ) would be consistent with an overfeeding syndrome?

(A) 0.65

(B) 0.7

(C) 0.8

(D) 1

(E) 1.3

QUESTION 1-122

A 19-year-old male is brought to a rural emergency department after experiencing penetrating trauma to the left chest by farm equipment. His initial set of vital signs after 2 L of fluid are heart rate 107 beats per minute and blood pressure 80/50 mm Hg. He is able to tell you what happened, but you are not able to hear heart sounds and breath sounds are distant on the left. What should be your next step?

(A) Chest x-ray while preparing a thoracostomy set

(B) Emergency thoracotomy in the operating room

(C) Emergent pericardiocentesis

(D) Intubation

(E) Large volume resuscitation

۰۲۱-۶۶۱۹۸۵۱۴ www.myuptodate.com دریافت آخرین نسخه آپتودیت آفلاین

QUESTION 1-123

A 62-year-old woman undergoes laparoscopic splenectomy for idiopathic thrombocytopenic purpura (ITP). After recovery from the operation she continues to have a platelet count of 20,000. What is the next step in her management?

(A) Administration of intravenous immunoglobulin (IVIG)

(B) Begin a 4-month course of danazol

(C) Bone marrow transplantation

(D) Do nothing

(E) Reoperate for missed accessory spleen

QUESTION 1-124

A 56-year-old woman is seen in clinic 6 months after undergoing a laparoscopic Nissen fundoplication for esophageal reflux disease and treatment of a type IV paraesophageal hernia. She complains of symptoms of persistent dysphagia. Which of the following is the cause of these complaints?

(A) The hiatal hernia has recurred

(B) The patient has gas bloat syndrome

(C) The patient has gastric stasis

(D) The stomach has become denervated

(E) The wrap has come undone

QUESTION 1-125

A 74-year-old former gardener presents with a suspicious, irregular mole on his left upper arm. Of note, there is no evidence of ulceration. Which of the following scenarios would warrant a sentinel lymph node biopsy?

(A) 0.5-mm thick melanoma of the arm with no clinical nodal metastases

(B) 0.8-mm thick melanoma of the arm with ulceration with no clinical nodal metastases

(C) 2-mm thick melanoma of the arm with axillary lymphadenopathy

(D) 3-mm thick melanoma of the arm with pulmonary metastases

(E) 4.5-mm thick melanoma of the arm with known metastasis to the brain

QUESTION 1-126

Three men are admitted to the emergency department after developing severe hypothermia and dehydration while ice fishing. You decide to rewarm and resuscitate them with warmed intravenous fluids. The nurse asks how warm you would like the fluids. You explain that the highest temperature that is safe to administer to the patients is:

(A) 45°C

(B) 55°C

(C) 65°C

(D) 75°C

(E) Rewarming with IV fluids above normal body temperatures is not recommended

QUESTION 1-127

A 23-year-old man presents to the emergency department with a single gunshot wound to the left chest. The patient is able to phonate but has severely decreased breath sounds on the left side, and therefore a 36-French thoracostomy tube is placed. Which of the following is an indication for operative management?

(A) 1,000 mL of sanguineous chest tube output upon insertion

(B) 300 mL of sanguineous chest tube output over the next 3 hours

(C) A small air leak in the chest tube that remains for 24 hours

(D) Hemodynamic instability on presentation to the emergency department

(E) The presence of gastric contents in the chest tube effluent

۰۲۱-۶۶۱۹۸۵۱۴ www.myuptodate.com دریافت آخرین نسخه آپتودیت آفلاین

QUESTION 1-128

A 52-year-old woman with multifocal tumor in her left breast with palpable lymphadenopathy was advised to have a simple mastectomy with axillary lymph node dissection, followed by a postoperative course of chemotherapy and radiation. She has a history of hypertension and quit smoking 15 years ago. Her surgical history includes a tonsillectomy and a laparoscopic cholecystectomy. Which statement is most appropriate regarding the patient's inquiry about transverse rectus abdominus myocutaneous (TRAM) flap reconstruction?

(A) A TRAM flap should yield a more natural cosmetic result compared to breast implantation, but is best performed months after radiotherapy

(B) A TRAM flap should yield a more natural cosmetic result compared to breast implantation, and is best performed immediately following the mastectomy

(C) Breast implantation is preferable to TRAM flap reconstruction due to patient's history of hypertension and smoking

(D) Breast implantation is preferable to TRAM flap reconstruction due to the patient's history of laparoscopic surgery

(E) Breast reconstruction should not be pursued following postmastectomy radiotherapy

QUESTION 1-129

Six weeks after undergoing a vagotomy and antrectomy with Billroth II reconstruction for peptic ulcer disease, a 76-year-old man presents with nausea, abdominal pain, and low-grade fever. Given his recent surgical history, your differential diagnosis includes afferent limb obstruction. Which one test will best confirm this diagnosis?

(A) Computed tomography (CT) scan with oral contrast

(B) Esophagogastroduodenoscopy (EGD)

(C) Hepatobiliary iminodiacetic acid (HIDA) scan

(D) Supine and erect abdominal x-ray

(E) Upper gastrointestinal (GI) series

QUESTION 1-130

A 58-year-old woman is rushed to the emergency department following an explosion in her basement that resulted in a shower of metallic shrapnel and multiple penetrating injuries. Her Glasgow Coma Scale (GCS) on arrival is 8. Noncontrast computed tomography (CT) of the head reveals one of the metallic fragments to have penetrated the inner table of the skull. Which of the following characteristics of this scenario portends the poorest prognosis given her preresuscitation GCS score?

(A) Age >55

(B) Blast injury

(C) Female gender

(D) Penetrating mechanism of injury

(E) Time of transportation

QUESTION 1-131

A 30-year-old man underwent pelvic fixation after a motorcycle accident 2 days ago. He has been vomiting episodically for the past 24 hours, has had a high nasogastric tube output, and his respiratory rate is 8. To correct his acid–base status electrolytes, you should:

(A) Administer acetazolamide

(B) Give 2.2-mEq/L ammonium chloride

(C) Infuse 1-L lactated Ringer solution

(D) Infuse 1-L normal saline with 20-mEq KCl/L

(E) Perform emergency dialysis

QUESTION 1-132

A 65-year-old man with a history of severe atherosclerosis, hypertension, and bicuspid aortic valve presents to the emergency department in acute distress complaining of sudden onset of tearing chest pain directly below his sternum. The patient is hypertensive (196/110 mm Hg) and appears very anxious with an overwhelming sense of doom. Which of the following tests or interventions is *contraindicated* in this patient?

(A) Administration of antihypertensive medications

(B) Computed tomography (CT) scan of the chest with contrast injection

(C) Echocardiogram

(D) Electrocardiogram

(E) Thrombolytic treatment of a myocardial infarction

۰۲۱-۶۶۱۹۸۵۱۴ www.myuptodate.com دریافت آخرین نسخه آپتودیت آفلاین

QUESTION 1-133

A 51-year-old man with diabetes and a 5.8-cm abdominal aortic aneurysm undergoes a preoperative evaluation. He has the following laboratory results: Sodium 144 mEq/L, potassium 5.7 mEq/L, chloride 117 mEq/L, bicarbonate 18 mEq/L, and creatinine 1.6 mg/dL. The plasma renin activity is 1.3 ng/mL/hr (normal 1.9 to 3.7 ng/mL/hr) and the urine pH is 5. These laboratory tests are consistent with:

(A) Conn syndrome

(B) Inappropriate antidiuretic hormone secretion

(C) Type 1 renal tubular acidosis

(D) Type 2 renal tubular acidosis

(E) Type 4 renal tubular acidosis

QUESTION 1-134

A 68-year-old woman presents with a history of weight loss and nausea, but denies vomiting or early satiety. Workup ultimately leads to biopsy-proven B-cell mucosa-associated lymphoid tissue (MALT) lymphoma confined to the stomach. What is the most appropriate treatment?

(A) Antibiotic therapy

(B) Chemotherapy and radiation therapy

(C) Proton pump inhibitor, clarithromycin, and amoxicillin for 10 to 14 days

(D) Radiation therapy

(E) Subtotal gastrectomy followed by radiation therapy

QUESTION 1-135

Which of the following statements is correct regarding the anatomy of the renal vasculature?

(A) The left renal artery is longer than the right renal artery

(B) The left renal artery is superior to the left renal vein

(C) The left renal vein lies posterior to the aorta

(D) The right renal artery lies posterior to the inferior vena cava (IVC)

(E) The right renal vein is anterior to the aorta

QUESTION 1-136

A 27-year-old man is shot in the leg and arm and arrives in the emergency department in hypovolemic shock from massive hemorrhage. After prolonged surgery to reconstruct his femoral and brachial arteries he is hemodynamically stable. On arrival to the intensive care unit, his arterial blood gas values are as follows: pH 7.50, pO_2 140 mm Hg, pCO_2 50 mm Hg, HCO_3^- 28 mEq/L. What is the likely etiology of his acid–base disturbance?

(A) Contraction alkalosis

(B) Dilutional acidosis

(C) Hyperventilation

(D) Ingestion of an excessive amount of antacid prior to the injury

(E) Lactic acidosis

QUESTION 1-137

A 54-year-old man presents to his gastroenterologist complaining of 3 weeks of right upper quadrant pain, jaundice, and intermittent hemobilia. An ultrasound and duplex scan are performed, showing a 2.5-cm intrahepatic artery aneurysm in the left lobe of the liver. The best option for treatment is:

(A) Coil embolization of the aneurysm with radiologic guidance

(B) Left hepatectomy

(C) Open surgical ligation

(D) Resection of the aneurysm and reconstruction of the hepatic arterial tree

(E) Serial radiologic studies to evaluate for expansion over time

۰۲۱-۶۶۱۹۸۵۱۴ www.myuptodate.com دریافت آخرین نسخه آپتودیت آفلاین

QUESTION 1-138

After radiographic localization of a solitary 3-cm insulinoma in the tail of the pancreas of a 56-year-old woman, you perform a distal pancreatectomy and splenectomy. Which of the following statements regarding the distribution of insulinomas is true?

(A) Fifteen percent of insulinomas are found in the tail of the pancreas

(B) Insulinomas are evenly distributed throughout the pancreas

(C) Malignant insulinomas are more frequently found in the head and uncinate process of the pancreas

(D) Most insulinomas are found in the tail of the pancreas

(E) Ninety percent of insulinomas are found in the head, uncinate process or body of the pancreas

QUESTION 1-139

Your sister states that she has been diagnosed with focal nodular hyperplasia (FNH) of her liver. How should you advise her to proceed with treatment?

(A) She may be observed with this condition

(B) She should visit a medical oncologist for an oral TNF-α inhibitor

(C) She should visit a medical oncologist for chemotherapy

(D) She should visit a radiation oncologist for radiation therapy

(E) She will likely require surgery for this condition

QUESTION 1-140

A negative side effect of delayed primary wound closure compared with healing by secondary intention includes which of the following?

(A) Increased width of scar

(B) Longer time to epithelialization

(C) Painful dressing changes

(D) Prolonged dressing changes

(E) Risk of delayed abscess/wound infection

QUESTION 1-141

A 40-year-old unrestrained male driver is involved in a high-speed motor vehicle crash with a 5-minute extrication time. First responders find him breathing shallowly, with a pulse rate of 113 and blood pressure of 110/70 mm Hg. He has a scalp laceration but no obvious extremity fractures. He is given a large volume of intravenous fluids en route to the hospital. Upon arrival, his Glasgow Coma Scale score is 8 and he is intubated and placed on a ventilator. Shortly thereafter, the patient becomes markedly hypotensive and is found to be in pulseless electrical activity. Cardiopulmonary resuscitation is initiated. What is the next best step in management of this patient?

(A) Bilateral-needle decompression

(B) Chest x-ray

(C) Close scalp laceration

(D) Emergent thoracotomy

(E) Transfusion of blood products

QUESTION 1-142

Which of the following is a characteristic of splenic artery aneurysms?

(A) Calcification of the aneurysm is thought to be associated with a decreased risk of rupture

(B) Elective surgery is indicated for aneurysms >1.5 cm in diameter

(C) Incidence is increased in female patients, multiparity, and portal hypertension

(D) Male to female ratio of 4:1

(E) Most patients present with symptoms consistent with splenic artery aneurysm rupture

۰۲۱-۶۶۱۹۸۵۱۴ www.myuptodate.com دریافت آخرین نسخه آپتودیت آفلاین

QUESTION 1-143

The following patients have all undergone splenectomy, and none have received vaccinations for *Streptococcus pneumoniae, Haemophilus influenzae,* or *Neisseria meningitidis.* Who is at greatest risk of postsplenectomy sepsis?

(A) A 14-year-old girl who underwent splenectomy for trauma 2 years ago

(B) A 20-year-old man with HIV who underwent splenectomy for trauma

(C) A 3-year-old boy who underwent splenectomy for thalassemia major

(D) A 45-year-old man who underwent splenectomy for Hodgkin disease

(E) A 73-year-old woman who underwent splenectomy for ITP

QUESTION 1-144

You see a 60-year-old woman in clinic complaining of progressive dysphagia. She denies pain while swallowing, but says she feels that some foods become stuck on a "lump in my throat." She has not lost any weight from these symptoms, has no smoking history, and does not use alcohol. You suspect a benign process. Which of the following studies and associated findings confirms your suspicion of an esophageal leiomyoma?

(A) Barium swallow study showing a bird-beak pattern in the distal third of the esophagus

(B) Computed tomography (CT) scan showing a circumferential narrowing along the distal third of the esophagus

(C) Esophagoscopy showing a submucosal lesion in the distal third of the esophagus

(D) Magnetic Resonance Imaging (MRI) demonstrating compression of the cervical esophagus by ankylosing spondylitis

(E) Plain films of the lateral neck demonstrating a pedunculated lesion arising from the posterior wall of the esophagus

QUESTION 1-145

A 35-year-old man is admitted with thermal burns resulting from the explosion of a gas cylinder at his factory. The man suffered 75% total body surface area burns, including his face, neck, chest, abdomen, back, arms, hands, and legs. More than 50% of his burn area was deep dermal in nature. Resuscitation was initiated with crystalloids and dry sterile dressings were placed over his wounds. Within 12 hours of admission, he developed respiratory distress, a high-grade temperature, and hypotension. Subsequent management should include which of the following?

(A) Allow burn wounds to demarcate

(B) Initiate antibiotics based upon the white blood count and fever

(C) Initiate total parenteral nutrition (TPN)

(D) Obtain a quantified wound biopsy

(E) Stop all enteral feeds

QUESTION 1-146

A 33-year-old adult male was extricated from a house fire and at the scene was found to have second-degree burns to his trunk and extremities totaling 35% of total body surface area. Primary survey showed singed nasal vibrissae and soot in the oropharynx, but unlabored breathing. He did not have rales, rhonchi, or wheezing and his O_2 saturation was 94% on room air. In this patient, development of hypoxia on hospital day 1 is most likely due to:

(A) Acute respiratory distress syndrome (ARDS)

(B) Bronchospasm

(C) Carbon monoxide poisoning

(D) Pulmonary edema

(E) Upper airway obstruction and asphyxia

۰۲۱-۶۶۱۹۸۵۱۴ www.myuptodate.com دریافت آخرین نسخه آپتودیت آفلاین

QUESTION 1-147

A 54-year-old man with atrial fibrillation refractory to multiple cardioversions and antiarrhythmic agents underwent attempted endocardial catheter ablation by a cardiac electrophysiologist. After unsuccessful catheter ablation, he is referred to a cardiac surgeon for evaluation. Which of the following is true regarding the modified Maze procedure?

(A) It is possible to perform the modified Maze procedure off cardiopulmonary bypass

(B) Sinus rhythm at 5 years is sustained in 80% to 90% of patients undergoing the modified Maze procedure

(C) Success in restoring sinus rhythm ranges from 40% to 50% with the modified Maze procedure

(D) The modified Maze procedure is not indicated in patients at risk for stroke

(E) The myocardium around the tricuspid valve is cut then sewn back together to interrupt aberrant circuits in the modified Maze procedure

QUESTION 1-148

A 52-year-old man with no prior medical problems reports intermittent episodes of tachycardia, nausea, and diaphoresis that improve with snacks. He has gained 4.54 kg (10 lb) in the past 3 months, and has become increasingly irritable. The patient's internist orders a monitored fast and makes the diagnosis of an insulinoma. A computed tomography (CT) scan with IV contrast fails to localize the tumor. The next step in the patient's management is to:

(A) Perform endoscopic ultrasonography

(B) Perform exploratory laparotomy and employ intraoperative ultrasound

(C) Perform selective arterial calcium stimulation with hepatic venous insulin sampling

(D) Perform somatostatin receptor scintigraphy

(E) Recommend judicious carbohydrate intake and a trial of octreotide

QUESTION 1-149

A 52-year-old man undergoes truncal vagotomy and antrectomy for peptic ulcer disease. Postoperatively, he complains of diarrhea. Which of the following physiologic alterations is due to the truncal vagotomy alone?

(A) Accelerated emptying of solids

(B) Decrease in gastrin production

(C) Decreased gallbladder distention

(D) Increase in gastric acid secretion

(E) Increased intragastric pressure

QUESTION 1-150

A 63-year-old woman is referred to your clinic for management of a biopsy-proven 1.7-mm thick nonulcerative melanoma on the center of her back. Lymph nodes are normal to palpation. What is an appropriate surgical margin to take during excision to minimize local recurrence?

(A) 5 mm

(B) 1 cm

(C) 2 cm

(D) >2 cm

(E) None

QUESTION 1-151

On routine annual examination a 78-year-old man has a 2-cm circular peripheral density in his right upper lung field on chest radiograph. To help establish a diagnosis, what is the next most appropriate step in the workup of this finding?

(A) Brain Magnetic Resonance Imaging (MRI)

(B) Chest Computed Tomography (CT) through the adrenal glands

(C) Fiberoptic bronchoscopy

(D) Integrated Positron Emission Tomography and Computed Tomography (PET–CT)

(E) Lactate dehydrogenase (LDH) level

۰۲۱-۶۶۱۹۸۵۱۴ www.myuptodate.com دریافت آخرین نسخه آپتودیت آفلاین

QUESTION 1-152

Which of the following statements regarding the scalenus muscle is true?

(A) The anterior body inserts into the first rib posterior to the subclavian vein

(B) The middle body inserts into the first rib anterior to the brachial plexus

(C) The muscle originates from the transverse processes of C1 through C6

(D) The phrenic nerve crosses the anterior body medial to lateral

(E) The phrenic nerve crosses the medial body medial to lateral

QUESTION 1-153

Which of the following is a characteristic of T3 colon cancer?

(A) Lesion invading through the muscularis propria into the serosa

(B) Lesion invading through the serosa into adjacent organs

(C) Lesion invading through the serosa, into the free peritoneal cavity

(D) Lesion invading through the submucosa into the muscularis propria

(E) Lesion not penetrating the submucosa

QUESTION 1-154

A 23-year-old man is referred to the surgery clinic after an endoscopic retrograde cholangiopancreatography shows a Type I choledochal cyst. What is the preferred method of surgical management?

(A) Cholecystectomy

(B) Complete excision with Roux-en-Y hepaticojejunostomy

(C) Complete excision, partial hepatectomy, and Roux-en-Y hepaticojejunostomy

(D) Cyst gastrostomy

(E) Cyst jejunostomy

QUESTION 1-155

A 54-year-old female with a low rectal cancer undergoes an abdominoperineal resection in what proves to be a challenging case that lasts 9 hours. Which of the following would be the earliest indicator of compartment syndrome in the lower extremities?

(A) Pain

(B) Pallor

(C) Paralysis

(D) Paresis

(E) Pulselessness

QUESTION 1-156

In clinic, a 40-year-old male states that for the past 2 days he has had air passing through his urethra, cramping abdominal pain, distension, and loose bowel movements. Physical examination is notable for oral temperature of 38.9°C, heart rate 120 beats per minute, and blood pressure 100/86 mm Hg. The patient has leukocyte count of 19,000/mm^3, serum Na^+ of 128 mEq/dL, K^+ of 3.0 mEq/dL, and computed tomography scan shows fistulous communication with the right ureter and a pericolic abscess. He is administered a dose of levofloxacin intravenously, upon which the patient goes into cardiopulmonary arrest. The fatal arrhythmia is caused by:

(A) Accessory conduction pathway

(B) After-depolarization

(C) Enhanced automaticity

(D) Premature repolarization

(E) Re-entrant rhythm

۰۲۱-۶۶۱۹۸۵۱۴ www.myuptodate.com دریافت آخرین نسخه آپتودیت آفلاین

QUESTION 1-157

A 65-year-old man is in the surgical intensive care unit 24 hours after an emergent exploration and Hartmann procedure for perforated diverticulitis. He has remained hemodynamically labile and oliguric despite 14 L of volume resuscitation. The EKG is unremarkable except for sinus tachycardia. The patient has a known history of moderate tricuspid regurgitation. The patient is intubated and sedated and has the following hemodynamic and laboratory values: Temperature 37.9°C, pulse 104 beats per minute, blood pressure 90/45 mm Hg, SaO_2 100% on 50% FiO_2, MvO_2 58%, CVP 10 mm Hg, BSA 2 m^2, Hbg 10 g/dL. Based on this information, calculate the cardiac output (CO) and systemic vascular resistance (SVR).

(A) CO 2.5 L/min, SVR 1,600 $dyn \cdot s \cdot cm^{-5}$

(B) CO 5 L/min, SVR 800 $dyn \cdot s \cdot cm^{-5}$

(C) CO 7.5 L/min, SVR 200 $dyn \cdot s \cdot cm^{-5}$

(D) CO 10 L/min, SVR 400 $dyn \cdot s \cdot cm^{-5}$

(E) CO 10 L/min, SVR 800 $dyn \cdot s \cdot cm^{-5}$

QUESTION 1-158

Among the examples given, which patient with pancreatic cancer would most likely be deemed unresectable based upon their abdominal computed tomography scan and laboratory findings? (CA 19-9 refers to Cancer Antigen 19-9.)

(A) 43-year-old male with a central pancreatic mass, CA 19-9 of 150 and tumor abutting the splenic vein

(B) 54-year-old female with a 3-cm mass in the head of the pancreas, CA 19-9 of 150 and encasement of the superior mesenteric vein

(C) 58-year-old female with a central pancreatic mass, CA 19-9 of 200 and adhesion to the ventral surface of the inferior vena cava (IVC)

(D) 67-year-old male with a 5-cm mass in the head of the pancreas, CA 19-9 of 50 and encasement of the superior mesenteric artery

(E) 75-year-old male with a 5-cm mass in the tail of the pancreas, CA 19-9 of 200 and no vessel invasion

QUESTION 1-159

A 75-year-old female falls while getting up from an unlocked wheelchair and subsequently complains of numbness in her index finger and thumb as well as difficulty in moving her thumb. Further questioning reveals a history of rheumatoid arthritis. She has tenderness on the dorsal aspect of her wrist, and at the base of her thumb. She also has a noticeable "dinner fork" deformity. Her findings are suggestive of which of the following diagnosis?

(A) Bennett fracture

(B) Colles fracture

(C) Lunate dislocation

(D) Scaphoid fracture

(E) Smith fracture

QUESTION 1-160

While performing a hepatic resection, you note that the left hepatic artery does not originate from the proper hepatic artery. Anatomically, what is the most likely origin of this anomalous takeoff of the left hepatic artery?

(A) Common hepatic artery

(B) Gastroduodenal artery

(C) Left gastric artery

(D) Right hepatic artery

(E) Superior mesenteric artery

QUESTION 1-161

A 67-year-old, otherwise healthy woman referred to you after arteriographic workup for multiple left hemispheric ischemic attacks reveals a "string of beads" appearance in the distal left internal carotid artery, proximal to the carotid canal at the base of the skull. There is no further evidence of narrowing at the bifurcation on the left side, or of any disease of the right internal carotid artery. What is the most appropriate management of this patient?

(A) Carotid artery interposition graft

(B) Chronic anticoagulation with regular observation

(C) High, internal carotid endarterectomy

(D) Open transluminal balloon dilation with stent placement

(E) Percutaneous transluminal balloon angioplasty

۰۲۱-۶۶۱۹۸۵۱۴ www.myuptodate.com دریافت آخرین نسخه آپتودیت آفلاین

QUESTION 1-162

A 60-year-old otherwise healthy male presents with symptoms of reflux disease and undergoes an endoscopic evaluation. The biopsies in the distal esophagus are consistent with high-grade dysplasia associated with Barrett esophagus. What is the appropriate treatment for this patient?

(A) Antireflux surgery

(B) Esophagectomy

(C) *Helicobacter pylori* antimicrobial therapy

(D) Observation with annual endoscopic gastroduodenoscopy

(E) Proton pump inhibitor therapy

QUESTION 1-163

You are caring for a 27-year-old man in the intensive care unit who sustained multiple abdominal gunshot wounds and is postoperative day 3 from extensive bowel resections, and has an open abdomen following the heavily contaminated procedure. He has a pulmonary artery catheter and has developed a depressed systemic blood pressure despite resuscitation to 10 kg above his baseline weight. Which pulmonary artery findings would support your suspicion of hyperdynamic septic shock?

Key:

CVP = central venous pressure

PCWP = pulmonary capillary wedge pressure

CO = cardiac output

SVR = systemic vascular resistance

SvO_2 = mixed venous oxygen saturation

(A) ⇓ CVP/PCWP, ⇓ CO, ⇑ SVR, ⇓ SvO_2

(B) ⇑ CVP/PCWP, ⇓ CO, ⇑ SVR, ⇓ SvO_2

(C) ⇓ CVP/PCWP, ⇓ CO, ⇓ SVR, ⇓ SvO_2

(D) ⇑ or ⇓ CVP/PCWP, ⇓ CO, ⇑ SVR, ⇑ or ⇓ SvO_2

(E) ⇑ or ⇓ CVP/PCWP, ⇑ CO, ⇓ SVR, ⇑ SvO_2

QUESTION 1-164

Which of the following is the most common site of lung abscesses?

(A) Left lower lobe, posterior basal segment

(B) Lingula

(C) Right lower lobe, anterior basal segment

(D) Right middle lobe, lateral segment

(E) Right upper lobe, posterior segment

QUESTION 1-165

A 58-year-old female presents with severe refractory peptic ulcer disease that has failed conventional treatment. Her workup includes an endoscopic ultrasound and octreotide scan that localize a 1.8-cm duodenal mass. There are no liver metastases. Laboratory evaluation reveals an elevated serum gastrin level. What is the appropriate surgical management?

(A) Duodenotomy and resection of the mass

(B) Endoscopic mucosal resection

(C) Pancreaticoduodenectomy

(D) Subtotal gastrectomy with truncal vagotomy

(E) Total gastrectomy

QUESTION 1-166

One night after undergoing an open gastric bypass procedure, a 45-year-old, 158.75-kg (350-lb) man had an isolated temperature spike to 38°C. Over the following 3 days, he was afebrile. This morning, on postoperative day 4, his pulse rate is 100 and blood pressure is 95/60 mm Hg, which is lower than his normal 120/70. His wound appears slightly erythematous and is more tender to palpation than yesterday. He admits to feeling slightly unwell. How might this complication have been avoided?

(A) Continue prophylactic antibiotics for 48 hours postoperatively

(B) Maintain tight glucose control following surgery

(C) Remove his Foley catheter on postoperative day 1

(D) Shave his abdomen prior to surgery

(E) Wash the abdominal cavity with antibiotic solution prior to closure during surgery

۰۲۱-۶۶۱۹۸۵۱۴ www.myuptodate.com دریافت آخرین نسخه آپتودیت آفلاین

QUESTION 1-167

A 72-year-old man with a history of hypertension, hyperlipidemia, diabetes mellitus, and an irregular heart rhythm presents in the emergency department with acute onset of unremitting right leg pain below the knee. He denies trauma and states that he regularly walks a block to the grocery store without difficulty. On physical examination, the leg appears white and cool to touch and is noticeably painful to palpation. In addition, no dorsalis pedis or posterior tibial pulse can be palpated nor can a signal be identified with use of the Doppler probe. The most likely etiology for this patient's peripheral ischemia is:

(A) Acute thrombosis

(B) Chronic atherosclerotic disease

(C) Drug-induced ischemia

(D) Embolic disease

(E) Vasculitis

QUESTION 1-168

A 35-year-old woman who has been on oral contraceptives for 10 years presents with a 6-month history of right upper quadrant discomfort. After a negative workup for cholelithiasis, computed tomography reveals a 6.5-cm tumor of hepatic segment IV. Complications of this tumor include:

(A) 30% risk of spontaneous thrombosis

(B) 50% to 65% risk of spontaneous rupture and intraperitoneal hemorrhage

(C) 90% risk of malignant transformation

(D) Compression of the common hepatic duct, leading to obstructive jaundice

(E) Compression of the portal vein, leading to portal hypertension

QUESTION 1-169

The chest x-ray of a 68-year-old intubated man in the surgical intensive care unit reveals an infiltrate in his right lower lobe. Concurrent with this finding, the patient has an elevated leukocyte count and increased endotracheal secretions. Which of the following procedures would have been most effective in preventing ventilator-associated pneumonia (VAP)?

(A) Elevation of the head of bed above 30 degrees

(B) Initiation of ranitidine

(C) Replacement of nasogastric tube with nasoduodenal tube for postpyloric enteral feeding

(D) Selective decontamination of the digestive tract

(E) Use of prophylactic topical antibiotics (intratracheal or oral)

QUESTION 1-170

A 62-year-old woman presents to your clinic with complaints of progressive leg swelling throughout the day. Which of the following is the best method for assessing venous valvular competency?

(A) Arteriography

(B) Duplex Doppler ultrasonography

(C) Impedance plethysmography

(D) Venography

(E) Venography with direct venous cannulation

QUESTION 1-171

A 45-year-old man with a 20-year history of alcohol dependence presents to your general surgery clinic with complaints of fatty, foul-smelling stools, and chronic intractable pain recalcitrant to narcotic therapy. Routine blood work is significant for a megaloblastic anemia, slightly elevated liver function tests, and high blood glucose level. Computed tomography (CT) scan of the abdomen is notable for a small pancreas containing several calcifications and a pancreatic duct dilated to 10 mm. What is the appropriate therapy for this patient?

(A) Analgesics and oral pancreatic enzymes

(B) Classic pancreaticoduodenectomy

(C) Distal pancreatectomy

(D) Longitudinal pancreaticojejunostomy

(E) Pylorus-preserving pancreaticoduodenectomy

۰۲۱-۶۶۱۹۸۵۱۴ www.myuptodate.com دریافت آخرین نسخه آپتودیت آفلاین

QUESTION 1-172

A 68-year-old retired construction worker is admitted to the intensive care unit (ICU) with severe acute pancreatitis. From discussions with his family it is learned that he drinks several glasses of beer and other alcoholic beverages daily. In the course of his resuscitation, he receives approximately 20 L of intravenous fluid. By hospital day 6 he has regained hemodynamic stability and begins to mobilize volume with the aid of furosemide. After a brisk diuresis of 6 L, the covering ICU physician is called to the patient's room because he has developed a substantial tremor, hyper-reflexia, and mental status changes. A serum electrolyte panel demonstrates low potassium. What additional electrolyte is likely to be decreased in this patient?

(A) Calcium
(B) Chloride
(C) Magnesium
(D) Phosphorus
(E) Sodium

QUESTION 1-173

A 70-year-old male with a 60 pack-year smoking history undergoes a Whipple operation for pancreatic adenocarcinoma. Intubated overnight in the surgical intensive care unit, his serial arterial blood gases show marked hypoxemia. The positive end-expiratory pressure (PEEP) is increased from 5-cm H_2O to 10-cm H_2O. The patient's urine output starts to decline thereafter and he receives several boluses of fluid throughout the night. The next morning, he is edematous and still intubated. What is the most likely etiology for his falling urine output?

(A) Acute tubular necrosis (ATN)
(B) Decrease in intra-abdominal pressure
(C) Increase in intrathoracic pressure
(D) Kinked urinary catheter
(E) Reduced renal blood flow

QUESTION 1-174

A 40-year-old female with a long-standing history of Crohn disease presents with rectal pain, intermittent drainage from her perineum, fevers and chills, tachycardia, and hypotension. On examination under anesthesia, the patient is found to have a perianal fistula above the dentate line involving the sphincter muscles. After stabilization of the patient with supportive therapy and initiation of appropriate antibiotics, what is the next most appropriate treatment?

(A) Anti-TNF antibody
(B) Diverting colostomy
(C) Fistulotomy
(D) Seton placement
(E) Treatment with ciprofloxacin and metronidazole

QUESTION 1-175

A 4-year-old girl is brought into the emergency department from preschool after being bitten by a classmate. The bite is on her forearm and is clean with no signs of devitalized tissue. The wound is copiously irrigated and primarily closed. Cultures of the wound taken prior to irrigation are most likely to reveal which bacteria?

(A) *Eikenella corrodens*
(B) *Fusobacterium species*
(C) *Pasteurella multocida*
(D) *Prevotella species*
(E) *Staphylococcus aureus*

QUESTION 1-176

Four years after surgery for a gunshot injury to the right thigh, a 26-year-old man with no other significant past medical history is referred to your clinic due to a thrill and bruit over his right thigh discovered during a routine physical examination. Which of the following findings might you find in this patient?

(A) Blood pressure 160/90 mm Hg
(B) Cardiac output of 3.2 L/min
(C) Heart rate of 55 beats per minute
(D) Left ventricular hypertrophy
(E) Mixed venous oxygen saturation (SvO_2) of 55%

۰۲۱-۶۶۱۹۸۵۱۴ www.myuptodate.com دریافت آخرین نسخه آپتودیت آفلاین

QUESTION 1-177

As part of her workup for anemia, a 60-year-old female undergoes esophagogastroduodenoscopy (EGD), which reveals a 5-cm mass along the greater curvature of the stomach. Biopsy of the mass reveals spindle cells and C-kit expression. A computed tomography (CT) scan shows no other abnormalities. The most appropriate next step for treatment is:

(A) Endoscopic submucosal resection

(B) Total gastrectomy with lymph node resection

(C) Treatment with imatinib followed by total gastrectomy

(D) Wedge resection of gastric mass followed by treatment with imatinib

(E) Wedge resection of the gastric mass

QUESTION 1-178

A 43-year-old male with end-stage renal disease secondary to type II diabetes underwent a deceased donor kidney transplant. Intraoperatively, the allograft became grossly mottled and cyanotic. The surgeon noted capsular bulging due to marked edema, followed by graft rupture. What is the most likely pathophysiology behind this graft failure?

(A) Acute thrombosis of the renal vein

(B) Presence of antibodies directed toward donor ABO blood group antigens

(C) Presence of recipient HLA class I antigens

(D) Sensitized T cells to donor antigens

(E) Stenosis or kinking of the renal artery

QUESTION 1-179

You are caring for a 75-year-old man in the surgical intensive care unit who is postoperative day 3 from an open cholecystectomy for a necrotic gallbladder. The patient is 10 L fluid positive since surgery and is producing only 10 cm^3 of urine per hour. You decide to insert a pulmonary artery catheter. What findings would suggest that the patient has suffered an acute myocardial infarction in the left anterior descending coronary artery distribution?

Key:

SBP = systemic blood pressure

CO = cardiac output

HR = heart rate

SV = stroke volume

SVR = systemic vascular resistance

CVP = central venous pressure

PCWP = pulmonary capillary wedge pressure

(A) ⇑ SBP, ⇓ CO, ⇑ HR, ⇑ SV, ⇑ SVR, ⇓ CVP, ⇓ PCWP

(B) ⇓ SBP, ⇓ CO, ⇓ HR, ⇓ SV, ⇑ SVR, normal CVP, ⇑ PCWP

(C) ⇓ SBP, ⇓ CO, ⇓ HR, ⇓ SV, ⇑ SVR, ⇑ CVP, ⇑ PCWP

(D) ⇓ SBP, normal CO, ⇓ HR, ⇑ SV, ⇑ SVR, ⇓ CVP, ⇑ PCWP

(E) ⇓ SBP, ⇓ CO, ⇑ HR, ⇓ SV, ⇑ SVR, ⇑ CVP, ⇑ PCWP

QUESTION 1-180

A 50-year-old man presents with a history of episodic facial flushing, diarrhea, and palpitations. His examination is notable for hepatomegaly. A workup reveals elevated 24-hour urine 5-hydroxyindoleacetic acid. He is diagnosed with carcinoid syndrome, and undergoes a computed tomography (CT) scan to evaluate the extent of his disease. The radiologist reports metastatic tumor to both lobes of his liver. The gastrointestinal site with the highest metastatic potential is the:

(A) Duodenum

(B) Ileum

(C) Jejunum

(D) Rectum

(E) Stomach

۰۲۱-۶۶۱۹۸۵۱۴ www.myuptodate.com دریافت آخرین نسخه آپتودیت آفلاین

QUESTION 1-181

After being struck by a moving truck, a 23-year-old woman undergoes splenectomy during diagnostic laparotomy. She leaves the hospital against medical advice on postoperative day 4, after refusing vaccination. Infection with which of the following organisms is most likely to result in her developing sepsis?

(A) *Beta–hemolytic streptococcus*

(B) *Candida albicans*

(C) *Clostridium difficile*

(D) *Escherichia coli*

(E) *Pseudomonas aeruginosa*

QUESTION 1-182

A 64-year-old man with a new diagnosis of lung cancer is scheduled for preoperative pulmonary function tests to determine if he is a candidate for surgical pneumonectomy. Which of the following results would confirm him as a good candidate for the proposed surgical procedure?

(A) Diffusing capacity of the lung for carbon monoxide (DLCO) of 85% the predicted value

(B) Predicted postoperative forced expiratory volume in 1 second (FEV1) of 0.7 L

(C) Preoperative PCO_2 of 48 mm Hg on room air

(D) Preoperative PO_2 of 48 mm Hg on room air

(E) VO_2 max (maximal oxygen consumption) of 10 mL/kg/min

QUESTION 1-183

A 62-year-old healthy female patient on your service has just undergone successful sigmoid resection. Final pathology reveals the tumor to be stage IIIA moderately differentiated adenocarcinoma. What adjuvant therapy would most commonly be recommended in this patient?

(A) 5-fluorouracil (5-FU) + leucovorin (LV) + irinotecan

(B) 5-FU + LV + oxaliplatin

(C) 5-FU + LV + oxaliplatin + bevacizumab

(D) Adjuvant therapy is not recommended in this setting

(E) Oral capecitabine

QUESTION 1-184

After sustaining a gunshot wound to the abdomen, a 24-year-old man is brought to the operating room. During exploratory laparotomy, you find gross contamination of the peritoneum by feces resulting from multiple sigmoid colonic enterotomies. Which of the following species of bacteria is the most abundant in feces?

(A) *Bacteroides vulgatus*

(B) *Enterococcus faecalis*

(C) *Escherichia coli*

(D) *Klebsiella pneumoniae*

(E) *Pseudomonas aeruginosa*

QUESTION 1-185

A 63-year-old female with a 30 pack-year history of smoking presents complaining of a persistent cough and a 4.54-kg (10-lb) weight loss, but is otherwise physically active. Chest computed tomography (CT) demonstrates a solitary, spiculated, 2.8-cm mass in the periphery of the right upper lobe without evidence of spread to mediastinal lymph nodes or to the contralateral lung. Fine-needle biopsy is consistent with non–small-cell adenocarcinoma of the lung. Integrated Positron Emission Tomography and Computed Tomography (PET–CT) demonstrates disease confined to the known right upper lobe lesion. She is referred to you for further management. What is the preferred treatment for this patient?

(A) Chemotherapy alone

(B) Chemotherapy plus radiation therapy

(C) Lobectomy and mediastinal lymphadenectomy

(D) Pneumonectomy and mediastinal lymphadenectomy

(E) Wedge resection of the tumor

QUESTION 1-186

A 50-year-old man with acute diverticulitis requires a colectomy. During the operation, it is noted that there is gross contamination of the peritoneal cavity with fecal material. The decision is made to perform a Hartman procedure and leave the patient with an end-colostomy. Over the next 5 years, the subsequent risk of development of a parastomal hernia in this patient is:

(A) 10%

(B) 20%

(C) 40%

(D) 50%

(E) 85%

۰۲۱-۶۶۱۹۸۵۱۴ www.myuptodate.com دریافت آخرین نسخه آپتودیت آفلاین

QUESTION 1-187

A 40-year-old woman with type I von Willebrand disease (vWD) presents for an elective cholecystectomy. What precautions should the surgical and anesthesia team take, and why?

(A) Administer a dose of IV Vitamin K the night prior to surgery for the anticipated elevated INR

(B) Ensure adequate fresh frozen plasma is ordered for the anticipated elevated INR

(C) Have desmopressin (DDAVP) available to reverse the platelet dysfunction

(D) Have recombinant factor VIII available for a deficiency in this clotting factor

(E) Type and cross 4 units of packed red blood cells for the congenital anemia

QUESTION 1-188

A 6-year-old boy referred to your clinic after workup for recurrent pneumonia reveals extralobar pulmonary sequestration (PS). Which of the following characteristics is most commonly associated with the patient's diagnosis?

(A) Abnormal tissue surrounded by normal lung parenchyma

(B) Arterial supply from the abdominal aorta

(C) Ebstein anomaly

(D) Usually occurs in upper lobes

(E) Venous drainage via the inferior pulmonary ligament

QUESTION 1-189

A 64-year-old male presents to clinic complaining of a recent history of bright red blood per rectum with associated constipation and decreased stool caliber. A digital rectal examination is performed and a mass is palpated in the proximal rectal vault. Endorectal ultrasound (EUS) with biopsy reveals a rectal adenocarcinoma invading the subserosa approximately 8 cm from the anal verge and a CT scan reveals no evidence of metastatic disease. Therefore, the stage is IIA (T3, N0, M0). What is the appropriate surgical management of this tumor?

(A) Abdominosacral resection

(B) Diverting colostomy followed by chemotherapy

(C) Low anterior resection (LAR)

(D) No surgery; primary chemotherapy and radiation therapy only

(E) Transanal excision

QUESTION 1-190

You are called to the neonatal intensive care unit to see a full-term neonate with suspected malrotation. The baby's nurse reminds you of the importance of washing your hands thoroughly before touching the child. Why is this of particular importance?

(A) It is unknown whether the child has HIV and he may be immunosuppressed

(B) Neonatal neutrophils have impaired chemotaxis

(C) Neonates have weak coughs and are unable to clear their secretions

(D) Newborn lungs lack IgA in the mucosal barrier to protect against airborne pathogens

(E) Newborns have immature immune systems because their T cells have not fully differentiated and remain within their thymus

۰۲۱-۶۶۱۹۸۵۱۴ www.myuptodate.com دریافت آخرین نسخه آپتودیت آفلاین

QUESTION 1-191

You are caring for an intubated patient in the intensive care unit who is hypovolemic but has normal left ventricular function. Which of the following is an effect of the inspiration phase of positive-pressure mechanical ventilation?

(A) Decreased cardiac output
(B) Decreased intrathoracic pressure
(C) Increased cardiac output
(D) Increased ventricular distensibility
(E) Reverse pulsus paradoxus

QUESTION 1-192

A duodenal diverticulum is seen in a 58-year-old man with recurrent episodes of acute pancreatitis. On endoscopic evaluation, the ampulla of Vater is found to be located just distal to the border of the diverticular opening. What is the most appropriate interventional management of this patient's duodenal diverticulum?

(A) Endoscopic sphincterotomy and stent placement
(B) Inversion and oversewing of the diverticulum
(C) Pancreaticoduodenectomy
(D) Resection with choledochoduodenostomy
(E) Resection with two-layer transverse closure

QUESTION 1-193

A 54-year-old woman visited her primary care physician for a routine check-up. On physical examination, the doctor noted a right carotid bruit. A subsequent contrast angiogram revealed 50% stenosis of her right carotid artery. Carotid endarterectomy for asymptomatic patients is indicated for stenoses defined by diameter reduction of:

(A) >90%
(B) >80%
(C) >70%
(D) >60%
(E) >50%

QUESTION 1-194

What is the anatomic origin of the replaced right hepatic artery?

(A) Common hepatic artery
(B) Gastroduodenal artery
(C) Proper hepatic artery
(D) Right hepatic artery
(E) Superior mesenteric artery (SMA)

QUESTION 1-195

A 37-year-old male is seen in the emergency department with abdominal pain. He has no known allergies. He undergoes computed tomography (CT) scan with oral and IV contrast. Which is the most likely reaction he will develop to the iodine contrast?

(A) Cardiac arrest
(B) Dyspnea
(C) Flushing
(D) Itching
(E) Nausea

QUESTION 1-196

Which of the following tests is the most prognostic of liver function reserve?

(A) Albumin measurement
(B) Aminopyrine breath test
(C) Bromsulphalein clearance test
(D) Gamma-glutamyl transpeptidase (GGT) measurement
(E) Transferrin measurement

QUESTION 1-197

You are treating a 56-year-old woman with Crohn disease for recurrent perianal fistulas. Before starting the patient on infliximab, you warn her that she may be at increased risk of several complications. Which of the following is considered the most common complication attributable to treatment of Crohn disease with infliximab?

(A) Anaphylaxis
(B) Lupus-like syndrome
(C) Lymphoma
(D) Tuberculosis pneumonia
(E) Urticaria

۰۲۱-۶۶۱۹۸۵۱۴ www.myuptodate.com دریافت آخرین نسخه آپتودیت آفلاین

QUESTION 1-198

Pancreatic acini secrete enzymes that play an important role in the digestion of proteins. What is the most potent stimulant of pancreatic acinar cells?

(A) Acetylcholine
(B) Cholecystokinin (CCK)
(C) Peptide YY
(D) Secretin
(E) Trypsinogen

QUESTION 1-199

You are a tumor researcher trying to find novel cancer treatments. One of your projects involves constructing a tumor vaccine for breast cancer. Such a vaccine would take advantage of which of the following aspects of the immune system to prevent cancer?

(A) Activation of latent T cells in the thymus
(B) Adaptive immunity
(C) Cytokine activation
(D) Innate immunity
(E) Type IV hypersensitivity reaction

QUESTION 1-200

A 72-year-old alcoholic man with ascites undergoes emergent colectomy for a lower gastrointestinal bleed. During his postoperative recovery, urine output is consistently low (250 to 475 mL/day), serum creatinine rises progressively but central venous pressure remains normal. Twenty-four-hour urinalysis on postoperative day 4 is as follows.

Volume:	374 cm^3
Color:	Yellow
Micro:	Renal epithelial cells
Urine [Na]:	<10 mEq/L
Urine Specific Gravity:	1.030
Serum Specific Gravity:	1.004
pH:	5.0

What is the most likely diagnosis accounting for this?

(A) Acute tubular necrosis (ATN)
(B) Hepatorenal syndrome
(C) Prerenal azotemia
(D) Type 1 renal tubular acidosis (RTA)
(E) Type 4 RTA

QUESTION 1-201

A 37-year-old woman with Crohn disease who has been managed on total parenteral nutrition for 6 months complains of nonhealing ulcers on her lower extremities. On physical examination she has bilateral pretibial erythematous areas with blisters, pustules, and superficial ulcerations. Which of the following elemental deficiencies would be most consistent with this clinical picture?

(A) Chromium
(B) Copper
(C) Iron
(D) Selenium
(E) Zinc

QUESTION 1-202

You are about to divide a short gastric artery during a total gastrectomy, when the attending surgeon asks you, "What is the mechanism of action of gastrin?" You answer that it is:

(A) Secreted by the chief cells of the stomach, and stimulates the release of cholecystokinin
(B) Secreted by the G cells of the stomach, and promotes peristalsis
(C) Secreted by the gastrin cells of the stomach, and stimulates parietal cells
(D) Secreted by the parietal cells of the stomach, and promotes mucus release
(E) Secreted by the parietal cells of the stomach, and stimulates the release of insulin from the pancreas

QUESTION 1-203

A 62-year-old man has developed acute respiratory distress syndrome 1 week after abdominal aortic aneurysm repair. Multiple efforts to control his high peak airway pressures have been unsuccessful, and you have decided to use muscle relaxants on him in order to facilitate ventilation. While preparing pancuronium for administration, the nurse asks what is the most likely side effect of this paralytic?

(A) Central nervous system toxicity
(B) Histamine release
(C) Hypotension
(D) Residual motor weakness
(E) Tachycardia

۰۲۱-۶۶۱۹۸۵۱۴ www.myuptodate.com دریافت آخرین نسخه آپتودیت آفلاین

QUESTION 1-204

Erythromycin can act as a secretagogue for which of the following?

(A) Cholecystokinin (CCK)

(B) Gastrin

(C) Motilin

(D) Secretin

(E) Somatostatin

QUESTION 1-205

A 43-year-old woman with Hepatitis C and hepatocellular carcinoma undergoes orthotopic liver transplantation. Her explanted liver demonstrates a solitary, 4.9-cm hepatocellular carcinoma with evidence of vascular invasion but without spread to regional lymph nodes. The stage of her hepatocellular carcinoma is:

(A) Stage I

(B) Stage II

(C) Stage IIIA

(D) Stage IIIB

(E) Stage IIIC

QUESTION 1-206

A 64-year-old man in the intensive care unit has hematemesis and melena. The patient has undergone unsuccessful endoscopic attempts to stop the bleeding of an ulcer in the duodenal bulb. He is now hemodynamically unstable and intubated. The ligation of which artery during surgery is most likely to stop the bleeding?

(A) Gastroduodenal artery (GDA)

(B) Posterior superior pancreaticoduodenal artery

(C) Right gastric artery

(D) Right gastroepiploic artery

(E) Supraduodenal artery

QUESTION 1-207

The policymakers at your institution would like to implement a new warfarin protocol for patients with aortic valve replacements. They would like you to provide them with the international normalized ratio (INR) value that best describes the current population of aortic valve replacement patients with stable INR levels. Assume the INR levels are normally distributed among your patient population. What test statistic would be best to provide them?

(A) Mean

(B) Median

(C) Mode

(D) Standard error

(E) Z statistic

QUESTION 1-208

A 50-year-old woman presents to your outpatient clinic with a 4-week history of postprandial right upper quadrant pain. A right upper quadrant ultrasound does not show any evidence of cholelithiasis or cholecystitis. You should next:

(A) Admit her for hydration and pain control and schedule a laparoscopic cholecystectomy for the following day

(B) Arrange for an endoscopic retrograde cholangiopancreatography (ERCP)

(C) Obtain a noncontrast computed tomography (CT) scan

(D) Obtain an upper endoscopy

(E) Obtain cholecystokinin cholescintigraphy (CCK-CS)

۰۲۱-۶۶۱۹۸۵۱۴ www.myuptodate.com دریافت آخرین نسخه آپتودیت آفلاین

QUESTION 1-209

Medicare is considering whether to continue funding gastric bypass procedures. A key concern of the Medicare officials is the average weight loss among gastric bypass patients. Your institution has been asked to provide them with evidence demonstrating the associated probability of weight loss reported by your center. What information should you provide to the medicare officials?

(A) 95% confidence interval of the mean difference between preoperative and postoperative weights

(B) 95% confidence interval of the median difference between preoperative and postoperative weights

(C) Mean difference between preoperative and postoperative weights

(D) Median difference between preoperative and postoperative weights

(E) Mode of the difference between preoperative and postoperative weights

QUESTION 1-210

Which of the following statements regarding lipid metabolism is correct?

(A) Fatty acids are used to synthesize glucose in times of starvation

(B) Fatty acids enter the tricarboxylic acid cycle as either acetyl-CoA or succinyl-CoA

(C) Glucagon and epinephrine act to promote fatty acid synthesis

(D) Insulin induces release of fatty acids from adipocytes

(E) Lipid oxidation occurs in the cytoplasm

QUESTION 1-211

A 10-year-old boy develops right lower quadrant pain, nausea, vomiting, and fever. You suspect appendicitis and plan for an emergent appendectomy. As you are preparing to transport him to the operating room, his parents mention that he has hemophilia A. What should you administer for this condition?

(A) Cryoprecipitate

(B) Factor VII

(C) Factor VIII

(D) Fresh frozen plasma (FFP)

(E) Vitamin K

QUESTION 1-212

A 52-year-old woman is referred to you after a several year history of progressive dysphagia that began with liquids and then progressed to include solid foods. She describes a sensation that her food is "sticking" and will not pass into her stomach. Barium swallow evaluation demonstrates diffuse dilation and a narrow tapering of the distal esophagus. Esophageal manometry reveals lower esophageal sphincter (LES) pressures that remain constant throughout a swallow test. You make the diagnosis of achalasia and discuss treatment options with her. Which of the following is true regarding the LES in healthy patients?

(A) Gastric distension causes decreased LES tone

(B) LES pressure decreases during the initiation of a swallow

(C) The LES can be visualized by upper endoscopy

(D) The LES is a specific anatomic sphincter

(E) The LES serves to prevent air from entering the stomach during a swallow

QUESTION 1-213

A 35-year-old man is referred to you with an asymptomatic, 12-cm mass in his left thigh. Magnetic resonance imaging (MRI) of the thigh and computed tomography (CT) of the chest demonstrate no evidence of nodal or distant metastases. A core-needle biopsy is interpreted as fibrosarcoma. You perform a radical resection and the final pathology returns as a moderately differentiated fibrosarcoma. The most important prognostic factor in soft tissue sarcomas is the:

(A) Location of the primary tumor

(B) Histologic grade of the tumor

(C) Size of the primary tumor

(D) Presence of nodal metastases

(E) Presence of distant metastases

۰۲۱-۶۶۱۹۸۵۱۴ www.myuptodate.com دریافت آخرین نسخه آپتودیت آفلاین

QUESTION 1-214

A 2-year-old boy with no significant past medical history presents with a 1-month history of episodic, painless rectal bleeding. Findings on physical examination, including rectal examination, are unremarkable. The most useful imaging study in this situation is:

(A) ^{99m}Tc-pertechnetate scan

(B) Abdominal computed tomography (CT) scan

(C) Abdominal ultrasound scanning

(D) Barium enema

(E) Selective mesenteric angiography

QUESTION 1-215

A 25-year-old man is brought to the trauma bay after two gunshot wounds to the left chest and mid back. His heart rate is 130 beats per minute, his blood pressure is 80/40 mm Hg and he has a Glasgow Coma Scale of 9. It is estimated that he lost approximately 2 L of blood in the field and that he has lost another 2 L within the trauma bay during the initial assessment. Which of the following effects would be most likely due to rapid resuscitation with blood products in this patient?

(A) Cerebral hemorrhage

(B) Jaundice and fever seen a week later

(C) Massive lower-extremity swelling

(D) Myoglobinuria

(E) Temporary blindness

QUESTION 1-216

A 48-year-old former alcoholic man is now 10 weeks status post liver transplantation. He has experienced several weeks of episodic fevers with leukocytosis, overall malaise, and failure to thrive. In addition, his liver enzymes have increased over the past several days. His blood cultures are positive but he has no central venous lines. His urine culture is negative for pathogens. Computed tomography (CT) of his abdomen reveals multiple liver abscesses. Which of the following organisms is most likely causing this condition?

(A) *Echinococcus*

(B) *Entamoeba histolytica*

(C) *Klebsiella pneumoniae*

(D) *Schistosoma mansoni*

(E) *Staphylococcus aureus*

QUESTION 1-217

On postoperative day 4 after a Whipple procedure, a patient develops symptoms consistent with massive pulmonary embolism. Computed tomography confirms a saddle embolus. After emergent lytic therapy with urokinase, the patient is bleeding from the surgical site. Which of the following options is the best choice to treat the bleeding?

(A) Aminocaproic acid

(B) Cryoprecipitate

(C) Dextran

(D) Fresh frozen plasma

(E) Packed red blood cells

QUESTION 1-218

A 65-year-old woman is referred by her primary care provider for a 2-month history of progressive nausea, vomiting, palpitations, anorexia, and lethargy. A computed tomography (CT) scan is performed and reveals a mass in the first portion of the duodenum. The diagnosis of gastric outlet obstruction secondary to pancreatic cancer is made. She is admitted to hospital for further preoperative evaluation. What metabolic abnormalities require monitoring in this patient?

(A) Euvolemic, normokalemia, respiratory acidosis, normochloremia

(B) Hypervolemia, hyperkalemia, metabolic acidosis, hyperchloremia

(C) Hypovolemia, hyperkalemia, metabolic acidosis, normochloremia

(D) Hypovolemia, hypokalemia, metabolic alkalosis, hypochloremia

(E) Hypovolemia, normokalemia, metabolic alkalosis, normochloremia

۰۲۱-۶۶۱۹۸۵۱۴ www.myuptodate.com دریافت آخرین نسخه آپتودیت آفلاین

QUESTION 1-219

You receive a phone call from a 62-year-old female complaining of inability to urinate. Ten hours prior, she underwent a hemorrhoidectomy. How should you manage this problem?

(A) Tell the patient not to worry, that she will urinate eventually

(B) Tell the patient to contact you again if she does not urinate within 24 hours of the surgery

(C) Tell the patient to drink more fluids

(D) Tell the patient to phone the urologist on call

(E) Tell the patient to return to the emergency department for placement of a Foley catheter

QUESTION 1-220

Which of the following characteristics is specific to the diagnosis of primary hyperaldosteronism?

(A) Adrenal tumor

(B) Aldosterone excess

(C) Edema

(D) Hypertension

(E) Hypokalemia

QUESTION 1-221

During afternoon rounds, a patient who is 3 days status post right hemicolectomy complains of right arm pain. You note that the arm has a peripheral intravenous (IV) in it with surrounding warmth and erythema. What is the best course of action?

(A) Begin a 3-day course of IV cephalosporin antibiotics

(B) Draw two sets of peripheral blood cultures

(C) Elevate the affected arm and alternate warm compresses and ice packs

(D) Order a stat right upper-extremity venous duplex

(E) Remove the peripheral IV

QUESTION 1-222

Pancreatic enzymes are secreted as zymogens to prevent inappropriate activation within the pancreas. Which of the following enzymes can autoactivate to produce the active form of the enzyme?

(A) Carboxypeptidase A

(B) Chymotrypsin

(C) Elastase

(D) Enterokinase

(E) Trypsin

QUESTION 1-223

A 68-year-old man presents with progressive onset of painless jaundice due to an adenocarcinoma located in the pancreatic head. He undergoes a pylorus-preserving pancreaticoduodenectomy without intraoperative complications. A peripancreatic drain is placed intraoperatively. Postoperative course is unremarkable and on postoperative day 4, he is advanced to a regular diet. Upon resuming this regular diet, it is noticed that the patient's peripancreatic drain begins to produce moderate volumes of murky fluid. An amylase level is sent from this fluid, which returns at 2,000 units/L (normal 23 to 85 units/L). The patient is kept in the hospital and the drain output over the next 3 days is 85 mL/24 hr, 73 mL/24 hr and 65 mL/24 hr. During this time, the patient looks and feels well, is able to tolerate a regular diet, and has no fever or elevation of white blood cell count. Which of the following is the most appropriate way to manage this problem?

(A) Continued hospitalization with continued drainage

(B) Delayed removal of drain over course of weeks with continuation of diet

(C) Removal of pancreatic drain and patient discharge

(D) Reoperative exploration

(E) Total parenteral nutrition with continued drainage

۰۲۱-۶۶۱۹۸۵۱۴ www.myuptodate.com دریافت آخرین نسخه آپتودیت آفلاین

QUESTION 1-224

A 58-year-old male presents complaining of constipation, nausea, loss of appetite, right-sided flank pain, and postural dizziness. A complete blood count (CBC) is drawn and reveals hemoglobin of 6.8 g/dL and slightly elevated WBC count of 12,000. Colonoscopy reveals a circumferential narrowing at the hepatic flexure that bleeds easily when biopsied. Computed tomography (CT) shows some enlarged mesenteric lymph nodes and a normal liver. The patient is referred for surgery. Which procedure would best benefit this patient?

(A) Extended right hemicolectomy

(B) Right hemicolectomy

(C) Subtotal colectomy with primary anastomosis

(D) Total colectomy with ileorectal anastomosis

(E) Total proctocolectomy with ileal-pouch anal anastomosis

QUESTION 1-225

Which of the following risk factors predicts the highest risk of developing breast cancer?

(A) Age greater than 55

(B) Biopsy proven lobular carcinoma in situ (LCIS)

(C) BRCA-1 or BRCA-2 (breast cancer 1 or breast cancer 2) mutation

(D) Mother with breast cancer

(E) Nulliparity

۰۲۱-۶۶۱۹۸۵۱۴ www.myuptodate.com دریافت آخرین نسخه آپتودیت آفلاین

ANSWER KEY FOR PRACTICE EXAMINATION 1

The answer key lists the correct answer choice by letter, followed by the explanation number.

B = Body as a Whole

G = Gastrointestinal

C = Cardiovascular and Respiratory

M = Miscellaneous (Genitourinary, Head and Neck, Skin, Muscle, and Nervous System)

E = Endocrine, Hematic, Lymphatic, and Breast

۰۲۱-۶۶۱۹۸۵۱۴ www.myuptodate.com دریافت آخرین نسخه آپتودیت آفلاین

Question Number	Correct Answer	Explanation Number	Question Number	Correct Answer	Explanation Number	Question Number	Correct Answer	Explanation Number
1-1	C	1B01	1-26	E	1B06	1-51	B	1B11
1-2	D	1C01	1-27	E	1C06	1-52	E	1C11
1-3	A	1E01	1-28	B	1E06	1-53	B	1E11
1-4	E	1G01	1-29	A	1G06	1-54	B	1G11
1-5	E	1M01	1-30	C	1M06	1-55	B	1M11
1-6	D	1B02	1-31	A	1B07	1-56	B	1B12
1-7	D	1C02	1-32	B	1C07	1-57	E	1C12
1-8	D	1E02	1-33	B	1E07	1-58	E	1E12
1-9	B	1G02	1-34	A	1G07	1-59	A	1G12
1-10	A	1M02	1-35	A	1M07	1-60	B	1M12
1-11	C	1B03	1-36	C	1B08	1-61	B	1B13
1-12	C	1C03	1-37	B	1C08	1-62	D	1C13
1-13	C	1E03	1-38	E	1E08	1-63	C	1E13
1-14	A	1G03	1-39	B	1G08	1-64	D	1G13
1-15	B	1M03	1-40	B	1M08	1-65	D	1M13
1-16	A	1B04	1-41	D	1B09	1-66	D	1B14
1-17	D	1C04	1-42	B	1C09	1-67	A	1C14
1-18	D	1E04	1-43	B	1E09	1-68	D	1E14
1-19	D	1G04	1-44	E	1G09	1-69	C	1G14
1-20	E	1M04	1-45	E	1M09	1-70	A	1M14
1-21	B	1B05	1-46	D	1B10	1-71	A	1B15
1-22	C	1C05	1-47	E	1C10	1-72	A	1C15
1-23	E	1E05	1-48	C	1E10	1-73	C	1E15
1-24	C	1G05	1-49	D	1G10	1-74	C	1G15
1-25	D	1M05	1-50	D	1M10	1-75	C	1M15

۰۲۱-۶۶۱۹۸۵۱۴ www.myuptodate.com دریافت آخرین نسخه آپتودیت آفلاین

Question Number	Correct Answer	Explanation Number
1-76	D	1B16
1-77	C	1E16
1-78	B	1E17
1-79	D	1G16
1-80	C	1M16
1-81	C	1B17
1-82	C	1E18
1-83	A	1E19
1-84	C	1G17
1-85	E	1M17
1-86	C	1B18
1-87	C	1E20
1-88	E	1E21
1-89	D	1G18
1-90	E	1M18
1-91	E	1B19
1-92	C	1E22
1-93	E	1E23
1-94	D	1G19
1-95	B	1M19
1-96	A	1B20
1-97	C	1E24
1-98	A	1E25
1-99	C	1G20
1-100	A	1M20
1-101	C	1B21
1-102	A	1E26
1-103	B	1E27
1-104	E	1G21
1-105	A	1M21
1-106	E	1B22
1-107	E	1C16
1-108	C	1E28
1-109	A	1G22
1-110	A	1M22
1-111	B	1B23
1-112	B	1C17
1-113	C	1E29
1-114	D	1G23
1-115	C	1M23
1-116	B	1B24
1-117	C	1C18
1-118	E	1E30
1-119	B	1G24
1-120	B	1M24
1-121	E	1B25
1-122	C	1C19
1-123	A	1E31
1-124	A	1G25
1-125	B	1M25
1-126	C	1B26
1-127	E	1C20
1-128	A	1E32
1-129	A	1G26
1-130	D	1M26
1-131	D	1B27
1-132	E	1C21
1-133	E	1E33
1-134	A	1G27
1-135	D	1M27
1-136	A	1B28
1-137	A	1C22
1-138	B	1E34
1-139	A	1G28
1-140	E	1M28
1-141	A	1B29
1-142	C	1C23
1-143	C	1E35
1-144	C	1G29
1-145	D	1M29
1-146	E	1B30
1-147	A	1C24
1-148	A	1E36
1-149	E	1G30
1-150	C	1M30

۰۲۱-۶۶۱۹۸۵۱۴ www.myuptodate.com دریافت آخرین نسخه آپتودیت آفلاین

Question Number	Correct Answer	Explanation Number	Question Number	Correct Answer	Explanation Number	Question Number	Correct Answer	Explanation Number
1-151	B	1B31	1-176	D	1C32	1-201	E	1B48
1-152	A	1C25	1-177	D	1G38	1-202	C	1G48
1-153	A	1G62	1-178	B	1B39	1-203	E	1B49
1-154	B	1G31	1-179	E	1C33	1-204	C	1G49
1-155	A	1M31	1-180	B	1G39	1-205	B	1B50
1-156	B	1B32	1-181	A	1B40	1-206	A	1G50
1-157	B	1C26	1-182	A	1C34	1-207	A	1B51
1-158	D	1G32	1-183	B	1G40	1-208	E	1G51
1-159	B	1M32	1-184	A	1B41	1-209	A	1B52
1-160	C	1B33	1-185	C	1C35	1-210	B	1G52
1-161	E	1C27	1-186	D	1G41	1-211	C	1B53
1-162	B	1G33	1-187	C	1B42	1-212	B	1G53
1-163	E	1B34	1-188	B	1C36	1-213	B	1B54
1-164	E	1C28	1-189	C	1G42	1-214	A	1G54
1-165	A	1G34	1-190	B	1B43	1-215	B	1B55
1-166	B	1B35	1-191	A	1C37	1-216	C	1G55
1-167	D	1C29	1-192	A	1G43	1-217	D	1B56
1-168	B	1G35	1-193	D	1B44	1-218	D	1G56
1-169	A	1B36	1-194	E	1G44	1-219	E	1B57
1-170	B	1C30	1-195	E	1B45	1-220	A	1G57
1-171	D	1G36	1-196	B	1G45	1-221	E	1B58
1-172	C	1B37	1-197	A	1B46	1-222	E	1G58
1-173	E	1C31	1-198	B	1G46	1-223	B	1G59
1-174	D	1G37	1-199	B	1B47	1-224	A	1G60
1-175	E	1B38	1-200	B	1G47	1-225	C	1G61

۰۲۱-۶۶۱۹۸۵۱۴ www.myuptodate.com دریافت آخرین نسخه آپتودیت آفلاین

II
QUESTIONS WITH ANSWERS AND EXPLANATIONS FOR PRACTICE EXAMINATION 1

۰۲۱-۶۶۱۹۸۵۱۴ www.myuptodate.com دریافت آخرین نسخه آپتودیت آفلاین

دریافت آخرین نسخه آپتودیت آفلاین www.myuptodate.com ۰۲۱-۶۶۱۹۸۵۱۴

1
BODY AS A WHOLE

CONTENTS:

Number:	Key Word:	Page:
1B01	Initial Treatment for Coagulopathy of Chronic Renal Failure	55
1B02	Condition Associated with Family History of Cecal Cancer	56
1B03	Treatment of Umbilical Hernia with Ascites	58
1B04	Characteristics of NSQIP	58
1B05	Diagnosis of Lymphocele in Deceased Donor Kidney Transplant	59
1B06	Treatment of CO_2 Embolus during Laparoscopic Cholecystectomy	60
1B07	Characteristics of Local Anesthetic Toxicity	60
1B08	Etiology of Recurrence in Laparoscopic Hernia Repair	62
1B09	Tetanus Prophylaxis	62
1B10	Difference in ARDS versus Ventilator-associated Pneumonia	63
1B11	Treatment of Incarcerated Inguinal Hernia	65
1B12	Etiology of Hyponatremia in Pancreatitis	66
1B13	Treatment of Hypotension after Removal of Pheochromocytoma	66
1B14	Initial IV Fluid in Treatment of Dehydration	67
1B15	Diagnosis of Thrombosis of Hepatic Artery after Liver Transplantation	68
1B16	Diagnostic Test for Soft Tissue Sarcoma of the Thigh	68
1B17	Conditions Associated with Normal Anion Gap Acidosis	69
1B18	Treatment of 0.6-mm Melanoma of the Forearm	70
1B19	Antibiotic Treatment of Emphysematous Cholecystitis	71
1B20	Preoperative Treatment of Increased INR from Warfarin	72
1B21	Maintenance of Core Temperature in the Operating Room	72
1B22	Treatment of Fournier Gangrene	73
1B23	Indications for Liver Transplant in End-stage Liver Disease	74
1B24	Preoperative Predictor of Perioperative Cardiac Complications	74
1B25	Respiratory Quotient of Fat in TPN	76
1B26	Treatment of Hypothermia	77
1B27	Treatment of Hypochloremic Alkalosis	77
1B28	Diagnosis of Metabolic Alkalosis	79
1B29	Etiology of Hypotension in Hemorrhagic versus Blunt Trauma	79
1B30	Treatment of Respiratory Burn	80
1B31	Diagnosis of Primary Lung Cancer	80
1B32	Etiology of Arrhythmia in Torsade de Pointes	81

۰۲۱-۶۶۱۹۸۵۱۴ www.myuptodate.com دریافت آخرین نسخه آپتودیت آفلاین

Number:	Key Word:	Page:
1B33	Most Common Hepatic Artery Variants	82
1B34	Hemodynamic Findings in Septic Shock	83
1B35	Prevention of Surgical Site Infections	84
1B36	Reduction of Nosocomial Infection on Ventilator	86
1B37	Findings Associated with Hypomagnesemia	87
1B38	Bacteriology of Human Bites	87
1B39	Hyperacute Rejection of Renal Transplants	88
1B40	Mechanism of Altered Immunity Postsplenectomy	89
1B41	Most Abundant Fecal Bacterial Flora	90
1B42	Laboratory Values Abnormal with von Willebrand Disease	91
1B43	Increased Bacterial Infection in Newborns versus Adults	92
1B44	Indication for Carotid Endarterectomy	92
1B45	Most Common Reaction to Iodine Contrast	93
1B46	Risks of Infliximab Therapy	94
1B47	Adaptive Immunotherapy for Tumors	95
1B48	Zinc Deficiency Secondary to TPN	95
1B49	Most Common Side Effect of Pancuronium	96
1B50	Staging of Hepatocellular Carcinoma	96
1B51	Most Representative Descriptive Statistic	97
1B52	Characteristics of Confidence Intervals	98
1B53	Perioperative Treatment of Hemophilia	98
1B54	Staging of Soft Tissue Sarcoma	100
1B55	Effects of Rapid Massive Transfusion	101
1B56	Treatment of Urokinase Overdose	102
1B57	Urinary Retention Post-hemorrhoidectomy	102
1B58	Treatment of Infected IV Site	103

۰۲۱-۶۶۱۹۸۵۱۴ www.myuptodate.com دریافت آخرین نسخه آپتودیت آفلاین

1B01

Key word: Initial Treatment for Coagulopathy of Chronic Renal Failure

Author: Robert A. Meguid, MD, MPH
Editor: Elliott R. Haut, MD, FACS

A 76-year-old dialysis-dependent woman with a history of multiple prior abdominal operations presents to the emergency room with worsening abdominal pain. Workup raises your suspicions for ischemic bowel. She last underwent hemodialysis 3 days prior, and is currently uremic. How will you best prepare the patient for emergent celiotomy?

(A) Administer conjugated estrogens

(B) Administer cryoprecipitate

(C) Administer desmopressin

(D) Arrange for dialysis

(E) Transfuse the patient with packed red blood cells (PRBC)

Answer: (C) Administer desmopressin

Rationale:

The patient has chronic renal failure (CRF), which results in a coagulopathy that must be corrected prior to surgery. The mechanism leading to the coagulopathy associated with CRF is thought to be due to uremic inactivation of von Willebrand Factor (vWF). vWF normally binds platelets to collagen, initiating formation of the platelet plug.

Desmopressin, or DDAVP, causes the release of vWF and Factor VIII from the endothelium. Time to effect of DDAVP is within 1 hour of administration and may last for up to 4 hours. DDAVP may also be used for reversal of platelet dysfunction caused by aspirin as well as following cardiopulmonary bypass. Treatment dose is 0.3 μg/kg, and this is typically given as a single dose. Administration of DDAVP avoids the risks associated with blood product transfusion.

Dialysis, while effective at correcting the patient's uremia, may not immediately correct the coagulopathy. Hemodialysis can correct platelet function but only transiently. The heparin commonly used with dialysis may contribute to the bleeding diathesis. While the effects of hemodialysis or peritoneal dialysis may last for up to a few days, the onset of effect and setup is slower than for DDAVP administration.

Transfusion with PRBC may correct the anemia associated with CRF, but does not rectify the coagulopathy caused by uremia.

Infusion of cryoprecipitate can shorten bleeding time for up to 12 hours by increasing Factor VIII and vWF levels. However, supplies may be limited, and a large quantity may be required to correct a uremic coagulopathy, translating into high costs.

Conjugated estrogens are effective at shortening the bleeding time in uremic patients. However, they need to be administered over several days, because onset to effect is 72 hours.

References:

Henke PK, Wakefield TW. Hemostasis. In: Mulholland MW, Lillemoe KD, Doherty GM, Maier RV, Upchurch GR, eds. *Greenfield's Surgery: Scientific Principles & Practice.* 5th ed. Philadelphia, PA: Lippincott Williams & Wilkins; 2011.

Marks PW, Rosovsky R. Chapter 156: Hematologic manifestations of systemic disease: Liver and renal disease. In: Hoffman R, Benz EJ, Shattil SJ, Furie B, Cohen HJ, Silberstein LE, McGlave P, eds. *Hematology: Basic Principles and Practice.* 4th ed. New York, NY: Elsevier; 2008.

۰۲۱-۶۶۱۹۸۵۱۴ www.myuptodate.com دریافت آخرین نسخه آپتودیت آفلاین

1B02

Key word: Condition Associated with Family History of Cecal Cancer

Author: Robert A. Meguid, MD, MPH
Editors: Thomas H. Magnuson, MD, and Kenzo Hirose, MD, FACS

A 39-year-old male is referred to your clinic for treatment of a cecal mass diagnosed by surveillance colonoscopy. His father, paternal grandmother, and paternal uncle all developed colon cancer by their fifth decade. Mutation of which of the following genes is associated with this man's disease?

(A) APC
(B) BRCA1
(C) BRCA2
(D) hMSH2
(E) K-Ras

Answer: (D) hMSH2

Rationale:

Hereditary nonpolyposis colorectal cancer (HNPCC), also known as Lynch syndrome, is an autosomal dominant hereditable disease caused by mutations in DNA mismatch repair genes including hMSH2, hMLH1, hPMS1, and hPMS2. Polyps are smaller than those seen in other familial colorectal cancer syndromes, and usually number less than 100. HNPCC tumors typically originate in the right colon; however, they may present as multiple synchronous cancers. Clinical criteria for the diagnosis of Lynch syndrome include the Amsterdam criteria I and II as well as the Bethesda criteria. Amsterdam criteria I requires that familial adenomatous polyposis be excluded, that three relatives with colorectal cancer, spanning two generations be affected with, one being a first-degree relative of the others, and one with a diagnosis before age 50. Amsterdam II criteria includes three relatives with an HNPCC-associated cancer (colorectal, endometrial, ovarian, stomach, small intestine, biliary tract, ureter, renal pelvis, and sebaceous gland adenomas) with relatives that meet the rest of the criteria of Amsterdam I. Amsterdam I and Amsterdam II have relatively low sensitivities in diagnosing Lynch syndrome of 61% and 78%, respectively, leading to the development of the Bethesda guidelines which expand the criteria, and include synchronous colon cancers, microsatellite instability, and synchronous HNPCC-related cancer. The patient in question meets Amsterdam I criteria and should have his cancer submitted for microsatellite instability testing and undergo genetic counseling and possible germline mutational analysis. Patients with HNPCC should undergo a total colectomy if cancer is suspected.

Mutations in the K-Ras oncogene are associated with greater than 90% of pancreatic cancer. This is currently thought to be a sporadic mutation, and occurs early in the accumulation of gene mutations resulting in the progression toward pancreatic adenocarcinoma, but is not associated with colorectal cancer. Mutations in the tumor suppressor gene APC are associated with the autosomal dominant disorder familial adenomatous polyposis (FAP). In contrast to HNPCC, these patients have hundreds to thousands of polyps present throughout the colon by 25 years of age, which manifest as cancers by 45 years of age. Polyps are small, and are concentrated in the left colon. Treatment of patients with FAP is usually total abdominal colectomy with mucosal proctectomy and ileoanal pull-through. Carrying the BRCA1 or BRCA2 gene mutation is associated with up to an 85% chance of developing breast cancer. Carriers of either mutation have an increased incidence of developing ovarian cancer; however, currently only the BRCA2 mutation is associated with an increased incidence of male breast cancer.

References:

Boland CR, Bresalier RS. Colonic polyps and polyposis syndromes. In: Mulholland MW, Lillemoe KD, Doherty GM, Maier RV, Upchurch GR, eds. *Greenfield's Surgery: Scientific Principles & Practice.* 5th ed. Philadelphia, PA: Lippincott Williams & Wilkins; 2011.

Hruban RH, Goggins M, Parsons J, et al. Progression model for pancreatic cancer. *Clin Cancer Res.* 2000;6(8):2969–2972.

Morris A. Colorectal cancer. In: Mulholland MW, Lillemoe KD, Doherty GM, Maier RV, Upchurch GR, eds. *Greenfield's Surgery: Scientific Principles & Practice.* 5th ed. Philadelphia, PA: Lippincott Williams & Wilkins; 2011.

۰۲۱-۶۶۱۹۸۵۱۴ www.myuptodate.com دریافت آخرین نسخه آپتودیت آفلاین

Comparison of Clinical Criteria for Hereditary Nonpolyposis Colorectal Cancer (HNPCC)[a]

	Criteria	Sensitivity	Specificity	Strengths	Weaknesses
Amsterdam	Three relatives with colorectal cancer, meeting all of the following criteria: (i) one of whom is a first-degree relative of the other two; (ii) colorectal cancer in at least two generations; (iii) one or more colorectal cancer cases diagnosed before age 50 years	61%	67%	Easy to remember and apply; good specificity	Limited sensitivity
Amsterdam II	Three relatives with HNPCC-associated cancer,[b] meeting all of the following criteria: (i) one of whom is a first-degree relative of the other two; (ii) colorectal cancer in at least two generations; (iii) one or more colorectal cancer cases diagnosed before age 50 years	78%	61%	Easy to remember and, apply; good specificity	Improved but limited sensitivity
Bethesda Guidelines	Meeting any of the following criteria:[c] (i) subjects with cancer in families that fulfill Amsterdam criteria; (ii) subjects with two HNPCC-related cancers; (iii) subjects with colorectal cancer and a first-degree relative with HNPCC-related cancer and/or colorectal adenoma; one of the cancers diagnosed at age <45 years and the adenoma diagnosed at age <40 years	94%	49%	Increased sensitivity	Complexity in the clinical setting
Revised Bethesda Guidelines	Meeting any of the following criteria: (i) colorectal cancer diagnosed in a patient younger than age 50 years; (ii) presence of synchronous or metachronous HNPCC-associated tumors, regardless of age; (iii) colorectal cancer with microsatellite instability high histology in a patient younger than age 60 years; (iv) colorectal cancer in one or more first-degree relatives with an HNPCC-related tumor, with one of the cancers diagnosed at age younger than 50 years; or (v) colorectal cancer diagnosed in two or more first- or second-degree relatives with HNPCC-associated tumors, regardless of age			Easier to apply in the clinical setting	Due to recent development, limited data regarding test

[a]After exclusion of familial adenomatous polyposis.

[b]HNPCC-associated cancers are colorectal, endometrial, ovarian, stomach, small intestine, biliary tract, ureter, renal pelvis, and brain cancers, and sebaceous gland adenomas and keratoacanthomas in Muir-Torre syndrome.

[c]Four additional original Bethesda criteria did not increase the sensitivity, but their inclusion decreased the specificity to 25%: (iv) Subjects with colorectal cancer or endometrial cancer at age <45 years; (v) subjects with right-sided colorectal cancer with an undifferentiated histopathologic pattern diagnosed at age <45 years; (vi) subjects with signet-ring cell type colorectal cancer diagnosed at age <45 years; (vii) subjects with adenomas diagnosed at age <40 years.

Reprinted with permission from: Morris A. Colorectal cancer. In: Mulholland MW, Lillemoe KD, Doherty GM, Maier RV, Upchurch GR, eds. *Greenfield's Surgery: Scientific Principles & Practice.* 5th ed. Philadelphia, PA: Lippincott Williams & Wilkins, 2011:1095.

۰۲۱-۶۶۱۹۸۵۱۴ www.myuptodate.com دریافت آخرین نسخه آپتودیت آفلاین

1B03

Key word: Treatment of Umbilical Hernia with Ascites

Author: Susanna M. Nazarian, MD, PhD
Editor: Frederick E. Eckhauser, MD, FACS

A 70-year-old man with ascites secondary to cirrhosis presents for elective umbilical hernia repair. Should he be offered repair of his hernia?

(A) No, he should not be offered repair
(B) Yes, if he had a recent myocardial infarction
(C) Yes, if he is leaking ascites from the hernia
(D) Yes, if he is listed for liver transplant
(E) Yes, if it is significantly affecting his lifestyle

Answer: (C) Yes, if he is leaking ascites from the hernia

Rationale:
The repair of umbilical hernias in patients with cirrhosis is associated with a high rate of recurrence secondary to the production of ascites and nutritional deficiencies resulting in muscular wasting and fascial thinning. Up to 20% of patients with cirrhosis develop a hernia of the anterior abdominal wall. Surgery on these patients is complicated by the risk of hemorrhage secondary to variceal disruption, peritonitis, postoperative ascites leak, and hepatic decompensation. Therefore, such a surgical undertaking should be considered only in select patients. One indication includes those patients leaking ascites, therefore, placing them at higher risk of peritonitis.

It is of utmost importance to minimize ascites preoperatively. Repair of an umbilical hernia without adequate control of ascites preoperatively contributes to a 73% recurrence rate. Medical control of ascites entails fluid and salt restriction, diuretics, and possibly paracentesis. Transjugular intrahepatic portosystemic shunt (TIPS) may be used preoperatively to reduce the production of ascites.

Reference:
Marvin MR, Edmond JC. Cirrhosis and portal hypertension. In: Mulholland MW, Lillemoe KD, Doherty GM, Maier RV, Upchurch GR, eds. *Greenfield's Surgery: Scientific Principles & Practice.* 5th ed. Philadelphia, PA: Lippincott Williams and Wilkins; 2011.

1B04

Key word: Characteristics of NSQIP

Author: Eric S. Weiss, MD, MPH
Editor: Dorry L. Segev, MD, PhD

The fundamental goal of the American College of Surgeons National Surgical Quality Improvement Program (NSQIP) is:

(A) To collect outcome data to measure and improve surgical care outcomes
(B) To identify those surgeons who deliver excellent surgical care
(C) To improve health care in underserved US populations
(D) To model systems for improved use of health care resources
(E) To monitor surgical costs in order to allocate health care

Answer: (A) To collect outcome data to measure and improve surgical care outcomes

Rationale:
The American College of Surgeons designed NSQIP to improve surgical quality in the United States. This validated, outcome-based program allows comparisons between hospitals to affect improvement. The program was first used in the Veterans Health Administration (VA) in the 1990s. Operative morbidity and mortality were collected and compared across VA hospitals. With the implementation of this program, morbidity has decreased by 45% and mortality has decreased by 27% in the VA system. There are currently many participating non-VA hospitals and the NSQIP helps pinpoint areas of improvement in individual hospitals and in surgical programs as a whole.

Reference:
Rowell KS, Turrentine FE, Hutter MM, et al. Use of national surgical quality improvement program data as a catalyst for quality improvement. *J Am Coll Surg.* 2007; 204(6):1293–1300.

۰۲۱-۶۶۱۹۸۵۱۴ www.myuptodate.com دریافت آخرین نسخه آپتودیت آفلاین

1B05

Key word: Diagnosis of Lymphocele in Deceased Donor Kidney Transplant

Author: Robert A. Meguid, MD, MPH
Editors: Robert A. Montgomery, MD, DPhil, FACS, and Dorry L. Segev, MD, PhD

Four weeks after a deceased donor kidney transplant, the recipient returns to the emergency department with bilateral lower-extremity edema. In spite of normal fluid intake, he reports that he has had minimal urine output over the past 18 hours. Serum creatinine is now elevated to 1.4 mg/dL from 1.0 mg/dL postoperatively. After failure to respond to a fluid challenge, an ultrasound is obtained. This reveals good perfusion, minimal hydronephrosis, and a 3- × 4- × 6-cm hypoechoic mass adjacent to the renal pelvis of the allograft. What is the most likely cause of the patient's oliguria?

(A) Compressive hematoma
(B) Lymphocele formation
(C) Renal artery stenosis
(D) Renal artery thrombosis
(E) Ureteroneocystostomy stenosis

Answer: (B) Lymphocele formation

Rationale:
The most common cause of urinary obstruction from extrinsic compression of the ureter at this point after a transplant is a lymphocele. The lymphocele forms in the retroperitoneal space at the iliac fossa developed for the implantation of the allograft, due to disruption of the tiny lymphatics that surround the recipient's external iliac artery and vein, and the inability of this space to absorb lymph (as opposed to, e.g., the peritoneal cavity). Postoperatively, as lymph collects in the perinephric space, pressure is exerted on the ureter, resulting in obstruction. Clinically this manifests as decreased urine output. Ultrasound reveals the offending fluid collection as a hypoechoic mass with accompanying hydronephrosis. Percutaneous drainage may be attempted and, if unsuccessful, creation of a peritoneal window laparoscopically is the preferred treatment.

Ureteroneocystostomy stenosis, or stenosis at the ureterovesical anastomosis, is a technical complication that occurs early in the postoperative course. To minimize the likelihood of this occurring, a stent may be placed intraoperatively through the anastomosis. Hydronephrosis would be expected, but no fluid collection.

Vascular compromise usually occurs within the first few hours to days after a kidney transplant. Events leading to this include renal artery or vein thrombosis, arterial dissection, and pseudoaneurysm formation. Hemorrhage, possibly from one of the vascular anastomoses, can result in pooling of blood around the ureter and subsequent obstruction, but this is almost always a very early complication.

Renal artery stenosis usually occurs months to years after transplantation, and presents with oliguria, hypertension, and rising serum creatinine levels.

References:
Fischer AC. Transplant immunology and solid organ transplantation. In: Fleischer KJ, ed. *Advanced Surgical Recall.* Philadelphia, PA: Lippincott Williams & Wilkins; 1995: 1150.

Freise C, Stock P. Renal transplantation. In: Mulholland MW, Lillemoe KD, Doherty GM, Maier RV, Upchurch GR, eds. *Greenfield's Surgery: Scientific Principles & Practice.* 5th ed. Philadelphia, PA: Lippincott Williams & Wilkins; 2011.

۰۲۱-۶۶۱۹۸۵۱۴ www.myuptodate.com دریافت آخرین نسخه آپتودیت آفلاین

1B06

Key word: Treatment of CO_2 Embolus during Laparoscopic Cholecystectomy

Author: Robert A. Meguid, MD, MPH
Editors: Thomas H. Magnuson, MD, and Kenzo Hirose, MD, FACS

While visualizing the gallbladder during an elective laparoscopic cholecystectomy, the anesthesiologist informs you that the patient has a heart rate of 130, and a dropping blood pressure. What is the *FIRST* step in management?

(A) Decrease insufflation pressure
(B) Give inotropes for blood pressure
(C) Give IV fluids
(D) Position the patient in the left lateral decubitus position
(E) Stop insufflation

Answer: (E) Stop insufflation

Rationale:
Tachycardia and hypotension shortly after insufflation for laparoscopy can be related to decreased venous return to the right heart, tension pneumothorax, or CO_2 embolism. The first step is to stop insufflation and immediately release the pneumoperitoneum.

In the event of a gas embolus, examination of the patient will reveal a "mill wheel" murmur due to air bubbling in the right ventricle, as well as jugular venous distention and hypoxemia. A tension pneumothorax is indicated by tracheal deviation and absence of breath sounds unilaterally will be present. If visible, the diaphragm may be bulging into the peritoneal space.

Further treatment of gas embolism involves positioning the patient in the left lateral decubitus position to limit the gas bubbles to the right atrium and ventricle, hyperventilation, and if present, using a central venous access to extract the gas via catheter.

Decreasing the insufflation pressure does not rectify the life-threatening problem, but will perpetuate it. Insufflation must be stopped immediately. Giving IV fluids, while appropriate when the cause of shock is relative hypovolemia, will not treat the cause of the problem in this example, nor the problem of a functional pulmonary artery or coronary artery obstruction itself. While giving inotropes may increase the blood pressure, it will not correct the life-threatening problem. Insufflation must be stopped immediately.

References:
Bayne S, Blackbourne LH. Laparoscopy. In: Fleischer KJ, ed. *Advanced Surgical Recall.* Philadelphia, PA: Lippincott Williams and Wilkins; 1995:315.

Moore FA, Moore EE. Trauma resuscitation. In: Souba WW, Fink MP, Jurkovich GJ, Kaiser LR, Pearce WH, Pemberton JH, Soper NJ, eds. *ACS Surgery: Principles and Practice,* 4th ed. New York, NY: WebMD; 2004:855–856.

1B07

Key word: Characteristics of Local Anesthetic Toxicity

Author: Robert A. Meguid, MD, MPH
Editor: Nicole M. Chandler, MD

A 26-year-old male is undergoing a nerve block for an outpatient orthopedic procedure on his left ankle. During injection of the superficial fibular nerve with lidocaine, he complains of tingling around his mouth and lips. What other symptom would be consistent with lidocaine toxicity?

(A) Hallucinations
(B) High fever
(C) Muscle rigidity
(D) Peripheral paralysis
(E) Skin ischemia

Answer: (A) Hallucinations

Rationale:
Local anesthetics are a class of drugs that produces effect by temporarily blocking nerve conduction by binding to neuronal sodium channels. The progression of action of local anesthetics on nerve function is as follows: Blockade of autonomic transmission, blockade of sensory transmission, and blockade of motor transmission.

The toxicity of local anesthetics is dependent on the site of injection and the rate of absorption. Inadvertent intravascular injection of a local anesthetic will produce signs of toxicity with much smaller doses. The progression of signs of local anesthesia toxicity and overdose are as follows: Perioral paresthesias, visual and auditory hallucinations, sedation, unconsciousness, seizures, respiratory depression, cardiac arrhythmias, and cardiovascular collapse. The best techniques to prevent toxicity from local anesthetics are to aspirate before injecting to avoid intravascular injection and knowledge of the maximal safe dose to be injected.

The maximum dose of lidocaine is 5 mg/kg of body weight, and increases to 7 mg/kg of body weight when epinephrine (1:100,000) is included in the formulation. The addition of epinephrine slows absorption as a result of vasoconstriction and also decreases the likelihood of toxicity, however, may induce local ischemia due to vasoconstriction. Bupivacaine's maximum dose is 2.5 mg/kg of body weight. Treatment of lidocaine toxicity includes supportive measures such as oxygen therapy and airway support and treatment of seizures if necessary. Cardiac toxicity may require inotropic and chronotropic agents or in extreme cases, temporary cardiopulmonary bypass. Cardiovascular toxicity from bupivacaine may be particularly difficult to treat.

۰۲۱-۶۶۱۹۸۵۱۴ www.myuptodate.com دریافت آخرین نسخه آپتودیت آفلاین

Local Anesthetics

	Maximum Single Dose (mg)	Duration (h)	Comments
Amides			
Lidocaine	500	1[a]	Fast onset
Ropivacaine	200	4–12[a]	Less cardiac toxicity than bupivacaine
Bupivacaine	200	4–12[a]	Exaggerated cardiotoxicity with IV injection Slow onset Long duration
Esters[b]			
2-Chloroprocaine	1,000	0.5–1[a]	Fast onset Lowest toxicity
Tetracaine	80	0.5–1	Slow onset

IV, intravenous.

[a]Addition of 100 µg of epinephrine (0.1 mL of 1:1,000) lowers the toxicity and increases the duration of the local anesthetic.

[b]Metabolism to paraaminobenzoic acid may cause allergic reactions.

Reprinted with permission from: Kheterpal S, Rutter TW, Tremper KK. Anesthesiology and pain management. In: Mulholland MW, Lillemoe KD, Doherty GM, Maier RV, Upchurch GR, eds. *Greenfield's Surgery: Scientific Principles & Practice*. 5th ed. Philadelphia, PA: Lippincott Williams & Wilkins, 2011:243.

References:

Kheterpal S, Rutter TW, Tremper KK. Anesthesiology and pain management. In: Mulholland MW, Lillemoe KD, Doherty GM, Maier RV, Upchurch GR, eds. *Greenfield's Surgery: Scientific Principles & Practice.* 5th ed. Philadelphia, PA: Lippincott Williams & Wilkins; 2011.

Sherwood ER, Williams CG, Prough DS. Chapter 16: Anesthesiology principles, pain management, and conscious sedation. In: Townsend CM, Beauchamp RD, Evers BM, Mattox KL, eds. *Sabiston Textbook of Surgery: The Basis of Modern Surgical Practice.* 19th ed. Philadelphia, PA: Saunders; 2012:389–417.

۰۲۱-۶۶۱۹۸۵۱۴ www.myuptodate.com دریافت آخرین نسخه آپتودیت آفلاین

1B08

Key word: Etiology of Recurrence in Laparoscopic Hernia Repair

Author: Susanna M. Nazarian, MD, PhD
Editor: Frederick E. Eckhauser, MD, FACS

An obese woman who underwent a transabdominal hysterectomy 10 years ago presents for an elective ventral hernia repair. She undergoes hernia repair via a laparoscopic approach, to which she responds well initially. However, she develops a recurrent bulge 2 months later and presents to your office for counseling. What is the most common reason for recurrence after laparoscopic ventral hernia repair?

(A) Failure of suture material or tacks
(B) Inadequate dissection of the fascial defect
(C) Separation of the mesh from the abdominal wall
(D) Seroma formation
(E) Unrecognized defect

Answer: (C) Separation of the mesh from the abdominal wall

Rationale:
Incisional abdominal hernias are attributed to poor technique, rough handling of tissues, closure of the wound under tension, and infection. In addition, patient comorbidities such as obesity, smoking, nutritional deficiencies, and pulmonary disease have been identified as contributing causes.

In a study of 121 laparoscopic hernia repairs published in 2005, Perrone and colleagues found a hernia recurrence rate of 9.3%. They concluded that the most common etiology of recurrence was separation of mesh from the posterior abdominal fascia, thereby allowing the intestine to interpose between the mesh and the wall. Some techniques employed to combat this problem include ensuring adequate mesh overlap of a defect, fixation of mesh, and adequate dissection. Although seroma is the most common complication following laparoscopic ventral hernia repair, it does not necessarily contribute to recurrence. The laparoscopic approach is well suited to patients with a "Swiss cheese" abdomen as small fascial defects are more likely to be recognized with the superior visualization. A more recent pooled data analysis of all English-language reports on laparoscopic ventral hernia repair from 1996 to 2006 measured the hernia recurrence rate for laparoscopic rates at 4.3%.

References:
Fitzgibbons RJ, Cemaj S, Quinn TH. Abdominal wall hernias. In: Mulholland MW, Lillemoe KD, Doherty GM, Maier RV, Upchurch GR, eds. *Greenfield's Surgery: Scientific Principles & Practice.* 5th ed. Philadelphia, PA: Lippincott Williams & Wilkins; 2011.

Perrone JM, Soper NJ, Eagon JC, et al. Perioperative outcomes and complications of laparoscopic ventral hernia repair. *Surgery.* 2005;138(4):708–715.

Pierce RA, Spitler JA, Frisella MM, et al. Pooled data analysis of laparoscopic vs. open ventral hernia repair: 14 years of patient data accrual. *Surg Endosc.* 2007;21(3):378–386.

1B09

Key word: Tetanus Prophylaxis

Author: Robert A. Meguid, MD, MPH
Editor: Nicole M. Chandler, MD

A 21-year-old male is brought to the trauma bay after sustaining a superficial stab wound to the left shoulder. He reports that he received his full series of shots as a child and received his last tetanus booster shot when he was 15. What should he receive for his tetanus prophylaxis?

(A) Amoxicillin 500-mg PO TID
(B) Nothing
(C) Tetanus immune globulin (TIG) 250-units IM
(D) Tetanus toxoid (dT) 0.5-mL IM
(E) Tetanus toxoid (dT) 0.5-mL IM and TIG 250-units IM

Answer: (D) Tetanus toxoid (dT) 0.5-mL IM

Rationale:
Active tetanus immunization is obtained by administration of three doses of tetanus toxoid, given at age 2, 4, and 6 months, followed by two additional doses ("boosters") of tetanus toxoid, given at age 1 and 5 years. Subsequent "booster" doses of tetanus toxoid are given at 10-year intervals for life. The Center for Disease Control recently provided new recommendations for tetanus prophylaxis, principally because of outbreaks of pertussis. As of 2005, there are two tetanus/diphtheria/acellular pertussis vaccines (Tdap) available for adolescents, one of which is available for adults as well. The CDC-based Advisory Committee on Immunization Practices (ACIP) now recommends that adolescents receive a one-time boost of Tdap for booster immunization rather than Td for booster immunization if they have completed the DTP/DTaP vaccination series and have not yet received their booster. The preferred age for Tdap vaccination is 11 to 12 years.

Passive TIG provides protective levels of antibodies for 3 to 4 weeks and the adult dose is 250-units IM. Tetanus toxoid (dT) 0.5-mL IM is the standard booster.

Natural immunity to tetanus does not occur in the United States. Forty percent of cases of tetanus are not associated with any history of injury, and the mortality rate is 20% to 40%. Universal recommendations from the CDC for tetanus prophylaxis depend on the wound characteristics and the patient's immunization status. Characteristics of tetanus-prone wounds include penetrating injuries greater than 1 cm in depth, wounds greater than 6 hours old, contaminated or infected wounds, and ischemic or denervated injuries.

The principles for tetanus prophylaxis of the acute wound are as follows.

- For patients with acute soft tissue injuries (regardless of suspicion for tetanus) who have not been immunized, a tetanus toxoid booster is required, along with follow-up to complete the series.
- For patients with a tetanus-prone wound who have not completed a primary immune series, administer TIG 250 units.

۰۲۱-۶۶۱۹۸۵۱۴ www.myuptodate.com دریافت آخرین نسخه آپتودیت آفلاین

- For patients who have completed a primary immune series, a booster is given if the last dose was >5 years prior (for tetanus-prone wound) or >10 years prior (for a nontetanus-prone wound).
- Patients with a contraindication to tetanus toxoid must be managed with TIG alone.

Tetanus Prophylaxis of Acute Wounds

	Nontetanus-prone Wounds	Tetanus-prone Wounds	
Primary immunization:	Td	Td	TIG
Not complete	Yes	Yes	Yes
Completed <5 yrs	No	No	No
Last booster >5 yrs	No	Yes	No
Last booster >10 yrs	Yes	Yes	No

Therefore, the correct answer is "tetanus toxoid (dT) 0.5-mL IM" as the patient has completed his primary immunizations and received his last booster 6 years ago.

References:

Adams CA, Heffernan DS, Cioffi WG. Chapter 47: Wounds, bites, and stings. In: Mattox KL, Moore EE, Feliciano DV, eds. *Trauma.* 7th ed. New York, NY: McGraw-Hill; 2013. http://www.accesssurgery.com/content.aspx?aID=56897521. Accessed March 20, 2013.

Centers for Disease Control and Prevention. Recommendations for postexposure interventions to prevent infection with hepatitis B virus, hepatitis C virus, or human immunodeficiency virus, and tetanus in persons wounded during bombings and similar mass-casualty events—United States, 2008. MMWR 2008; 57 (No. RR-6).

Howdieshell TR, Heffernan D, Dipiro JT, et al. Surgical infection society guidelines for vaccination after traumatic injury. *Surg Infect.* 2006;7(3):275–303.

1B10

Key word: Difference in ARDS versus Ventilator-associated Pneumonia

Authors: Justin B. Maxhimer, MD, and Susanna M. Nazarian, MD, PhD
Editor: Elliott R. Haut, MD, FACS

A 56-year-old male is ventilator dependent due to an open abdomen secondary to trauma. On the third day following his injury, he develops hypoxemia and tachypnea requiring an increase of the fraction of inspired oxygen (FiO_2) and positive end-expiratory pressure (PEEP). His partial pressure of oxygen in arterial blood (PaO_2) increases minimally with these changes. Plain chest radiograph shows bilateral infiltrates and pulmonary artery occlusion pressure is 16 mm Hg. Which combination of features would support a diagnosis of acute respiratory distress syndrome (ARDS) over ventilator-associated pneumonia (VAP)?

(A) PaO_2/FiO_2 ratio <200 mm Hg

(B) Pulmonary artery occlusion pressure ≥18 mm Hg

(C) Temperature 38.3°C, WBC = 12, minimal pleural effusion, increased protein on bronchoalveolar lavage (BAL), infiltrates not seen on chest radiograph

(D) Temperature 38.5°C, WBC = 16, no effusions, increased protein on BAL

(E) Temperature 38.7°C, WBC = 14, pleural effusions, increased protein on BAL

Answer: (D) Temperature 38.5°C, WBC = 16, no effusions, increased protein on BAL

Rationale:

ARDS is sudden, life-threatening lung failure. This diffuse inflammatory process leads to leaky capillaries and proteinaceous exudate accumulates in alveoli. The alveoli subsequently collapse and gas exchange ceases in the obliterated air spaces. Hypoxemia ensues requiring mechanical ventilation or some other form of assisted breathing. ARDS is a syndrome, not a specific disease, and a variety of underlying conditions can lead to the end-organ damage. Etiologies of ARDS range from trauma to sepsis, from burns to major surgery.

The initial lung injury of ARDS is poorly understood. Animal studies suggest that activated white blood cells and platelets accumulate in capillaries, the interstitium, and airspaces, leading to the release of prostaglandins, toxic O_2 radicals, proteolytic enzymes, and other mediators such as tumor necrosis factor and interleukins. These injure cells, promote inflammation and fibrosis, and alter bronchomotor tone and vasoreactivity.

Early diagnosis requires a high index of suspicion aroused by the onset of dyspnea in settings that predispose to ARDS. The American-European Consensus Committee developed the first consensus definition of ARDS in 1994, which was recently revised in 2011 to the Berlin Definition: (1) Onset within 1 week of a clinical insult or new or worsening respiratory symptoms, (2) bilateral opacities on CXR or CT not

۰۲۱-۶۶۱۹۸۵۱۴ www.myuptodate.com دریافت آخرین نسخه آپتودیت آفلاین

explained by effusions, lobar collapse, or nodules, (3) respiratory failure not explained by cardiac failure or fluid overload (can determine using PA catheter, echocardiography, etc.), (4) oxygenation difficulty as defined by PaO_2/FiO_2 ratio (with minimum PEEP 5 cm H_2O): 200 mm Hg < PaO_2/FiO_2 ≤300 mm Hg (mild), 100 mm Hg < PaO_2/FiO_2 ≤ 200 mm Hg (moderate), or 100 mm Hg < PaO_2/FiO_2. Of note, the term acute lung injury was removed from the definition.

It should be noted that these defining characteristics for ARDS diagnosis do not help in distinguishing it from VAP. Indeed, VAP may be the driving force behind the development of ARDS. Both ARDS and VAP patients may have PaO_2/FiO_2 ratio <300 mm Hg. A more reliable method for confirming ARDS is BAL. The BAL of ARDS patients is characterized by high neutrophil percentage (up to 80%) and large protein content. More specifically, a ratio of protein in BAL to that in serum >0.7 is consistent with ARDS. While BAL is more reliable in establishing a diagnosis of ARDS than the consensus diagnostic criteria, it is an invasive procedure that may temporarily further compromise the patient's respiratory status.

Answer **(B)** is an example of a patient who is more likely to have VAP. VAP is defined as nosocomial pneumonia in a patient on mechanical ventilatory support (by endotracheal tube or tracheostomy) for ≥48 hours. VAP is characterized by the appearance of a new or progressive pulmonary infiltrate and effusions, fever, leukocytosis, and purulent tracheobronchial secretions; however, these criteria are nonspecific. The patient in example **(D)** should be worked up for a pulmonary embolism.

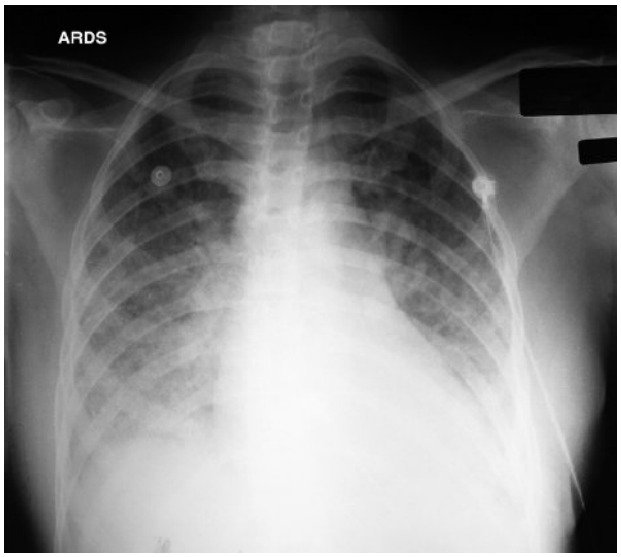

Upright portable chest x-ray from a patient with ARDS. The infiltrate appears to be homogeneous or equally distributed throughout both lower lung fields. Reprinted with permission from: Marino PL. Acute respiratory distress syndrome. *The ICU Book.* 3rd ed. Philadelphia, PA: Lippincott Williams & Wilkins; 2007:423.

Diagnostic Criteria for ALI and ARDS

1. Acute Onset
2. Presence of a predisposing condition.
3. Bilateral infiltrates on frontal chest x-ray.
4. PaO_2 / FiO_2 <200 mm Hg for ARDS, <300 mm Hg for ALI
5. Pulmonary artery occlusion pressure ≤18 mm Hg or no clinical evidence of left atrial hypertension.

ALI = acute lung injury, ARDS = acute respiratory distress syndrome.

Reprinted with permission from: Marino PL. Acute respiratory distress syndrome. *The ICU Book.* 3rd ed. Philadelphia, PA: Lippincott Williams & Wilkins, 2007:423.

References:

ARDS Definition Task Force, Ranieri VM, Rubenfeld GD, et al. Acute respiratory distress syndrome: The Berlin definition. *JAMA.* 2012;307(23):2526–2533.

Bernard GR, Artigas A, Brigham KL, et al. Report of the American-European Consensus conference on acute respiratory distress syndrome: Definitions, mechanisms, relevant outcomes, and clinical trial coordination. *J Crit Care.* 1994;9(1):72–81.

Marino PL. "Acute respiratory distress syndrome" and "Principles of mechanical ventilation." *The ICU Book.* 3rd ed. Philadelphia, PA: Lippincott Williams and Wilkins; 2007: 419–471.

Markowicz P, Wolff M, Djedaïni K, et al. Multicenter prospective study of ventilator-associated pneumonia during acute respiratory distress syndrome. Incidence, prognosis, and risk factors ARDS Study Group. *Am J Respir Crit Care Med.* 2000;161(6):1942–1948.

Mayhall CG. Ventilator-associated pneumonia or not? Contemporary diagnosis. *Emerg Infect Dis.* 2001;7(2):200–204.

۰۲۱-۶۶۱۹۸۵۱۴ www.myuptodate.com دریافت آخرین نسخه آپتودیت آفلاین

1B11

Key word: Treatment of Incarcerated Inguinal Hernia

Author: Justin B. Maxhimer, MD
Editor: Frederick E. Eckhauser, MD, FACS

A 2-year-old boy is brought to the emergency department by his mother. She reports that he has been inconsolable for the past 24 hours and has refused his feeds. Upon further questioning, the physician finds that the child has vomited twice and has not had a bowel movement. Examination reveals a slightly distended and diffusely tender abdomen, especially in the inguinal area, without signs of peritonitis. What should be your first step?

(A) Arrange for immediate groin exploration in the operating room without attempting manual reduction

(B) Elevation of the child's lower extremities with a pillow, followed by an attempt at manual reduction

(C) Emergent exploratory laparotomy

(D) Apply ice pack to the affected area

(E) Overnight inpatient observation

Answer: (B) Elevation of the child's lower extremities with a pillow, followed by an attempt at manual reduction

Rationale:

Most children with an inguinal hernia present with a history of intermittent swelling in the inguinal region, which in boys, may extend to the scrotum. The presence of a mass or thickening in the inguinal canal or at the level of the internal inguinal ring is diagnostic of an inguinal hernia. The swelling is usually nontender and readily reducible with gentle pressure.

Most inguinal hernia repairs in full-term healthy infants and older children may be performed electively in an outpatient surgical setting. Infants less than 6 to 12 months of age, particularly former premature babies, are at greater risk for incarceration. Repair in these babies should be carried out as soon as convenient, and preferably within 1 week of the diagnosis. An overnight hospitalization after surgery may be necessary for postoperative apnea monitoring in these former premature babies and infants under 6 to 12 months of age as well as other children with special needs (a group which includes those with ventriculo-peritoneal shunts, cardiopulmonary disease, etc.).

A hernia is considered incarcerated when the contents of the hernia sac are trapped in the inguinal canal and cannot be easily reduced into the abdominal cavity. Incarceration of an inguinal hernia is most common in the first year of life. The incidence falls with age, but never disappears entirely and must be considered with hernias at any age. An incarcerated hernia usually presents as a firm swelling in the inguinal region (possibly extending to the scrotum) that is tender to palpation and does not readily reduce with pressure. The child may be extremely irritable and unwilling to eat. Intestinal obstruction, with abdominal distention and vomiting, may be present. The differential diagnosis includes inguinal lymphadenitis, torsion of the testicle, and acute hydrocele. Even with an incarcerated hernia, the affected groin may become edematous and a reactive hydrocele may evolve.

Elevation of the child's legs can help encourage spontaneous reduction but is just a temporizing maneuver. Ice packs should be avoided in both infants and children. Reduction of an incarcerated hernia should be attempted and can be achieved in the majority of cases. Sedation (with a short-acting benzodiazepine or opiate narcotic) and firm, steady pressure over the hernia (for several minutes and up to half an hour) may be necessary. If reduction is successful, the child should be admitted to the hospital and surgical correction planned for 24 to 48 hours later (when some of the initial edema has resolved). The patient should not be discharged since the risk of recurrence is very high. If signs of strangulation are present, no attempt at reduction should be made, and emergency surgical intervention should be undertaken. Under these circumstances, resection of a segment of ischemic bowel may be necessary.

Reference:

Sato TT, Oldham KT. Pediatric abdomen. In: Mulholland MW, Lillemoe KD, Doherty GM, Maier RV, Upchurch GR, eds. *Greenfield's Surgery: Scientific Principles & Practice.* 5th ed. Philadelphia, PA: Lippincott Williams & Wilkins; 2011.

۰۲۱-۶۶۱۹۸۵۱۴ www.myuptodate.com دریافت آخرین نسخه آپتودیت آفلاین

1B12

Key word: Etiology of Hyponatremia in Pancreatitis

Author: Susanna M. Nazarian, MD, PhD
Editor: Martin A. Makary, MD, MPH

A 45-year-old woman with a history of gallstones is admitted to the intensive care unit after diagnosis with acute pancreatitis with hemodynamic instability. Her admission laboratory values were remarkable for a number of abnormalities, including hyponatremia, hyperamylasemia, hyperlipasemia, and hyperlipidemia. What is the etiology of hyponatremia in pancreatitis?

(A) Hypoalbuminemia
(B) Pseudohyponatremia
(C) Renal failure
(D) Salt wasting
(E) Syndrome of inappropriate antidiuretic hormone (SIADH)

Answer: (B) Pseudohyponatremia

Rationale:
Pseudohyponatremia in pancreatitis derives from the method of sodium measurement. In pancreatitis with hyperlipidemia, circulating lipids draw water into the intravascular compartment, leading to relative hyponatremia. Plasma exchange can be used to remove lipids from the circulation. Aggressive overcorrection of pseudohyponatremia with hyperosmolar fluids can lead to dangerous electrolyte disturbances.

Patients with acute pancreatitis are subject to numerous other disturbances in their laboratory values. The primary pancreatic enzymes of amylase and lipase are increased three times higher than baseline, although amylase levels may return to baseline within 3 to 5 days given its short half-life. Patients with gallstones as the etiology of their disease may have laboratory values reflecting inflammation or obstruction of the biliary tract. Hypercalcemia is a source of pancreatitis, while hypocalcemia can result from the action of leaking pancreatic enzymes during an attack of pancreatitis.

References:
Gold JS, Whang EE. Acute pancreatitis. In: Mulholland MW, Lillemoe KD, Doherty GM, Maier RV, Upchurch GR, eds. *Greenfield's Surgery: Scientific Principles & Practice.* 5th ed. Philadelphia, PA: Lippincott Williams & Wilkins; 2011.
Howard JM, Reed J. Pseudohyponatremia in acute hyperlipemic pancreatitis. A potential pitfall in therapy. *Arch Surg.* 1985;120(9):1053–1055.

1B13

Key word: Treatment of Hypotension after Removal of Pheochromocytoma

Author: Robert A. Meguid, MD, MPH
Editor: Frederick E. Eckhauser, MD, FACS

A 42-year-old woman is in the intensive care unit immediately following removal of a left adrenal pheochromocytoma. Her blood pressure is 80/40 mm Hg. The most appropriate treatment of the patient's hypotension is:

(A) Epinephrine
(B) IV bolus of lactated Ringer solution
(C) Methylprednisolone
(D) Phenoxybenzamine
(E) Phenylephrine

Answer: (B) IV bolus of lactated Ringer solution

Rationale:
Hypotension after removal of a pheochromocytoma is due to hypovolemia. This should have been prevented by appropriate fluid resuscitation prior to operation. Occurring postoperatively, it is most appropriately treated with aggressive IV fluid administration.

Patients with pheochromocytomas are hypertensive, with increased vasomotor tone, and prone to cardiac arrhythmias. Preoperative preparation of patients with pheochromocytomas begins with α-adrenergic blockade 1 to 3 weeks prior to surgery. Phenoxybenzamine is the preferred long-acting agent. In conjunction with this pharmacologic treatment, fluid resuscitation should be given to fill the re-expanding vascular compartment. Typically patients should gain significant weight (fluid) during this period of preoperative preparation, and failure to do so may foreshadow postoperative hypotension. Once α-adrenergic blockade has been achieved (as measured by normal orthostatic changes in blood pressure), β-adrenergic blockade should be initiated. This is achieved with propranolol, started 48 hours prior to surgery. Of note, β-adrenergic blockade should never be instituted prior to adequate α-adrenergic blockade and fluid resuscitation, as the ensuing unopposed α-adrenergic activity may result in worsened vasoconstriction leading to myocardial infarction, hypertensive crisis, or pulmonary edema.

Treatment of the hypotensive patient status post removal of pheochromocytoma with phenoxybenzamine will result in further vasodilation and will worsen hypotension. While epinephrine and phenylephrine may ameliorate this patient's hypotension transiently, neither of them will treat the underlying cause—namely hypovolemia. Phenylephrine is a dedicated α_1-agonist, while epinephrine acts on α_1-, β_1-, and β_2-adrenergic receptors.

As with any other operation, bleeding must be considered as the cause of hypotension following pheochromocytoma removal.

۰۲۱-۶۶۱۹۸۵۱۴ www.myuptodate.com دریافت آخرین نسخه آپتودیت آفلاین

References:
Hodgett S, Brunt LM. Adrenalectomy. In: Cance WG, Jurkovich GJ, Napolitano LM, eds. *ACS Surgery: Principles and Practice.* New York, NY: WebMD; 2011.
Silberfein E, Perrier ND. Management of pheochromocytomas. In: Cameron JL, ed. *Current Surgical Therapy.* 10th ed. Philadelphia, PA: Mosby; 2011:579–584.

1B14

Key word: Initial IV Fluid in Treatment of Dehydration

Author: Nikiforos Ballian, MBBS
Editor: Nicole M. Chandler, MD

A 7-week-old boy is referred with a 3-day history of projectile nonbilious vomiting. He appears dehydrated and, on abdominal examination, an olive-shaped epigastric mass is palpable. The most appropriate initial IV fluid regimen for resuscitation is:

(A) 2% sodium chloride
(B) 5% dextrose
(C) Lactated Ringer
(D) Normal saline
(E) Normal saline + 20-mmol/L potassium chloride

Answer: (D) Normal saline

Rationale:
Hypertrophic pyloric stenosis (HPS) occurs in 2 to 4 per 1,000 live births and is more common in males. It is characterized by thickening of the pyloric smooth muscle, which is palpable as an abdominal "olive-like" mass, pathognomonic for this condition. HPS presents between 2 and 12 weeks of age with projectile nonbilious vomiting that leads to dehydration with hyponatremia, hypokalemia, hypochloremia, and metabolic alkalosis.

Preoperative correction of dehydration and electrolyte deficits is critical. Normal saline should be used without added potassium until an adequate urine output has been restored, to prevent rapid changes in serum potassium. Hypotonic solutions such as 5% dextrose should never be used to correct dehydration in children as they can cause lethal hyponatremia. There is no role for lactated Ringer in resuscitating alkalotic chloride-depleted patients. Hypertonic sodium chloride is used to correct severe symptomatic hyponatremia and/or for rapid expansion intravascular volume. Initial resuscitation with normal saline is the most appropriate option to address the fluid and electrolyte deficiencies of HPS patients.

References:
Aspelund G, Langer JC. Current management of hypertrophic pyloric stenosis. *Semin Pediatr Surg.* 2007;16(1):27–33.
Jackson J, Bolte RG. Risks of intravenous administration of hypotonic fluids for pediatric patients in ED and prehospital settings: Let's remove the handle from the pump. *Am J Emerg Med.* 2000;18(3):269–270.
Miozzari HH, Tonz M, von Vigier RO, et al. Fluid resuscitation in infantile hypertrophic pyloric stenosis. *Acta Paediatr.* 2001;90(5):511–514.
To T, Wajja A, Wales PW, et al. Population demographic indicators associated with incidence of pyloric stenosis. *Arch Pediatr Adolesc Med.* 2005;159(6):520–525.
Warner BW. Pediatric surgery. In: Townsend CM, Beauchamp RD, Evers BM, Mattox KL, eds. *Sabiston Textbook of Surgery.* 17th ed. Philadelphia, PA: Saunders; 2004:2097–2134.

۰۲۱-۶۶۱۹۸۵۱۴ www.myuptodate.com دریافت آخرین نسخه آپتودیت آفلاین

1B15

Key word: Diagnosis of Thrombosis of Hepatic Artery after Liver Transplantation

Author: Robert A. Meguid, MD, MPH
Editor: Andrew M. Cameron, MD, PhD

A 45-year-old female is in the SICU 2 days postoperative from an orthotopic liver transplant for primary biliary cirrhosis. The patient's condition has rapidly deteriorated, with signs consistent with fulminant hepatic failure. Ultrasound of the graft is most likely to reveal which of the following?

(A) Hepatic artery thrombosis
(B) Hepatic vein thrombosis
(C) Inferior vena cava stenosis
(D) Portal vein stenosis
(E) Portal vein thrombosis

Answer: (A) Hepatic artery thrombosis

Rationale:

Hepatic artery thrombosis can occur early in the postoperative period. This is manifested as fulminant hepatic failure; treatment is retransplantation. Delayed hepatic artery thrombosis can result in necrosis of the bile duct, as the biliary anastomosis receives its blood supply from the hepatic artery.

Less common than hepatic artery thrombosis, portal vein thrombosis presents with liver dysfunction in the immediate postoperative period. Treatment is reoperation with thrombectomy. Delay in the development of portal vein thrombosis or stenosis results in portal venous hypertension. Symptoms include ascites, variceal bleeding, and splenomegaly. Treatment of thrombosis is operative; however, stenosis may be treated with angioplasty.

Even more uncommon, hepatic vein thrombosis and IVC stenosis may result in Budd–Chiari syndrome. Again, operative treatment is indicated. IVC stenosis may occasionally be dilated and stented.

References:

Crawford JM. The liver and the biliary tract. In: Cotran RS, Kumar V, Collins T, eds. *Robbins Pathologic Basis of Disease.* 6th ed. Philadelphia, PA: W.B. Saunders. 1999: 883–884.

Martin P, Rosen HR. Liver transplantation. In: Feldman M, Friedman LS, Brandt LJ, eds. *Sleisenger and Fordtran's Gastrointestinal and Liver Disease.* 8th ed. Philadelphia, PA: Saunders Elsevier; 2006. Online Edition.

1B16

Key word: Diagnostic Test for Soft Tissue Sarcoma of the Thigh

Authors: Robert A. Meguid, MD, MPH, and Susanna M. Nazarian, MD, PhD
Editor: Frank J. Frassica, MD

A 55-year-old man presents with a firm mass on his left thigh, which he noticed recently after bumping into a chair. The mass is painless, not discolored, and 5 cm in diameter. What is the next diagnostic test you should perform?

(A) Excisional biopsy
(B) Fine-needle aspiration
(C) Incisional biopsy
(D) Magnetic resonance imaging (MRI) scan
(E) Wide excision with 2-cm margins

Answer: (D) Magnetic resonance imaging (MRI) scan

Rationale:

The lesion of concern for an extremity mass is a soft tissue sarcoma. The area most commonly involved by sarcomas is the thigh. While there is no correlation of development of soft tissue sarcomas with trauma, attention is often called to the presence of a mass after trauma to that area.

Imaging is the first step in evaluation of a presumed sarcoma, and MRI offers superior soft tissue resolution without radiation exposure. Removal of the mass without prior imaging should never be performed. If the imaging studies suggest a soft tissue sarcoma, either a needle biopsy (fine-needle or core) or an incisional biopsy should be performed. Excisional biopsy would be a major error in treatment, as resection of high-grade soft tissue sarcoma with multiple positive margins greatly increases the risk of local failure. In addition, excisional biopsy risks infection, wound-healing problems, and contamination of major neurovascular structures, thus compromising definitive therapy.

Staging studies include a CT scan of the chest and a chest radiograph.

Reference:

Frassica FJ, Khanna JA, McCarthy EF. The role of MR imaging in soft tissue tumor evaluation: Perspective of the orthopedic oncologist and musculoskeletal pathologist. *Magn Reson Imaging Clin N Am.* 2000;8(4):915–927.

۰۲۱-۶۶۱۹۸۵۱۴ www.myuptodate.com دریافت آخرین نسخه آپتودیت آفلاین

1B17

Key word: Conditions Associated with Normal Anion Gap Acidosis

Authors: Kelly Olino, MD, and Susanna M. Nazarian, MD, PhD
Editor: Elliott R. Haut, MD, FACS

A 42-year-old man with marked ascites is being treated with lactulose for hepatic encephalopathy secondary to alcoholic cirrhosis. What is the most likely acid–base abnormality found in this patient?

(A) Anion gap metabolic acidosis

(B) Metabolic alkalosis

(C) Normal anion gap metabolic acidosis

(D) Respiratory acidosis

(E) Respiratory alkalosis

Answer: (C) Normal anion gap metabolic acidosis

Rationale:

Metabolic acidosis is classified as either elevated anion gap metabolic acidosis or normal anion gap (or hyperchloremic) metabolic acidosis. The anion gap is calculated by subtracting the sum of serum concentrations of the anions, Cl^- and HCO_3^-, from the sum of the cations, Na^+ and K^+: Anion gap = $([Na^+] + [K^+]) - ([Cl^-] + [HCO_3^-])$. The normal anion gap ranges from 14 to 18. For simplicity, some experts do not use the serum potassium value in the calculation and thus the normal anion gap range would be 10 to 14. The differentiation of metabolic acidosis into anion gap or normal anion gap categories assists in the formulation of a differential diagnosis and in treatment.

Patients with hepatic encephalopathy are likely to be treated with two medications that are known to cause a normal anion gap metabolic acidosis: Lactulose and spironolactone. Lactulose causes an osmotic diarrhea leading to bicarbonate losses. Spironolactone is an aldosterone antagonist, limiting potassium and hydrogen ion excretion in the distal renal tubules and contributing to hyperchloremic metabolic acidosis.

Generally speaking, there are a number of potential causes of normal anion gap metabolic acidosis. Bicarbonate may be lost through the gastrointestinal tract (nasogastric tube suctioning, small bowel drainage, diarrhea) or kidneys (renal tubular acidosis, ureteroileostomy). Iatrogenic causes include improper balancing of electrolytes in total parenteral nutrition (TPN) formulations or administration of excessive amounts of normal saline, potassium chloride, or ammonium chloride. Medications such as ammonium chloride, lysine, or arginine hydrochloride and carbonic anhydrase inhibitors may also induce metabolic acidosis. Primary hyperparathyroidism and aldosterone deficiency or insensitivity are other causes of metabolic acidosis.

References:

Andreoli TE, Abul-Ezz SR. Fluid and electrolyte disorders. In: Andreoli TE, Carpenter CCJ, Griggs RC, Loscalzo J, eds. *Cecil Essentials of Medicine.* 5th ed. Philadelphia, PA: W.B. Saunders Company; 2001:238–252.

Gabow PA, Moore S, Schrier RW. Spironolactone-induced hyperchloremic acidosis in cirrhosis. *Ann Intern Med.* 1979;90(3):338–340.

Gauthier PM, Szerlip HM. Metabolic acidosis in the intensive care unit. *Crit Care Clin.* 2002;18:289–308.

Slonim AD. Consider excess chloride as a cause of an unexplained non-anion-gap metabolic acidosis. In: Marcucci L, Martinez EA, Haut ER, Slonim AD, Suarez JI, eds. *Avoiding Common ICU Errors.* Philadelphia, PA: Lippincott Williams & Wilkins; 2007:429–430.

۰۲۱-۶۶۱۹۸۵۱۴ www.myuptodate.com دریافت آخرین نسخه آپتودیت آفلاین

1B18

Key word: Treatment of 0.6-mm Melanoma of the Forearm

Authors: Robert A. Meguid, MD, MPH, and Susanna M. Nazarian, MD, PhD
Editors: Charles M. Balch, MD, FACS, and Lisa K. Jacobs, MD

A 76-year-old man presents with a lesion on the left forearm suspicious for melanoma. Biopsy confirms a melanoma of 0.6 mm thickness. What margin around the lesion do you need to take during excision to minimize the likelihood of recurrence?

(A) None
(B) 5 mm
(C) 1 cm
(D) 2 cm
(E) Greater than 2 cm

Answer: (C) 1 cm

Rationale:
The Melanoma Task Force of the American Joint Committee on Cancer (AJCC) revised the melanoma staging system in 2003. Please see the explanation for question M30 for detailed discussion of this TNM-based system. A patient with a localized invasive melanoma is either Stage I or II, depending on the thickness of the lesion (Breslow thickness).

Numerous clinical trials have revised the former practice of excision of all melanomas with a 4- to 5-cm margin. Current recommendations for surgical margin include the following.

Tumor Thickness (mm)	Excision Margin (cm)
In situ	0.5–1
0–1	1
1–2	1 or 2[a]
2–4	2
>4	At least 2 cm

[a]A 1 cm margin is appropriate in anatomically restricted areas; otherwise a 2 cm margin is preferable.

Adapted from: Table 10-12, Ross MI, Balch CM, Cascinelli N, et al. Excision of primary melanoma. In: Balch CM, Houghton AN, Sober AJ, Soong SJ, eds. *Cutaneous Melanomas*. 4th ed, p. 218–222. St. Louis, MO: Quality Medical Publishing; 2003.

Normally excision is performed using an elliptical excision with primary closure. Cosmesis is improved by using a 3:1 ratio of length:width in creating the ellipse. Excision should extend to the underlying muscle fascia, but not through it. In extremely obese patients, the excision depth should extend at least to the superficial fascia.

T1b, T2, T3, and T4 melanomas should have lymphatic mapping and sentinel lymph node biopsy. A completion radical lymph node dissection should be performed when the sentinel lymph contains metastatic disease or in patients with clinically apparent nodal involvement when the diagnosis is confirmed by fine-needle aspiration. Stage III disease usually warrants systemic therapy.

Of note, additional factors associated with a worsened outcome include male sex, ulceration of the primary melanoma, mitotic rate >1/mm^2 and location on the head or trunk.

References:

Balch CM, Buzaid AC, Soong S-J, et al. Final version of the American Joint Committee on Cancer staging system for cutaneous melanoma. *J Clin Oncol.* 2001; 19(16):3635–3648.

Balch CM, Soong SJ, Gershenwald JE, et al. Prognostic factors analysis of 17,600 melanoma patients: Validation of the American Joint Committee on Cancer Melanoma Staging System. *J Clin Oncol.* 2001;19(16):3622–3634.

Gershenwalk JE, Balch CM, Soong S-J, et al. Prognostic factors and natural history. In: Balch CM, Houghton AN, Sober AJ, Soong S-J, eds. *Cutaneous Melanomas.* 4th ed. St. Louis, MO: Quality Medical Publishing; 2003:25–54.

Ross MI. New American Joint Commission on Cancer staging system for melanoma: Prognostic impact and future directions. *Surg Oncol Clin N Am.* 2006;15(2):341–352.

Ross MI, Balch CM, Cascinelli N, et al. Excision of primary melanoma. In: Balch CM, Houghton AN, Sober AJ, Soong S-J, eds. *Cutaneous Melanomas,* 4th ed. St. Louis, MO: Quality Medical Publishing; 2003:218–222.

Veronesi U, Cascinelli N, Adamus J, et al. Thin stage I primary cutaneous malignant melanoma: Comparison of excision with margins of 1 or 3 cm. *N Engl J Med.* 1988;318(18): 1159–1162.

۰۲۱-۶۶۱۹۸۵۱۴ www.myuptodate.com دریافت آخرین نسخه آپتودیت آفلاین

1B19

Key word: Antibiotic Treatment of Emphysematous Cholecystitis

Author: Bonnie E. Lonze, MD, PhD
Editor: Martin A. Makary, MD, MPH

A 42-year-old diabetic woman presents to the emergency department complaining of nausea, vomiting, and abdominal pain. She had been in her usual state of health until the prior day when the symptoms began. Her temperature is 38°C and her white blood cell count is 17,000. Initial workup includes a right upper quadrant ultrasound that is negative for stones but is suggestive of air within the lumen of the gallbladder. The most appropriate initial antibiotic choice for this patient would be:

(A) Intravenous amikacin

(B) Intravenous ampicillin/sulbactam

(C) Intravenous cefazolin

(D) Intravenous clindamycin

(E) Intravenous piperacillin/tazobactam

Answer: (E) Intravenous piperacillin/tazobactam

Rationale:

Emphysematous cholecystitis is a particularly severe variant of acute cholecystitis which is associated with a significantly greater mortality and morbidity when compared to other types of acute cholecystitis. In emphysematous cholecystitis, the infection is caused by a gas-forming bacterium. Radiographic diagnosis is made via ultrasound or computed tomography, and characteristic radiographic findings in this disease, namely gas within the gallbladder lumen, gallbladder wall, and occasionally, bile ducts. The incidence of gallbladder perforation is approximately fivefold greater in emphysematous cholecystitis. There is a higher incidence of emphysematous cholecystitis in diabetics, and in men who develop cholecystitis. Gallstones are seen in many but not all cases of emphysematous cholecystitis; there are many documented cases of acalculous emphysematous cholecystitis.

Management includes the prompt initiation of intravenous antibiotics that cover a broad spectrum of gram-negative organisms and definitive operative therapy. Of the antibiotic choices listed above, piperacillin/tazobactam would be the most appropriate choice, but other acceptable alternatives would include third-generation cephalosporins and quinolones (although anaerobic therapy should also be added). Amikacin is not an ideal initial line of therapy because of its potential nephrotoxicity and the need to monitor drug levels. In addition, it only covers gram-negative pathogens. Clindamycin would provide anaerobic coverage but would not cover the necessary spectrum of gram-negative organisms, including pseudomonas. Ampicillin/sulbactam, likewise would not provide coverage of pseudomonas. Cefazolin, with predominantly gram-positive coverage, would be inappropriate.

Reference:

Sawyer RG, Barkun JS, Smith R, et al. Intra-abdominal infection. In: Souba WW, Fink MP, Jurkovich GJ, Kaiser LR, Pearce WH, Pemberton JH, Soper NJ, eds. *ACS Surgery: Principles and Practice.* 4th ed. New York, NY: WebMD; 2004:1339–1340.

۰۲۱-۶۶۱۹۸۵۱۴ www.myuptodate.com دریافت آخرین نسخه آپتودیت آفلاین

1B20

Key word: Preoperative Treatment of Increased INR from Warfarin

Author: Robert A. Meguid, MD, MPH
Editor: Frederick E. Eckhauser, MD, FACS

A 53-year-old man is brought into the emergency department after sustaining a gunshot wound to the left flank. You suspect a splenic injury with ongoing bleeding. The patient discloses that he is on warfarin, and his international normalized ratio (INR) is 3. What do you use to correct the coagulopathy en route to the operating room?

(A) Fresh frozen plasma (FFP) transfusion
(B) Packed red blood cell (PRBC) transfusion
(C) Protamine infusion
(D) Vitamin K intravenously
(E) Vitamin K orally

Answer: (A) Fresh frozen plasma (FFP) transfusion

Rationale:
When emergency surgery must be performed on patients who are currently anticoagulated with therapeutic warfarin (coumadin) levels, normalization of anticoagulation may be obtained most expediently by transfusion with FFP. FFP replaces Factors II, VII, IX, and X. Synthesis of these coagulation factors is Vitamin K dependent, and is inhibited in the liver by warfarin.

While vitamin K given intravenously does reverse anticoagulation due to warfarin, it takes approximately 6 hours to be effective. This time may not be adequate based on the nature of the surgical emergency. Orally administered vitamin K takes substantially longer to be effective, between 12 and 18 hours. When vitamin K is administered for reversal, it should be given in relatively small doses with the recognition that the time required for future anticoagulation will be somewhat prolonged.

PRBC do not contain the clotting factors necessary for reversal of anticoagulation. In fact, large volume PRBC transfusions further dilute the endogenous clotting factors, necessitating additional transfusion with FFP.

Protamine is used to reverse the effects of heparin, but it is ineffective in reversing the effects of warfarin.

Reference:
Marks PW, Rosovsky R. Chapter 156: Hematologic manifestations of systemic disease: Liver and renal disease. In: Hoffman R, Benz EJ Jr, Shattil SJ, Furie B, Cohen HJ, Silberstein LE, eds. *Hematology: Basic Principles and Practice.* 5th ed. New York, NY: Elsevier; 2008.

1B21

Key word: Maintenance of Core Temperature in the Operating Room

Authors: Susanna M. Nazarian, MD, PhD, and Robert A. Meguid, MD, MPH
Editors: Thomas H. Magnuson, MD, and Kenzo Hirose, MD, FACS

After a prolonged, open abdominal aortic aneurysm repair requiring large volumes of fluid resuscitation, a 75-year-old man remains paralyzed and sedated, on full ventilatory support in the intensive care unit. While he is hemodynamically stable, his core body temperature is only 34°C. What would have been the most important way to maintain his core temperature intraoperatively?

(A) Keep the room temperature elevated
(B) Surround the patient with blankets
(C) Use forced-air warming devices
(D) Use of warmed intravenous fluids
(E) Warm intra-abdominal irrigation fluids

Answer: (C) Use forced-air warming devices

Rationale:
Hypothermia, core body temperature less than 35°C, may result from prolonged operations with exposure of large surface areas, such as abdominal operations, situations where large volumes of unheated fluid are transfused intravenously, and during paralysis, where the body's shiver mechanism is impeded. Hypothermia can result in cardiac arrhythmias, decreased cardiac output, hypocoagulability, and increased wound infection rates.

Initial management of hypothermia consists of minimizing heat loss through insulation of the patient. However, given that this patient was paralyzed and sedated during the procedure, he was unable to generate sufficient metabolic activity to increase his own body temperature by more than 1°C/hr with passive insulation in place.

While intravenous transfusion with 1 L of room temperature fluid decreases the mean body temperature by approximately 0.25°C, administration of heated fluids may maintain body temperature but is insufficient to rewarm patients. Therefore, the most effective initial action to treat mild hypothermia in the stable patient is institution of active rewarming through use of warm blankets and forced-air warming devices.

It is best to prevent hypothermia with a forced-air warming blanket. If the patient does become hypothermic, measures such as warmed IVF should be instituted. While environmental temperature should not be cold, elevating the room temperature can lead to staff discomfort, with little effect on patient temperature. Peritoneal warming is an effective means of warming an extremely hypothermic patient.

۰۲۱-۶۶۱۹۸۵۱۴ www.myuptodate.com دریافت آخرین نسخه آپتودیت آفلاین

References:
Cuschieri J. Shock. In: Mulholland MW, Lillemoe KD, Doherty GM, Maier RV, Upchurch GR, eds. *Greenfield's Surgery: Scientific Principles & Practice.* 5th ed. Philadelphia, PA: Lippincott Williams & Wilkins; 2011.
Dayton MT. Surgical complications. In: Townsend CM, Beauchamp RD, Evers BM, Mattox KL, eds. *Sabiston Textbook of Surgery.* 17th ed. Philadelphia, PA: W.B. Saunders; 2004. Accessed online July 27,2007. Online Edition.
Sessler DI. Complications and treatment of mild hypothermia. *Anesthesiology.* 2001;95(2):531–543.

1B22

Key word: Treatment of Fournier Gangrene

Author: Robert A. Meguid, MD, MPH
Editor: Elliott R. Haut, MD, FACS

A 24-year-old HIV-positive man presents to the emergency room with acute-onset pain and redness in his scrotum, penis, and perineum. Upon examination, you feel crepitus over the erythematous area described, which emits a foul-smelling grey discharge. What is the most appropriate management for this patient's illness?

(A) Apply topical polymycin ointment
(B) Give hydrocortisone infusion
(C) Initiate highly active antiretroviral treatment (HAART)
(D) Initiate penicillin G infusion
(E) Surgical debridement of affected tissue

Answer: **(E)** Surgical debridement of affected tissue

Rationale:
Fournier gangrene is a soft tissue infection usually involving the scrotum, penis, and perineum. Patients are often immunosuppressed or immunocompromised, often due to steroid use or with diabetes mellitus, and present with acute-onset pain and erythema of affected tissues. While Fournier gangrene is classically seen in men, women may develop it of the perineum, labia majora, and abdominal wall.

Fournier gangrene progresses rapidly, is usually polymicrobial in etiology, and is associated with a 50% mortality rate. Broad-spectrum antibiotic treatment for both anaerobic and aerobic bacteria should be instituted immediately. Radical surgical debridement down to healthy, bleeding tissue remains the mainstay of treatment, with possible diversion of gastrointestinal and genitourinary tracts. Intraoperative aerobic and anaerobic bacterial cultures should be obtained. A common combination for antibiotic therapy includes a third-generation cephalosporin and clindamycin. Clindamycin effectively covers anaerobes and also binds toxins produced by the gram-positive organisms.

While steroids and HAART may be indicated for treatment of other maladies of this patient, they are not the most appropriate management for this patient's acute illness of Fournier gangrene.

Reference:
Dellinger EP. Surgical infections. In: Mulholland MW, Lillemoe KD, Doherty GM, Maier RV, Upchurch GR, eds. *Greenfield's Surgery: Scientific Principles & Practice.* 5th ed. Philadelphia, PA: Lippincott Williams & Wilkins; 2011.

۰۲۱-۶۶۱۹۸۵۱۴ www.myuptodate.com دریافت آخرین نسخه آپتودیت آفلاین

1B23

Key word: Indications for Liver Transplant in End-stage Liver Disease

Author: Jayme E. Locke, MD, MPH
Editors: Robert A. Montgomery, MD, DPhil, FACS, and Dorry L. Segev, MD, PhD

A 35-year-old former intravenous drug user with a history of Hepatitis C infection has developed cirrhosis and has recently been placed on the liver transplant waiting list. He would like to know how "sick" he must be, as assessed the model for end-stage liver disease score (MELD), before the benefits of liver transplantation outweigh the risks. What do you tell him his MELD score has to be greater than?

(A) 10
(B) 15
(C) 20
(D) 30
(E) 40

Answer: **(B)** 15

Rationale:
Merion and colleagues performed a retrospective analysis of the Scientific Registry for Transplant Recipients (the national database of solid organ transplant outcomes) and determined that liver transplantation offers a survival benefit only to those patients with MELD scores greater than 15. In other words, patients with MELD scores ≤15 are more likely to die from the transplant procedure itself as opposed to their underlying liver disease. Of note, this risk–benefit calculation for liver transplantation applies to the "average" patient, and does not consider accompanying complications of liver disease that may be indications for transplantation but not captured in the MELD score, such as portopulmonary or hepatopulmonary syndrome.

The MELD score is used for patients aged 12 years and older, and is calculated as follows:

MELD = 3.8 [natural log of serum bilirubin (mg/dL)] + 11.2 [natural log of INR] + 9.6 [natural log of serum creatinine (mg/dL)]

The maximum MELD score is 40, and all scores greater than 40 are assigned the value of 40. A creatinine of 4.0 is substituted for patients who have undergone dialysis at least two times in the past 7 days. Any values less than 1 are rounded to 1.0. Currently, liver transplant priority in the United States depends on MELD score, with the goal of minimizing the chances that a patient will die on the waiting list.

Reference:
Merion RM, Schaubel DE, Dykstra DM, et al. The survival benefit of liver transplantation. *Am J Transplant.* 2005; 5(2):307–313.

1B24

Key word: Preoperative Predictor of Perioperative Cardiac Complications

Author: Jonathan A. Forbes, MD
Editors: Duke E. Cameron, MD, and Christopher M. Sciortino, MD, PhD

A 67-year-old man with a medical history of hypertension and insulin-dependent diabetes mellitus presents for preoperative counseling before an open abdominal aortic aneurysm repair scheduled 3 weeks from now. He has never had a cerebrovascular accident (CVA) or a myocardial infarction and denies symptoms of angina or heart failure. His preoperative laboratory values are unremarkable except for a creatinine of 2.2 mg/dL. The patient also reports that he is unable to walk up two flights of stairs before tiring. An electrocardiogram reveals normal sinus rhythm. Which of the following measures is appropriate given his current level of cardiac risk?

(A) He should have a coronary angiogram and be considered for coronary revascularization before surgery
(B) He should receive perioperative beta blockade, but noninvasive stress testing is not mandated
(C) He should undergo coronary revascularization before repair of his abdominal aortic aneurysm
(D) He should undergo noninvasive stress testing (i.e., exercise stress testing, dipyridamole thallium imaging) and if negative for high-risk features should receive perioperative beta blockade
(E) There is no indication for noninvasive stress testing or perioperative beta blockade

Answer: **(B)** He should receive perioperative beta blockade, but noninvasive stress testing is not mandated

Rationale:
Estimation of cardiac risk prior to surgery allows for patient stratification into low-, intermediate-, and high-risk groups that help guide the clinician on whether or not to delay surgery, offer a medical or surgical intervention, or do nothing. When estimating risk, it is customary to grade the patient in three realms: Functional status (generally thought to be satisfactory if the patient is able to walk two flights of stairs without stopping), clinical risk factors, and risk of procedure. In general, low-risk patients require no therapy, intermediate- and high-risk patients benefit from perioperative beta blockade, and high-risk patients require revascularization for documented severe left main or three-vessel disease.

The American College of Cardiology and American Heart Association 2007 Guidelines on Perioperative Cardiovascular Evaluation and Care for Noncardiac Surgery offer comprehensive recommendations for these complex patients. For patients requiring emergency surgery, they should proceed directly to the operating room. In the event of nonemergency surgery, patients who have any of the following active cardiac conditions require evaluation and treatment

۰۲۱-۶۶۱۹۸۵۱۴ www.myuptodate.com دریافت آخرین نسخه آپتودیت آفلاین

prior to noncardiac surgery: Unstable coronary syndromes, decompensated heart failure, significant arrhythmias, and/or severe valvular disease. In the absence of active cardiac conditions and in the case of low-risk surgery or in patients with good functional capacity, those patients may proceed with surgery.

For those with poor functional status, their approach will hinge on the number of clinical risk factors they have and whether or not they will be undergoing vascular surgery. Clinical risk factors include ischemic heart disease, compensated heart failure or a history of prior heart failure, diabetes mellitus, renal insufficiency, and cerebrovascular disease. If the patient has no risk factors, they may proceed with his/her planned surgery. For patients with one or two clinical risk factors, they may proceed with the planned surgery with heart rate control or the clinician may consider noninvasive testing if the results will change the management. The same holds true for patients with three or more risk factors who are undergoing intermediate risk surgery. For patients with three or more clinical risk factors undergoing vascular surgery, they will most likely require noninvasive testing prior to their operation.

This particular patient, while undergoing high-risk surgery and having a relatively poor functional status, has only two relevant clinical risk factors: Diabetes mellitus and baseline renal insufficiency. Noninvasive testing may be considered by the clinician, but is certainly not mandated. Beta blockade, in the absence of any contraindications, should be started for the patient.

While perioperative beta blockade is often employed in clinical practice, preoperative revascularization (angioplasty +/– stenting, coronary artery bypass graft [CABG]) is much less commonly endorsed. The reasons behind the reluctance to pursue CABG are illustrated by the CASS trial, where the risk of cardiac events in surgical patients was lower in patients who underwent preoperative CABG (0.9% vs. 2.4%), but this trend was offset by the 1.4% mortality associated with the CABG procedure. The risk/benefit profile of revascularization versus perioperative beta blockade is further illustrated by the CARP trial, where postoperative myocardial infarction in the two groups occurred with similar frequency (11.6% vs. 14.3%, respectively) and there were no effective differences between the left ventricular ejection fractions at 3 months. Thus, the decision to revascularize the patient is made independent of his or her need for surgery.

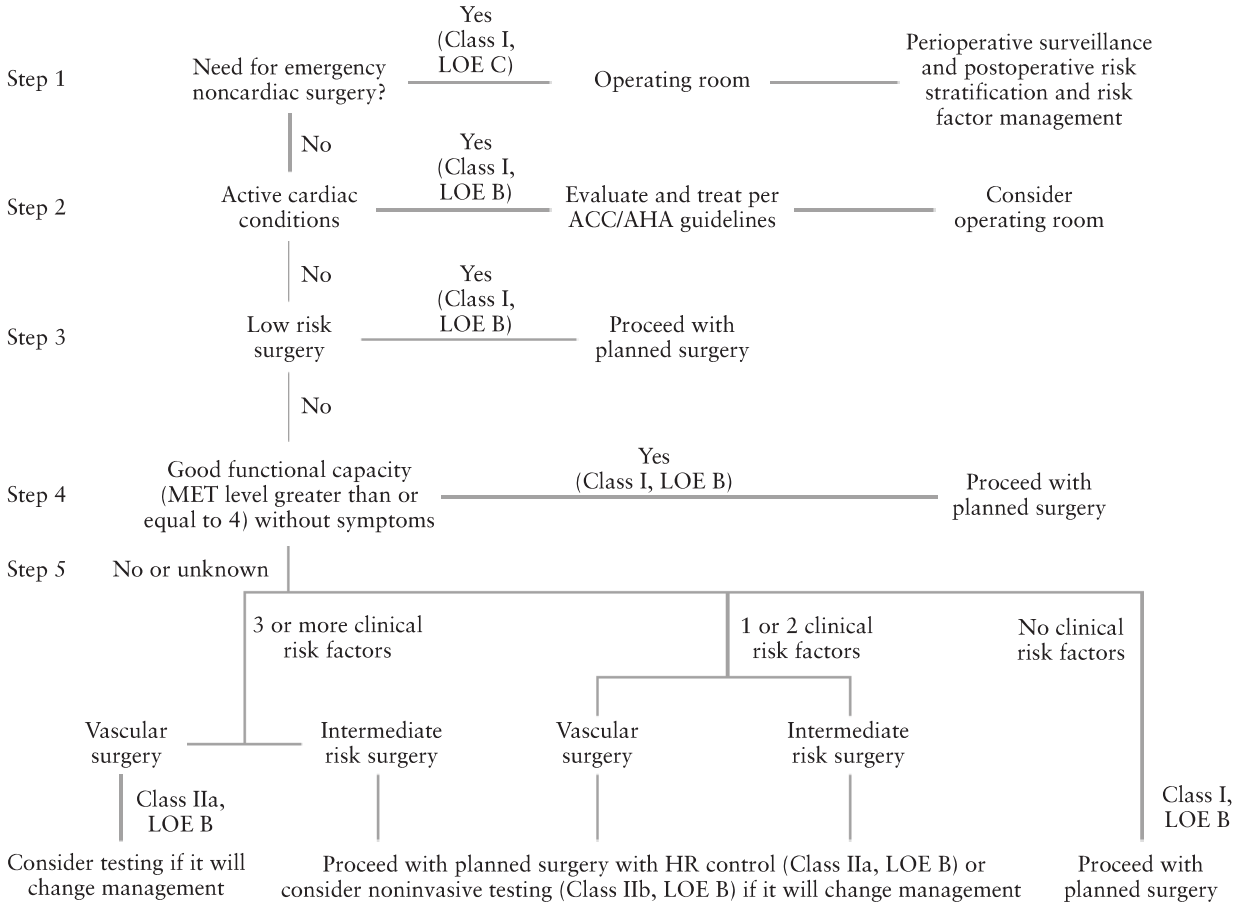

Decision aid for preoperative cardiac evaluation prior to noncardiac surgery. The decision tree for preoperative evaluation takes into account not only the patient's physical status but also the severity of the surgical procedure. ACC, American College of Cardiology; AHA, American Heart Association; LOE, level of evidence. Reprinted with permission from: Kheterpal S, Rutter TW, Tremper KK. Anesthesiology and pain management. In: Mulholland MW, Lillemoe KD, Doherty GM, Maier RV, Upchurch GR, eds. *Greenfield's Surgery: Scientific Principles & Practice*. 5th ed. Philadelphia, PA: Lippincott Williams & Wilkins, 2011:247.

۰۲۱-۶۶۱۹۸۵۱۴ www.myuptodate.com دریافت آخرین نسخه آپتودیت آفلاین

References:

Almanaseer Y, Mukherjee D, Kline-Rogers EM, et al. Implementation of the ACC/AHA guidelines for preoperative cardiac risk assessment in a general medicine preoperative clinic: Improving efficiency and preserving outcomes. *Cardiology.* 2005;103(2):24–29.

Fleisher LA, Beckman JA, Brown KA, et al. ACC/AHA 2007 Guidelines on Perioperative Cardiovascular Evaluation and Care for Noncardiac Surgery: A Report of the American College of Cardiology/American Heart Association Task Force on Practice Guidelines (Writing Committee to Revise the 2002 Guidelines on Perioperative Cardiovascular Evaluation for Noncardiac Surgery). *J Am Coll Cardiol.* 2007;50:159–e242.

Kheterpal S, Rutter TW, Tremper KK. Anesthesiology and pain management. In: Mulholland MW, Lillemoe KD, Doherty GM, Maier RV, Upchurch GR, eds. *Greenfield's Surgery: Scientific Principles & Practice.* 5th ed. Philadelphia, PA: Lippincott Williams & Wilkins; 2011.

Mangano DT, Goldman L. Preoperative assessment of patients with known or suspected coronary disease. *N Engl J Med.* 1995;333(26):1750–1756.

McFalls EO, Ward HB, Moritz TE, et al. Coronary-artery revascularization before elective major vascular surgery. *N Engl J Med.* 2004;351:2795–2804.

Wesorick DH, Eagle KA. The preoperative cardiovascular evaluation of the intermediate-risk patient: New data, changing strategies. *Am J Med.* 2005;118(12):1413.

1B25

Key word: Respiratory Quotient of Fat in TPN

Author: Bonnie E. Lonze, MD, PhD
Editor: David T. Efron, MD, FACS

A 50-year-old man is in the intensive care unit with necrotizing pancreatitis. He is struggling to wean from the ventilator. As he has been maintained on total parenteral nutrition (TPN), you are suspicious of an overfeeding syndrome and elect to perform indirect calorimetry. Which of the following values for the respiratory quotient (RQ) would be consistent with an overfeeding syndrome?

(A) 0.65
(B) 0.7
(C) 0.8
(D) 1
(E) 1.3

Answer: (E) 1.3

Rationale:

A respiratory quotient of greater than 1 is indicative of an overfeeding syndrome. The respiratory quotient is the ratio of carbon dioxide produced to oxygen consumed during oxidation of a given energy substrate (glucose, protein, or fat). A respiratory quotient of >1 indicates lipogenesis, consistent with overfeeding. A respiratory quotient of <0.7 indicates ketogenesis, consistent with starvation. A respiratory quotient of 1 indicates pure carbohydrate metabolism, a respiratory quotient of 0.8 indicates protein metabolism, and a respiratory quotient of 0.7 indicates fat metabolism. Overfeeding leads to overproduction of CO_2, which leads to increased ventilatory demand and increased work of breathing. The total caloric content in this patient's TPN would need to be decreased.

Reference:

Halsted CH. Malnutrition and nutritional assessment. In: Fauci AS, Braunwald E, Kasper DL, Hauser SL, Longo DL, Jameson JL, Loscalzo J, eds. *Harrison's Principles of Internal Medicine.* 17th ed. New York, NY: McGraw-Hill; 2009.

۰۲۱-۶۶۱۹۸۵۱۴ www.myuptodate.com دریافت آخرین نسخه آپتودیت آفلاین

1B26

Key word: Treatment of Hypothermia

Author: Trevor A. Ellison, MD, MBA
Editor: Martin A. Makary, MD, MPH

Three men are admitted to the emergency department after developing severe hypothermia and dehydration while ice fishing. You decide to rewarm and resuscitate them with warmed intravenous fluids. The nurse asks how warm you would like the fluids. You explain that the highest temperature that is safe to administer to the patients is:

(A) 45°C
(B) 55°C
(C) 65°C
(D) 75°C
(E) Rewarming with IV fluids above normal body temperatures is not recommended

Answer: (C) 65°C

Rationale:
Rewarming a hypothermic patient can be divided into three treatment strategies: Passive external rewarming, active external rewarming, and active core rewarming.

Passive external rewarming is used for those with mild hypothermia and consists of taking the patient out of the hypothermic environment.

Active external rewarming includes treatment with warm blankets, heating pads, infrared heating lights, and immersion in warm water. A disadvantage of active external rewarming is that the peripheral tissues are rewarmed before the body core. This causes peripheral vasodilation and can lead to "rewarming shock," vascular collapse in setting of inadequate volume resuscitation. Also of concern with active external rewarming is "afterdrop." Afterdrop refers to a fall in core temperature due to an unknown mechanism. Theories attribute this fall in temperature to cold blood returning to the core or volume contraction due to vasoconstriction, cold diuresis, and cell swelling with inadequate resuscitation.

Active core rewarming comes in many forms: Heating intravenous fluids (up to 65°C), heated peritoneal/thoracic/gastric/bladder/colonic lavage, heated and water-saturated inhaled air, extracorporeal circulatory rewarming (the greatest rate of heat transfer), and blood rewarming up to 42°C (maximum of 49°C according to the American Association of Blood Banks). Of note, lavage rewarming rates vary greatly depending on initial core temperature, rewarming fluid temperature, infusion rate, and the amount of time the fluid is left in the body cavity ("dwell time").

Reference:
Jurkovich GJ. Environmental injuries. In: Mulholland MW, Lillemoe KD, Doherty GM, Maier RV, Upchurch GR, eds. *Greenfield's Surgery: Scientific Principles & Practice.* 5th ed, Philadelphia, PA: Lippincott Williams & Wilkins; 2011.

1B27

Key word: Treatment of Hypochloremic Alkalosis

Author: Susanna M. Nazarian, MD, PhD
Editor: Dorry L. Segev, MD, PhD

A 30-year-old man underwent pelvic fixation after a motorcycle accident 2 days ago. He has been vomiting episodically for the past 24 hours, has had a high nasogastric tube output, and his respiratory rate is 8. To correct his acid–base status electrolytes, you should:

(A) Administer acetazolamide
(B) Give 2.2-mEq/L ammonium chloride
(C) Infuse 1-L lactated Ringer solution
(D) Infuse 1-L normal saline with 20-mEq KCl/L
(E) Perform emergency dialysis

Answer: (D) Infuse 1-L normal saline with 20 mEq KCl/L

Rationale:
This patient is suffering from hypochloremic metabolic alkalosis brought on by vomiting and loss of gastric fluids. Acute metabolic alkalosis leads to central nervous system changes such as confusion, obtundation, and stupor, as well as possible neuromuscular consequences including tetany. The loss of hydrogen chloride from gastric acid results in a net gain in bicarbonate (HCO_3^- is secreted in equimolar amounts along with gastric HCl). Although the kidneys can secrete bicarbonate, sodium is required for cotransport in the renal tubule. Given the dehydration accompanying vomiting, this compensatory mechanism becomes limited and alkalosis ensues. The respiratory system accommodates by hypoventilation, as higher concentrations of CO_2 will be converted into acid via carbonic anhydrase:

$$CO_2 + H_2O \Rightarrow H_2CO_3 \Rightarrow H^+ + HCO_3^-$$

Normal saline with 20-mEq/L KCl should be administered to the patient as it has the most sodium (and chloride) of the resuscitative fluids. Each liter of normal saline contains 154 mEq of sodium, compared with 130 mEq for lactated Ringer solution. Sodium is necessary to facilitate the excretion of bicarbonate from the kidney. Chloride is necessary as the replacement anion and this form of alkalosis is known as "chloride responsive." The other component of treatment should include potassium repletion in patients with adequate renal function. Acetazolamide can be administered to patients with metabolic alkalosis who are not volume depleted. Acids, including dilute hydrochloric acid, ammonium chloride, arginine hydrochloride, and lysine hydrochloride, can be administered with great care to a patient in severe metabolic alkalosis with renal insufficiency.

۰۲۱-۶۶۱۹۸۵۱۴ www.myuptodate.com دریافت آخرین نسخه آپتودیت آفلاین

Electrolyte Content of Commonly Used Intravenous Crystalloid Solutions

	Electrolyte (mEq/L)					
Solution	**Na^+**	**K^+**	**Ca^{2+}**	**Mg^{2+}**	**Cl^-**	**Lactate**
0.9% NaCl	154	—	—	—	154	—
0.45% NaCl	77	—	—	—	77	—
0.33% NaCl	56	—	—	—	56	—
0.2% NaCl	34	—	—	—	34	—
Lactated Ringer	130	4	4	—	109	28
3.0% NaCl	513	—	—	—	513	—
5.0% NaCl	855	—	—	—	855	—

Reprinted with permission from: Wait RB, Alouidor Rl. Fluids, electrolytes, and acid–base balance. In: Mulholland MW, Lillemoe KD, Doherty GM, Maier RV, Upchurch GR, eds. *Greenfield's Surgery: Scientific Principles & Practice*. 5th ed. Philadelphia, PA: Lippincott Williams & Wilkins, 2011:196.

Reference:

Wait RB, Alouidor R. Fluids, electrolytes, and acid–base balance. In: Mulholland MW, Lillemoe KD, Doherty GM, Maier RV, Upchurch GR, eds. *Greenfield's Surgery: Scientific Principles & Practice*. 5th ed. Philadelphia, PA: Lippincott Williams & Wilkins; 2011:196.

۰۲۱-۶۶۱۹۸۵۱۴ www.myuptodate.com دریافت آخرین نسخه آپتودیت آفلاین

1B28

Key word: Diagnosis of Metabolic Alkalosis

Author: Susanna M. Nazarian, MD, PhD
Editors: Charles M. Balch, MD, FACS, and Lisa K. Jacobs, MD

A 27-year-old man is shot in the leg and arm and arrives in the emergency department in hypovolemic shock from massive hemorrhage. After prolonged surgery to reconstruct his femoral and brachial arteries he is hemodynamically stable. On arrival to the intensive care unit, his arterial blood gas values are as follows: pH 7.50, pO_2 140 mm Hg, pCO_2 50 mm Hg, HCO_3^- 28 mEq/L. What is the likely etiology of his acid–base disturbance?

(A) Contraction alkalosis
(B) Dilutional acidosis
(C) Hyperventilation
(D) Ingestion of an excessive amount of antacid prior to the injury
(E) Lactic acidosis

Answer: (A) Contraction alkalosis

Rationale:
Metabolic alkalosis is characterized by an elevated level of bicarbonate (HCO_3^-) without an associated decrease in arterial pCO_2. A dehydrated patient may develop an alkaline pH secondary to a higher concentration of HCO_3^- in his intravascular space. This is the opposite of dilutional acidosis, in which overaggressive resuscitation with normal saline leads to decreased HCO_3^- concentration. Moreover, volume depletion spurs reabsorption of sodium in the kidney. Since sodium requires bicarbonate for cotransport, bicarbonate rises correspondingly. Furthermore, contraction of the intravascular volume leads to the release of renin, leading to the formation of aldosterone and the excretion of hydrogen ions in the distal tubule. Treatment should begin with infusion of isotonic saline.

Reference:
Marino PL. Contraction alkalosis. *The ICU Book*. 3rd ed. Philadelphia, PA: Lippincott Williams & Wilkins; 2007: 565–576.

1B29

Key word: Etiology of Hypotension in Hemorrhagic versus Blunt Trauma

Author: Kelly Olino, MD
Editors: Edward E. Cornwell III, MD, FACS, WACS, FCCM, and Albert Chi, MD

A 40-year-old unrestrained male driver is involved in a high-speed motor vehicle crash with a 5-minute extrication time. First responders find him breathing shallowly, with a pulse rate of 113 and blood pressure of 110/70. He has a scalp laceration but no obvious extremity fractures. He is given a large volume of intravenous fluids en route to the hospital. Upon arrival, his Glasgow Coma Scale score is 8 and he is intubated and placed on a ventilator. Shortly thereafter, the patient becomes markedly hypotensive and is found to be in pulseless electrical activity. Cardiopulmonary resuscitation is initiated. What is the next best step in management of this patient?

(A) Bilateral-needle decompression
(B) Chest x-ray
(C) Close scalp laceration
(D) Emergent thoracotomy
(E) Transfusion of blood products

Answer: (A) Bilateral-needle decompression

Rationale:
The etiologies of hypotension in hemorrhagic versus blunt trauma differ. Hemorrhage leading to hypotension is possible in this patient given his mechanism of injury. However, based on his vital signs, the patient likely has a class II hemorrhage and was adequately resuscitated en route to the hospital. Resuscitation with blood products or closure of the scalp laceration would not be the best choices.

An unrestrained driver in a high-speed motor vehicle crash is very likely to have sustained blunt chest injury with rib fractures. Because the pulseless electrical activity arrest occurred after intubation, one should strongly consider the possibility of tension pneumothorax as the etiology. Bilateral-needle decompression would be the next important thing to do as tension pneumothorax would be exacerbated by intubation and is a common and reversible cause of pulseless electrical activity.

Spinal cord injuries are common, especially of the cervical spine, and can lead to neurogenic shock for which fluid resuscitation and vasopressors are the treatment of choice. Blunt cardiac injury can also occur as well as deceleration injuries to the aorta and its branches in the abdomen leading to cardiogenic or hemorrhagic shock. Based on Advanced Trauma Life Support guidelines, emergent thoracotomy has little role in a blunt thoracic trauma patient who exhibits electrical activity although indications are still controversial.

Reference:
American College of Surgeons Committee on Trauma. *ATLS: Advanced Trauma Life Support For Doctors (Student Course Manual)*. 8th ed. Chicago: American College of Surgeons; 2008.

۰۲۱-۶۶۱۹۸۵۱۴ www.myuptodate.com دریافت آخرین نسخه آپتودیت آفلاین

1B30

Key word: Treatment of Respiratory Burn

Author: Sunil S. Karhadkar, MD
Editor: Elliott R. Haut, MD, FACS

A 33-year-old adult male was extricated from a house fire and at the scene was found to have second-degree burns to his trunk and extremities totaling 35% of total body surface area. Primary survey showed singed nasal vibrissae and soot in the oropharynx, but unlabored breathing. He did not have rales, rhonchi, or wheezing and his O_2 saturation was 94% on room air. In this patient, development of hypoxia on hospital day 1 is most likely due to:

(A) Acute respiratory distress syndrome (ARDS)

(B) Bronchospasm

(C) Carbon monoxide poisoning

(D) Pulmonary edema

(E) Upper airway obstruction and asphyxia

Answer: (E) Upper airway obstruction and asphyxia

Rationale:

Acute upper airway obstruction occurs in approximately one-fifth to one-third of hospitalized burn victims with inhalation injury and is a major hazard because of the possibility of rapid progression from mild pharyngeal edema to complete upper airway obstruction with asphyxia. The worsening of upper airway edema is most prominent in supraglottic structures and not in the lower airways (bronchi). Serial nasopharyngoscopic evaluations demonstrate obliteration of the aryepiglottic folds, arytenoid eminences, and interaryteniod areas by edematous tissues that prolapse to occlude the airway. For patients with large surface area burns that require rapid fluid administration, these changes may be accentuated, and early intubation may be indicated in order to secure the airway, and prevent sequelae of upper airway edema. ARDS and pulmonary edema are unlikely in a young adult with no stated comorbidities. Tracheal stenosis is a late complication of inhalational burn injury.

Reference:

Mlcak RP, Suman OE, Herndon DN. Respiratory management of inhalation injury. *Burns.* 2007;33(1):2–13.

1B31

Key word: Diagnosis of Primary Lung Cancer

Author: Susanna M. Nazarian, MD, PhD
Editors: Malcolm V. Brock, MD, FACS, and Robert A. Meguid, MD, MPH

On routine annual examination a 78-year-old man has a 2-cm circular peripheral density in his right upper lung field on chest radiograph. To help establish a diagnosis, what is the next most appropriate step in the workup of this finding?

(A) Brain Magnetic Resonance Imaging (MRI)

(B) Chest Computed Tomography (CT) through the adrenal glands

(C) Fiberoptic bronchoscopy

(D) Integrated Positron Emission Tomography and Computed Tomography (PET–CT)

(E) Lactate dehydrogenase (LDH) level

Answer: (B) Chest Computed Tomography (CT) through the adrenal glands

Rationale:

In diagnosing lung cancer, it is important to define the extent of disease and confirm diagnosis. Diagnosis and staging guides treatment and aids in assessment of patient prognosis. The first steps in the evaluation of a patient with suspected lung cancer include a thorough history and physical examination, and chest radiograph. Following this, workup progress to chest CT imaging, including imaging through the adrenal glands due to possible metastasis of lung cancer to the adrenals. Integrated ^{18}F-2-fluoro-2-deoxy-D-glucose-PET–CT is used for assessment of regional and metastatic disease. Routine MRI of the brain is controversial for low-stage non–small-cell lung cancer. Bronchoscopic evaluation is useful for obtaining tissue biopsy from direct biopsy, navigational bronchoscopic biopsy, or endobronchial ultrasound-guided biopsy of primary lesions and lymph nodes, and is routinely performed prior to surgical resection of appropriate tumors to rule out bronchial involvement. Obtaining tissue for diagnosis is paramount in patient management, with options including image-guided biopsy (CT-guided percutaneous biopsy), bronchoscopic biopsy (discussed above), and surgical biopsy, and usually follows initial high-quality imaging, such as chest CT.

Elevated alkaline phosphatase may indicate bony metastases, while elevated LDH subunit B has been correlated with the clinical stage of lung cancer. Lactate dehydrogenase is an enzyme that catalyzes the conversion of pyruvate to lactate. The upregulation of this enzyme is thought to assist cancer cells in promulgating and reducing their dependence on oxygen. However, LDH is too nonspecific to end a diagnostic evaluation without further tests.

۰۲۱-۶۶۱۹۸۵۱۴ www.myuptodate.com دریافت آخرین نسخه آپتودیت آفلاین

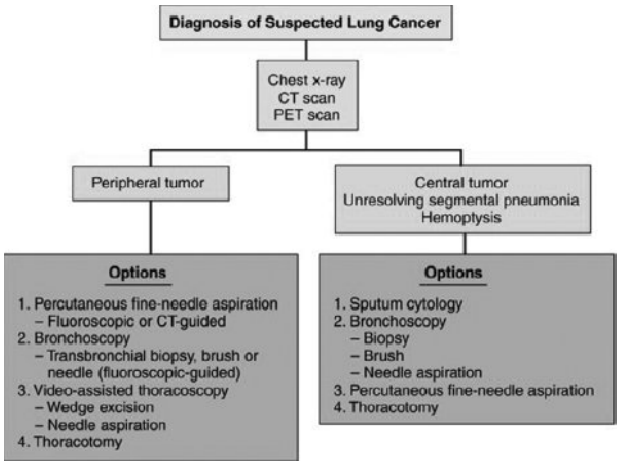

Schema of lung cancer diagnosis and workup. Reprinted with permission from: Schrump DS, Carter D, Kelsey CR. Nonsmall cell lung cancer. In: Devita VT, Lawrence TS, Rosenberg SA, eds. *Cancer: Principles & Practice of Oncology.* 9th ed. Philadelphia, PA: Lippincott Williams & Wilkins, 2011:811.

References:

Chang AC, Lin J. Lung neoplasms. In: Mulholland MW, Lillemoe KD, Doherty GM, Maier RV, Upchurch GR, eds. *Greenfield's Surgery: Scientific Principles & Practice.* 5th ed. Philadelphia, PA: Lippincott Williams & Wilkins; 2011.

Chen Y, Zhang H, Xu A, et al. Elevation of serum l-lactate dehydrogenase B correlated with the clinical stage of lung cancer. *Lung Cancer.* 2006;54(1):95–102.

McNamme CJ, Strauss GM, Sugarbaker DJ. Lung cancer-overview. In: Sugarbaker DJ, Bueno R, Krasna MJ, Mentzer SJ, Zellos L, eds. *Adult Chest Surgery.* New York, NY: McGraw Hill; 2009:508–522.

1B32

Key word: Etiology of Arrhythmia in Torsade de Pointes

Author: Sunil S. Karhadkar, MD
Editor: William A. Baumgartner, MD

In clinic, a 40-year-old male states that for the past 2 days he has had air passing through his urethra, cramping abdominal pain, distension, and loose bowel movements. Physical examination is notable for oral temperature of 38.9°C, heart rate 120 beats per minute, and blood pressure 100/86 mm Hg. The patient has leukocyte count of 19,000/mm^3, serum Na^+ of 128 mEq/dL, K^+ of 3.0 mEq/dL and computed tomography scan shows fistulous communication with the right ureter and a pericolic abscess. He is administered a dose of levofloxacin intravenously, upon which the patient goes into cardiopulmonary arrest. The fatal arrhythmia is caused by:

(A) Accessory conduction pathway
(B) After-depolarization
(C) Enhanced automaticity
(D) Premature repolarization
(E) Re-entrant rhythm

Answer: (B) After-depolarization

Rationale:

This patient, who has a urinary tract infection (UTI) from a coloureteral fistula, has several risk factors for development of QT prolongation and Torsade de pointes. Torsade de pointes is believed to arise from early after-depolarization initiated by a premature ventricular beat or salvo of ventricular beats, followed by a pause and then a supraventricular beat. Another premature ventricular beat arrives at a short coupling interval and falls on the preceding T wave, precipitating the rhythm.

Quinolones are widely used for treatment of UTI and prolongation of the QT interval is an adverse effect associated with the use of fluoroquinolones. Anecdotally, moxifloxacin carries the greatest risk of QT prolongation from all available quinolones. Although levofloxacin and ofloxacin are associated with a lower risk of QT prolongation compared with moxifloxacin, they should also be used with caution in patients with risk factors for QT prolongation. Ciprofloxacin appears to be associated with the lowest risk for QT prolongation and the lowest rate of Torsade de pointes. Hypokalemia can also cause lengthening of the QT interval.

Reference:

Calkins H. Chapter 61: Principles of electrophysiology. In: Goldman L, Schafer A, eds. *Cecil Textbook of Medicine.* 24th ed. Philadelphia, PA: W.B. Saunders; 2011. Accessed October 12, 2011. Online Edition.

۰۲۱-۶۶۱۹۸۵۱۴ www.myuptodate.com دریافت آخرین نسخه آپتودیت آفلاین

1B33

Key word: Most Common Hepatic Artery Variants

Author: Trevor A. Ellison, MD, MBA
Editor: Frederick E. Eckhauser, MD, FACS

While performing a hepatic resection, you note that the left hepatic artery does not originate from the proper hepatic artery. Anatomically, what is the most likely origin of this anomalous takeoff of the left hepatic artery?

(A) Common hepatic artery
(B) Gastroduodenal artery
(C) Left gastric artery
(D) Right hepatic artery
(E) Superior mesenteric artery

Answer: (C) Left gastric artery

Rationale:
In 15% to 20% of the general population, the right hepatic artery has its origin in the superior mesenteric artery (called an accessory if in addition or replaced right hepatic artery if solitary) and passes behind the head of the pancreas on its way into the liver. It is important to note the prevalence of this variant to avoid inadvertent division of a replaced right hepatic artery and subsequent right-sided liver injury.

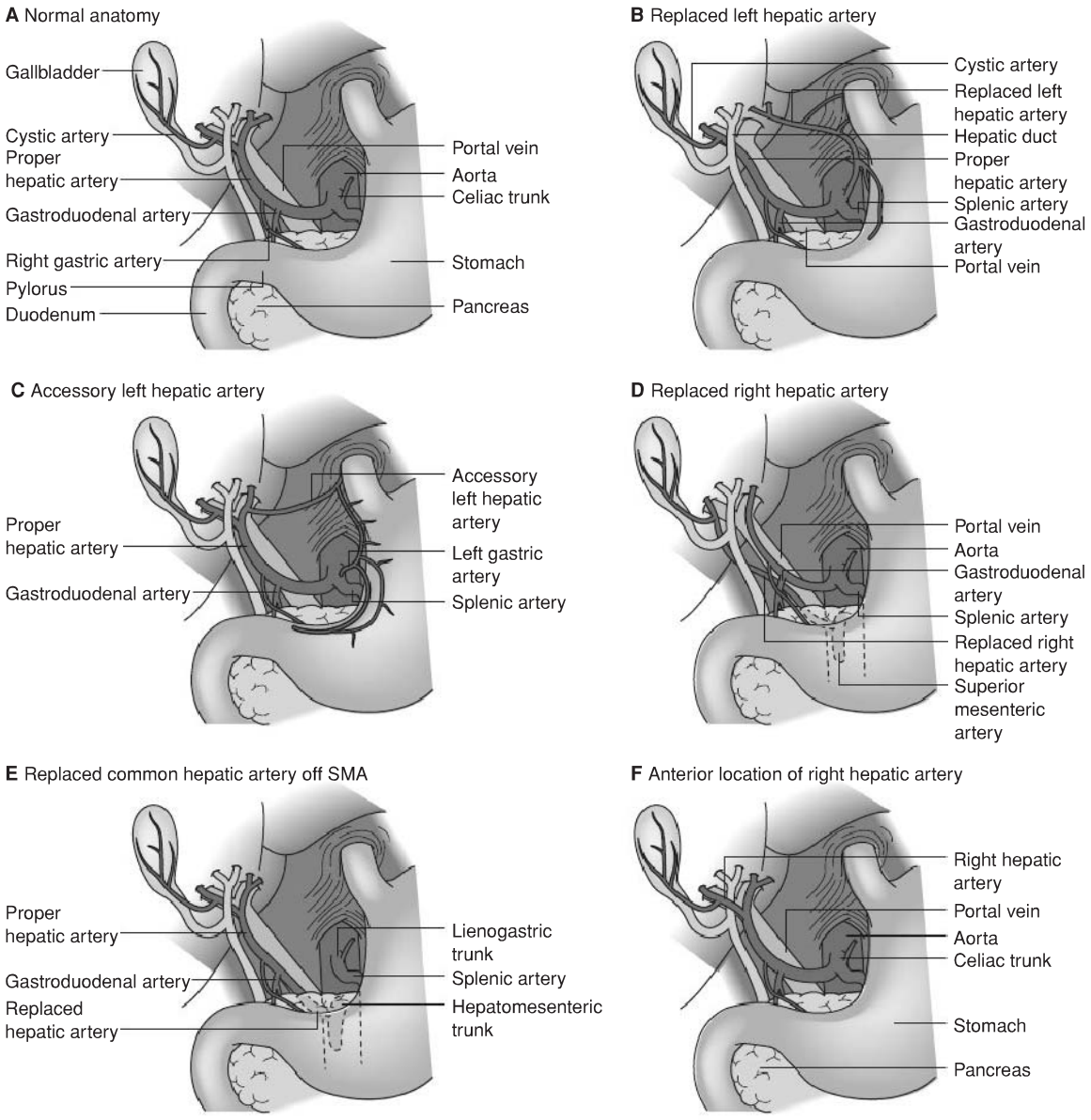

Variations in hepatic arterial anatomy. Reprinted with permission from: Schulick RD. Hepatobiliary anatomy. In: Mulholland MW, Lillemoe KD, Doherty GM, Maier RV, Upchurch GR, eds. *Greenfield's Surgery: Scientific Principles & Practice*. 5th ed. Philadelphia, PA: Lippincott Williams & Wilkins, 2011:877.

۰۲۱-۶۶۱۹۸۵۱۴ www.myuptodate.com دریافت آخرین نسخه آپتودیت آفلاین

In 10% to 15% of the general population, the left hepatic artery has its origin in the left gastric artery (called an accessory or replaced left hepatic artery, as above). Again, it is important to be cognizant of this variant in the operative setting so that inadvertent damage to the left side of the liver by indiscriminant division of a replaced left hepatic artery is avoided.

The most prevalent anatomy, shared by 55% of the general population, is a common hepatic artery that arises distal to the takeoff of the gastroduodenal artery, becomes the proper hepatic artery, and gives off the cystic artery, followed by the right, middle, and left hepatic arteries. It is salient to remember there is great variation to this anatomy.

References:

Michels NA. Newer anatomy of the liver and its variant blood supply and collateral circulation. *Am J Surg.* 1966; 112(3):337–347.

Schulick RD. Hepatobiliary anatomy. In: Mulholland MW, Lillemoe KD, Doherty GM, Maier RV, Upchurch GR, eds. *Greenfield's Surgery: Scientific Principles & Practice.* 5th ed. Philadelphia, PA: Lippincott Williams & Wilkins; 2011.

1B34

Key word: Hemodynamic Findings in Septic Shock

Author: Susanna M. Nazarian, MD, PhD
Editors: Edward E. Cornwell III, MD, FACS, WACS, FCCM, and Albert Chi, MD

You are caring for a 27-year-old man in the intensive care unit who sustained multiple abdominal gunshot wounds and is postoperative day 3 from extensive bowel resections, and has an open abdomen following the heavily contaminated procedure. He has a pulmonary artery catheter and has developed a depressed systemic blood pressure despite resuscitation to 10 kg above his baseline weight. Which pulmonary artery findings would support your suspicion of hyperdynamic septic shock?

Key:

CVP = central venous pressure

PCWP = pulmonary capillary wedge pressure

CO = cardiac output

SVR = systemic vascular resistance

SvO_2 = mixed venous oxygen saturation

(A) CVP/PCWP, ⇓ CO, ⇑ SVR, ⇓ SvO_2

(B) CVP/PCWP, ⇓ CO, ⇑ SVR, ⇓ SvO_2

(C) CVP/PCWP, ⇓ CO, ⇓ SVR, ⇓ SvO_2

(D) ⇑ or ⇓ CVP/PCWP, ⇓ CO, ⇑ SVR, ⇑ or ⇓ SvO_2

(E) ⇑ or ⇓ CVP/PCWP, ⇑ CO, ⇓ SVR, ⇑ SvO_2

Answer: (E) ⇑ or ⇓ CVP/PCWP, ⇑ CO, ⇓ SVR, ⇑ SvO_2

Rationale:

Shock is the insufficient delivery of oxygenated blood to tissues at the cellular level. In hyperdynamic (or early) septic shock, the peripheral vasculature dilates secondary to inflammatory cytokines. The SVR falls markedly, leaving little after-load and

Hemodynamic Patterns in Shock

Type	CO	SVR	PAOP	CVP	SvO_2
Hypovolemic	↓	↑	↓	↓	↓
Cardiogenic					
Left ventricular MI	↓	↑	↑	N, ↑	↓
Right ventricular MI	↓	↑	N, ↓	↑	↓
Extracardiac obstructive					
Pericardial tamponade	↓	↑	↑	↑	↓
Pulmonary embolism	↓	↑	↑	↑	↓
Distributive					
Early	↑, N, ↓	↑, N, ↓	N	N, ↑	N, ↑
Early after fluid administration	↑	↓	N, ↑	N, ↑	↑, N, ↓
Late	↓	↑	N	N	↓

CO, cardiac output; CVP, central venous pressure; MI, myocardial infarction; N, normal; PAOP, pulmonary artery occlusion pressure; SvO_2, mixed venous oxygen saturation; SVR, systemic vascular resistance.

Reprinted with permission from: Cuschieri J. Shock. In: Mulholland MW, Lillemoe KD, Doherty GM, Maier RV, Upchurch GR, eds. *Greenfield's Surgery: Scientific Principles & Practice*. 5th ed. Philadelphia, PA: Lippincott Williams & Wilkins, 2011:151.

۰۲۱-۶۶۱۹۸۵۱۴ www.myuptodate.com دریافت آخرین نسخه آپتودیت آفلاین

a hyperdynamic myocardium. The CO, defined as L blood/minute, consequently rises. Given decreased venous return, preload falls as represented by lower CVP/PCWP. Finally, due to bacterial toxins such as lipopolysaccharide (LPS) and innate inflammatory products, cells in shock are less efficient at extracting the oxygen from the blood. As a consequence, the mixed venous oxygen saturation (SvO_2) rises.

The alternate answer options given represent the pulmonary artery catheter findings for different types of shock. Option **(A)** would be seen in hypovolemic shock; option **(B)** in cardiogenic shock; option **(D)** in hypodynamic septic shock; and option **(E)** in neurogenic shock. Hypodynamic (or late) septic shock follows hyperdynamic septic shock, and is characterized by vasoconstriction, impaired myocardial contractility, hypotension, oliguria, and mottled extremities.

Reference:

Cuschieri J. Shock. In: Mulholland MW, Lillemoe KD, Doherty GM, Maier RV, Upchurch GR, eds. *Greenfield's Surgery: Scientific Principles & Practice.* 5th ed. Philadelphia, PA: Lippincott Williams & Wilkins; 2011.

1B35

Key word: Prevention of Surgical Site Infections

Author: Susanna M. Nazarian, MD, PhD
Editor: Frederick E. Eckhauser, MD, FACS

One night after undergoing an open gastric bypass procedure, a 45-year-old, 158.76-kg (350-lb) man had an isolated temperature spike to 38°C. Over the following 3 days, he was afebrile. This morning, on postoperative day 4, his pulse rate is 100 and blood pressure is 95/60, which is lower than his normal 120/70. His wound appears slightly erythematous and is more tender to palpation than yesterday. He admits to feeling slightly unwell. How might this complication have been avoided?

(A) Continue prophylactic antibiotics for 48 hours postoperatively

(B) Maintain tight glucose control following surgery

(C) Remove his Foley catheter on postoperative day 1

(D) Shave his abdomen prior to surgery

(E) Wash the abdominal cavity with antibiotic solution prior to closure during surgery

Answer: (B) Maintain tight glucose control following surgery

Rationale:

This patient likely has a surgical site infection (SSI), which can be more difficult to diagnose in morbidly obese patients. SSI includes all infections occurring at the operative site. A gastric bypass procedure is classified as a clean–contaminated procedure:

Wound Classification

Class	Definition
Clean	An uninfected operative wound in which no inflammation is encountered and the respiratory, alimentary, genital, or infected urinary tract is not entered. In addition, clean wounds are closed primarily
Clean-contaminated	An operative wound in which the respiratory, alimentary, genital, or urinary tracts are entered under controlled conditions and without unusual contamination
Contaminated	Open, fresh, accidental wounds. Operations with major breaks in sterile technique or gross spillage from the gastrointestinal tract, and incisions in which acute, nonpurulent inflammation is encountered
Dirty	Old traumatic wounds with retained devitalized tissue and those that involve existing clinical infection or perforated viscera

Reprinted with permission from: Dellinger EP. Surgical infections. In: Mulholland MW, Lillemoe KD, Doherty GM, Maier RV, Upchurch GR, eds. *Greenfield's Surgery: Scientific Principles & Practice.* 5th ed. Philadelphia, PA: Lippincott Williams & Wilkins, 2011:134.

۰۲۱-۶۶۱۹۸۵۱۴ www.myuptodate.com دریافت آخرین نسخه آپتودیت آفلاین

However, a more accurate method of classifying wound risk for infection is the National Nosocomial Infection Surveillance System (NNIS). In this classification system, one point is awarded for each of the following: (a) Contaminated or dirty wound; (b) American Society of Anesthesiologists (ASA) class 3 or higher; (c) duration of operation exceeding the 75th percentile for that operation.

Comparison of Wound Classification and NNIS System for Evaluating Risk of Surgical Site Infection

	NNIS Risk Index				
Wound Class	**0**	**1**	**2**	**3**	**All**
Clean	1.0	2.3	5.4	—	2.1
Clean-contaminated	2.1	4.0	9.5	—	3.3
Contaminated	—	3.4	6.8	13.2	6.4
Dirty	—	3.1	8.1	12.8	7.1
All	1.5	2.9	6.8	13.0	2.8
Maximum ratio[a]	2.1	1.7	1.8	1.0	

NNIS, National Nosocomial Infection Surveillance System.

[a]Ratio of lowest to highest infection rate in wound class or in risk index.

Adapted from: Dellinger EP, Ehrenkranz NJ, Jarvis WR, Surgical site infections. In: Jarvis WR, ed. *Bennett & Brachman's Hospital Infections*. 5th ed. Philadelphia, PA: Wolters Kluwer Health/Lippincott Williams & Wilkins; 2007:583–598.

The Hospital Infection Control Practices Advisory Committee of the Center for Disease Control has produced a set of category 1 recommendations to reduce SSIs.

Category 1 Recommendations from the Hospital Infection Control Practices Advisory Committee for the Prevention of Surgical Site Infections

- Do not operate on patients with active infections.
- Do not shave patient in advance.
- Control glucose in diabetic patients.
- Stop tobacco use in patient.
- Have patient shower with antiseptic soap.
- Prepare skin with appropriate agent.
- Surgeon's nails should be short.
- Surgeons scrub hands.
- Exclude infected surgeons.
- Give prophylactic antibiotics when indicated.
- Maintain prophylactic antibiotic levels during operation.
- Keep operating room doors closed.
- Use sterile instruments.
- Avoid flash sterilization.
- Wear a mask.[a]
- Cover all hair.[a]
- Wear sterile gloves.[a]
- Use gowns and drapes that resist fluid penetration.
- Handle tissue gently.
- Use closed suction drains (when used).
- Delay primary closure for heavily contaminated wounds.
- Use sterile dressing for 24–48 h.
- Use CDC definitions for SSI.
- Watch for SSI and give feedback to surgeons.

CDC, Centers for Disease Control and Prevention; SSI, surgical site infection.

[a]These items are required by Occupational Safety and Health Administration (OSHA) regulations and are not actually supported by class 1 data.

From: Mangram AJ, Horan TC, Pearson ML, et al. Guideline for prevention of surgical site infection, 1999. Hospital Infection Control Practices Advisory Committee. *Infect Control Hosp Epidemiol.* 1999;20:250–278, with permission.

These recommendations include glucose control.

Other measures that can decrease rates of SSIs include temperature control, antibiotic prophylaxis, and not shaving the patient. Two recent prospective trials have demonstrated reduced rates of SSI in patients who were actively warmed during their operations. Prophylactic antibiotics are indicated for all gastrointestinal, obstetrical, gynecologic, oropharyngeal, vascular (abdominal and leg), and open-heart procedures. The use of prophylactic antibiotics in clean procedures remains controversial since the baseline infection rate is low in these cases. Much controversy has existed surrounding the length of time to maintain antibiotic prophylaxis. However, numerous trials have demonstrated no additional benefit of maintaining treatment doses beyond the operating room. At present, the Center for Medicare and Medicaid Services recommends continuing antibiotic coverage for not more than 24 hours after surgery. Prolongation beyond this time frame risks the development of antibiotic resistance without additional prophylactic benefit. Clipping the hair at the surgical site rather than shaving it reduces infection.

Reference:

Dellinger EP. Surgical infections. In: Mulholland MW, Lillemoe KD, Doherty GM, Maier RV, Upchurch GR, eds. *Greenfield's Surgery: Scientific Principles & Practice.* 5th ed. Philadelphia, PA: Lippincott Williams & Wilkins; 2011.

۰۲۱-۶۶۱۹۸۵۱۴ www.myuptodate.com دریافت آخرین نسخه آپتودیت آفلاین

1B36

Key word: Reduction of Nosocomial Infection on Ventilator

Author: Robert A. Meguid, MD, MPH
Editor: Elliott R. Haut, MD, FACS

The chest x-ray of a 68-year-old intubated man in the surgical intensive care unit reveals an infiltrate in his right lower lobe. Concurrent with this finding, the patient has an elevated leukocyte count and increased endotracheal secretions. Which of the following procedures would have been most effective in preventing ventilator-associated pneumonia (VAP)?

(A) Elevation of the head of bed above 30 degrees

(B) Initiation of ranitidine

(C) Replacement of nasogastric tube with nasoduodenal tube for postpyloric enteral feeding

(D) Selective decontamination of the digestive tract

(E) Use of prophylactic topical antibiotics (intratracheal or oral)

Answer: **(A)** Elevation of the head of bed above 30 degrees

Rationale:

After urinary tract infection and surgical site infection, pneumonia is the most common postoperative infection. However, pneumonia accounts for the majority of nosocomial infections in intensive care unit patients. The pathogenesis of VAP is thought primarily to be initiated with overgrowth of oropharyngeal flora, followed by aspiration of these microbes into the lungs. The colonizing bacteria are a combination of endogenous and exogenous flora.

Evidence-based factors that reduce the likelihood of developing VAP include minimizing duration of intubation, practice of barrier techniques by staff attending to and contacting patients, elevating the head of the bed above 30 degrees, and adequate drainage of subglottic secretions. In addition, orotracheal intubation is associated with a lower risk of VAP than nasotracheal intubation, likely due to the increased risk of sinusitis in nasotracheally intubated patients. Improved oral hygiene through tooth brushing and frequent assessment is also associated with reduced risk of VAP.

While H_2 receptor blockers (e.g., ranitidine) decrease the rate of gastrointestinal bleeding, they are not clinically effective in reducing the rate of VAP through reduction of bacterial overgrowth. The frequency of ventilator circuit changes does not influence the incidence of VAP. Ventilator circuits should be changed for each new patient but thereafter only changed in the event of soilage; similar guidelines apply for closed endotracheal suction systems. The use of heat and moisture exchangers may slightly decrease the incidence of VAP compared with heated humidifiers.

Selective decontamination of the digestive tract entails systemic and topical use of antibiotics to minimize colonization and translocation of bacteria from the gut. Selective decontamination has not found wide acceptance in the United States due to concerns for promoting antibiotic-resistant bacteria. The studies supporting selective decontamination were performed in ICUs with low levels of antibiotic-resistant microbes, and resulted in increase in development of antibiotic-resistant microbes. Only the combination of intravenous and topical antibiotics has been shown to decrease mortality.

Gastric over-distension is associated with increased risk of aspiration. However, use of postpyloric enteral feeding has not been shown to definitively decrease the risk of pneumonia in intubated patients as compared to gastric enteral feeding.

References:

Berenholtz SM, Pham JC, Thompson DA, et al. Collaborative cohort study of an intervention to reduce ventilator-associated pneumonia in the intensive care unit. *Infect Control Hosp Epidemiol.* 2011;32(4):305–314.

Dodek P, Kennan S, Cook D, et al. Evidence-based clinical practice guideline for the prevention of ventilator-associated pneumonia. *Ann Intern Med.* 2004;141(4):305–313.

Drakulovic MB, Torres A, Bauer TT, et al. Supine body position as a risk factor for nosocomial pneumonia in mechanically ventilated patients: A randomised trial. *Lancet.* 1999; 354(9193):1851–1858.

Marino PL. Principles of mechanical ventilation. *The ICU Book.* 3rd ed. Philadelphia, PA: Lippincott Williams & Wilkins; 2007:457–471.

۰۲۱-۶۶۱۹۸۵۱۴ www.myuptodate.com دریافت آخرین نسخه آپتودیت آفلاین

1B37

Key word: Findings Associated with Hypomagnesemia

Author: Eric S. Weiss, MD, MPH
Editor: David T. Efron, MD, FACS

A 68-year-old retired construction worker is admitted to the intensive care unit (ICU) with severe acute pancreatitis. From discussions with his family it is learned that he drinks several glasses of beer and other alcoholic beverages daily. In the course of his resuscitation, he receives approximately 20 L of intravenous fluid. By hospital day 6 he has regained hemodynamic stability and begins to mobilize volume with the aid of furosemide. After a brisk diuresis of 6 L, the covering ICU physician is called to the patient's room because he has developed a substantial tremor, hyperreflexia, and mental status changes. A serum electrolyte panel demonstrates low potassium. What additional electrolyte is likely to be decreased in this patient?

(A) Calcium
(B) Chloride
(C) Magnesium
(D) Phosphorus
(E) Sodium

Answer: (C) Magnesium

Rationale:

Disorders of magnesium balance are frequently encountered by physicians who treat patients in the ICU. In particular, magnesium depletion affects up to 65% of patients in the ICU. Common predisposing conditions include diuretic therapy with loop diuretics, chronic alcohol abuse, diarrhea, antibiotics such as amphotericin or aminoglycosides, and additional drugs such as digitalis, cyclosporine, or cisplatin. The patient presented here is very likely to have low magnesium because of his history of alcohol abuse and massive postresuscitation diuresis. The two most significant clinical manifestations of low magnesium are cardiac arrhythmias; including Torsade de pointes and neurologic derangements, including seizures, ataxia, slurred speech, tremors, and gait disturbances. Treatment is aimed at correcting magnesium deficits by administering intravenous magnesium sulfate in a solution of 8 mEq/g.

Reference:

Marino PL. Magnesium. *The ICU Book.* 3rd ed. Philadelphia, PA: Lippincott Williams & Wilkins; 2007:625–638.

1B38

Key word: Bacteriology of Human Bites

Author: Trevor A. Ellison, MD, MBA
Editors: Edward E. Cornwell III, MD, FACS, WACS, FCCM, and Albert Chi, MD

A 4-year-old girl is brought into the emergency department from preschool after being bitten by a classmate. The bite is on her forearm and is clean with no signs of devitalized tissue. The wound is copiously irrigated and primarily closed. Cultures of the wound taken prior to irrigation are most likely to reveal which bacteria?

(A) *Eikenella corrodens*
(B) Fusobacterium species
(C) *Pasteurella multocida*
(D) Prevotella species
(E) *Staphylococcus aureus*

Answer: (E) *Staphylococcus aureus*

Rationale:

The most common bacteria found in human bites are *S. aureus, Staphylococcus epidermidis,* alpha- and beta-hemolytic Streptococcus species, Corynebacterium species, and *E. corrodens.*

Human bites are divided into occlusional bites, in which the teeth puncture the skin, and clenched-fist injuries where the hand hits the teeth causing a wound. Occlusional injuries share the same risk of infection as dog and cat bites, except when the bite is on the hand— in which case the risk for infection is higher. Clenched-fist injuries are at a much higher risk of infection and can lead to septic arthritis and osteomyelitis. *E. corrodens* infects up to 25% of clenched-fist injuries and can lead to a chronic, indolent infection. Human bites are polymicrobial and have an average of five different anaerobic/aerobic bacteria in the wound—significantly more than in dog or cat bites. This finding has been attributed to the fact that humans have a higher concentration of intraoral bacteria than do dogs and cats. In addition, human bites have a higher percentage of Bacteroides species than dog and cat bites as well as a higher proportion of bacteria that produce beta-lactamases. In addition to the bacterial component, human bites are also able to transmit Hepatitis B, Hepatitis C, *Mycobacterium tuberculosis,* and possibly HIV. Treatment is thorough irrigation and cleaning with 1% povidone-iodine, which is both bactericidal as well as viricidal. If the bite in question is located on an extremity, the limb should be elevated and immobilized. Broad-spectrum antibiotics should be given for all hand injuries and those at increased risk for infection. Admission to the hospital for intravenous antibiotics should be accomplished for those with systemic manifestations of infection. A tetanus booster is appropriate when indicated.

Regarding animal bites, 80% to 90% of all animal bites are from dogs, 3% to 15% are from cats, and only 1% to 2% are from nondomestic animals. These bites are often polymicrobial and should be treated with a 3- to 5-day course of broad-spectrum antibiotics if the injury is on the hand or if the person has risk factors that place them at increased risk

۰۲۱-۶۶۱۹۸۵۱۴ www.myuptodate.com دریافت آخرین نسخه آپتودیت آفلاین

for wound infection. The injuries themselves should be copiously irrigated and debrided if necessary with primary closure if the wound is treated in less than 12 hours from the event, is not on the hand, and is not a cat bite. The most common pathogen is *P. multocida* (50% to 80% of cat bites and 25% of dog bites). A rare bacterium that is especially destructive in immunocompromised patients is *Capnocytophaga canimorsus,* which leads to overwhelming sepsis and death in 25% to 30% of patients. A list of the most common aerobes includes *P. multocida,* Corynebacterium species, Staphylcoccus species, Streptococcus species, and *C. canimorsus.* A list of the most common anaerobes includes Bacteroides species, Prevotella species, Porphyromonas species, Peptostreptococci, Fusobacterium species, *Bacteroides fragilis,* and *Veillonella parvula.*

References:

Malangoni MA. Soft tissue infection. In: Souba WW, Fink MP, Jurkovich GJ, Kaiser LR, Pearce WH, Pemberton JH, Soper NJ, eds. *ACS Surgery: Principles and Practice.* 5th ed. New York, NY: WebMD; 2005: 221–222.

Thomas N, Brook I. Animal bite-associated infections: Microbiology and treatment. *Expert Rev Anti Infect Ther.* 2011; 9(2):215–226.

1B39

Key word: Hyperacute Rejection of Renal Transplants

Author: Justin B. Maxhimer, MD
Editors: Robert A. Montgomery, MD, DPhil, FACS, and Dorry L. Segev, MD, PhD

A 43-year-old male with end-stage renal disease secondary to type II diabetes underwent a deceased donor kidney transplant. Intraoperatively, the allograft became grossly mottled and cyanotic. The surgeon noted capsular bulging due to marked edema, followed by graft rupture. What is the most likely pathophysiology behind this graft failure?

(A) Acute thrombosis of the renal vein

(B) Presence of antibodies directed toward donor ABO blood group antigens

(C) Presence of recipient HLA class I antigens

(D) Sensitized T cells to donor antigens

(E) Stenosis or kinking of the renal artery

Answer: (B) Presence of antibodies directed toward donor ABO blood group antigens

Rationale:

Hyperacute rejection of the kidney generally occurs immediately after reperfusion and results from preformed donor-specific antibodies. Hyperacute rejection is not salvageable and is treated with allograft removal. Although, as a general process, antibody-mediated rejection can occur at any time after transplantation and results from ongoing production of antibody directed against donor antigens, the specific process of hyperacute rejection results from preformed antibodies and occurs immediately. Histologically, hyperacute rejection is characterized by widespread glomerular capillary thrombosis and necrosis. Frequent areas of interstitial hemorrhage are noted as well. Antibody-mediated rejection may be more subtle and diagnostic criteria include margination of neutrophils and diffuse C4d staining in the peritubular capillaries.

In addition to antibodies to the ABO blood group, anti-human leukocyte antigen (anti-HLA) antibodies can also cause hyperacute rejection; these develop as a result of a prior exposure of the recipient to donor antigens from blood transfusions, pregnancies, or previous transplants. If the strength or presence of these antibodies has waned, a few days or even weeks may elapse before an amnestic immune response can develop. Antibody-mediated rejection in such cases may be somewhat delayed, less severe, and sometimes treatable with plasmapheresis or other agents that either reduce antibody formation or effector arms. HLA and endothelium-associated donor antigens are the usual target for antibody-mediated rejection.

۰۲۱-۶۶۱۹۸۵۱۴ www.myuptodate.com دریافت آخرین نسخه آپتودیت آفلاین

References:
Montgomery RA, Zachary AA, Racusen LC, et al. Plasmapheresis and intravenous immune globulin provides effective rescue therapy for refractory humoral rejection and allows kidneys to be successfully transplanted into cross-match-positive recipients. *Transplantation.* 2000;70(6):887–895.
Porter KA. Renal transplantation. In: Heptinstall RH, ed. *Pathology of the Kidney.* 4th ed. Boston, MA: Little Brown and Co.; 1992:1799–1934.
Trpkov K, Campbell P, Pazderka F, et al. Pathologic features of acute renal allograft rejection associated with donor-specific antibody: Analysis using the Banff grading schema. *Transplantation.* 1996;61(11):1586–1592.

1B40

Key word: Mechanism of Altered Immunity Postsplenectomy

Authors: Robert A. Meguid, MD, MPH, and Susanna M. Nazarian, MD, PhD
Editor: Mark D. Duncan, MD, FACS

After being struck by a moving truck, a 23-year-old woman undergoes splenectomy during diagnostic laparotomy. She leaves the hospital against medical advice on postoperative day 4, after refusing vaccination. Infection with which of the following organisms is most likely to result in her developing sepsis?

(A) Beta-hemolytic streptococcus
(B) *Candida albicans*
(C) *Clostridium difficile*
(D) *Escherichia coli*
(E) *Pseudomonas aeruginosa*

Answer: (A) Beta-hemolytic streptococcus

Rationale:
The spleen is a secondary organ of the immune system. Encapsulated pathogens are opsonized and then cleared from circulation by the spleen. Therefore, asplenic patients are primarily at risk of overwhelming postsplenectomy infection (OPSI) caused by encapsulated organisms.

Asplenic adults are at 40% to 60% greater risk of sepsis as compared to normosplenic adults. However, the risk of OPSI in adult trauma patients is less than 1% in comparison to the higher rates seen in patients undergoing splenectomy for hematologic disease. The risk and impact of OPSI is inversely related to age. In 80% of cases, OPSI occurs within the first 2 years after splenectomy. The risk of OPSI is further increased in asplenic patients with malignancy, hematological disorders such as thalassemia, or the immunosuppressed (e.g., those undergoing chemotherapy). Overall, OPSI has a 50% to 60% mortality rate.

The most common organisms that cause OPSI are as follows, in order of decreasing frequency.

1. *Streptococcus pneumoniae*
2. *Haemophilus influenzae*
3. *Neisseria meningitides*
4. β–hemolytic streptococcus
5. *Staphylococcus aureus*
6. *E. coli*
7. Pseudomonas species

Guidelines for reduction of the risk of OPSI focus on immunization of patients undergoing elective splenectomy with polyvalent pneumococcal vaccine 10 to 14 days prior to surgery. Those undergoing splenectomy for trauma should receive the immunization 14 days postoperatively. Booster immunization is recommended every 3 years. In addition, vaccination with the polyvalent vaccines for *H. influenzae* type B, meningococcus and annually for influenza is recommended

۰۲۱-۶۶۱۹۸۵۱۴ www.myuptodate.com دریافت آخرین نسخه آپتودیت آفلاین

and mandated for immunosuppressed patients and those less than 10 years of age. Antibiotic prophylaxis should be administered prior to instrumentation, such as dental work.

Patient education is important following splenectomy. Asplenic patients should be encouraged to carry identification cards to alert health care workers and should be advised to take every sign of early infection very seriously.

Guidelines for Prevention of Postsplenic Sepsis

- Vaccinate with polyvalent pneumococcal vaccine at least 10–14 days prior to splenectomy, if possible
- If splenectomy is urgent, wait until at least 14 days postprocedure to vaccinate
- For high-risk patients (immunosuppressed, children <10 years of age), meningococcal vaccine and *Haemophilus influenza* vaccine
- Antibiotic prophylaxis for children <5 years of age
- Early antibiotic treatment for initial signs of infection
- Medi-Alert bracelet

Reprinted with permission from: Fraker DL. The spleen. In: Mulholland MW, Lillemoe KD, Doherty GM, Maier RV, Upchurch GR, eds. *Greenfield's Surgery: Scientific Principles & Practice*. 5th ed. Philadelphia, PA: Lippincott Williams & Wilkins; 2011:1218.

References:

Fraker DL. The spleen. In: Mulholland MW, Lillemoe KD, Doherty GM, Maier RV, Upchurch GR, eds. *Greenfield's Surgery: Scientific Principles & Practice.* 5th ed. Philadelphia, PA: Lippincott Williams & Wilkins; 2011.

Gilbert DN, Moellering RC, Eliopoulos GM, et al. *The Sanford Guide to Antimicrobial Therapy 2005.* 35th ed. Hyde Park: Antimicrobial Therapy; 2005:140.

Reihner E, Brismar B. Management of splenic trauma—changing concepts. *Eur J Emerg Med.* 1995;2(1):47–51.

1B41

Key word: Most Abundant Fecal Bacterial Flora

Author: Robert A. Meguid, MD, MPH
Editor: Anne O. Lidor, MD, MPH

After sustaining a gunshot wound to the abdomen, a 24-year-old man is brought to the operating room. During exploratory laparotomy, you find gross contamination of the peritoneum by feces resulting from multiple sigmoid colonic enterotomies. Which of the following species of bacteria is the most abundant in feces?

(A) *Bacteroides vulgatus*
(B) *Enterococcus faecalis*
(C) *Escherichia coli*
(D) *Klebsiella pneumoniae*
(E) *Pseudomonas aeruginosa*

Answer: (A) *Bacteroides vulgatus*

Rationale:

Of the 25 most common species of bacteria found in fecal flora, none is a clinically important pathogen. The most abundant bacterium found in feces is *B. vulgatus,* which comprises approximately 12% of fecal bacteria. In contrast, *E. coli,* Klebsiella, and *E. faecalis,* along with about 40 other species, make up only 0.06%. In the colon, anaerobes outnumber aerobic bacteria 1,000:1. It is important to consider this in immunocompromised patients in which bacterial translocation has occurred, where enteric flora may be the source of sepsis.

Reference:

Simmons RL, Kispert PH. Infection and host defences. In: Simmons RL, Steed DL, eds. *Basic Science Review for Surgeons.* St. Louis, MO: W.B. Saunders; 1992:61–62.

۰۲۱-۶۶۱۹۸۵۱۴ www.myuptodate.com دریافت آخرین نسخه آپتودیت آفلاین

1B42

Key word: Laboratory Values Abnormal with von Willebrand Disease

Author: Susanna M. Nazarian, MD, PhD
Editor: David T. Efron, MD, FACS

A 40-year-old woman with type I von Willebrand disease (vWD) presents for an elective cholecystectomy. What precautions should the surgical and anesthesia team take, and why?

(A) Administer a dose of IV Vitamin K the night prior to surgery for the anticipated elevated INR

(B) Ensure adequate fresh frozen plasma is ordered for the anticipated elevated INR

(C) Have desmopressin (DDAVP) available to reverse the platelet dysfunction

(D) Have recombinant factor VIII available for a deficiency in this clotting factor

(E) Type and cross 4 units of packed red blood cells for the congenital anemia

Answer: (C) Have desmopressin (DDAVP) available to reverse the platelet dysfunction

Rationale:

vWD is an inherited disease of platelet dysfunction. Normally, platelets release von Willebrand factor (vWF) along with thrombospondin, fibrinogen, ADP, ATP, serotonin, and other procoagulants upon degranulation. This degranulation (and the preceding morphologic change) of the platelets is prompted by platelet agonists such as ATP, ADP, epinephrine, thromboxane A_2, and collagen and thrombin exposure. Upon degranulation, the platelets attach to the exposed endothelium via binding of vWF to the glycoprotein Ib-IX-V complex.

A history of mucosal bleeding may serve as a clue to vWD. There are three subtypes of vWD: Type I in which function vWF is present at reduced concentrations, type II in which the vWF is dysfunctional, and type III in which the vWF is absent altogether. Types I and II are inherited in an autosomal dominant pattern, while type III follows recessive inheritance. The prothrombin times (PT) and partial thromboplastin times (PTT) in patients with vWD may be normal, or the PTT may be slightly elevated.

Perioperative treatment of vWD differs by disease type. Type I may be treated by administration of DDAVP, a synthetic analog of vasopressin. Although its mechanism is incompletely understood, DDAVP induces an increase in plasma levels of vWF via activation of the endothelial vasopressin V2R receptor, leading to exocytosis of vWF from the Weibel Palade bodies. Since its action relies on the release of endogenous vWF, DDAVP is not effective in Type II (defective vWF) or Type III disease (absent vWF).

A test dose of DDAVP is necessary prior to administration of the full dose, as rare severe allergic reactions have been reported, including anaphylaxis. More common side effects include transient headache, nausea, mild abdominal pain, facial flushing, and injection site erythema, swelling or burning pain. In major surgery, patients with type I vWD disease should also receive a concentrate of vWF and Factor VIII.

Factor VIII cryoprecipitate with vWF is indicated for patients with Type III vWD, for some forms of Type II vWD, and for major bleeding or surgery in all types of vWD. Cryoprecipitate is made from pooled extracts of human plasma.

References:

Kaufmann JE, Vischer UM. Cellular mechanisms of the hemostatic effects of desmopressin (DDAVP). *J Thromb Haemost.* 2003;1(4):682–689.

Owings JT, Gosselin RC. Bleeding and transfusion. In: Souba WW, Fink MP, Jurkovich GJ, Kaiser LR, Pearce WH, Pemberton JH, Soper NJ, eds. *ACS Surgery: Principles and Practice.* New York, NY: WebMD; 2011.

۰۲۱-۶۶۱۹۸۵۱۴ www.myuptodate.com دریافت آخرین نسخه آپتودیت آفلاین

1B43

Key word: Increased Bacterial Infection in Newborns versus Adults

Author: Susanna M. Nazarian, MD, PhD
Editor: Nicole M. Chandler, MD

You are called to the neonatal intensive care unit to see a full-term neonate with suspected malrotation. The baby's nurse reminds you of the importance of washing your hands thoroughly before touching the child. Why is this of particular importance?

(A) It is unknown whether the child has HIV and he may be immunosuppressed

(B) Neonatal neutrophils have impaired chemotaxis

(C) Neonates have weak coughs and are unable to clear their secretions

(D) Newborn lungs lack IgA in the mucosal barrier to protect against airborne pathogens

(E) Newborns have immature immune systems because their T cells have not fully differentiated and remain within their thymus

Answer: (B) Neonatal neutrophils have impaired chemotaxis

Rationale:
The neonatal immune system is not yet mature, rendering even full-term neonates uniquely susceptible to infection. There is only a limited supply of available granulocytes in the neonatal bone marrow and the shift to a predominance of phagocytic cells is less rapid in neonates compared with older children. At the cellular level, neonatal neutrophils exhibit impaired chemotaxis and migration. Newborns are particularly susceptible to cutaneous infections, for example, infection at circumcision sites, the umbilicus or intertriginous areas by *Staphylococcus aureus,* Candida species, or gram-negative rod bacteria. Some postulate that the propensity of neonates to develop systemic infection from native flora of the gastrointestinal or respiratory tract may be due to the incomplete infiltration of innate immune cells into the neonatal submucosal tissues.

Reference:
Smith CW, Mariscalco MM. Functional disorders of granulocytes. In: McMillan JA, Feigin RD, DeAngelis C,Jones MD, eds. *Oski's Pediatrics: Principles and Practice of Pediatrics.* 4th ed. Philadelphia, PA: Lippincott Williams & Wilkins; 2006:2456.

1B44

Key word: Indication for Carotid Endarterectomy

Author: Trevor A. Ellison, MD, MBA
Editors: G. Melville Williams, MD, FACS, and Christopher J. Abularrage, MD

A 54-year-old woman visited her primary care physician for a routine checkup. On physical examination, the doctor noted a right carotid bruit. A subsequent contrast angiogram revealed 50% stenosis of her right carotid artery. Carotid endarterectomy for asymptomatic patients is indicated for stenoses defined by diameter reduction of:

(A) >90%

(B) >80%

(C) >70%

(D) >60%

(E) >50%

Answer: (D) >60%

Rationale:
Fifty to eighty percent of patients who have suffered ischemic stroke are found to have a carotid artery lesion responsible for the event. Carotid artery endarterectomy to avoid future ischemic stroke has been well studied in several large, prospective, randomized trials. Patients in these trials are often divided into those with symptoms (previous monocular/hemispheric transient ischemic attacks, prior hemispheric stroke with recovery and no disability, and global ischemic attacks) and those without symptoms. These studies have compared surgical and medical management versus medical management alone in avoiding future fatal and nonfatal stroke.

For symptomatic patients, three trials – the North American Symptomatic Carotid Endarterectomy Trial (NASCET), the European Carotid Stenosis Trail (ECST), and the symptomatic carotid stenosis trial from the Veteran's Affairs Cooperative Study Program—found that carotid endarterectomy significantly reduced the risk of future stroke and the degree of stenosis correlated directly with the benefit of surgery. These findings hold true as long as the perioperative morbidity and mortality from a stroke is 6% or less.

For asymptomatic patients, two studies have shown decreased risk of transient ischemic attacks and stroke following carotid endarterectomy in those with 60% or greater carotid stenosis as determined by contrast angiography. The Asymptomatic Carotid Atherosclerosis (ACAS) trial found a 5-year stroke risk reduction from 11% to 5% in patients treated surgically for stenoses >60%. The European Asymptomatic Carotid Stenosis Trial (ACST) similarly found a 5-year stroke risk reduction from 12% to 6%.

Of note, all measurements of carotid stenosis in these trials are based off contrast angiography. However, the sensitivity and specificity of noninvasive imaging has improved significantly since these trials. Many surgeons will now perform a carotid endarterectomy based on duplex ultrasound,

۰۲۱-۶۶۱۹۸۵۱۴ www.myuptodate.com دریافت آخرین نسخه آپتودیت آفلاین

magnetic resonance angiography, or CT angiography, and without digital subtraction angiographic confirmation of the percent stenosis.

References:

Beneficial effect of carotid endarterectomy in symptomatic patients with high-grade carotid stenosis. North American Symptomatic Carotid Endartectomy Trial Collaborators. *N Engl J Med.* 1991;325(7):445–453.

Endarterectomy for asymptomatic carotid artery stenosis. Executive Committee for the Asymptomatic Carotid Atherosclerosis Study. *JAMA.* 1995;273(18):1421–1428.

Moore WS. Carotid arterial procedures. In: Souba WW, Fink MP, Jurkovich GJ, Kaiser LR, Pearce WH, Pemberton JH, Soper NJ, eds. *ACS Surgery: Principles and Practice.* New York, NY: WebMD; 2004:845.

1B45

Key word: Most Common Reaction to Iodine Contrast

Author: Robert A. Meguid, MD, MPH
Editor: Andrew M. Cameron, MD, PhD

A 37-year-old male is seen in the emergency department with abdominal pain. He has no known allergies. He undergoes computed tomography (CT) scan with oral and IV contrast. Which is the most likely reaction he will develop to the iodine contrast?

(A) Cardiac arrest
(B) Dyspnea
(C) Flushing
(D) Itching
(E) Nausea

Answer: **(E)** Nausea

Rationale:

As reported by Katayama et al. in a study of roughly 338,000 patients, the most common adverse reaction to ionic (iodinated) contrast media administered IV was nausea, which was observed in 4.6% of patients. The next most frequently observed adverse reactions were urticaria (3.2%), itching (3%), and heat sensation (2.3%). The most frequently observed adverse reaction requiring medical intervention was dyspnea (0.17%). The next most frequent were acute hypotension (0.10%), loss of consciousness (0.02%), and cardiac arrest (0.00004%).

Radiologic contrast media is available as either ionic hypertonic hyperosmolar tri-iodinated monomer salts (iodinated or ionic contrast) or low-osmolar nonionic media (noniodinated or nonionic contrast). The overall prevalence of adverse reactions to iodinated contrast is ~13%, while that of noniodinated contrast is ~3%. Severe adverse drug reactions, constituting symptoms requiring medical intervention, occur in 0.22% of iodine and 0.04% of noniodine IV contrast administrations.

The majority (~70%) of adverse reactions occur within 5 minutes of injection of contrast. Prevalence of adverse reactions is increased in patients with history of asthma (approximately eightfold increase), allergy to contrast (approximately fivefold increase), and atopy (approximately fivefold increase).

References:

Grainger RG. Intravascular radiological iodinated contrast media. In: Grainger RG Allison D, eds. *Grainger and Allison's Diagnostic Radiology.* 4th ed. London: Churchill Livingstone; 2001. Online Edition.

Katayama H, Yamaguchi K, Kozuka T, et al. Adverse reactions to ionic and nonionic contrast media. A report from the Japanese Committee on the Safety of Contrast Media. *Radiology.* 1990;175(3):621–628.

۰۲۱-۶۶۱۹۸۵۱۴ www.myuptodate.com دریافت آخرین نسخه آپتودیت آفلاین

1B46

Key word: Risks of Infliximab Therapy

Author: Robert A. Meguid, MD, MPH
Editor: Susan L. Gearhart, MD

You are treating a 56-year-old woman with Crohn disease for recurrent perianal fistulas. Before starting the patient on infliximab, you warn her that she may be at increased risk of several complications. Which of the following is considered the most common complication attributable to treatment of Crohn disease with infliximab?

(A) Anaphylaxis
(B) Lupus-like syndrome
(C) Lymphoma
(D) Tuberculosis pneumonia
(E) Urticaria

Answer: **(A)** Anaphylaxis

Rationale:

Infliximab (Remicade), an anti-TNF antibody, has been shown to elicit a clinical response in Crohn disease, including clinical remission in up to 50% of patients. Specifically, improved healing of fistulas is noted with infliximab treatment.

Fifty percent of patients experience infectious complications during and following treatment with infliximab. Up to 20% of patients treated with infliximab will develop anaphylaxis. The development of newer biologic agents has provided alternative therapy for patients who cannot take infliximab because of anaphylaxis.

Tuberculosis has been reported after infliximab therapy. Therefore, current guidelines for use of infliximab suggest that a tuberculin test (purified protein derivative [PPD]) be performed before beginning treatment. For patients who manifest a positive PPD isoniazid should be administered during infliximab treatment. For this reason, the occurrence of this complication in the United States is rare, and development of tuberculosis is thought to be secondary to reactivation of a prior exposure. Other infectious pathogens associated with infliximab use include *Pneumocystis jiroveci* (previously named *Pneumocystis carinii),* Legionella spp., and *Listeria monocytogenes.*

During a clinical trial of infliximab, 5 of 500 patients treated developed lymphoma. However, four of these patients were being treated with infliximab for rheumatoid arthritis and only one for Crohn disease. The investigators concluded that there is no direct evidence supporting that infliximab increases the risk of the development of lymphoma. A lupus-like reaction to infliximab is rare but serious.

References:

Bart PA, Pantaleo G. Immunodeficiencies associated with immunosuppressive agents. In: Cohen J, Powderly WG, eds. *Infectious Diseases.* 2nd ed. Edinburgh, IN: Elsevier; 2004. Accessed August 3, 2007. Online Edition.

Cohen Z, Sabo G, McLeod RS. Inflammatory bowel disease. In: Pemberton JH, ed. *Shackelford's Surgery of the Alimentary Tract.* 5th ed. Vol. 4. Philadelphia, PA: W.B. Saunders; 2002:75.

Michelassi F, Stein SL. Crohn disease. In: Mulholland MW, Lillemoe KD, Doherty GM, Maier RV, Upchurch GR, eds. *Greenfield's Surgery: Scientific Principles & Practice.* 5th ed. Philadelphia, PA: Lippincott Williams & Wilkins; 2011.

Sandborn WJ, Hanauer S, Loftus EV Jr, et al. An open-label study of the human anti-TNF monoclonal antibody adalimumab in subjects with prior loss of response or intolerance to infliximab for Crohn disease. *Am J Gastroenterol.* 2004;99(10):1984–1989.

Yamada T. Inflammatory bowel disease. In: Yamada T, Alpers DH, Powell DW, Owyang C, Silverstein FE, Hasler WL, Traber PG, Tierney WM, eds. *Handbook of Gastroenterology.* Philadelphia, PA: Lippincott-Raven; 1998:415.

۰۲۱-۶۶۱۹۸۵۱۴ www.myuptodate.com دریافت آخرین نسخه آپتودیت آفلاین

1B47

Key word: Adaptive Immunotherapy for Tumors

Author: Susanna M. Nazarian, MD, PhD
Editors: Charles M. Balch, MD, FACS, and Lisa K. Jacobs, MD

You are a tumor researcher trying to find novel cancer treatments. One of your projects involves constructing a tumor vaccine for breast cancer. Such a vaccine would take advantage of which of the following aspects of the immune system to prevent cancer?

(A) Activation of latent T cells in the thymus
(B) Adaptive immunity
(C) Cytokine activation
(D) Innate immunity
(E) Type IV hypersensitivity reaction

Answer: (B) Adaptive immunity

Rationale:
Cancer vaccines make use of the body's adaptive immune system, which differentiates "self" from "nonself." The adaptive immune system is composed of T and B cells. The immune system is generally "tolerant" of established cancers, and tumor cells secrete factors to block the activation of dendritic cells and induce tolerance. Dendritic cells are the cell type responsible for regulating adaptive immunity.

Cancer vaccines may be composed of cancer peptides, genes carrying sequence for a peptide or antigen or entire tumor lysates. After vaccination, the antigen is presented on the surface of the major histocompatibility I (MHC I) molecule, promulgating an immune response. These techniques have been used in breast colon, renal, melanoma, and head and neck cancer, with demonstrated immunity of the vaccinated patient against tumor antigens. However, there have not yet been widespread studies documenting tumor regression with cancer vaccine administration.

References:
Libutti SK. Cancer. In: Mulholland MW, Lillemoe KD, Doherty GM, Maier RV, Simeone DM, Upchurch GR, eds. *Greenfield's Surgery: Scientific Principles & Practice.* 5th ed. Philadelphia, PA: Lippincott Williams & Wilkins; 2011.
Wang T, Niu G, Kortylewski M, et al. Regulation of the innate and adaptive immune responses by Stat-3 signaling in tumor cells. *Nat Med.* 2004;10(1):48–54.

1B48

Key word: Zinc Deficiency Secondary to TPN

Author: Bonnie E. Lonze, MD, PhD
Editor: David T. Efron, MD, FACS

A 37-year-old woman with Crohn disease who has been managed on total parenteral nutrition for 6 months complains of nonhealing ulcers on her lower extremities. On physical examination she has bilateral pretibial erythematous areas with blisters, pustules, and superficial ulcerations. Which of the following elemental deficiencies would be most consistent with this clinical picture?

(A) Chromium
(B) Copper
(C) Iron
(D) Selenium
(E) Zinc

Answer: (E) Zinc

Rationale:
Zinc is a cofactor for hundreds of enzymes essential for processes including wound healing, immunity, cell growth, and cell division. Symptoms of zinc deficiency include the dermatitis that is described above. The skin lesions seen in acquired zinc deficiency are the same lesions observed in the genetic syndrome acrodermatitis enteropathica. In this autosomal recessive syndrome, a mutation in a gut transmembrane protein leads to impaired enteral absorption of zinc. Other symptoms of zinc deficiency include alopecia, diarrhea, poor wound healing, recurrent infections, and hypogonadism in developing males. Iron deficiency manifests as a hypochromic microcytic anemia and its symptoms are those seen in anemia such as easy fatigability and muscular dysfunction. Copper is a cofactor for several antioxidant enzymes. Copper deficiency results in neutropenia, an increased susceptibility to infections, and a hypochromic microcytic anemia that is refractory to iron supplementation. Selenium is a cofactor for a peroxidase enzyme that has activity in multiple tissue types. Deficiency can lead to a spectrum of clinical pictures, including a fatal cardiomyopathy. Symptoms associated with selenium deficiency include neurologic deterioration, visual changes, hyperpigmentation of the skin, and nail bed discoloration.

References:
Leung FY. Trace elements in parenteral micronutrition. *Clin Biochem.* 1995;28(6):561–566.
Prasad AS. Clinical manifestations of zinc deficiency. *Annu Rev Nutr.* 1985;5:341–363.

۰۲۱-۶۶۱۹۸۵۱۴ www.myuptodate.com دریافت آخرین نسخه آپتودیت آفلاین

1B49

Key word: Most Common Side Effect of Pancuronium

Author: Jayme E. Locke, MD, MPH
Editor: David T. Efron, MD, FACS

A 62-year-old man has developed acute respiratory distress syndrome 1 week after abdominal aortic aneurysm repair. Multiple efforts to control his high-peak airway pressures have been unsuccessful, and you have decided to use muscle relaxants on him in order to facilitate ventilation. While preparing pancuronium for administration, the nurse asks what is the most likely side effect of this paralytic?

(A) Central nervous system toxicity
(B) Histamine release
(C) Hypotension
(D) Residual motor weakness
(E) Tachycardia

Answer: (E) Tachycardia

Rationale:
Neuromuscular relaxants are either competitive (nondepolarizing) or noncompetitive (depolarizing) inhibitors of the neurotransmitter acetylcholine, at the neuromuscular junction. The only noncompetitive inhibitor in use clinically is succinylcholine. Succinylcholine cannot be reversed, but does have a short duration of action, as it is quickly degraded by plasma cholinesterases. The remaining paralytics in use clinically are competitive inhibitors, and thus, their effects can be reversed. There are three main competitive paralytics with long duration of action (approximately 1 hour): Pancuronium, pipecuronium, and doxacurium. None of these agents are associated with histamine release, but all have some cardiovascular side effects. In particular, the most common side effect associated with the administration of pancuronium is tachycardia. In addition, with prolonged use, pancuronium is associated with muscle weakness.

There are several intermediate-acting competitive paralytics in clinical use, including atracurium, vecuronium, rocuronium, and mivacurium. Both vecuronium and rocuronium have the advantage of not causing cardiovascular side effects. However, both atracurium and mivacurium are associated with histamine release.

Reference:
Kheterpal S, Rutter TW, Tremper KK. Anesthesiology and pain management. In: Mulholland MW, Lillemoe KD, Doherty GM, Maier RV, Upchurch GR, eds. *Greenfield's Surgery: Scientific Principles & Practice.* 5th ed. Philadelphia, PA: Lippincott Williams & Wilkins; 2011.

1B50

Key word: Staging of Hepatocellular Carcinoma

Author: Clinton D. Kemp, MD
Editor: Martin A. Makary, MD, MPH

A 43-year-old woman with Hepatitis C and hepatocellular carcinoma undergoes orthotopic liver transplantation. Her explanted liver demonstrates a solitary, 4.9-cm hepatocellular carcinoma with evidence of vascular invasion but without spread to regional lymph nodes. The stage of her hepatocellular carcinoma is:

(A) Stage I
(B) Stage II
(C) Stage IIIA
(D) Stage IIIB
(E) Stage IIIC

Answer: (B) Stage II

Rationale:
Although the incidence of hepatocellular carcinoma in the United States is quite low (less than 5 cases per 100,000 people), it remains of high worldwide significance as it is the fifth most common tumor across the globe.

Hepatocellular carcinoma arises from abnormal liver parenchymal cells in the setting of cirrhosis from any etiology, such as alcohol or chronic viral infections (Hepatitis B and C). Viral hepatitis, especially Hepatitis C, is the most common predisposing factor to hepatocellular carcinoma.

The diagnosis of hepatocellular carcinoma is attributed to a hepatic mass with characteristic features observed on abdominal imaging in a patient with a history of chronic liver disease and an elevated alpha-fetoprotein level in the serum. Rarely are biopsies of these lesions indicated given a convincing scenario, because of the associated danger as these lesions may bleed and the possibility of tumor seeding during biopsy.

The staging of hepatocellular carcinoma is based upon the TNM system set forth by the American Joint Committee on Cancer (AJCC). The 2002 classification system is provided here. Tumors of any size without vascular invasion are classified as T1 lesions. Those less than 5 cm with vascular invasion, or multiple tumors less than 5 cm are classified as T2 lesions. Multiple tumors greater than 5 cm or a solitary tumor that involves a major branch of a hepatic or portal vein is a T3 tumor. T4 tumors are those that demonstrate invasion of adjacent organs (except gallbladder) or spread to the visceral peritoneum.

Those tumors without evidence of lymphatic spread are staged based upon the size of the primary tumor from Stage I to Stage IIIB. Stage IIIC tumors are those with regional lymph node metastases. Stage IV tumors are those with evidence of distant metastasis.

This lesion is less than 5 cm but with vascular invasion, and it is a T2 tumor. There is no evidence of lymphatic (N0)

۰۲۱-۶۶۱۹۸۵۱۴ www.myuptodate.com دریافت آخرین نسخه آپتودیت آفلاین

or metastatic (M0) disease; thus this tumor is T3N0M0 or Stage II.

The treatment of hepatocellular carcinoma is primarily surgical with either anatomic resection or orthotopic liver transplantation. Criteria for orthotopic liver transplantation for hepatocellular carcinoma are based upon the Milan criteria and patients eligible for this treatment are those with solitary tumors less than 5 cm in size, or patients with three or less tumors, all of which are less than 3 cm in size.

Figure based upon the AJCC, 6th ed. Cancer Staging Manual, 2002, and adapted from reference below.

TNM Classification

Primary Tumor (T)	TX	Primary tumor not able to be assessed
	T0	No evidence of tumor
	T1	Solitary tumor without vascular invasion
	T2	Solitary tumor with vascular invasion
		Multiple tumors, all less than 5 cm in diameter
	T3	Multiple tumors greater than 5 cm
		Tumor involving major branch of hepatic or portal vein
	T4	Tumor directly invading adjacent organ (except gallbladder)
		Tumor spread to visceral peritoneum
Nodal Status (N)	NX	Regional lymph nodes not able to be assessed
	N0	No evidence of regional lymph node metastasis
	N1	Regional lymph node metastases present
Metastasis (M)	MX	Distant metastasis not able to be assessed
	M0	No evidence of distant metastasis
	M1	Distant metastasis present

Staging

	T	N	M
I	T1	N0	M0
II	T2	N1	M1
IIIA	T3	N2	M2
IIIB	T4	N3	M3
IIIC	Any T	N1	M0
IV	Any T	Any N	M1

Reference:

Strasberg SM, Lineham DC. Tumors of the pancreas, biliary tract, and liver. In: Souba WW, Fink MP, Jurkovich GJ, Kaiser LR, Pearce WH, Pemberton JH, Soper NJ, eds. *ACS Surgery: Principles and Practice.* New York, NY: WebMD; 2004:511–514.

1B51

Key word: Most Representative Descriptive Statistic

Author: Jayme E. Locke, MD, MPH
Editor: Dorry L. Segev, MD, PhD

The policymakers at your institution would like to implement a new warfarin protocol for patients with aortic valve replacements. They would like you to provide them with the international normalized ratio (INR) value that best describes the current population of aortic valve replacement patients with stable INR levels. Assume the INR levels are normally distributed among your patient population. What test statistic would be best to provide them?

(A) Mean
(B) Median
(C) Mode
(D) Standard error
(E) Z statistic

Answer: (A) Mean

Rationale:

The mean is the mathematical average, and is the best measure of central tendency if the units on the scale are equal, particularly when the values are distributed symmetrically (normal distribution). On the other hand, if the underlying distribution is non-normal and extreme outlier values exist, the median is a better descriptor. The median represents the 50th percentile. The mode is the most frequently occurring value.

Reference:

Aron A, Aron EN, Coups EJ. *Statistics for the Behavioral and Social Sciences: A Brief Course.* 3rd ed. New York, NY: Prentice Hall; 2004. Accessed August 15, 2007. Online Edition.

۰۲۱-۶۶۱۹۸۵۱۴ www.myuptodate.com دریافت آخرین نسخه آپتودیت آفلاین

1B52

Key word: Characteristics of Confidence Intervals

Authors: Jayme E. Locke, MD, MPH, and Susanna M. Nazarian, MD, PhD
Editor: Dorry L. Segev, MD, PhD

Medicare is considering whether to continue funding gastric bypass procedures. A key concern of the Medicare officials is the average weight loss among gastric bypass patients. Your institution has been asked to provide them with evidence demonstrating the associated probability of weight loss reported by your center. What information should you provide to the medicare officials?

(A) 95% confidence interval of the mean difference between preoperative and postoperative weights

(B) 95% confidence interval of the median difference between preoperative and postoperative weights

(C) Mean difference between preoperative and postoperative weights

(D) Median difference between preoperative and postoperative weights

(E) Mode of the difference between preoperative and postoperative weights

Answer: (A) 95% confidence interval of the mean difference between preoperative and postoperative weights

Rationale:
The mean, median, and mode represent point estimates, and as a result these values do not provide an estimate of how likely the weight loss is to occur. A 95% confidence interval, on the other hand, reflects the interval within which the true weight loss will fall for 95% of the subjects in the study. Suppose the 95% confidence interval for kilograms (pounds) of weight loss for gastric bypass patients from your center is [2 kg, 20 kg] ([5 lb, 45 lb]), with a median loss of 9.07 kg (20 lb). Then in a survey of 100 of your gastric bypass patients, the true weight loss will fall between 2.27 kg (5 lb) and 20.41 kg (45 lb) 95 times. A narrower confidence interval would describe greater assurance of the truth falling near the point estimate. For instance, a 95% confidence interval of [8 kg, 10 kg] ([17 lb, 23 lb]) for the same median of 9.07 kg (20 lb) reflects that in 100 cases, the true weight loss for that individual would lie within 1.36 kg (3 lb) of the average of 9.07 kg (20 lb) for 95 individuals.

A confidence interval of 95% is commonly used, as this incorporates samples within two standard deviations of the mean in either direction. However, other confidence intervals such as 90% or 99% are also used in clinical investigation.

Reference:
Dawson B, Trapp RG. *Basic and Clinical Biostatistics.* 4th ed. Philadelphia, PA: McGraw-Hill Companies; 2004:23–60.

1B53

Key word: Perioperative Treatment of Hemophilia

Author: Susanna M. Nazarian, MD, PhD
Editors: Martha A. Zeiger, MD, FACS, and Konstantinos I. Makris, MD

A 10-year-old boy develops right lower quadrant pain, nausea, vomiting, and a fever. You suspect appendicitis and plan for an emergent appendectomy. As you are preparing to transport him to the operating room, his parents mention that he has hemophilia A. What should you administer for this condition?

(A) Cryoprecipitate

(B) Factor VII

(C) Factor VIII

(D) Fresh frozen plasma (FFP)

(E) Vitamin K

Answer: (C) Factor VIII

Rationale:
Patients with hemophilia A have a lack of, or reduced activity of, factor VIII. As with hemophilia B (Christmas disease), hemophilia A is inherited as a sex-linked recessive trait, and thus is seen primarily in males. Hemophilia is categorized as *mild* if factor levels are between 5% and 50% of normal levels, *moderate* if factor levels are between 1% and 5% of normal levels, and *severe* if they are less than 1% of normal levels. Mild hemophilia does not cause spontaneous bleeding and may elude diagnosis until adulthood, whereas severe hemophilia is marked by spontaneous hemorrhages into muscles, joints, and soft tissues.

The best treatment for these patients prior to invasive procedures is the replacement of the deficient factor (VIII for hemophilia A, IX for hemophilia B, and XI for hemophilia C). The administration of recombinant factors rather than FFP can limit transfusion reactions and prevents antibody sensitization, which is prevalent in 15% to 30% of these patients. The infusion of DDAVP (1-deamino-8-D-arginine vasopressin (D)) causes a two- to threefold increase in circulating factor VIII levels. However, this may lead to depletion of factor stores and unsafely low factor levels following surgery. Cryoprecipitate is another treatment option but carries a higher risk of blood-borne disease transmission, since each unit is pooled from plasma from multiple donors.

During surgery on patients with hemophilia, the factor levels should be monitored. For minor surgery on patients with hemophilia A, a factor level greater than 30% of normal levels is desired for 3 to 4 days postoperatively. Major surgery requires factor levels between 80% and 100% of normal levels for 4 days, and then greater than 50% for an additional 3 to 7 days, postoperatively. Cardiovascular, prostate, and neurosurgery require factor levels of 100% for 3 days, then between 80% and 100% of normal levels for an additional 7 to 10 days postoperatively. Factor levels should be checked every 8 to 12 hours following surgery, equivalent to the half-life of factor

۰۲۱-۶۶۱۹۸۵۱۴ www.myuptodate.com دریافت آخرین نسخه آپتودیت آفلاین

Common Congenital Coagulation Disorders: Diagnosis and Treatment[a]

Disorder	Deficiency	Test(s) Result(s)	Treatment
Hemophilia A	Factor VIII	Normal PT, prolonged PTT, reduced factor VIII	DDAVP or replete with FFP or factor VIII concentrate
Hemophilia B *Christmas disease*	Factor IX	Normal PT, prolonged PTT, reduced factor IX	Replete with FFP or factor IX concentrate
Parahemophilia	Factor V	Prolonged PT/PTT, reduced factor V	Replete with FFP or factor V concentrate
Factor VII deficiency	Factor VII	Prolonged PT/PTT, reduced factor VII	Replete with FFP or activated factor VII or factor VII concentrate
Stuart-Power defect	Factor X	Prolonged PT/PTT, reduced factor X	FFP, factor IX concentrate
Hemophilia C	Factor XI	Normal PT, prolonged PTT, reduced factor XI	FFP, factor XI concentrate
Hageman trait	Factor XII	Normal PT, prolonged PTT, reduced factor XII	None, no abnormal bleeding noted
Prekallikrein		Normal PT, prolonged PTT, reduced level	None, no abnormal bleeding noted
High molecular weight kininogen		Normal PT, prolonged PTT, reduced level	None, no abnormal bleeding noted
von Willebrand disease	von Willebrand factor	Normal PT/PTT, prolonged bleeding time, reduced vWF	DDAVP, factor VIII concentrate, cryoprecipitate
Afibrinogenemia/ hypofibrinogenemia	Factor I	Prolonged PT/PTT and thrombin time, and decreased fibrinogen level	FFP or cryoprecipitate
Factor XIII deficiency	Factor XIII	Normal PT/PTT, decreased factor XIII	FFP, cryoprecipitate, or factor XIII concentrate
Hypoprothrombinemia	Factor II	Prolonged PT/PTT and thrombin time, decreased factor II	FFP or cryoprecipitate, factor IX concentrate

[a]PT, prothrombin time; PTT, partial thromboplastin time; DAVP, deamino-arginine vasopressin; FFP, fresh-frozen plasma; vWF, von Willebrand factor; DDAVP, 1-deamino-8-D-arginine vasopressin.

Reprinted with permission from: Comerota AJ, Miller MT. Hemorrhagic risk and blood components. In: Fischer JF, Bland KI, eds. *Mastery of Surgery.* 5th ed. Philadelphia, PA: Lippincott Williams & Wilkins, 2007:90.

VIII. The dose of factor VIII can be calculated using the following formula:

Dose of factor VIII (IU) = % (U/dL) desired rise in plasma factor VIII level × body weight (kg) × 0.5

In this particular case, given the urgent nature of the surgery, factor VIII should be administered prior to, and during surgery, as there will likely not be time to check factor levels.

Reference:

Comerota AJ, Miller MT. Hemorrhagic risk and blood components. In: Fischer JE, Bland KI, eds. *Mastery of Surgery.* 5th ed. Philadelphia, PA: Lippincott Williams & Wilkins; 2007:89–90.

۰۲۱-۶۶۱۹۸۵۱۴ www.myuptodate.com دریافت آخرین نسخه آپتودیت آفلاین

1B54

Key word: Staging of Soft Tissue Sarcoma

Author: Clinton D. Kemp, MD
Editors: Charles M. Balch, MD, FACS, and Lisa K. Jacobs, MD

A 35-year-old man is referred to you with an asymptomatic, 12-cm mass in his left thigh. Magnetic resonance imaging (MRI) of the thigh and computed tomography (CT) of the chest demonstrate no evidence of nodal or distant metastases. A core-needle biopsy is interpreted as fibrosarcoma. You perform a radical resection and the final pathology returns as a moderately differentiated fibrosarcoma. The most important prognostic factor in soft tissue sarcomas is the:

(A) Location of the primary tumor

(B) Histologic grade of the tumor

(C) Size of the primary tumor

(D) Presence of nodal metastases

(E) Presence of distant metastases

Answer: **(B)** Histologic grade of the tumor

Rationale:

Soft tissue sarcomas are rare tumors and account for less than 1% of all adult tumors and 7% to 15% of pediatric tumors. Approximately 6,000 to 8,000 new cases are diagnosed in the United States each year.

Histologically soft tissue sarcomas comprise a wide variety of subtypes with the most common being malignant fibrous histiocytoma, leiomyosarcoma, and liposarcoma. More than half of these tumors occur in an extremity, followed by the trunk and retroperitoneum. The majority of patients have no predisposing factors identified, although patients with genetic syndromes such as Li-Fraumeni, neurofibromatosis, and familial adenomatous polyposis are at higher risk, as are those patients with prior radiation exposure or chronic lymphedema. Carcinogen exposure and trauma have also been implicated in the pathogenesis of these tumors. A variety of genetic mutations in these tumors have been identified.

Survival for soft tissue sarcomas is 50% to 60% at 5 years, with most patients eventually dying of metastatic disease. Disease-free survival is inversely correlated with local recurrence and development of distant metastases. Tumor spread is primarily hematogenous with the lungs as the most common site, followed by the liver, bone, and brain. Lymphatic metastasis is rare.

Workup for these lesions includes incisional or core biopsy for tissue diagnosis and chest CT to evaluate for distant metastases in the lung. Treatment involves radical soft part resection, with adjuvant radiation for tumors at high risk of recurrence. Recurrent and metastatic tumor can be resected, resulting in prolonged survival. Unresectable local or distant metastases can be treated with systemic chemotherapy.

The American Joint Committee on Cancer has published a staging system for soft tissue sarcomas that includes histologic grade in addition to tumor size, nodal metastasis, and distant metastasis. In fact, for soft tissue sarcomas, the single most important prognostic indicator is histologic grade. The factors that are utilized in determining histopathologic grade include degree of differentiation, cellularity, number of mitoses per high-power field, pleomorphism, and necrosis. There is a direct correlation between histologic grade and metastatic potential, with only 5% to 10% of patients with low-grade tumors developing metastasis as compared to 50% to 60% of patients with high-grade lesions.

7th Edition AJCC Soft-tissue Sarcoma Staging System

Primary Tumor (T)	
TX	Primary tumor cannot be assessed
T0	No evidence of primary tumor
T1	Tumor ≤5 cm in greatest dimension
	T1a Tumor above superficial fascia
	T1b Tumor invading or deep to superficial fascia
T2	Tumor >5 cm in greatest dimension
	T2a Tumor above superficial fascia
	T2b Tumor invading or deep to superficial fascia
Regional Lymph Nodes (N)	
NX	Regional lymph nodes cannot be assessed
N0	No regional lymph node metastasis
N1	Regional lymph node metastasis
Distant Metastasis (M)	
MX	Distant metastasis cannot be assessed
M0	No distant metastasis
M1	Distant metastasis
Histopathological Grade (G)	
GX	Grade cannot be assessed
G1	Grade 1
G2	Grade 2
G3	Grade 3
Stage Grouping	
Stage I	
A	T1a N0 M0 G1, Gx
	T1b N0 M0 G1, Gx
B	T2a N0 M0 G1, Gx
	T2b N0 M0 G1, Gx
Stage II	
A	T1a N0 M0 G2, G3
	T1b N0 M0 G2, G3
B	T2a N0 M0 G2
	T2b N0 M0 G2
Stage III	T2a, T2b N0 M0 G3
	Any T N1 M0 Any G
Stage IV	Any T Any N M1 Any G

Reprinted with permission from: Caudle AS, Delman KA, Cormier JN. Soft tissue and bone sarcoma. In: Feig BW, Cormier JN, Ching CD, eds. *The M.D. Anderson Surgical Oncology Handbook*. 5th ed. Philadelphia, PA: Lippincott Williams & Wilkins; 2012.

References:

Caudle AS, Delman KA, Cormier JN. Soft tissue and bone sarcoma. In: Feig BW, Cormier JN, Ching CD, eds. *The M.D. Anderson Surgical Oncology Handbook*. 5th ed. Philadelphia, PA: Lippincott Williams & Wilkins; 2012.

Singer S. Soft tissue sarcomas. In: Townsend CM Jr, Beauchamp RD, Evers BM, Mattox KL, eds. *Sabiston Textbook of Surgery*. 19th ed. Philadelphia, PA: Elsevier; 2012:768–782.

۰۲۱-۶۶۱۹۸۵۱۴ www.myuptodate.com دریافت آخرین نسخه آپتودیت آفلاین

1B55

Key word: Effects of Rapid Massive Transfusion

Author: Justin B. Maxhimer, MD
Editor: Dorry L. Segev, MD, PhD

A 25-year-old man is brought to the trauma bay after two gunshot wounds to the left chest and mid back. His heart rate is 130 beats per minute, his blood pressure is 80/40 mm Hg, and he has a Glasgow Coma Scale of 9. It is estimated that he lost approximately 2 L of blood in the field and that he has lost another 2 L within the trauma bay during the initial assessment. Which of the following effects would be most likely due to rapid resuscitation with blood products in this patient?

(A) Cerebral hemorrhage
(B) Jaundice and fever seen a week later
(C) Massive lower-extremity swelling
(D) Myoglobinuria
(E) Temporary blindness

Answer: (B) Jaundice and fever seen a week later

Rationale:

There are numerous potential adverse results of blood transfusions, and side effects are associated with 20% of transfusions. In one study, trauma patients that received an average of 25 units of blood were exposed to the blood of 80 different donors, resulting in a high antigen exposure. Complications can arise from the preservation process of blood, an adverse reaction to the transfusion, or infectious agents. Clinical complications that arise from massive transfusion are most often a result of the biologic effects of blood preservation or the physiologic changes that occur during the storage period. These alterations include increased acidity, elevated plasma potassium, and a decrease in 2, 3-diphosphoglycerate (DPG) levels and half-saturation (P_{50}) values that affect the blood's ability to transport oxygen to the cells. In addition to changes affecting the quality of erythrocytes, platelet function decreases with storage, and levels of factors V and VIII drop. Transfusion reactions can be immediate and life-threatening, or delayed and insidious.

Acute hemolytic transfusion reaction is a severe, life-threatening condition that occurs once in every 25,000 units of infused erythrocytes and is usually caused by an antigen–antibody reaction to ABO-incompatible blood. Most incidents occur as a result of errors in patient identification and the administration of incompatible blood. Primary symptoms of fever and hypotension can occur with infusion of as little as 0.7 mL, and death has occurred after infusion of only 30 mL. Treatment includes immediate discontinuation of the blood, hemodynamic and renal support with vasopressors and diuretic agents, and avoidance of future incompatibility by obtaining an updated blood sample for crossmatching.

Delayed hemolytic transfusion reaction occurs once in every 2,500 units of erythrocytes and often goes unnoticed. The reaction typically occurs 2 to 14 days after transfusion and results in fever, jaundice, and anemia. Delayed hemolytic transfusion reaction results from the clearance of the antibody-coated erythrocyte by the reticuloendothelial system. Therapy includes treating the anemia should symptoms develop and transfusion of antigen-negative blood if needed in the future.

Transfusion-related acute lung injury (TRALI), or noncardiogenic pulmonary edema, is a reaction caused by antibodies in the donor blood that react against the leukocytes of the recipient. The estimated rate of occurrence is once in 10,000 units. Symptoms include bronchospasm, hypoxia, fever, and diffuse bilateral pulmonary infiltrates and occurs less than 6 hours after transfusion. Pulmonary failure usually ensues and mechanical ventilatory support is required. Full recovery occurs within 2 to 4 days, but occasionally takes as long as 7 days. Chest radiograph is not a definitive diagnostic tool, in that the signs and symptoms are sometimes confused with those of congestive heart failure or of adult respiratory distress syndrome.

Anaphylactic reactions to blood transfusions are rare, occurring only once in 150,000 units, and often the exact allergen is never identified. Clinical signs generally occur shortly after the transfusion is begun and include swelling of the throat and hypertension followed by chills, flushing, bronchospasm, and gastrointestinal distress. Treatment includes immediate discontinuation of the blood, administration of epinephrine and corticosteroids, avoidance of fresh frozen plasma in the future, and infusion of only washed blood to decrease the allergen potential.

Reference:

Sloop GD, Friedberg RC. Complications of blood transfusion: How to recognize and respond to noninfectious reactions. *Postgrad Med.* 1995;98(1):159–172.

۰۲۱-۶۶۱۹۸۵۱۴ www.myuptodate.com دریافت آخرین نسخه آپتودیت آفلاین

1B56

Key word: Treatment of Urokinase Overdose

Author: Robert A. Meguid, MD, MPH
Editor: Dorry L. Segev, MD, PhD

On postoperative day 4 after a Whipple procedure, a patient develops symptoms consistent with massive pulmonary embolism. Computed tomography confirms a saddle embolus. After emergent lytic therapy with urokinase, the patient is bleeding from the surgical site. Which of the following options is the best choice to treat the bleeding?

(A) Aminocaproic acid
(B) Cryoprecipitate
(C) Dextran
(D) Fresh frozen plasma
(E) Packed red blood cells

Answer: (D) Fresh frozen plasma

Rationale:
Absolute contraindications to lytic therapy include active internal bleeding, cerebrovascular accident within 2 months, and intracranial disease. Relative contraindications include surgery or trauma within 10 days, likelihood of left heart thrombus, episodes of serious gastrointestinal bleeding within 90 days, hypertension, pregnancy, bacterial endocarditis, and diabetic hemorrhagic retinopathy.

Of the lytic agents currently in use, urokinase is one of the most expensive. While the half-life of streptokinase is 80 minutes, that of urokinase is 15 minutes, and that of tissue plasminogen activator (t-PA) is 4 minutes. While streptokinase use carries the risk of severe allergic reactions, urokinase and t-PA do not. Both urokinase and t-PA are metabolized by the liver. The mechanism of action of all three described lytic agents is activation of plasminogen into plasmin on the fibrin surface, resulting in degradation of fibrin clots. The resulting activity of these lytic agents is fibrin specific.

Bleeding, the most common adverse reaction to urokinase administration, can be treated with transfusion of whole blood or fresh frozen plasma, which restores plasma fibrin. Cryoprecipitate must be administered in combination with packed red blood cells for effective control of bleeding after urokinase overdose. Aminocaproic acid is considered a last resort for treatment of bleeding after urokinase overdose, as its efficacy has not been documented in humans. Dextran should not be used for treatment of bleeding.

References:
Henke PK, Wakefield TW. Hemostasis. In: Mulholland MW, Lillemoe KD, Doherty GM, Maier RV, Upchurch GR, eds. *Greenfield's Surgery: Scientific Principles & Practice.* 5th ed. Philadelphia, PA: Lippincott Williams & Wilkins; 2011.
Owings JT. Venous thromboembolism. In: Souba WW, Fink MP, Jurkovich GJ, Kaiser LR, Pearce WH, Pemberton JH, Soper NJ, eds. *ACS Surgery: Principles and Practice.* 4th ed. New York, NY: WebMD; 2004:730–731.
Physicians' Desk Reference. 403–404. Montvale, NJ: Medical Economics Company; 1996.

1B57

Key word: Urinary Retention Post-hemorrhoidectomy

Author: Robert A. Meguid, MD, MPH
Editor: Arthur L. Burnett, MD, MBA, FACS

You receive a phone call from a 62-year-old female complaining of inability to urinate. Ten hours prior, she underwent a hemorrhoidectomy. How should you manage this problem?

(A) Tell the patient not to worry, that she will urinate eventually
(B) Tell the patient to contact you again if she does not urinate within 24 hours of the surgery
(C) Tell the patient to drink more fluids
(D) Tell the patient to phone the urologist on call
(E) Tell the patient to return to the emergency department for placement of a Foley catheter

Answer: (E) Tell the patient to return to the emergency department for placement of a Foley catheter

Rationale:
Urinary retention is a common complication after surgery for anorectal disease, occurring in approximately 20% of patients after hemorrhoidectomy. The etiology is likely due to reflex spasm of the pelvic musculature due to postoperative pain. Independent risk factors for urinary retention after hemorrhoidectomy include female sex, resection of more than three hemorrhoids, diabetes mellitus, the need for postoperative pain medications, and the presence of urinary symptoms preoperatively.

Patients typically encounter urinary retention after local anesthesia wears off. In this case where the patient has not voided at all, her bladder most likely would contain at least 500 to 700 cm^3. Accepted treatment is placement of a Foley catheter for at least 12 hours, as well as improved pain control. It is inappropriate for patients to undergo the discomfort of urinary retention at home, or to delay treatment.

Adequate postoperative pain control reduces the incidence of urinary retention threefold, and perioperative fluid restriction reduces it twofold. Giving more fluids in the setting of no improvement in pain control and no urinary catheter will worsen the patient's discomfort.

References:
Kodner IJ. Anal procedures. In: Souba WW, Fink MP, Jurkovich GJ, Kaiser LR, Pearce WH, Pemberton JH, Soper NJ, eds. *ACS Surgery: Principles and Practice.* 4th ed. New York, NY: WebMD; 2004:628.
Toyonaga T, Matsushima M, Sogawa N, et al. Postoperative urinary retention after surgery for benign anorectal disease: Potential risk factors and strategy for prevention. *Int J Colorectal Dis.* 2006;21(7):676–682. Epub 2006 Mar 22.

۰۲۱-۶۶۱۹۸۵۱۴ www.myuptodate.com دریافت آخرین نسخه آپتودیت آفلاین

1B58

Key word: Treatment of Infected IV Site

Author: Susanna M. Nazarian, MD, PhD
Editor: Julie A. Freischlag, MD

During afternoon rounds, a patient who is 3 days status post right hemicolectomy complains of right arm pain. You note that the arm has a peripheral intravenous (IV) in it with surrounding warmth and erythema. What is the best course of action?

(A) Begin a 3-day course of IV cephalosporin antibiotics

(B) Draw two sets of peripheral blood cultures

(C) Elevate the affected arm and alternate warm compresses and ice packs

(D) Order a stat right upper-extremity venous duplex

(E) Remove the peripheral IV

Answer: (E) Remove the peripheral IV

Rationale:
Treatment of a potentially infected peripheral IV catheter site should begin with removal of the suspected catheter. Further treatment depends on the physical examination and clinical status of the patient. Local infections devoid of systemic responses, such as leukocytosis and fever, may be treated by removal of the peripheral IV catheter followed by elevation of the extremity and application of warm compresses. The physician should be attuned to signs of thrombophlebitis: Streaking redness, swelling of the arm, and a palpable cord. Such findings should heighten suspicion of septic thrombophlebitis and a duplex should be obtained to check for thrombosis of the involved vessel. IV antibiotics should be instituted following the procurement of blood cultures. If a prior IV catheter site continues to have evidence of purulence or if there is persistent gram-positive bacteremia after removal of all IV catheters, the patient may require operative exploration to remove the entire length of the affected vein. *Staphylococcus aureus* is the most common cause of suppurative thrombophlebitis.

Reference:
Fry DE. Blood cultures and infections in the patient with the septic response. In: Souba WW, Fink MP, Jurkovich GJ, Kaiser LR, Pearce WH, Pemberton JH, Soper NJ, eds. *ACS Surgery: Principles and Practice.* New York, NY: WebMD; 2004:1271–1272.

۰۲۱-۶۶۱۹۸۵۱۴ www.myuptodate.com دریافت آخرین نسخه آپتودیت آفلاین

دریافت آخرین نسخه آپتودیت آفلاین www.myuptodate.com ۰۲۱-۶۶۱۹۸۵۱۴

2
GASTROINTESTINAL

CONTENTS:

Number:	Key Word:	Page:
1G01	Diagnosis of Appendicitis versus Acute Ileitis	107
1G02	Treatment of Recent 4-cm Pancreatic Pseudocyst	107
1G03	Best Test of Successful Treatment of *H. Pylori*	108
1G04	Treatment of Liver Hemobilia	109
1G05	Treatment of Rectal Bleeding after Hemorrhoid Banding	110
1G06	Treatment of Colon Cancer Metastases to the Liver	110
1G07	Treatment of Duodenal Obstruction in Crohn Disease	111
1G08	Diagnosis of Caustic Ingestion	112
1G09	Etiology of Hematogenous Metastases to the Small Bowel	113
1G10	Treatment of *C. difficile* in Pregnancy	114
1G11	Treatment of Anal Fissure with Rectal Bleeding	114
1G12	Treatment of Esophageal Perforation	115
1G13	Arterial Supply for a Gastric Tube	116
1G14	Diagnosis of Colonic Pseudo-obstruction	117
1G15	Treatment of Gallstone Ileus	118
1G16	Treatment of Retained Common Bile Duct Stone after T-tube	120
1G17	Treatment of Squamous Cell Carcinoma of the Anal Canal	121
1G18	Most Common Etiology of Common Bile Duct Injury in Laparoscopic Cholecystectomy	122
1G19	Treatment of Duodenojejunal Adenocarcinoma	123
1G20	Treatment of a Dark Stoma Following Abdominoperineal Resection	124
1G21	Diagnosis of Acute Gastric Dilation	124
1G22	Diagnosis of Common Bile Duct Stricture from Chronic Pancreatitis	125
1G23	Treatment of Gallbladder Carcinoma	126
1G24	Treatment of Incompletely Reduced Ileocolic Intussusception	128
1G25	Complications after Nissen Fundoplication	129
1G26	Diagnosis of Afferent Limb Obstruction	130
1G27	Treatment of MALT Lymphoma	131
1G28	Treatment of Focal Nodular Hyperplasia of the Liver	132
1G29	Treatment of Esophageal Leiomyoma	133
1G30	Physiology of Truncal Vagotomy	134

۰۲۱-۶۶۱۹۸۵۱۴ www.myuptodate.com دریافت آخرین نسخه آپتودیت آفلاین

Number:	Key Word:	Page:
1G31	Treatment of Choledochal Cyst	135
1G32	Unresectable Pancreatic Cancer	137
1G33	Treatment of Barrett Esophagus with High-grade Dysplasia	138
1G34	Treatment of Gastrinoma of the Duodenum	138
1G35	Complications of Hepatic Adenoma	139
1G36	Treatment of Chronic Pancreatitis	139
1G37	Treatment to Close Fistula Secondary to Crohn Disease	141
1G38	Treatment of Gastrointestinal Stromal Tumors	141
1G39	Site of Primary Tumor in Carcinoid Syndrome	142
1G40	Adjuvant Chemotherapy for Sigmoid Carcinoma	143
1G41	Characteristics of Parastomal Hernias	143
1G42	Treatment of Rectal Adenocarcinoma	144
1G43	Treatment of Diverticulum of the Duodenum	144
1G44	Anatomy of Replaced Right Hepatic Artery	145
1G45	Prognostic Test of Liver Function Reserve	146
1G46	Most Effective Stimulant of Pancreatic Acinar Cells	147
1G47	Findings Associated with Hepatorenal Syndrome	147
1G48	Mechanism of Action of Gastrin	148
1G49	Site of Effect of Motilin	150
1G50	Ligation of Artery in Bleeding Duodenal Ulcer	151
1G51	Diagnosis of Biliary Dyskinesia	152
1G52	Characteristics of Lipid Digestion and Absorption	152
1G53	Lower Esophageal Sphincter Pressure during Swallowing	153
1G54	Most Accurate Diagnostic Imaging in Meckel Diverticulum	154
1G55	Organism Associated with Multiple Liver Abscesses	154
1G56	Metabolic Condition Associated with Gastric Outlet Obstruction	156
1G57	Characteristics of Primary Hyperaldosteronism	156
1G58	Pancreatic Enzyme Secretion	158
1G59	Treatment of Pancreatic Fistula	158
1G60	Treatment of Cancer at the Hepatic Flexure	159
1G61	Patients with the Highest Rate of Breast Cancer	162
1G62	Characteristics of T3 Colon Cancer	163

۰۲۱-۶۶۱۹۸۵۱۴ www.myuptodate.com دریافت آخرین نسخه آپتودیت آفلاین

1G01

Key word: Diagnosis of Appendicitis versus Acute Ileitis

Author: Susanna M. Nazarian, MD, PhD
Editor: Dorry L. Segev, MD, PhD

A 46-year-old woman comes to the emergency department complaining of acute right lower quadrant pain. How could appendicitis be differentiated from acute ileitis?

(A) Colonoscopic biopsy

(B) Development of acute or subacute pain in the right lower quadrant

(C) Elevated white blood cell count

(D) Presence of diarrhea

(E) Thickened mesenteric lymph nodes on radiographic imaging

Answer: (E) Thickened mesenteric lymph nodes on radiographic imaging

Rationale:

Acute ileitis may masquerade as acute appendicitis. Both present primarily as acute or subacute pain in the right lower quadrant. The astute clinician may be able to elicit slight differences in the history and physical examination: (1) Those patients with infectious ileitis may have colicky, intermittent pain; (2) local tenderness in the right lower quadrant may be less severe with ileitis than fulminant appendicitis; (3) while the white blood cell count is elevated in both pathologies, the erythrocyte sedimentation rate is typically higher in infectious ileitis.

In a study of 533 consecutive patients with suspected acute appendicitis or appendiceal mass by Puylaert et al., 11.4% were actually found to have bacterial enteritis of the ileocecal region on ultrasonography. Radiographic findings suggestive of ileocecal inflammation rather than acute appendicitis include enlarged mesenteric lymph nodes and symmetric mural thickening of the terminal ileum and cecum, with nonvisualization of the appendix. Responsible organisms include *Campylobacter jejuni, Salmonella enteritidis,* and *Yersinia enterocolitica.* Not all patients with ileitis have diarrhea; in this study, only 36% patients eventually confirmed to have this diagnosis suffered from diarrhea. Infectious ileitis is typically a benign and self-limiting condition—thus effort should be made to exclude it as a possible mimicker of appendicitis before proceeding to the operating room for an appendectomy. Antibiotic treatment is typically not necessary, nor is operative resection.

References:

Melton GB, Li R, Duncan MD, et al. Acute appendicitis. In: Cameron JL, Cameron AM, eds. *Current Surgical Therapy.* 10th ed. Philadelphia, PA: Mosby; 2011:219–223.

Puylaert JB, Van der Zant FM, Mutsaers JAEM. Infectious ileocecitis caused by Yersinia, Campylobacter and Salmonella: clinical, radiologic and US findings. *Eur Radiol.* 1997;7:3–9.

Puylaert JB, Vermeijden RJ, van der Werf SD, et al. Incidence and sonographic diagnosis of bacterial ileocaecitis masquerading as appendicitis. *Lancet.* 1989;2(8654):84–86.

1G02

Key word: Treatment of Recent 4-cm Pancreatic Pseudocyst

Author: Justin B. Maxhimer, MD
Editors: Timothy M. Pawlik, MD, MPH, PhD, and Matthew J. Weiss, MD

A 60-year-old man who suffers from chronic alcoholism is admitted to the hospital with an episode of acute pancreatitis. He suffered similar episodes in the past—all of which have resolved without complications. On laboratory studies, he is found to have an elevated serum amylase level. A computed tomography (CT) scan is performed which demonstrates a 4-cm pancreatic pseudocyst. What would be the best subsequent treatment?

(A) Esophagogastroduodenoscopy

(B) Observation and serial CT scans

(C) Percutaneous drainage

(D) Puestow procedure

(E) Simple aspiration

Answer: (B) Observation and serial CT scans

Rationale:

Pseudocysts are fluid collections, usually inflammatory in origin, that arise in or in close proximity to the pancreas. By definition, pseudocysts lack an epithelial lining. Most pseudocysts are seen in the context of either acute or chronic pancreatitis. A small proportion of pseudocysts are post-traumatic. In children, trauma is the most common etiology of pancreatic pseudocysts. Pseudocysts developing from acute pancreatitis usually are extrapancreatic, loculated collections of amylase-rich fluid that develops within 2 weeks of the onset of the attack. It probably results from either the disruption of a pancreatic duct or from leakage from the inflamed surface of the gland. A ductal communication is not typically demonstrable. Most such peripancreatic "acute fluid collections" resolve spontaneously unless they contain a large amount of necrotic material or become infected. Some persist and develop a wall of fibrous granulation tissue.

The pseudocysts of chronic pancreatitis may result from one of two pathogenic processes. First, a necrotic collection may develop as a complication of an attack of acute-on-chronic pancreatitis. Secondly, a retention collection may occur as a result of blockage of a major branch of the pancreatic duct by localized fibrosis, a calculus, or a protein plug, leading to the rupture of the corresponding acini. O'Malley et al. noted that pseudocysts of more than 4 cm resolved spontaneously at a mean of 3 months after diagnosis although, in one case, resolution did not occur until 28 months. Maringhini et al. found that within 1 year after diagnosis, 65% of acute pseudocysts resolved. Pseudocysts of less than 5 cm in size were more likely to resolve than larger ones. Gouyon et al. observed a pseudocyst resolution rate of 26% in patients with chronic alcoholic pancreatitis. The median time to regression was 29 weeks (range 2 to 143 weeks) and the independent

۰۲۱-۶۶۱۹۸۵۱۴ www.myuptodate.com دریافت آخرین نسخه آپتودیت آفلاین

predictive factor of pseudocyst resolution or an asymptomatic course was a size of less than 4 cm. Size was also a major factor predicting pseudocyst resolution in the Aranha et al. series. The mean diameter of cystic lesions that resolved was 4 ± 1 cm as compared to a diameter of 9 ± 1 cm in those cysts that did not resolve. Only 4 of 26 pseudocysts greater than 6 cm in diameter at initial examination resolved. Several more studies also confirmed that cysts less than 4 cm in diameter can resolve spontaneously.

Reference:

Andrén-Sandberg A, Dervenis C. Pancreatic pseudocysts in the 21st century. Part I: classification, pathophysiology, anatomic considerations and treatment. *JOP.* 2004;5:8–24.

1G03

Key word: Best Test of Successful Treatment of *H. Pylori*

Author: Robert A. Meguid, MD, MPH
Editors: Thomas H. Magnuson, MD, and Kenzo Hirose, MD, FACS

A 63-year-old man presents with a "gnawing" upper abdominal pain. He reports that he was diagnosed with a gastric ulcer years ago. Which of the following tests is most sensitive in diagnosing the patient with infection with *Helicobacter pylori*?

(A) Histologic examination of endoscopic antral biopsies

(B) Serum antibodies to *H. pylori*

(C) Upper GI radiographic series

(D) Urea breath test

(E) Urease test of endoscopic antral biopsies

Answer: (A) Histologic examination of endoscopic antral biopsies

Rationale:

H. pylori has a strong association with the development of peptic ulcer disease. Treatment with bismuth, metronidazole, and tetracycline is associated with eradication of *H. pylori* and peptic ulcers.

The gold standard of testing for diagnosis of *H. pylori* is histologic examination of endoscopic antral biopsies for presence of *H. pylori,* with 92% sensitivity and 100% specificity.

The urease test requires placing the endoscopic biopsies into a gel matrix and looking for color change. While the turnaround time for the urease test using endoscopic antral biopsies is quicker than histology, it has 90% sensitivity and 100% specificity.

The urea breath test, also known as the ^{13}C- or ^{14}C-urea breath test, while noninvasive, is limited to 90% sensitivity. All of the aforementioned tests can give false negatives if the patient has undergone a recent short course of antibiotics.

ELISA testing for serum antibodies to *H. pylori* has 87% sensitivity and 85% specificity, as antibodies may persist for up to 1 year after eradication.

The upper GI radiographic series is useful for diagnosis of peptic ulcer disease by visualization of ulceration, not infection with *H. Pylori.* However, it has 54% sensitivity and 91% specificity. Therefore, endoscopy, providing the ability to take mucosal biopsies, is also the gold standard for diagnosis of peptic ulcer disease.

References:

Mulholland MW. Gastroduodenal ulceration. In: Mulholland MW, Lillemoe KD, Doherty GM, Maier RV, Upchurch GR, eds. *Greenfield's Surgery: Scientific Principles & Practice.* 5th ed. Philadelphia, PA: Lippincott Williams & Wilkins; 2011.

Yamada T. Acid-peptic disorders and Zollinger-Ellison syndrome. In: Yamada T, Alpers DH, Powell DW, Owyang C, Silverstein FE, Hasler WL, Traber PG, Tierney WM, eds. *Handbook of Gastroenterology.* Philadelphia, PA: Lippincott-Raven; 1998:265–280.

۰۲۱-۶۶۱۹۸۵۱۴ www.myuptodate.com دریافت آخرین نسخه آپتودیت آفلاین

1G04

Key word: Treatment of Liver Hemobilia

Author: Susanna M. Nazarian, MD, PhD
Editor: Richard D. Schulick, MD, MBA, FACS

A 72-year-old man undergoes percutaneous transhepatic cholangiography (PTC) and percutaneous biliary drainage (PBD) for obstructive jaundice secondary to pancreatic cancer. Following the PTC/PBD, he develops melena and bright red blood is seen in the biliary drain. Laboratory work reveals a drop in hematocrit and increase in his liver function tests. What is the definitive treatment for this change in his condition?

(A) Biliary stent placement

(B) Endoscopic epinephrine injection at the site of the bleeding vessel

(C) Hepatic resection

(D) Transarterial embolization

(E) Whipple procedure

Answer: (D) Transarterial embolization

Rationale:

Hemobilia is defined as bleeding into the bile duct resulting from communication between a blood vessel and the duct. Clinical manifestations include melena and/or hematemesis, right upper quadrant pain, anemia, transient worsening of liver function tests, and jaundice. Shock may ensue if the bleeding is profuse. The site of communication between the duct and vessel may be either intra- or extrahepatic.

The most common causes of hemobilia are iatrogenic, accounting for two-thirds of cases, with percutaneous liver procedures accounting for 38%. Other than PTC/PBD (incidence 2% to 10%), liver biopsy (incidence <1%) and hepatectomy may result in hemobilia. Other causes of hemobilia include trauma, liver abscesses, mycotic aneurysms, vascular malformations, tumors, and hemorrhagic cholecystitis. Since frank bleeding is rare, the diagnosis may be unclear for months; alternately, a patient may present with melena or hematemesis. Brisk bleeding may be difficult to differentiate from that originating from the stomach or duodenum. Bleeding at a slow rate may clot within the biliary tree leading to obstructive jaundice.

Currently, the standard of care for treatment of hemobilia secondary to erosion into a hepatic artery branch is to attempt transarterial embolization. Angiography detects over 90% of causes of major hemobilia, and selective embolization is successful in 80% to 100% of the time. If hemobilia is secondary to erosion into a portal vein branch, upsizing the PBD may be sufficient to prevent bleeding by inducing tamponade. Surgery is indicated if embolization fails or in the settings of hemorrhagic cholecystitis or hepatic necrosis. Surgical treatment entails selective ligation of the bleeding artery, which may require a segmental liver resection, or removal of the root cause (i.e., vascular malformation, mycotic aneurysm, etc.) Mortality from hemobilia currently is <5%.

References:

Dousset B, Sauvanet A, Bardou M, et al. Selective surgical indications for iatrogenic hemobilia. *Surgery.* 1997;121(1): 37–41.

Schlinkert RT, Kelly KA. Upper gastrointestinal bleeding. In: Souba WW, Fink MP, Jurkovich GJ, Kaiser LR, Pearce WH, Pemberton JH, Soper NJ, eds. *ACS Surgery: Principles and Practice.* 4th ed. New York, NY: WebMD; 2004:321.

Srivastava DN, Sharma S, Pal S, et al. Transcatheter arterial embolization in the management of hemobilia. *Abdom Imaging.* 2006;31(4):439–448.

Wolf DS, Wasan SM, Merhav H, et al. Hemobilia in a patient with protein S deficiency after laparoscopic cholecystectomy that caused acute pancreatitis: Successful endoscopic management. *Gastrointest Endosc.* 2005;62(1):163–166.

۰۲۱-۶۶۱۹۸۵۱۴ www.myuptodate.com دریافت آخرین نسخه آپتودیت آفلاین

1G05

Key word: Treatment of Rectal Bleeding after Hemorrhoid Banding

Author: Robert A. Meguid, MD, MPH
Editor: Susan L. Gearhart, MD

A 36-year-old woman underwent banding for an internal hemorrhoid 1 week ago. She contacts your office complaining of a small amount of blood on toilet paper after defecation, but denies pain or fever. The next step in her management is:

(A) Direct the patient to the emergency room

(B) Instruct the patient to apply cold compresses to the perineum

(C) Instruct the patient to take fiber supplementation and increase fluid intake

(D) Prescribe nifedipine ointment BID to the perianal region

(E) Tell the patient there is nothing to do

Answer: (C) Instruct the patient to take fiber supplementation and increase fluid intake

Rationale:
Five to ten days after banding or surgery for internal hemorrhoids, it is common for patients to experience minimal bleeding due to sloughing of eschar. It is important to reassure patients that this occurs frequently and should not cause alarm. Sitz baths can be helpful in easing pain and inflammation, while fiber supplementation can help soften stool, thereby preventing local trauma to the surgical site. Patients should be encouraged to maintain adequate fluid intake. Aspirin-containing compounds should be avoided, as they may precipitate further bleeding. Nifedipine ointment is used in the treatment of fissures, which is unlikely in this patient as she denies presence of pain.

Only in the event of significant bleeding is further intervention warranted. Should this occur, patients should undergo examination under anesthesia with ligation of the source of the bleeding.

Reference:
Kodner IJ. Anal procedures for benign disease. In: Souba WW, ed. *ACS Surgery: Principles and Practice*. Decker Intellecutal Properties, 2009. Accessed August 27, 2013. Online Edition.

1G06

Key word: Treatment of Colon Cancer Metastases to the Liver

Author: Robert A. Meguid, MD, MPH
Editor: Michael A. Choti, MD, MBA

A 56-year-old man 2 years status post left colectomy for stage IIA colon cancer is now found to have rising carcinoembryonic antigen (CEA) and two new lesions in the liver on follow-up CT scan (see scans below). There is no evidence of extrahepatic disease. How do you manage this patient?

(A) Extended left hepatectomy

(B) Orthotopic liver transplantation

(C) Palliative chemotherapy

(D) Radiofrequency ablation of the two tumors

(E) Y-90 intra-arterial therapy

Answer: (A) Extended left hepatectomy

Rationale:
The most common site of distant metastases from colorectal cancer is the liver. A 5-year survival rate of approximately 50% is seen in patients who undergo resection for hepatic metastases. However, not all patients are candidates for surgical resection. Resectabilty is no longer defined by size, number, or location of metastases within the liver. Rather, a patient is considered resectable if all disease can be resected with negative margins (R0) and a sufficient healthy remnant liver remains with adequate vascular inflow, outflow, and biliary drainage.

In this case, the patient has two bilobar lesions, one 4-cm tumor in the left liver and a second 1.5-cm tumor in the anterior right liver (segment 8). The disease appears resectable. Extended left hepatectomy or two separate resections (left partial or complete hepatectomy and wedge resection of the right-sided lesion) could be performed. Radiofrequency ablation or other ablative approaches should only be reserved in cases where the disease is unresectable. Similarly, intra-arterial therapy is generally only considered in selective cases of unresectable disease. In most cases such as this, chemotherapy is recommended in the perioperative period. It can be administered adjuvantly following resection or it can be offered for a short duration as neoadjuvant therapy.

References:
Choti MA, Sitzmann JV, Tiburi MF, et al. Trends in long-term survival following liver resection for hepatic colorectal metastases. *Ann Surg.* 2002;235(6):759–766.

Pawlik TM, Choti MA. Surgical therapy for colorectal metastases to the liver. *J Gastrointest Surg.* 2007;11(8):1057–1077.

۰۲۱-۶۶۱۹۸۵۱۴ www.myuptodate.com دریافت آخرین نسخه آپتودیت آفلاین

1G07

Key word: Treatment of Duodenal Obstruction in Crohn Disease

Authors: Robert A. Meguid, MD, MPH, and Susanna M. Nazarian, MD, PhD
Editor: Mark D. Duncan, MD, FACS

Workup for vomiting in a 46-year-old woman with Crohn disease reveals a stricture in the second portion of the duodenum. What is the best surgical management of this problem?

(A) Heineke–Mikulicz strictureplasty

(B) Pylorus-preserving pancreaticoduodenectomy (Whipple procedure)

(C) Resection of the affected segment with primary anastomosis

(D) Roux-en-Y duodenojejunostomy

(E) Side-to-side retrocolic gastrojejunostomy

Answer: (A) Heineke–Mikulicz strictureplasty

Rationale:
Involvement of the duodenum in Crohn disease is usually limited to stricture formation, ulceration, and edema, as opposed to fistulization or abscess formation. Therefore, strictureplasty and bypass operations may be used rather than resection. Most strictures are limited to the first or second portion of the duodenum, and may be managed via a strictureplasty in the manner of Heineke–Mikulicz. This technique calls for a longitudinal incision on the antimesenteric border of the stricture, followed by transverse closure. Longer strictures in the duodenum should be managed with side-to-side retrocolic gastrojejunostomy. However, due to the ulcerogenic nature of this procedure, a truncal vagotomy, or preferably a highly selective vagotomy, should be performed at the same time as the gastrojejunostomy. Disease affecting the distal duodenum, but sparing the first two portions of the duodenum, are amenable to bypass via Roux-en-Y duodenojejunostomy. A vagotomy is not necessary for this procedure.

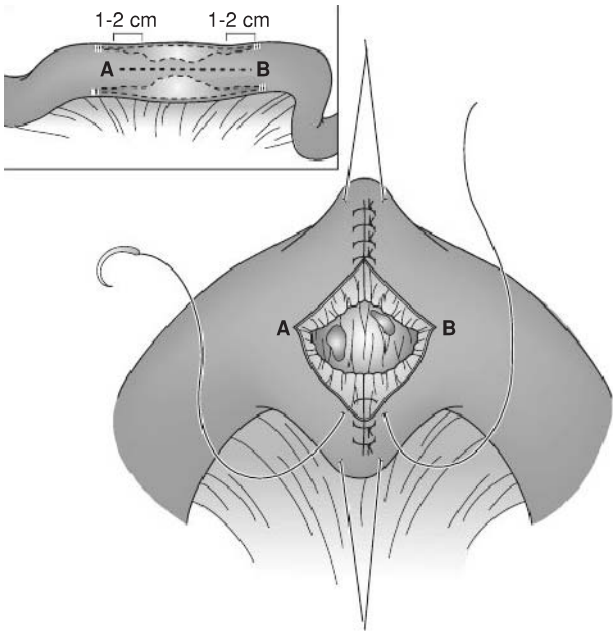

Heineke–Mikulicz strictureplasty. This technique is limited to patients with short-segment disease in close proximity. Adapted from: Milsom JW. Strictureplasty and mechanical dilation in strictured Crohn's disease. In: Michelassi F, Milsom JW, eds. *Operative Strategies in Inflammatory Bowel Disease.* New York, NY: Springer-Verlag; 1999:259–267.

Reference:
Michelassi F, Stein SL. Crohn disease. In: Mulholland MW, Lillemoe KD, Doherty GM, Maier RV, Upchurch R, eds. *Greenfield's Surgery: Scientific Principles & Practice.* 5th ed. Philadelphia, PA: Lippincott Williams & Wilkins; 2011.

۰۲۱-۶۶۱۹۸۵۱۴ www.myuptodate.com دریافت آخرین نسخه آپتودیت آفلاین

1G08

Key word: Diagnosis of Caustic Ingestion

Author: Robert A. Meguid, MD, MPH
Editor: Nicole M. Chandler, MD

A 38-year-old male presents to the emergency department after attempted suicide via ingestion of oven cleaner. Upon rigid esophagoscopy, you observe erythematous, friable, mucosa with superficial, noncircumferential white ulcerations in the mid-esophagus. What degree of injury is this lesion?

(A) Grade I
(B) Grade IIA
(C) Grade IIB
(D) Grade III
(E) Grade IV

Answer: (B) Grade IIA

Rationale:
Classically, there is a bimodal distribution of patients presenting with caustic injuries to the oropharynx and esophagus; children who ingest caustic materials accidentally, and adults who ingest them during a suicide attempt.

Patients with significant caustic ingestion may present with oropharyngeal and/or chest pain, dysphagia, and drooling. Hoarseness and stridor are associated with laryngeal and epiglottal injuries and may necessitate orotracheal intubation for airway protection. Dysphagia and hematemesis are associated with esophageal injury, with retrosternal and epigastric pain associated with full-thickness injury and/or gastric injury. Peritoneal signs, cervical emphysema, and back pain are associated with esophageal perforation. However, in 37% of patients found to have esophageal damage, there are no signs of oropharyngeal burns.

Therapy should begin as soon as diagnosis is suspected. Attempts to dilute or neutralize caustic agents are contraindicated, in part because induction of vomiting will increase exposure to the agent. Similarly, blind passage of nasogastric tubes or nasopharyngeal intubation is contraindicated due to risk of perforation and further injury.

Treatment begins with airway assessment and stabilization, and is followed by fluid resuscitation. Plain radiographs of the chest and abdomen can reveal indications for emergent exploration, such as pneumoperitoneum, pneumomediastinum, and pleural effusions, which are all consistent with esophageal perforation.

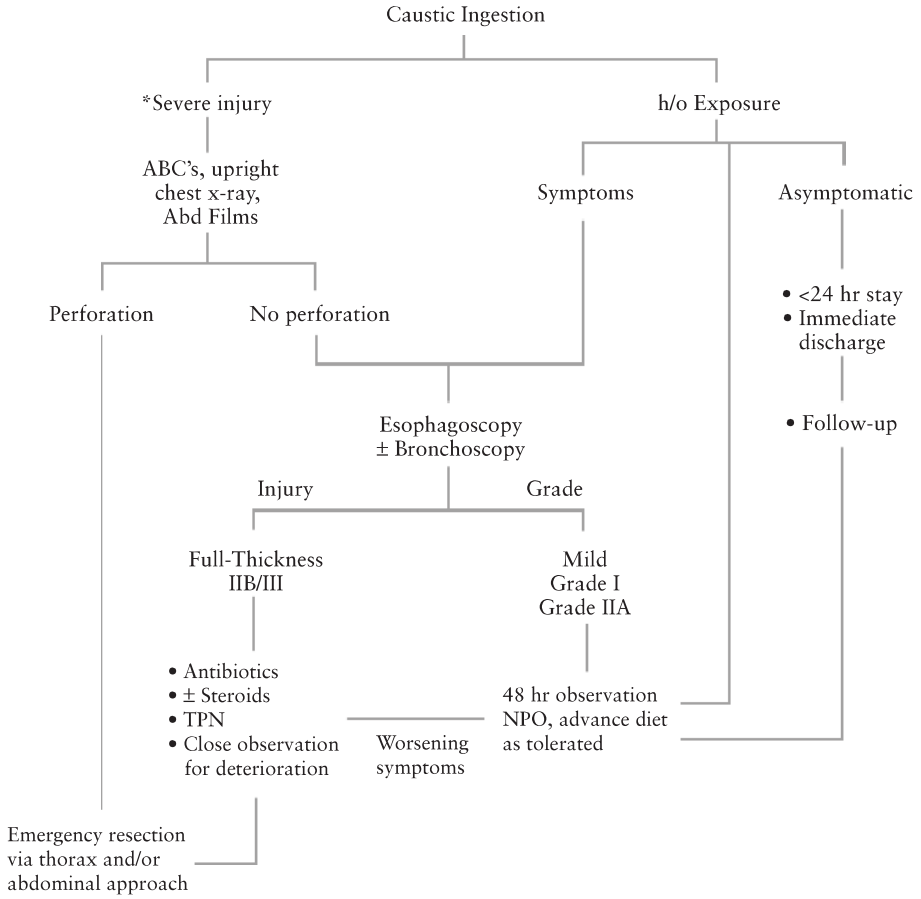

Evaluation and management of acute caustic ingestion. Adapted with permission from: Paidas CN. Caustic burns of the esophagus. In: Yang SC, Cameron DE, eds. *Current Therapy in Thoracic and Cardiovascular Surgery.* St. Louis, MO: Mosby; 2004:99.

۰۲۱-۶۶۱۹۸۵۱۴ www.myuptodate.com دریافت آخرین نسخه آپتودیت آفلاین

If there is no indication for immediate surgical intervention, patients should undergo endoscopy, preferably within 12 to 24 hours of the toxic exposure. Delay in endoscopy can increase the likelihood of iatrogenic perforation as wounds begin to remodel and soften by postinjury day 2. All symptomatic patients should undergo endoscopy. Endoscopy should not be performed past the level of the greatest injury, to minimize the risk of iatrogenic perforation.

Degrees of Esophageal Burns:

- Grade I: Superficial mucosal injury characterized by erythema and mucosal edema
- Grade IIA: As above PLUS partial-thickness noncircumferential ulceration characterized by white, patchy ulcers, mucosal sloughing, and pseudomembranes
- Grade IIB: As above PLUS deep or circumferential ulceration
- Grade IIIA: As above PLUS transmural injury characterized by full-thickness scattered necrosis, dark ulcers with eschar formation
- Grade IIIB: Extensive areas of necrosis

Between 70% and 100% of Grade IIB and 100% of Grade III injuries result in strictures.

References:

Crookes PF. Esophageal caustic injury. In: Yeo CJ, ed. *Shackelford's Surgery of the Alimentary tract.* 7th ed. Philadelphia, PA: Elsevier Inc.; 2013:486–493.

Rascoe PA, Kucharczuk JC, Kaiser L. Esophagus: tumors and injury. In: Mulholland MW, Lillemoe KD, Doherty GM, Maier RV, Upchurch GR, eds. *Greenfield's Surgery: Scientific Principles & Practice.* 5th ed. Philadelphia, PA: Lippincott Williams & Wilkins; 2011.

1G09

Key word: Etiology of Hematogenous Metastases to the Small Bowel

Author: Kelly Olino, MD
Editor: Mark D. Duncan, MD, FACS

A 40-year-old male former Australian lifeguard with a history of melanoma presents to the emergency department with a month-long history of abdominal pain, nausea, and vomiting. What is the most likely cause for his symptoms?

(A) Colonic obstruction

(B) Diverticulitis

(C) Duodenal adenocarcinoma

(D) Gastroenteritis

(E) Intussusception of the small bowel

Answer: **(E)** Intussusception of the small bowel

Rationale:

The most common extraintestinal cancer to metastasize to the small bowel is melanoma, followed by bronchogenic carcinoma and breast cancer. The route of hematologic dissemination is via the arterial blood supply from the superior mesenteric artery. In a Memorial Sloan-Kettering review of metastatic melanoma to the gastrointestinal tract, the most common presenting symptoms were intermittent small bowel obstruction, due to intussusception, and gastrointestinal bleeding–induced anemia. Although only a minority of patients was clinically diagnosed with small bowel metastases, autopsies revealed up to 50% of patients with disseminated melanoma had gastrointestinal metastases. It is, therefore, important in patients with a history of melanoma to work up all cases of abdominal pain for metastatic disease. Gastroenteritis or diverticulitis would not fit the time course stated. Duodenal or colonic adenocarcinoma is possible but unlikely given the patient's age.

References:

Agrawal S, Yao TJ, Coit DG. Surgery for melanoma metastatic to the gastrointestinal tract. *Ann Surg Oncol.* 1999;6:336–344.

Gill SS, Heuman DM, Mihas AA. Small intestinal neoplasms. *J Clin Gastroenterol.* 2001;33:267–282.

۰۲۱-۶۶۱۹۸۵۱۴ www.myuptodate.com دریافت آخرین نسخه آپتودیت آفلاین

1G10

Key word: Treatment of *C. difficile* in Pregnancy

Author: Robert A. Meguid, MD, MPH
Editor: Nicole M. Chandler, MD

A 22-week pregnant, 31-year-old woman received 7 days of ampicillin for a urinary tract infection. The patient developed diarrhea on day 5 of therapy, and stool is positive for *Clostridium difficile* toxin. How would you treat the patient?

(A) Clindamycin 300-mg PO QID for 10 days
(B) Do nothing, this is usually self-limiting
(C) Metronidazole 500-mg PO QID for 10 days
(D) Vancomycin 500-mg PO QID for 10 days
(E) Vancomycin 500-mg PR QID for 10 to 14 days

Answer: (D) Vancomycin 500-mg PO QID for 10 days

Rationale:
Diarrhea develops in 5% to 20% of patients taking antibiotics. One in approximately 1,000 of these cases is due to *C. difficile.* Most episodes of antibiotic-induced diarrhea occur after ampicillin, clindamycin, or third-generation cephalosporin use, and may present up to 6 weeks after cessation of antibiotics. In asymptomatic patients, the disease may be self-limiting and does not necessarily require antibiotic treatment.

Treatment of *C. difficile* gastrointestinal infection is with antibiotics when the disease is symptomatic. Metronidazole, 250-mg to 500-mg PO QID for 10 days is the treatment of choice for most patients. However, in patients who are pregnant or lactating, oral vancomycin 500-mg PO QID for 10 days is preferred to metronidazole. Orally and rectally administered vancomycin is not absorbed by the gastrointestinal tract. Therefore, it does not become systemic, and the risk of exposure to the fetus or accumulation in breast milk is minimal.

Other indications for use of oral vancomycin in lieu of metronidazole are in the setting of failure of metronidazole therapy after 3 to 5 days of use, and metronidazole intolerance. Metronidazole-resistant isolates of *C. difficile* have been identified; thus vancomycin therapy should be used for refractory or recurrent cases.

While clindamycin 300-mg PO QID for 10 days is effective and safe to use in pregnant patients based on animal studies, it is more likely to cause this disease than to treat it.

References:
Bartlett JG. Clinical practice. Antibiotic-associated diarrhea. *N Engl J Med.* 2002;346(5):334–339.
Christou NV. Antibiotics. In: Souba WW, ed. *ACS Surgery: Principles and Practice.* Decker Intellecutal Properties, 2010. Accessed August 27, 2013. Online Edition.
Garey KW, Jiang Z-D, Yadav Y, et al. Peripartum *Clostridium difficile* infection: Case series and review of the literature. *Am J Obstet Gynecol.* 2008;199:332–337.
Green SM, ed. *Tarascon pocket pharmacopoeia.* 2005 classic shirt-pocket edition, Lompoc, CA: Tarascon; 2005:33–35.

1G11

Key word: Treatment of Anal Fissure with Rectal Bleeding

Author: Robert A. Meguid, MD, MPH
Editors: Christopher L. Wolfgang, MD, PhD, and Matthew J. Weiss, MD

A 43-year-old man presents to your clinic complaining of intermittent blood spotting on toilet paper for 2 weeks. Anoscopy reveals a 1-cm split in the anoderm posteriorly on the midline distal to the dentate line, lacking any hypertrophy or visible muscle fibers. What is the optimal management?

(A) Bisacodyl suppositories
(B) Initiate stool softeners
(C) Lateral internal anal sphincterotomy
(D) Observation only
(E) Resection of affected tissue

Answer: (B) Initiate stool softeners

Rationale:
Anal fissures result from laceration of the anoderm by large hard stools in combination with inability to properly relax the anal sphincter. Fissures are diagnosed via anoscopy, and are usually located midline posteriorly or anteriorly.

Acute anal fissures, existing less than 4 weeks, are best managed nonoperatively with stool softeners, increased dietary water intake, sitz baths, and application of topical anesthetic ointments. Suppositories are to be avoided as they irritate the fissure.

On the other hand, chronic anal fissures, of greater than 4 weeks duration, are characterized by the presence of a sentinel skin tag with an adjacent hypertrophied anal papilla. Often, internal anal sphincter fibers are visible at the base of chronic anal fissures. Chronic fissures respond poorly to conservative management. Operative management entails lateral internal anal sphincterotomy, with a cure rate of up to 98%. Recent effective therapy has also been obtained with local injection of botulinum toxin (Botox).

Reference:
Kodner IJ. Anal procedures for benign disease. In: Souba WW, ed. *ACS Surgery: Principles and Practice.* Decker Intellecutal Properties, 2009. Accessed August 27, 2013. Online Edition.

۰۲۱-۶۶۱۹۸۵۱۴ www.myuptodate.com دریافت آخرین نسخه آپتودیت آفلاین

1G12

Key word: Treatment of Esophageal Perforation

Author: Robert A. Meguid, MD, MPH
Editors: Stephen M. Cattaneo II, MD, and Robert A. Meguid, MD, MPH

A 54-year-old alcoholic man presents to the emergency department with severe substernal and epigastric pain after vomiting while drinking earlier that evening. Gastrografin esophagogram shows perforation of the distal esophagus with drainage into the left pleural space. What is the most appropriate treatment?

(A) Emergent primary repair via left thoracotomy

(B) Esophageal stent placement

(C) Esophagectomy and delayed reconstruction with interposition graft

(D) Esophagostomy and placement of a feeding jejunostomy tube

(E) Nonoperative management with total parenteral nutrition and nasogastric decompression

Answer: (A) Emergent primary repair via left thoracotomy

Rationale:
Causes of esophageal perforation, by incidence, are medical instrumentation (43%), trauma (19%), spontaneous (e.g., vomiting) (16%), surgical (8%), foreign body (7%), tumor (4%), and others (3%). Perforation due to diagnostic endoscopy usually occurs at or just proximal to a pathologic process. Other locations where instrumentation may cause perforation include Killian triangle, formed by the inferior constrictors and cricopharyngeus muscle, and other sites of anatomic narrowing including at the level of the aortic arch and just proximal to esophagogastric junction. Causes of spontaneous rupture are related to rapidly increased intraluminal pressure and include vomiting, coughing, seizures, weight lifting, and childbirth, among others. Location of spontaneous rupture is usually either at the distal esophagus on the left, or just above the level of the esophagogastric junction. Seventy percent of perforations are on the left, 20% on the right, and 10% bilateral.

The clinical presentation of esophageal perforations is dependent upon location of the tear and degree of associated contamination. Cervical perforation results in cervical pain and tenderness, pain and difficulty on swallowing, and sometimes crepitus. Fevers develop early, and pleural effusions may develop up to 24 hours after the injury. Patients who experience spontaneous rupture are usually middle-aged males with a recent history of vomiting. These patients present with substernal and epigastric pain, pleural effusions, and mediastinal emphysema. As these patients often appear late relative to the timing of their perforation, they often have fevers and tachycardia and early signs of sepsis and fare poorly.

The key to successful patient management is suspicion and early diagnosis. After history and physical examination, posterior–anterior and lateral chest x-rays should be obtained. Chest films reveal pneumothorax (77%), mediastinal emphysema (40%), or no abnormalities (10%). Following suspicious chest x-ray, a contrast espohagogram should be performed (first using water-based contrast such as gastrografin, and then repeated with thin barium if no leak is seen initially). Leaks are seen on esophagogram in 90% of patients with thoracic esophageal perforation, but this modality is less sensitive for cervical leaks. CT may aid in identifying cases where an esophagogram is equivocal, but is seldom diagnostic alone.

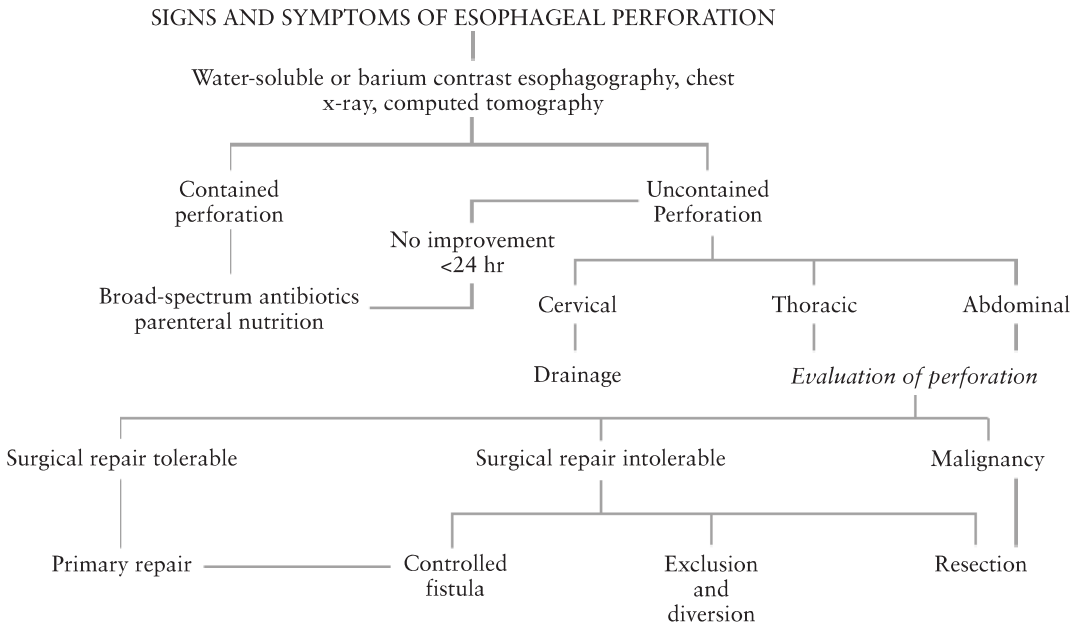

Evaluation and treatment of esophageal perforation. Adapted with permission from: Brinster CJ, Singhal S, Lawrence L, et al. Evolving options in the management of esophageal perforation. *Ann Thorac Surg*. 2004;77:1475.

۰۲۱-۶۶۱۹۸۵۱۴ www.myuptodate.com دریافت آخرین نسخه آپتودیت آفلاین

Principals underlying treatment are preventing further contamination, debriding infected and necrotic tissue, providing appropriate nutritional support, and restoring the continuity of the gastrointestinal tract. The surgeon must also establish whether the perforation occurred in the setting of a normal esophagus or secondary to a tumor, stricture, or motility dysfunction. Initial management includes NPO status, intravenous fluid resuscitation, careful placement of a nasogastric tube put to sump-suction, and administration of broad-spectrum antibiotics.

Nonoperative management is a viable option for patients with small intramural or transmural perforations contained in the mediastinum with good drainage back into the esophagus, no distal obstruction or malignancy, and no signs of sepsis. Patients meeting these criteria should be maintained NPO, with TPN and H_2 blockers. Re-evaluation is via esophagogram after 7 to 14 days. Endoscopic stenting may be a viable option in similar patients.

Repair of esophageal perforation occurring within 24 hours is associated with a 92% survival rate. A left thoracotomy is performed for ruptures of the distal third of the esophagus, with debridement of devitalized tissues, primary repair of the perforation, and reinforcement with tissue buttress such as parietal pleura or an intercostal muscle flap. Mediastinal debridement and drainage is necessary. Intra-abdominal esophageal perforations are repaired through a midline abdominal incision. In the setting of a highly unstable patient with a massively contaminated field, diversion by esophagostomy or esophageal stenting, with tube thoracostomy drainage of the chest may be the best option.

In the event of delayed diagnosis (>24 hours), esophagectomy with delayed reconstruction has a more favorable outcome than primary repair (13% mortality vs. 68%).

References:

Rascoe PA, Kucharczuk JC, Kaiser L. Esophagus: Tumors and injury. In: Mulholland MW, Lillemoe KD, Doherty GM, Maier RV, Upchurch GR, eds. *Greenfield's Surgery: Scientific Principles & Practice.* 5th ed. Philadelphia, PA: Lippincott Williams & Wilkins; 2011.

Wright CD. Management of esophageal perforation. In: Sugarbaker DJ, Bueno R, Krasna MJ, Mentzer SJ, Zellos L, eds. *Adult Chest Surgery.* New York, NY: McGraw Hill; 2009:353–360.

1G13

Key word: Arterial Supply for a Gastric Tube

Author: Susanna M. Nazarian, MD, PhD
Editors: Timothy M. Pawlik, MD, MPH, PhD, and Matthew J. Weiss, MD

A 60-year-old man with a long history of smoking and heavy alcohol use undergoes a transhiatal esophagectomy for esophageal cancer. He does well and is discharged from the intensive care unit on the second postoperative day. However, on the third day he develops a fever and malaise. A chest and neck CT scan demonstrates severe inflammation as indicated by stranding around, and wall thickening of, the gastric conduit but no intramural air. Which vascular supply to the stomach may have been compromised during the transhiatal esophagectomy?

(A) Gastroduodenal artery
(B) Left gastric artery
(C) Left gastroepiploic artery
(D) Right gastroepiploic artery
(E) Short gastric arteries

Answer: (D) Right gastroepiploic artery

Rationale:

The stomach is extremely well vascularized, deriving blood from the left and right gastric arteries, the left and right gastroepiploic and the short gastric arteries. The anterior wall of the stomach is supplied primarily by the right gastroepiploic artery, which is a terminal branch of the gastroduodenal artery, which branches off the common hepatic artery. The right gastroepiploic artery supplies the greater curvature of the stomach, along with the left gastroepiploic, which derives from the splenic artery. The right and left gastric arteries supply the lesser curvature. The right gastric artery branches off the proper hepatic artery, while the left gastric is one of the three primary divisions of the celiac trunk. The short gastric arteries also supply the greater curvature, stemming from the splenic artery.

A transhiatal esophagectomy, however, requires mobilization of the stomach for creation of the conduit and ligation of many vessels. This patient is suffering from necrosis of his esophageal replacement conduit. During dissection, all of the short gastric arteries are ligated, as are the left gastroepiploic and left gastric arteries. Care must be taken during dissection along the inferior aspect of the stomach within the greater omentum where the left and right gastroepiploic meet so as not to injure the right-sided vessel. The right gastric and right gastroepiploic arteries are responsible for supplying the gastric conduit once it is mobilized into the neck. Another cause for conduit necrosis can be division of the left gastroepiploic vessels too close to the stomach or excessive traction on the stomach.

۰۲۱-۶۶۱۹۸۵۱۴ www.myuptodate.com دریافت آخرین نسخه آپتودیت آفلاین

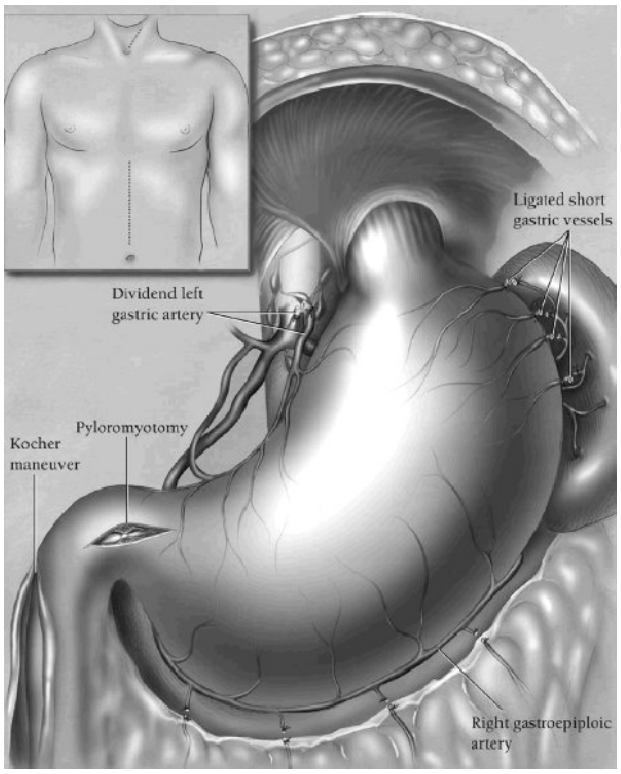

Diagram depicting the peritoneal incision (inset) and operative anatomy for the abdominal phase of the procedure. From: Orringer MB. Transhiatal esophagectomy without thoracotomy. *Oper Tech Thorac Cardiovasc Surg.* 2005;10:63, with permission.

References:

Netter FH. *Atlas of Human Anatomy.* 2nd ed. Plates 282–283. East Hanover, NJ: Novartis; 1997.

Orringer MB. Transhiatal esophagectomy without thoractomy. In: Fischer JE, Bland KI, eds. *Mastery of Surgery.* 5th ed. Philadelphia, PA: Lippincott Williams & Wilkins; 2007:773–774.

1G14

Key word: Diagnosis of Colonic Pseudo-obstruction

Author: Susanna M. Nazarian, MD, PhD
Editors: Christopher L. Wolfgang, MD, PhD, and Matthew J. Weiss, MD

You are called by the intensive care unit (ICU) regarding a 45-year-old man intubated for ARDS for the past 3 weeks. Over the past 48 hours, he has developed increased abdominal distension. His last bowel movement was 4 days ago, and the ICU staff has attempted multiple enemas without result. An abdominal plain film has revealed diffuse dilation of the colon consistent with ileus, without an identifiable transition point. Your physical examination demonstrates a critically ill man with a rotund abdomen. There is no fluid wave or shifting dullness, just diffuse tympany. There is no stool in the rectal vault. How should you proceed with treatment?

(A) Endoscopic decompression

(B) Manual disimpaction

(C) Nasogastric tube decompression and serial examinations

(D) Neostigmine

(E) Therapeutic enteroclysis

Answer: (C) Nasogastric tube decompression and serial examinations

Rationale:

Acute colonic pseudo-obstruction, also known as Ogilvie syndrome, arises spontaneously in critically ill patients. In spite of signs and symptoms of bowel obstruction, there is no actual mechanical obstruction. Signs and symptoms mimic those of true mechanical obstruction: Distension, diarrhea, nausea, vomiting, abdominal pain, and tenderness to palpation. Colonic distension is often localized to the right side.

Although the etiology is incompletely understood, the condition may derive from the dysregulation of the autonomic nervous syndrome combined with pharmacologic or metabolic factors. The risk of spontaneous colonic perforation is 3%, with an ensuing mortality of up to 50%.

The surgical consultant must rule out true obstruction in evaluating potential Ogilvie syndrome. The cecum should be carefully evaluated for size, and concern should be raised if the acute distention results in a cecal diameter greater than 12 cm. Most cases respond to conservative treatment within 3 days, including a nasogastric tube, promotility agents, and enemas. The surgeon must monitor the patient closely for untoward changes with serial abdominal examinations. Should the problem persist, 2.5 mg of the acetylcholinesterase inhibitor neostigmine may be administered. This agent can have significant side effects such as bradycardia, bronchial secretions, asthma exacerbation, salivation, and of course gastrointestinal output. If still unresolved, endoscopic decompression should be attempted. Surgical treatment is indicated

۰۲۱-۶۶۱۹۸۵۱۴ www.myuptodate.com دریافت آخرین نسخه آپتودیت آفلاین

only in the event of refractory pseudo-obstruction or in the case of spontaneous perforation.



Pseudo-obstruction of the colon (Ogilvie syndrome). Reprinted with permission from: Wick EC. Colonic and rectal anatomy and physiology. In: Mulholland MW, Lillemoe KD, Doherty GM, Maier RV, Upchurch GR, eds. *Greenfield's Surgery: Scientific Principles & Practice*. 5th ed. Philadelphia, PA: Lippincott Williams & Wilkins, 2011:1025.

References:

Mehta R, John A, Nair P, et al. Factors predicting successful outcome following neostigmine therapy in acute colonic pseudo-obstruction: A prospective study. *J Gastroenterol Hepatol.* 2006;21(2):459–461.

Soybel DL, Landman WB. Ileus and bowel obstruction. In: Mulholland MW, Lillemoe KD, Doherty GM, Maier RV, Upchurch GR, eds. *Greenfield's Surgery: Scientific Principles & Practice.* 5th ed. Philadelphia, PA: Lippincott Williams & Wilkins; 2011.

Tack J. Acute colonic pseudo-obstruction (Ogilvie's syndrome). *Curr Treat Options Gastroenterol.* 2006;9(4):361–368.

Wick EC. Colonic and rectal anatomy and physiology. In: Mulholland MW, Lillemoe KD, Doherty GM, Maier RV, Upchurch GR, eds. *Greenfield's Surgery: Scientific Principles & Practice.* 5th ed. Philadelphia, PA: Lippincott Williams & Wilkins; 2011.

1G15

Key word: Treatment of Gallstone Ileus

Author: Susanna M. Nazarian, MD, PhD
Editors: Thomas H. Magnuson, MD, and Kenzo Hirose, MD, FACS

An 88-year-old woman presents from a nursing home with altered mental status and abdominal distension. She has a history of gallstones and has never had abdominal surgery. On examination, she is febrile and tachycardic and has a distended, tender abdomen that is tympanitic to percussion. A plain abdominal film demonstrates dilated loops of small bowel with air in the biliary tree. What is your proposed management?

(A) A trial of nasogastric tube decompression, IV fluids, bowel rest

(B) ERCP and stent placement

(C) Exploratory laparotomy

(D) Family meeting and likely comfort care measures only given extremely poor prognosis

(E) Laparoscopic cholecystectomy

Answer: (C) Exploratory laparotomy

Rationale:

This woman has likely developed gallstone ileus and warrants surgical exploration. This condition develops most often in the elderly who have a history of gallstones and is characterized by the triad of small bowel obstruction, pneumobilia, and an ectopic gallstone. A laminated, calcified mass is visualized on CT scan, and occasionally on plain film. The gallstone may travel through the common duct, or via a cholecystoenteric fistula (a choledoduodenal fistula was found in 68% of patients in one study). The terminal ileum at the ileocecal valve is the most common site of obstruction.

Spontaneous passage of the stone occurs rarely (7%) so an emergent laparotomy for stone removal is warranted. An accompanying cholecystectomy and resection of the fistula is controversial, as cholangitis may result from passage of intestinal contents into the biliary tree. Fortunately, gallstone ileus is a rare complication, presenting in fewer than 6 of 1,000 cases of cholelithiasis and is associated with less than 3% of intestinal obstruction.

۰۲۱-۶۶۱۹۸۵۱۴ www.myuptodate.com دریافت آخرین نسخه آپتودیت آفلاین



A: Plain radiograph of a patient with gallstone ileus, showing obstructed loops of small intestine (*black arrow*) in the abdomen and a gallstone (*white arrow*) in the pelvis (gallstone was initially misinterpreted as an EKG lead [*black arrow*]). **B:** Computed tomography (CT) scan showing a cholecystoduodenal fistula (*black arrow*) with air in the biliary tree (D, Duodenum). **C:** CT scan showing gallstone (*white arrow*) in the distal ileum and fecalization of luminal content adjacent to the stone. Reprinted with permission from: Soybel DI, Landman WB. Ileus and bowel obstruction. In: Mulholland MW, Lillemoe KD, Doherty GM, Maier RV, Upchurch GR, eds. *Greenfield's Surgery: Scientific Principles & Practice.* 5th ed. Philadelphia, PA: Lippincott Williams & Wilkins, 2011:760.

References:

Ishikura H, Sakata A, Kimua S, et al. Gallstone ileus of the colon. *Surgery.* 2005;138(3):540–542.

Soybel DI, Landman WB. Ileus and bowel obstruction. In: Mulholland MW, Lillemoe KD, Doherty GM, Maier RV, Upchurch GR, eds. *Greenfield's Surgery: Scientific Principles & Practice.* 5th ed. Philadelphia, PA: Lippincott Williams & Wilkins; 2011.

۰۲۱-۶۶۱۹۸۵۱۴ www.myuptodate.com دریافت آخرین نسخه آپتودیت آفلاین

1G16

Key word: Treatment of Retained Common Bile Duct Stone after T-tube

Author: Susanna M. Nazarian, MD, PhD
Editor: Michael A. Choti, MD, MBA

A 54-year-old woman comes to clinic 3 weeks after undergoing a common bile duct exploration for biliary stones refractory to endoscopic management. She was left with a T-tube in place, which has been reliably draining bile until 2 days ago. Over the past 48 hours, she has noted increased right upper quadrant pain that is similar to her preoperative pain. You order a tube cholangiogram, which demonstrates a retained stone lodged in the common bile duct. How should you proceed?

(A) Admit to the hospital, make NPO with IVF, provide analgesia and observe

(B) Endoscopic retrograde cholangiopancreatography (ERCP)

(C) Laparoscopic stone extraction

(D) Remove the T-tube and perform immediate choledochoscopy

(E) Repeat open common bile duct exploration

Answer: (D) Remove the T-tube and perform immediate choledochoscopy

Rationale:
The common bile duct exploration assists in gallstone removal, particularly when ERCP is not feasible. Postoperatively, the surgeon may place a T-tube within the choledochotomy in order to drain bile and prevent bile leakage. In addition, persistently retained stones may be removed via the T-tube tract. Once the tract has been well established, it is reasonable to approach stone extraction percutaneously. Typically the tract is well established between 2 and 3 weeks postoperatively. In this event, the surgical endoscopist would remove the T-tube while maintaining the patency of the tract. After dilation, the endoscope can be introduced to retrieve retained stones. Alternately, ERCP may be used for postoperative stone retrieval, particularly in the absence of a T-tube. Although laparoscopic common bile duct exploration and stone extraction is successful in some hands, at this point it is not a commonly accepted technique.

A retained stone is a likely culprit if a patient postoperative from gallstone surgery is draining a high amount of bile through a drain, develops postoperative jaundice, or has clinical signs of cholangitis. In a review of such patients published in 2002, Yamaner et al. found that 46.6% (195 patients) had a retained common bile duct stone on ERCP.

References:

Garden OJ. Cholecystotomy, cholecystectomy and intraoperative evaluation of the biliary tree. In: Fischer JE, Bland KI, eds. *Mastery of Surgery.* 5th ed. Philadelphia, PA: Lippincott Williams & Wilkins; 1114.

Tu Z, Li J, Zin H, et al. Primary choledochorrhaphy after common bile duct exploration. *Dig Surg.* 1999;16(2):137–139.

Yamaner S, Bilsel Y, Bulut T, et al. Endoscopic diagnosis and management of complications following surgery for gallstones. *Surg Endosc.* 2002;16:1685–1690.

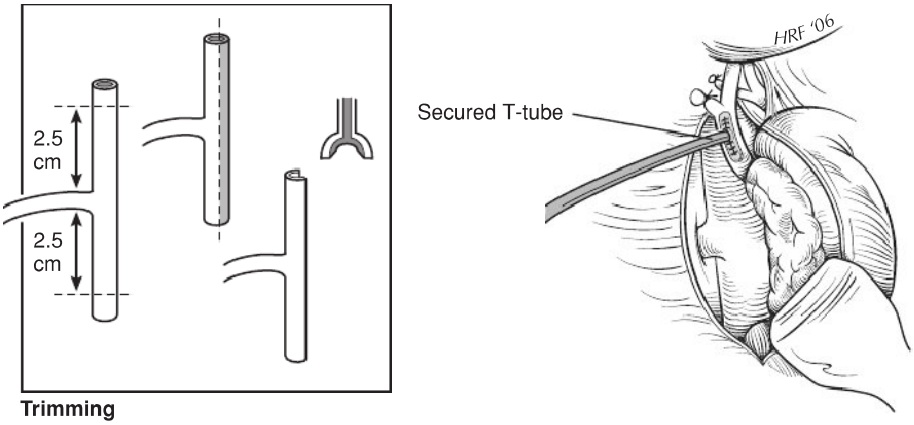

The T-Tube is trimmed and secured in the choledochotomy by placement of interrupted 4–0 polydioxanone. Reprinted with permission from: Garden OJ. Cholecystostomy, cholecystectomy and intraoperative evaluation of the biliary tree. In: Fischer JF, Bland KI, eds. *Mastery of Surgery.* 5th ed. Philadelphia, PA: Lippincott Williams & Wilkins, 2007:1113.

۰۲۱-۶۶۱۹۸۵۱۴ www.myuptodate.com دریافت آخرین نسخه آپتودیت آفلاین

1G17

Key word: Treatment of Squamous Cell Carcinoma of the Anal Canal

Authors: Susanna M. Nazarian, MD, PhD, and Robert A. Meguid, MD, MPH
Editor: Susan L. Gearhart, MD

A 65-year-old man presents with rectal pain, pencil-thin stools, and occasional bright red blood per rectum. A rectal examination under anesthesia reveals a 1-cm raised lesion at the anal verge, and extending for 3 cm proximally. There are no palpable lymph nodes or signs of systemic disease. Biopsy demonstrates squamous cell carcinoma. Which of the following is the standard therapy for this disease?

(A) Abdominoperineal resection with permanent colostomy

(B) Abdominoperineal resection with total mesorectal excision and bilateral inguinal lymph node dissection

(C) Chemoradiation therapy with 5-fluorouracil and mitomycin C

(D) Chemotherapy with 5-fluorouracil and cisplatin

(E) Low anterior resection

Answer: (C) Chemoradiation therapy with 5-fluorouracil and mitomycin C

Rationale:
In the absence of nodal disease, T2 cancer of the anal canal can be treated with chemoradiation therapy with 5-fluorouracil and mitomycin C. Cisplatin may be used in place of

American Joint Committee on Cancer Staging of Anal Canal Cancer

Primary Tumor (T)			
TX	Primary tumor cannot be assessed		
T0	No evidence of primary tumor		
TIS	Carcinoma in situ		
T1	Tumor ≤2 cm in greatest dimension		
T2	Tumor >2 cm but not >5 cm in greatest dimension		
T3	Tumor >5 cm in greatest dimension		
T4	Tumor of any size invades adjacent organ(s)		
Lymph Nodes (N)			
NX	Regional lymph nodes cannot be assessed		
N0	No regional lymph node metastasis		
N1	Metastasis in perirectal lymph node(s)		
N2	Metastasis in unilateral internal iliac and/or inguinal lymph node(s)		
	Metastasis in perirectal and inguinal lymph nodes and/or bilateral nodes internal iliac and/or inguinal lymph nodes		
Distant Metastasis (M)			
MX	Presence of distant metastasis cannot be assessed		
M0	No distant metastasis		
M1	Distant metastasis		
Stage Grouping			
0	TIS	N0	M0
I	T1	N0	M0
II	T2	N0	M0
	T3	N0	M0
IIIA	T1	N1	M0
	T2	N1	M0
	T3	N1	M0
	T4	N0	M0
IIIB	T4	N1	M0
	Any T	N2	M0
	Any T	N3	M0
IV	Any T	Any N	M1

Reprinted with permission from Silberfein EJ, Chang GJ, You YQN, et al. Cancer of the colon, rectum, and anus. In: Feig BW, Ching CD, eds. *The MD Anderson Surgical Oncology Handbook*, 5th ed. Philadelphia, PA: Lippincott Williams & Wilkins, 2012:402.

۰۲۱-۶۶۱۹۸۵۱۴ www.myuptodate.com دریافت آخرین نسخه آپتودیت آفلاین

mitomycin C, especially as salvage chemotherapy. Wide local excision is reserved for patients with T1 and small T2 lesions and those with persistent disease following chemoradiation. Although abdominoperineal resection with permanent colostomy was the standard of care in the past, the desire to avoid permanent colostomy has led to trials supporting chemoradiation therapy alone. Abdominoperineal resection is reserved for disease recurrences. Inguinal lymph node dissection is directed at patients with inguinal nodal involvement.

Reference:

Silberfein EJ, Chang GJ, You Y-QN, et al. Cancer of the colon, rectum, and anus. In: Feig BW, Ching CD, eds. *The M.D. Anderson Surgical Oncology Handbook*. 5th ed. Philadelphia, PA: Wolters Kluwer Lippincott Williams & Wilkins; 2012.

1G18

Key word: Most Common Etiology of Common Bile Duct Injury in Laparoscopic Cholecystectomy

Author: Susanna M. Nazarian, MD, PhD
Editor: Mark D. Duncan, MD, FACS

What is the most common etiology of common bile duct injury during laparoscopic cholecystectomy?

(A) Acute or chronic inflammation
(B) Bleeding
(C) Congenital anatomic anomalies
(D) Excess cephalad retraction of the gallbladder
(E) Obesity

Answer: (D) Excess cephalad retraction of the gallbladder

Rationale:

Although all the options above may contribute to the surgeon mistaking the common bile duct for the cystic duct, the classic mistake is to retract too forcibly on the fundus in the cephalad direction. This causes the common bile duct and cystic duct to align in the same plane, making their identity difficult to discern. This arrangement may lead to inadvertent clipping and transection of the common bile duct. Misidentification of ductal anatomy can be minimized by achieving the "critical view" achieved by dissecting along the inferior and medial aspects of the gallbladder between the liver bed and gallbladder/cystic duct junction. Visualizing the window in Calot triangle (the "critical view") should demonstrate only the cystic duct and cystic artery going to the gallbladder.

The occurrence of bile duct injury during laparoscopic cholecystectomy ranges from 0.3% to 0.7%.

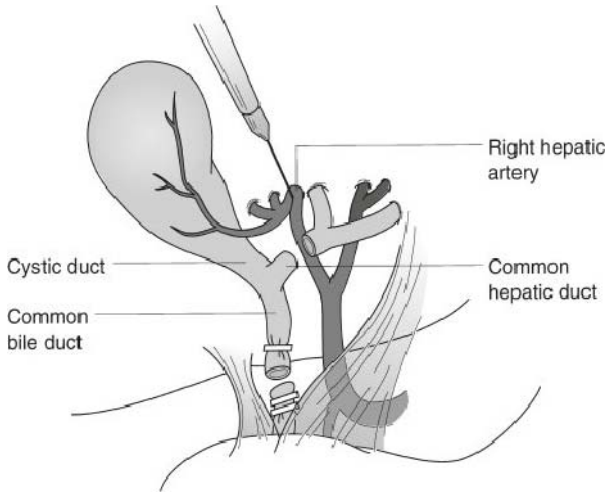

Classic laparoscopic bile duct injury. The common bile duct is mistaken for the cystic duct and transected. A variable extent of the extrahepatic biliary tree is resected with the gallbladder. The right hepatic artery, in background, is also often injured. Adapted from: Branum G, Schmidt C, Baillie J, et al. Management of major biliary complications after laparoscopic cholecystectomy. *Ann Surg*. 1993;217:532.

۰۲۱-۶۶۱۹۸۵۱۴ www.myuptodate.com دریافت آخرین نسخه آپتودیت آفلاین

Reference:
Lillemoe KD. Biliary injuries and strictures and sclerosing cholangitis. In: Mulholland MW, Lillemoe KD, Doherty GM, Maier RV, Upchurch GR, eds. *Greenfield's Surgery: Scientific Principles & Practice.* 5th ed. Philadelphia, PA: Lippincott Williams & Wilkins; 2011.

1G19

Key word: Treatment of Duodenojejunal Adenocarcinoma

Author: Robert A. Meguid, MD, MPH
Editor: Michael A. Choti, MD, MBA

A 76-year-old man undergoes exploratory laparotomy for a suspected bowel obstruction. During the operation, you discover a mass in the duodenum just proximal to the ligament of Treitz, with no palpable lymphadenopathy. Intraoperative pathology confirms adenocarcinoma. What is the best course of management for this patient?

(A) Gastrojejunostomy

(B) Local resection with primary repair

(C) Pancreaticoduodenectomy

(D) Surgical resection with duodenojejunostomy

(E) Surgical resection with intraoperative chemotherapy

Answer: (D) Surgical resection with duodenojejunostomy

Rationale:
Of the malignant tumors of the small bowel, approximately 50% are adenocarcinomas. Forty percent of these occur in the duodenum, of which two-thirds are periampullary lesions. Most patients with small bowel adenocarcinoma present with advanced disease (stage III or IV). When possible, surgical resection is the treatment of choice. Ideally, preoperative diagnosis and staging is best in order to determine resectability and plan therapy. In this case, the diagnosis was made intraoperatively without the advantage of imaging to rule out extent of disease. However, if the tumor appears resectable at surgery, this approach can be considered. Principles of surgical therapy include en bloc resection incorporating the mesentery. In case of tumors located in the first and second portions of duodenum, pancreaticoduodenectomy will likely be required. For tumors in the distal duodenum or proximal jejunum as in this case, pancreas preserving resection with duodenojejunostomy is preferred, often requiring the anastomosis to the second portion of the duodenum. When unresectable and resulting in obstruction, gastrojejunostomy can offer palliation.

References:
Hrabe JE, Cullen JJ. Management of small bowel tumors. In: Cameron JL, Cameron AM, eds. *Current Surgical Therapy.* 10th ed. Philadelphia, PA: Mosby; 2011;106–109.
Spalding DR, Isla AM, Thompson JN, et al. Pancreas-sparing distal duodenectomy for infrapapillary neoplasms. *Ann R Coll Surg Engl.* 2007;89(2):130–135.

۰۲۱-۶۶۱۹۸۵۱۴ www.myuptodate.com دریافت آخرین نسخه آپتودیت آفلاین

1G20

Key word: Treatment of a Dark Stoma Following Abdominoperineal Resection

Author: Robert A. Meguid, MD, MPH
Editor: Mark D. Duncan, MD, FACS

Two days after undergoing an abdominoperineal resection, a 64-year-old man's colostomy stoma is dusky. On evaluation at the bedside on postoperative day 3, the dark bowel extends below the level of the abdominal wall fascia. What is the most appropriate management?

(A) Arteriography
(B) Bedside debridement
(C) Exploration and revision in the operating room
(D) Initiate wet-to-dry dressings to stoma
(E) Observation

Answer: (C) Exploration and revision in the operating room

Rationale:
Dark bowel in a colostomy signals poor perfusion of the terminal bowel, either due to disruption of the vascular arcade during surgical skeletonization, or from passing the bowel through too small an aperture in the abdominal wall fascia. While retraction of bowel below the level of the skin will result in chronic irritation in ileostomies, this is usually not the case with colostomies. Necrosis of colon below the level of the skin but above the fascia leads to a retracted stoma. However, this bowel will remain viable and does not require urgent repair, and may be managed by observation. On the other hand, necrosis of bowel below the fascia must be corrected by surgical revision of the stoma. A good dictum regarding the creation of colostomies is that the colostomy will not look better 2 days postoperatively than it does in the operating room. Any stoma that appears dusky in the operating room will only worsen in the postoperative period, and warrants strong consideration for immediate revision.

Intraoperatively, attention should be paid to the health of the remaining colon, the mesenteric vessels, and alignment such that undue stretch or torsion on the mesentery is avoided.

Reference:
Kann BR. Early stomal complications. *Clin Colon Rectal Surg.* 2008; 21(1): 23–30.

1G21

Key word: Diagnosis of Acute Gastric Dilation

Author: Robert A. Meguid, MD, MPH
Editors: Christopher L. Wolfgang, MD, PhD, and Matthew J. Weiss, MD

After undergoing resection of the right middle lobe of her lung, a 65-year-old woman complains of acute abdominal pain while eating breakfast in the morning. Her stomach is distended and tympanitic, she is bradycardic, hypotensive, tachypneic, and sweating profusely. What is the most appropriate next course of action?

(A) Emergency exploratory surgery
(B) Increase the patient's pain medication
(C) Obtain supine and erect abdominal x-rays
(D) Perform esophagogastroscopy
(E) Place a nasogastric tube

Answer: (E) Place a nasogastric tube

Rationale:
The patient is experiencing acute gastric dilation. Acute gastric dilation can occur in patients following any surgical procedure involving anesthetics and analgesics. The cause is sudden distension of the stomach, resulting in a vagal response. The ensuing symptoms are abdominal pain, tachypnea, pallor, sweating, bradycardia, and hypotension. If untreated, acute gastric dilation can lead to vomiting, which can result in aspiration, bleeding from erosive gastritis, and possible esophageal perforation.

Initial diagnosis relies on clinical acumen as well as examination. Classically, patients have a distended and tympanitic stomach. Confirmation of diagnosis may be obtained by placement of a nasogastric tube, resulting in rapid decompression. In addition, nasogastric decompression is the treatment for acute gastric dilation, which usually lasts 24 to 48 hours until motility is regained.

Reference:
Moody FG, McGreevy, JM, Miller TA. Stomach. In: Schwartz SI, Shires GT, Spencer FC, eds. *Principles of Surgery.* 5th ed. New York, NY: McGraw-Hill; 1989:1157–1188.

۰۲۱-۶۶۱۹۸۵۱۴ www.myuptodate.com دریافت آخرین نسخه آپتودیت آفلاین

1G22

Key word: Diagnosis of Common Bile Duct Stricture from Chronic Pancreatitis

Author: Susanna M. Nazarian, MD, PhD
Editor: Michael A. Choti, MD, MBA

A 48-year-old alcoholic man with painless jaundice appears to have intrahepatic biliary ductal dilation on computed tomography (CT) scan. The bilirubin is 12.6 with other liver function tests normal. On review of the CT scan, you can detect no obstructing mass. Magnetic resonance cholangiopancreatography (MRCP) demonstrates no stones in his biliary tree with dilation extending to the pancreas. The most likely cause of his ductal dilation is:

(A) Benign common bile duct stricture
(B) Gallbladder carcinoma
(C) Klatskin tumor
(D) Pancreatic cancer
(E) Pancreatic pseudocyst

Answer: (A) Benign common bile duct stricture

Rationale:

Strictures of the common bile duct are a relatively frequent complication of chronic pancreatitis, occurring between 3% and 29% of the time in patients with chronic alcoholic pancreatitis. This is due to the close anatomical relationship of the common bile duct and pancreas in 90% of the population. In addition, the duct lies within a posterior groove of the pancreas in 25% of the time. On CT, common bile duct strictures due to chronic pancreatitis are characterized by long, tapering strictures, rather than the abrupt terminations seen in malignant strictures. Of note, chronic pancreatitis causes only 10% of all cases of bile duct strictures.

Strictures of the common bile duct may be diagnosed through a variety of modalities, including endoscopic retrograde cholangiopancreatography (ERCP), percutaneous transhepatic cholangiography (PTC), CT, or endoscopic ultrasound (EUS). Serum alkaline phosphatase is elevated in 80% of patients with common bile duct strictures. It is important to rule out other causes of obstructive jaundice in these patients, including malignancy. While less likely, this patient may still have pancreatic cancer and this diagnosis should always be considered in such a case. Pancreatic pseudocysts, while occasionally presenting with jaundice, will typically have an associated cystic lesion identified on cross-sectional imaging. Common bile duct strictures may be treated acutely with endoscopic dilation and stenting, but may require surgical therapy via choledochoduodenostomy or choledochojejunostomy in refractory cases.

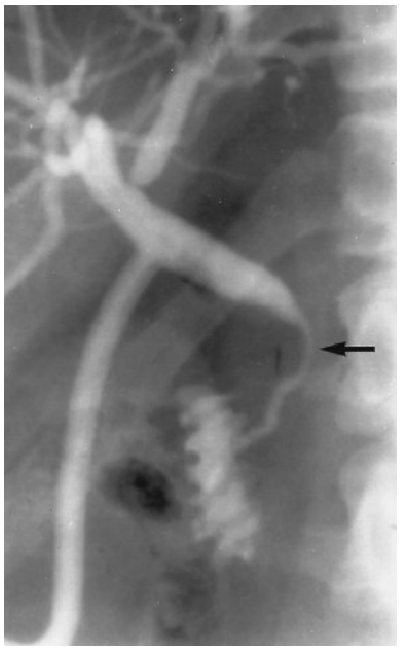

Cholangiogram of a patient with a long distal common bile duct stricture (*arrow*) caused by chronic pancreatitis. Reprinted with permission from: Lillemoe KD. Biliary injuries and strictures and sclerosing cholangitis. In: Mulholland MW, Lillemoe KD, Doherty GM, Maier RV, Upchurch GR, eds. *Greenfield's Surgery: Scientific Principles & Practice.* 5th ed. Philadelphia, PA: Lippincott Williams & Wilkins, 2011:995.

References:

Kahl S, Zimmermann S, Genz I, et al. Biliary strictures are not the cause of pain in patients with chronic pancreatitis. *Pancreas.* 2004;28(4):387–390.

Lillemoe KD. Biliary injuries and strictures and sclerosing cholangitis. In: Mulholland MW, Lillemoe KD, Doherty GM, Maier RV, Upchurch GR, eds. *Greenfield's Surgery: Scientific Principles & Practice.* 5th ed. Philadelphia, PA: Lippincott Williams & Wilkins; 2011.

۰۲۱-۶۶۱۹۸۵۱۴ www.myuptodate.com دریافت آخرین نسخه آپتودیت آفلاین

1G23

Key word: Treatment of Gallbladder Carcinoma

Author: Susanna M. Nazarian, MD, PhD
Editor: Richard D. Schulick, MD, MBA, FACS

You perform an uncomplicated laparoscopic cholecystectomy on a 50-year-old woman for symptomatic cholelithiasis. One week later, the surgical pathologist calls you to say that the specimen contains adenocarcinoma of the gallbladder wall. The cancer is limited to the muscular layer of the gallbladder and the cystic duct margin is negative. In your subsequent discussion with the patient, what should you recommend as the treatment plan?

(A) Extended right hepatectomy, portal lymphadenectomy and resection/reconstruction of the extrahepatic biliary tree

(B) No further treatment is needed

(C) Radiation and chemotherapy with 5-fluorouracil and mitomycin C

(D) Resection of the gallbladder fossa and portal lymphadenectomy

(E) Resection of the laparoscopic trocar sites and chemotherapy with 5-fluorouracil and mitomycin C

Answer: **(D)** Resection of the gallbladder fossa and portal lymphadenectomy

Rationale:

Gallbladder carcinoma is a rare but aggressive cancer. Although there are only approximately 7,500 new cases of gallbladder cancer in the United States yearly, the disease often manifests late and many cases are unresectable at presentation. Gallbladder carcinoma spreads early to peritoneal surfaces and lymph nodes, as well as metastasizing hematologically. Most series report a 5-year survival of less than 5%, and the median survival for those with unresectable disease is only 6 months. Adenocarcinoma is the predominant lesion, found in over 80% of cases. Adenoma subtypes include papillary, tubular, and nodular. Other histological types include anaplastic (10%) and squamous cell carcinoma (<5%).

This malignancy is more common in the Native American populations of the United States and Mexico, Bolivians, Chileans and residents of Northern India, and Central Europe. There is a 3:1 female to male predominance and peak incidence in the seventh decade. The relationship between gallbladder carcinoma and cholelithiasis is well established. Seventy to ninety percent of all patients with the cancer have gallstones and the risk of the carcinoma in those with stones is four to five times higher than in acalculous individuals. However, the scenario presented above, in which gallbladder carcinoma is discovered after elective cholecystectomy, occurs only 1% of the time. Pathologically, the chronic inflammation induced by the stones probably contributes to the development of the malignancy. Patients with larger stones (>3 cm) have a tenfold higher rate of carcinoma. The traditional teaching of the association between "porcelain gallbladder" and higher rates of gallbladder cancer has recently been shown to be overestimated. Although patients with limited areas of calcification of the gallbladder wall have an increased incidence of gallbladder cancer, those with diffuse calcification ("porcelain gallbladder") do not seem to have a higher risk for the malignancy.

Current staging is a tumor-node-metastasis (TNM) system revised in 2010 by the American Joint Committee on Cancer (see table on next page)

The cystic duct lymph node (Calot node) is usually the first site of metastasis, followed by surrounding node beds. Nodal disease may lead to common bile duct obstruction and jaundice, which is found in 37% of patients. Symptomatic patients may also report abdominal pain (73%), nausea and vomiting (43%), anorexia (35%), and weight loss (35%).

The goal for treatment of gallbladder carcinoma is removal of all tumors (R0 resection). Tumors limited to the lamina propria (T1a) may be cured by a simple cholecystectomy, provided the cystic duct margin is negative. The patient in this scenario has a T1b tumor, with disease in the muscularis layer. Since lymphovascular invasion is present in 30% of patients with T1b disease, resection of the gallbladder fossa and portal lymphadenectomy is the proper treatment. Patients with T2 or greater tumors require a larger resection, although the recommended extent remains controversial. At a minimum, resection of a 1- to 2-cm rim of normal liver around the gallbladder fossa should be performed. Regional lymphadenectomy is necessary, from the bifurcation of the hepatic ducts to the distal common bile duct. T3 and resectable T4 tumors require segment 4b and 5 resection at least and often an extended right hepatectomy. Patients with common bile duct or common hepatic duct involvement require an extended liver resection, removal of a portion of the CBD and reconstruction with a Roux-en-Y hepaticojejunostomy. Cystic duct margin positivity mandates bile duct excision.

The resection of laparoscopic trocar port sites remains controversial, as does the role for adjuvant chemotherapy and radiation. A recent prospective, randomized phase III trial of adjuvant 5-fluorouracil and mitomycin C versus surgery alone did demonstrate improved 5-year survival for those receiving chemotherapy. Radiation therapy has not been convincingly proven to be effective.

۰۲۱-۶۶۱۹۸۵۱۴ www.myuptodate.com دریافت آخرین نسخه آپتودیت آفلاین

American Joint Committee on Cancer Seventh Edition Staging System for Gallbladder Carcinoma

Stage	Tumor	Nodes	Metastasis
0	T_{IS}	N0	M0
I	T1	N0	M0
II	T2	N0	M0
IIIA	T3	N0	M0
IIIB	T1–T3	N1	M0
IVA	T4	N0–N1	M0
IVB	Any T	N2	M0
	Any T	Any N	M1

Definition of TNM	
Primary Tumor (T)	
TX	Primary tumor cannot be assessed
T0	No evidence of primary tumor
T_{IS}	Carcinoma in situ
T1	Tumor invades lamina propria or muscular layer
T1a	Tumor invades lamina propria
T1b	Tumor invades muscular layer
T2	Tumor invades perimuscular connective tissue; no extension beyond serosa or into liver
T3	Tumor perforates the serosa (visceral peritoneum) and/or directly invades the liver and/or one other adjacent organ or structure, such as the stomach, duodenum, colon, pancreas, omentum, or extrahepatic bile ducts
T4	Tumor invades main portal vein or hepatic artery or invades two or more extrahepatic organs or structures
Regional Lymph Nodes (N)	
NX	Regional lymph nodes cannot be assessed
N0	No regional lymph node metastases
N1	Nodes confined to the hepatic hilus (including nodes along the common bile duct, hepatic artery, portal vein, and cystic duct
N2	Metastases to celiac, periduodenal, peripancreatic, and/or superior mesenteric artery lymph nodes
Distant Metastasis (M)	
M0	No distant metastasis
M1	Distant metastasis

Reprinted with permission from Weber S, Yamane B, Fong Y. Biliary neoplasms. In: Mulholland MW, Lillemoe KD, Doherty GM, Maier RV, Upchurch GR, eds. *Greenfield's Surgery: Scientific Principles & Practice,* 5th ed. Philadelphia, PA: Lippincott Williams & Wilkins, 2011:1000.

References:

Albores-Saavedra J, Tuck M, McLaren BK, et al. Papillary carcinomas of the gallbladder: analysis of noninvasive and invasive types. *Arch Pathol Lab Med.* 2005;129(7):905–909.

Foster JM, Hoshi H, Gibbs JF, et al. Gallbladder resection: defining the indications for primary radical resection and radical re-resection. *Ann Surg Oncol.* 2007;14(2):833–840.

Principe A, Del Gaudio M, Ercolani G, et al. Radical surgery for gallbladder carcinoma: possibilities of survival. *Hepatogastroenterology.* 2006;53(71):600–604.

Reid KM, Ramos-De la Medina A, Donohue JH. Diagnosis and surgical management of gallbladder cancer: a review. *J Gastrointest Surg.* 2007;11:671–681.

Weber S, Yamane B, Fong Y. Biliary neoplasms. In: Mulholland MW, Lillemoe KD, Doherty GM, Maier RV, Upchurch GR, eds. *Greenfield's Surgery: Scientific Principles & Practice.* 5th ed. Philadelphia, PA: Lippincott Williams & Wilkins; 2011.

۰۲۱-۶۶۱۹۸۵۱۴ www.myuptodate.com دریافت آخرین نسخه آپتودیت آفلاین

1G24

Key word: Treatment of Incompletely Reduced Ileocolic Intussusception

Author: Robert A. Meguid, MD, MPH
Editors: Timothy M. Pawlik, MD, MPH, PhD, and Matthew J. Weiss, MD

You are called to the emergency department to see a 68-year-old woman who has undergone a barium enema for ileocolic intussusception. The films show that the intussusception has been only partly reduced. What is your next step?

(A) Colonoscopic reduction

(B) Laparotomy for manual reduction

(C) Observation

(D) Pneumatic reduction

(E) Repeat barium enema

Answer: (B) Laparotomy for manual reduction

Rationale:

Ninety percent of intussusception in adults is due to pathology of the bowel, with 65% involving tumors. Postoperative intussusception is often due to drainage or feeding tubes, adhesions, or the suture line of a bowel anastomosis. These usually resolve without intervention. Otherwise, intussusception in adults should be managed with operative reduction. Upon laparotomy, manual reduction should be attempted. After reduction, bowel should be carefully examined for signs of ischemia or necrosis, as well as for the pathology causing the event. Resection is usually warranted for intussusception in adults, even if manual reduction is successful. This is because cancer has to be presumed a cause and a local resection is almost always warranted to rule out a subtle underlying malignancy.

Unlike in adults, the cause of intussusception in the pediatric patient population is usually unknown. The lead point is thought to be lymphoid hyperplasia leading to intramural thickening, polyps, or Meckel diverticula. Patients present at 5 to 10 months of age. Initial diagnosis is made by history and physical examination, with intermittent colicky abdominal pain, progressively bilious vomiting, and abdominal distension being the most common symptoms. Abdominal examination is frequently notable for a palpable right lower quadrant sausage-like mass and currant jelly stool is sometimes present.

Diagnosis is confirmed by a barium enema, which often itself reduces the intussusception. This hydrostatic pressure reduction uses a fluid column of 91 cm (3 ft) for 10 minutes at a time, with a 60% success rate. If unsuccessful, pneumatic reduction using 80 to 120 mm Hg of pressure has a 90% success rate.

Should nonoperative reduction fail, or if the patient develops signs of peritonitis after successful reduction, operative exploration is warranted. In pediatric patients, this entails a right lower quadrant incision with reduction or resection of the involved bowel if reduction is unsuccessful. Appendectomy should accompany the procedure. The recurrence rate for intussusception is 12%.

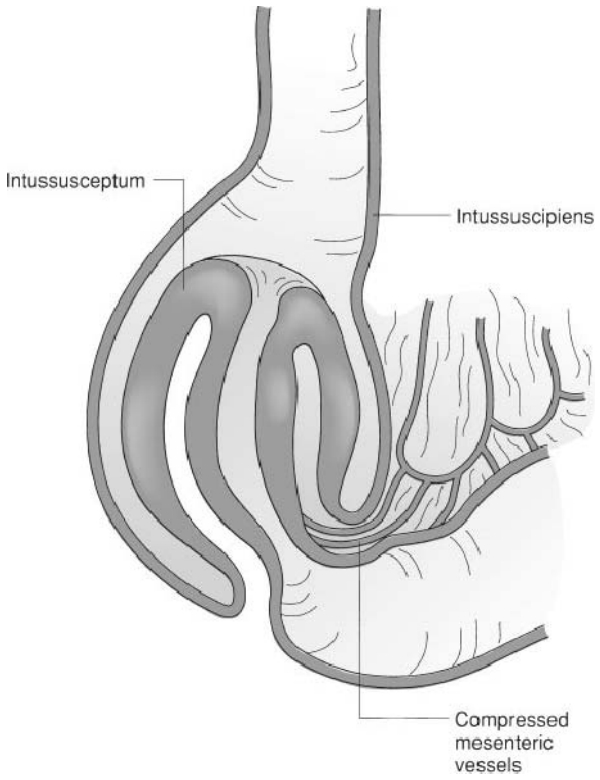

Anatomy of Intussusception. The intussusceptum is the segment of bowel that invaginates into the intussuscipiens. Reprinted with permission from: Soybel DI, Landman WB. Ileus and bowel obstruction. In: Mulholland MW, Lillemoe KD, Doherty GM, Maier RV, Upchurch GR, eds. *Greenfield's Surgery: Scientific Principles & Practice*. 5th ed. Philadelphia, PA: Lippincott Williams & Wilkins, 2011:761.

References:

Arnaoutakis GJ, Eckhauser FE. Small bowel obstruction. In: Cameron JL, Cameron AM, eds. *Current Surgical Therapy.* 10th ed. Philadelphia, PA: Mosby; 2011;93–96.

Gingalewski CA, Mattei P. Pediatric surgery. In: Fleischer KJ, ed. *Advanced Surgical Recall.* Philadelphia, PA: Williams & Wilkins; 1995:863–865.

Soybel DL, Landman WB. Ileus and bowel obstruction. In: Mulholland MW, Lillemoe KD, Doherty GM, Maier RV, Upchurch GR, eds. *Greenfield's Surgery: Scientific Principles & Practice.* 5th ed. Philadelphia, PA: Lippincott Williams & Wilkins; 2011.

۰۲۱-۶۶۱۹۸۵۱۴ www.myuptodate.com دریافت آخرین نسخه آپتودیت آفلاین

1G25

Key word: Complications after Nissen Fundoplication

Author: Robert A. Meguid, MD, MPH
Editor: Mark D. Duncan, MD, FACS

A 56-year-old woman is seen in clinic 6 months after undergoing a laparoscopic Nissen fundoplication for esophageal reflux disease and treatment of a type IV paraesophageal hernia. She complains of symptoms of persistent dysphagia. Which of the following is the cause of these complaints?

(A) The hiatal hernia has recurred

(B) The patient has gas bloat syndrome

(C) The patient has gastric stasis

(D) The stomach has become denervated

(E) The wrap has come undone

Answer: (A) The hiatal hernia has recurred

Rationale:

Following repair of paraesophageal hernias, the rate of failure requiring reoperation is as high as 40%. Failure requiring reoperation after fundoplication for gastroesophageal reflux disease alone is only around 5%. This increased rate of failure for repair of paraesophageal hernias is thought to be due to presence of a larger hiatal hernia, resulting in crural repair under tension, esophageal shortening, and concurrent connective tissue diseases.

Late complications of fundoplication include partial or complete dehiscence of repair with recurrence of hernia, stricture of the distal esophagus or too tight a wrap, slippage of a complete wrap onto the body of the stomach, herniation of the wrap or stomach into the chest, ulceration or perforation of the stomach, gastric stasis, and gas bloat syndrome.

Patients with dehiscence will usually present with recurrence of reflux, and may necessitate revision or redofundoplication. Following Nissen fundoplication, dysphagia is common but usually resolves within 3 months of surgery. Stricture or too tight a repair will lead to persistent dysphagia, often to solids more than liquids. If initial bougie dilation is unsuccessful, revision of the fundoplication may be warranted. Persistent, severe dysphagia may also be due to esophageal hypomotility. In this setting, treatment involves revision of a 360-degree fundoplication to a partial fundoplication, such as a Belsey repair.

Slippage of a complete wrap onto the body of the stomach, called a "slipped" Nissen, may result in dysphagia or recurrent symptoms of reflux. This may occur immediately after surgery, due to wrapping of the fundus around the stomach instead of the distal esophagus, or several months to years later, due to cephalad retraction of the esophagus. Management is via revision of the fundoplication, with adequate mobilization of the distal 6 cm of the esophagus. In the setting of a shortened esophagus, use of a Collis gastroplasty procedure will create a gastric tube to supplement the length of the esophagus. This is especially useful in the setting of a recurrent hiatal hernia, which is associated with shortening of the esophagus due to progressive ischemic damage.

Paraesophageal herniation of the posterior fundus into the chest, or herniation of the intact wrap and esophagogastric junction into the chest may result from failure of the hiatal hernia repair. Herniation of the stomach through the intact wrap, with preservation of the position of the esophagogastric junction below the diaphragm may result in acute strangulation and perforation of the stomach. These complications are managed surgically, the latter being a surgical emergency. Repair, as with a "slipped" Nissen, may benefit from a gastroplasty. Patients may present with dysphagia, or acutely ill with perforation and a bleeding ulcer.

Gastric stasis is associated with vagal nerve injury sustained during the operation. Patients present with nausea and vomiting, the latter which may disrupt the fundoplication. If persistent, treatment includes pyloromyotomy or pyloroplasty.

Gas bloat syndrome is likely due to aerophagia by patients, which they may use to lessen symptoms of reflux disease. Following fundoplication, patients present with abdominal distention, inability to belch or vomit, early satiety, and increased flatus. Treatment is not surgical, but by counseling patients to minimize aerophagia.

References:

Daniel TM. Complications after hiatal hernia repair. In: Wolfe WG, ed. *Complications in Thoracic Surgery.* St. Louis, MO: Mosby; 1992:212–224.

Krasna MJ. Surgical therapy of gastroesophageal reflux disease. In: Shields TW, Locicero J, Reed CE, Feins RH, eds. *General Thoracic Surgery.* 7th ed. Philadelphia, PA: Lippincott Williams & Wilkins; 2009:1913–1923. Accessed online March 29, 2013.

Peters JH, Little VR, Watson TJ. Esophageal anatomy and physiology and gastroesophageal reflux disease. In: Mulholland MW, Lillemoe KD, Doherty GM, Maier RV, Simeone DM, Upchurch GR, eds. *Surgery: Scientific Principles and Practice.* 5th ed. Philadelphia, PA: Lippincott Williams & Wilkins; 2011:629–665. Accessed online March 29, 2013.

۰۲۱-۶۶۱۹۸۵۱۴ www.myuptodate.com دریافت آخرین نسخه آپتودیت آفلاین

1G26

Key word: Diagnosis of Afferent Limb Obstruction

Author: Robert A. Meguid, MD, MPH
Editor: Michael A. Choti, MD, MBA

Six weeks after undergoing a vagotomy and antrectomy with Billroth II reconstruction for peptic ulcer disease, a 76-year-old man presents with nausea, abdominal pain, and low-grade fever. Given his recent surgical history, your differential diagnosis includes afferent limb obstruction. Which one test will best confirm this diagnosis?

(A) Computed tomography (CT) scan with oral contrast
(B) Esophagogastroduodenoscopy (EGD)
(C) Hepatobiliary iminodiacetic acid (HIDA) scan
(D) Supine and erect abdominal x-ray
(E) Upper gastrointestinal (GI) series

Answer: (A) Computed tomography (CT) scan with oral contrast

Rationale:
Complications following antrectomy with reconstruction include afferent limb obstruction, duodenal stump leakage, and delayed gastric emptying. Afferent limb obstruction occurs due to internal herniation, adhesion formation, volvulus, or formation of a kink at the junction of the afferent limb with the gastric remnant. The best form of imaging is abdominal CT scan with oral contrast, where a dilated, fluid-filled afferent limb that does not fill with oral contrast might be apparent. Afferent limb obstruction is typically not seen on HIDA scan. Duodenal stump leakage is confirmed by visualization of a fluid collection on CT with subsequent aspiration of bile from the right upper quadrant, or via HIDA scan revealing the bile leak. Duodenal stump leakage will not be seen on an upper GI series or an EGD. Delayed gastric emptying may be best diagnosed via upper GI series, however, may be implied by the presence of a dilated stomach on abdominal CT with oral contrast. Delayed gastric emptying will not be seen on a HIDA scan.

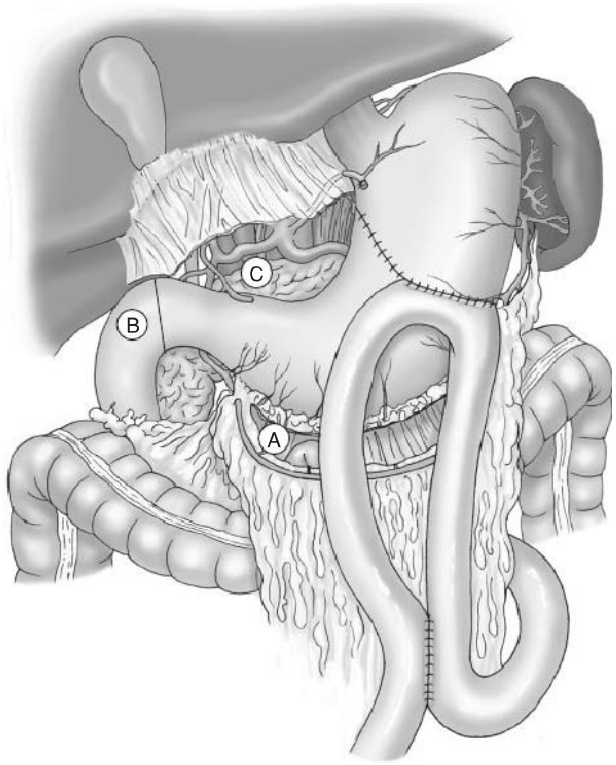

The Billroth II reconstruction. The first or second jejunal loop of the jejunum is used, and a jejunojejunostomy (according to Braun) should be accomplished in order to prevent bile reflux. Reprinted with permission from: Siewert JR, Bumm R. Distal gastrectomy with Billroth I, Billroth II, or Roux-Y reconstruction. In: Fischer JF, Bland KI, eds. *Mastery of Surgery.* 5th ed. Philadelphia, PA: Lippincott Williams & Wilkins, 2007:855.

References:
Clancy TE, Ashley SW. Procedures for benign and malignant gastric and duodenal disease. In: Souba WW, ed. *ACS Surgery: Principles and Practice.* Decker Intellecutal Properties, 2009. Accessed August 27, 2013. Online Edition.
Gayer G, Barsuk D, Hertz M, et al. CT diagnosis of afferent loop syndrome. *Clin Radiol.* 2002;57(9):835–839.

۰۲۱-۶۶۱۹۸۵۱۴ www.myuptodate.com دریافت آخرین نسخه آپتودیت آفلاین

1G27

Key word: Treatment of MALT Lymphoma

Author: Robert A. Meguid, MD, MPH
Editors: Timothy M. Pawlik, MD, MPH, PhD, and Matthew J. Weiss, MD

A 68-year-old woman presents with a history of weight loss and nausea, but denies vomiting or early satiety. Workup ultimately leads to biopsy-proven B-cell mucosa-associated lymphoid tissue (MALT) lymphoma confined to the stomach. What is the most appropriate treatment?

(A) Antibiotic therapy

(B) Chemotherapy and radiation therapy

(C) Proton pump inhibitor, clarithromycin and amoxicillin for 10 to 14 days

(D) Radiation therapy

(E) Subtotal gastrectomy followed by radiation therapy

Answer: (A) Antibiotic therapy

Rationale:

Greater than 50% of gastrointestinal lymphomas arise in the stomach, which is the most common extranodal site of non-Hodgkin lymphoma. Most patients present with epigastric pain, weight loss, nausea, vomiting, anorexia, and sometimes gastric obstruction. Differential diagnosis includes gastric adenocarcinoma, Menetrier disease, Zollinger–Ellison syndrome, hypertrophic gastritis, and gastric lymphoma.

Diagnosis is made via histologic examination of endoscopic biopsies and brushings, combined with endoscopic ultrasound. Upper gastrointestinal series show characteristic enlarged mucosal folds, and/or mass and ulcers. Additional workup should include chest and abdominal computed tomography (CT), and biopsy of bone marrow and any enlarged peripheral lymph nodes, to evaluate the patient for systemic disease.

Radiation therapy alone is successful in treatment of low-stage gastric lymphoma, with long-term survival comparable to that of surgery, and avoids the risk of postoperative complications. Surgical resection should be reserved for large lesions causing gastric outlet obstruction, and is followed by radiation. Systemic disease is treated with chemoradiation.

While gastric submucosa does not normally contain lymphoid tissue, chronic *Helicobacter pylori* infection is associated with development of Peyer patch-like lymphoid tissue in the stomach. This is known as MALT, and is thought to be monoclonal B-cell proliferation. Low-grade MALT lymphomas can be differentiated from low-grade gastric lymphomas histologically.

Treatment of low-grade MALT lymphomas is by antibiotic eradication of *H. Pylori.* This is effective in 70% to 100% of cases, with a median complete response time of 5 months. Chemoradiation is reserved for failure of regression with antibiotics.

References:

Choi SW, Ryu J. Lymphoma and sarcoma. In: Fleischer KJ, ed. *Advanced Surgical Recall.* Philadelphia, PA: Williams & Wilkins; 1995:621–622.

Minter RM. Gastric neoplasms. In: Mulholland MW, Lillemoe KD, Doherty GM, Maier RV, Upchurch GR, eds. *Greenfield's Surgery: Scientific Principles & Practice.* 5th ed. Philadelphia, PA: Lippincott Williams & Wilkins; 2011.

Reddy N, Blackbourne LH. Stomach and duodenum. In: Fleischer KJ, ed. *Advanced Surgical Recall.* Philadelphia, PA: Williams & Wilkins; 1995:381–382.

Yamada T. Tumors of the stomach. In: Yamada T, Alpers DH, Powell DW, Owyang C, Silverstein FE, Hasler WL, Traber PG, Tierney WM, eds. *Handbook of Gastroenterology.* Philadelphia, PA: Lippincott-Raven; 1998;305–306.

۰۲۱-۶۶۱۹۸۵۱۴ www.myuptodate.com دریافت آخرین نسخه آپتودیت آفلاین

1G28

Key word: Treatment of Focal Nodular Hyperplasia of the Liver

Author: Susanna M. Nazarian, MD, PhD
Editor: Richard D. Schulick, MD, MBA, FACS

Your sister states that she has been diagnosed with focal nodular hyperplasia (FNH) of her liver. How should you advise her to proceed with treatment?

(A) She may be observed with this condition

(B) She should visit a medical oncologist for an oral TNF-α inhibitor

(C) She should visit a medical oncologist for chemotherapy

(D) She should visit a radiation oncologist for radiation therapy

(E) She will likely require surgery for this condition

Answer: (A) She may be observed with this condition

Rationale:
FNH is a benign liver tumor with a benign course, and can be managed with observation if the patient is asymptomatic. If the patient is experiencing right upper quadrant pain or symptoms of fullness or if the lesion appears to have bled, resection may be considered after a period of observation. FNH is the second most common benign lesion of the liver after liver hemangioma, and is usually found in women between the ages of 20 and 40. It has been linked with oral contraceptive use.

Although FNH is usually found incidentally (upon laparotomy for other reasons or abdominal imaging), it rarely causes vague right upper quadrant abdominal pain. While it may be difficult to make a definitive diagnosis of FNH radiographically, a homogenous lesion with uniform enhancement on the arterial phase is highly suggestive of FNH, particularly when a high signal central scar is evident on T_2 magnetic resonance imaging. The lesions are often located peripherally and a feeding artery may be visualized. If this diagnosis is strongly suspected, an interval period of observation and reimaging may further confirm the diagnosis.

Reference:
Sonnenday CJ, Welling TH, Pelletier SJ. Hepatic neoplasms. In: Mulholland MW, Lillemoe KD, Doherty GM, Maier RV, Upchurch GR, eds. *Greenfield's Surgery: Scientific Principles & Practice.* 5th ed. Philadelphia, PA: Lippincott Williams & Wilkins; 2011.

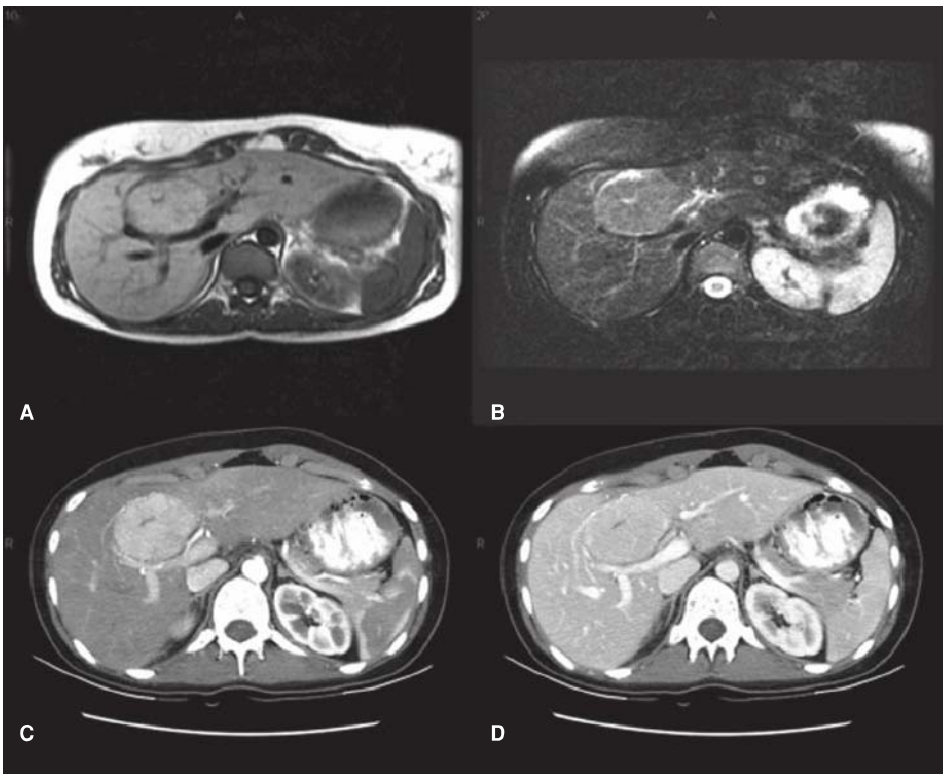

Focal nodular hyperplasia on cross-sectional T_1-weighted **(A)** and T_2-weighted **(B)** magnetic resonance imaging. Both scans were made using manganese-based contrast, an agent taken up by hepatocytes generating a hyperintense appearance in the lesion with a high concentration of hepatocytes. Note also, the obvious peripheral vessel on the T_2-weighted image. **(C)** Arterial phase computed tomography scan of the same lesion, again hyperintense compared with background liver parenchyma. **(D)** The lesion washes out during the portal phase, demonstrating the importance of three-phase imaging in characterizing and detecting lesions within the liver. Reprinted with permission from: Delman KA, Curley SA. Hepatic neoplasms. In: Mulholland MW, Lillemoe KD, Doherty GM, Maier RV, Upchurch GR, eds. *Greenfield's Surgery: Scientific Principles & Practice*. 4th ed. Philadelphia, PA: Lippincott Williams & Wilkins, 2006:963.

۰۲۱-۶۶۱۹۸۵۱۴ www.myuptodate.com دریافت آخرین نسخه آپتودیت آفلاین

1G29

Key word: Treatment of Esophageal Leiomyoma

Author: Susanna M. Nazarian, MD, PhD
Editors: Stephen M. Cattaneo II, MD, and Robert A. Meguid, MD, MPH

You see a 60-year-old woman in clinic complaining of progressive dysphagia. She denies pain while swallowing, but says she feels that some foods become stuck on a "lump in my throat." She has not lost any weight from these symptoms, has no smoking history and does not use alcohol. You suspect a benign process. Which of the following studies and associated findings confirms your suspicion of an esophageal leiomyoma?

(A) Barium swallow study showing a bird-beak pattern in the distal third of the esophagus

(B) Computed tomography (CT) scan showing a circumferential narrowing along the distal third of the esophagus

(C) Esophagoscopy showing a submucosal lesion in the distal third of the esophagus

(D) Magnetic Resonance Imaging (MRI) demonstrating compression of the cervical esophagus by ankylosing spondylitis

(E) Plain films of the lateral neck demonstrating a pedunculated lesion arising from the posterior wall of the esophagus

Answer: (C) Esophagoscopy showing a submucosal lesion in the distal third of the esophagus



Endoscopic appearance of an esophageal leiomyoma at the level of the gastroesophageal junction. Courtesy of Michael L. Kochman, MD, Hospital of the University of Pennsylvania, Philadelphia.

Rationale:
Esophageal leiomyomas comprise two-thirds of benign esophageal tumors. Other benign esophageal entities include esophageal cysts, granular cell tumors, and fibrovascular polyps. Leiomyomas occur in the distal two-thirds of the esophagus, and arise from the muscularis propria. They are usually

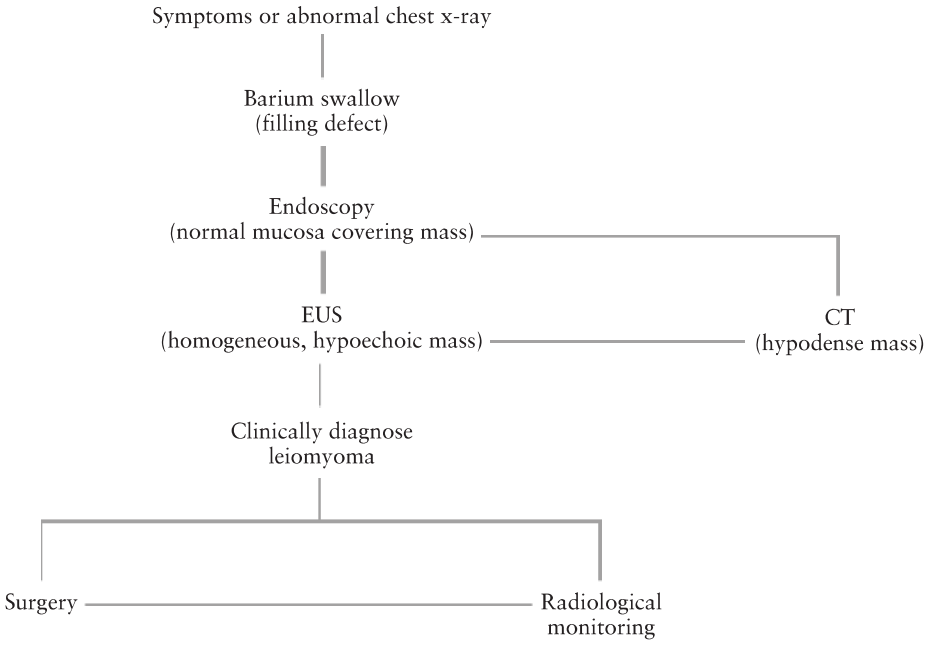

Evaluation and treatment of esophageal leiomyoma. Adapted with permission from: Lee LS, Singhal S, Brinster CJ, et al. Current management of esophageal leiomyoma. *J Am Coll Surg.* 2004;198:136.

۰۲۱-۶۶۱۹۸۵۱۴ www.myuptodate.com دریافت آخرین نسخه آپتودیت آفلاین

solitary lesions and appear as smooth, convex, submucosal lesions on barium swallow.

Appropriate evaluation of a patient with a suspected esophageal leiomyoma includes a barium swallow, endoscopy, endoscopic ultrasound, and a CT scan of the chest. The lesion may be observed if the patient is asymptomatic. However, lesions that are enlarging on interval studies, those which are ulcerated, or those causing dysphagia warrant resection. Lesions less than 8 cm can usually be enucleated in an extramucosal fashion, whereas those that are greater than 8 cm or annular may require esophageal resection.

Reference:

Rascoe PA, Kucharczuk JC, Kaiser L. Esophagus: Tumors and injury. In: Mulholland MW, Lillemoe KD, Doherty GM, Maie r RV, Upchurch GR, eds. *Greenfield's Surgery: Scientific Principles & Practice.* 5th ed. Philadelphia, PA: Lippincott Williams & Wilkins; 2011.

1G30

Key word: Physiology of Truncal Vagotomy

Author: Robert A. Meguid, MD, MPH
Editors: Christopher L. Wolfgang, MD, PhD, and Matthew J. Weiss, MD

A 52-year-old man undergoes truncal vagotomy and antrectomy for peptic ulcer disease. Postoperatively, he complains of diarrhea. Which of the following physiologic alterations is due to the truncal vagotomy alone?

(A) Accelerated emptying of solids
(B) Decrease in gastrin production
(C) Decreased gallbladder distention
(D) Increase in gastric acid secretion
(E) Increased intragastric pressure

Answer: **(E)** Increased intragastric pressure

Rationale:

Physiologic alterations resulting from truncal vagotomy are multifold. Truncal vagotomy interrupts vagal innervation of viscera distal to the esophageal hiatus, as opposed to a selective proximal gastric vagotomy that denervates the proximal stomach only. A proximal gastric vagotomy is also known as super-selective or parietal cell vagotomy. To allow adequate gastric emptying, a truncal vagotomy must be paired with either antrectomy or pyloroplasty.

Truncal vagotomy, as well as super-selective vagotomy, causes hypergastrinemia, due to loss of feedback inhibition as well as gastric cell hyperplasia. This may be as high as twice preoperative levels. However, antrectomy in combination with vagotomy decreases gastrin levels to half of the preoperative level.

The primary aims of vagotomy, truncal, or super-selective, are reduction of gastric acid secretion. Following vagotomy, basal acid secretion is reduced by 80%, and acid secretion in response to a meal is reduced by 60% to 70%. This occurs via reduction of cholinergic stimulation of parietal cells. Inclusion of antrectomy with surgery further reduces acid secretion, presumably via a decrease in gastrin production signaled by G cells located predominantly in the antrum.

Truncal vagotomy results in an increased rise in intragastric pressures, and affects both proximal and distal gastric motor activities. This translates into accelerated emptying of liquids, however, impairs emptying of solids. Therefore, a truncal vagotomy is combined with pyloroplasty or antrectomy to facilitate emptying of solids. While a super-selective vagotomy only affects distal gastric motor activities, it is also associated with an accelerated emptying of liquids, but not solids.

Truncal vagotomy decreases enzyme and bicarbonate secretion by the exocrine pancreas. In addition, truncal vagotomy results in decreased secretion of cholecystokinin, secretin, and pancreatic polypeptide, as well as decreased biliary secretion, with increased gallbladder distention noted. All of these changes are absent in super-selective vagotomy.

۰۲۱-۶۶۱۹۸۵۱۴ www.myuptodate.com دریافت آخرین نسخه آپتودیت آفلاین

Most of the manifestations of the above physiologic changes are subclinical. However, the most common side effects of truncal vagotomy are diarrhea, followed by cholelithiasis.

Reference:

Mulholland MW. Gastroduodenal ulceration. In: Mulholland MW, Lillemoe KD, Doherty GM, Maier RV, Upchurch GR, eds. *Greenfield's Surgery: Scientific Principles & Practice.* 5th ed. Philadelphia, PA: Lippincott Williams & Wilkins; 2011.

1G31

Key word: Treatment of Choledochal Cyst

Author: Trevor A. Ellison, MD, MBA
Editor: Michael A. Choti, MD, MBA

A 23-year-old man is referred to the surgery clinic after an endoscopic retrograde cholangiopancreatography shows a Type I choledochal cyst. What is the preferred method of surgical management?

(A) Cholecystectomy

(B) Complete excision with Roux-en-Y hepaticojejunostomy

(C) Complete excision, partial hepatectomy, and Roux-en-Y hepaticojejunostomy

(D) Cyst gastrostomy

(E) Cyst jejunostomy

Answer: **(B)** Complete excision with Roux-en-Y hepaticojejunostomy

Rationale:

Choledochal cysts are usually associated with a common bile duct that joins the pancreatic duct more proximal to the ampulla of Vater, extrinsic to the normal intramural duodenal location. This observation led to the hypothesis that aberrant ductal anatomy may predispose an individual to pancreatic reflux up the common bile duct and subsequent cyst formation. Regarding histology, the cyst itself does not have normal biliary epithelium and instead is often replaced by dysplastic columnar epithelium. Notably, the normal smooth muscle layer is usually present (the exception to these rules are Type III cysts which have normal duodenal mucosa).

Less than 50% of people with choledochal cysts present with the classic triad of episodic abdominal pain, jaundice, and a palpable right upper quadrant mass. Imaging for diagnosis in infants includes ultrasound. In adults, an endoscopic retrograde cholangiopancreatography is sufficient to diagnose the condition.

Choledochal cysts are classified according to the Todani modification of the Alonso-Lej classification.

- Type I cysts (85% to 90%) are fusiform dilations of the entire common bile duct normally starting at the origin of the common bile duct and sparing the common hepatic ducts as well as the intrahepatic ducts. These cysts tend to be large and displace local structures leading to the typical finding of obstructive jaundice and frequently in children an abdominal mass. Treatment is primary excision of the cyst with a Roux-en-Y hepaticojejunostomy. In some cases (where inflammation has led to cyst adherence to the portal vein and hepatic artery), an intramural cyst dissection with excision of the epithelial layer while leaving the posteromedial outer wall of the cyst intact may be preferable. Complete excision is preferred as these types of lesions confer a 3% to 5% risk of malignancy anywhere in the gallbladder, biliary tree, or pancreas (approximately 1,000 times the risk of the general population).

۰۲۱-۶۶۱۹۸۵۱۴ www.myuptodate.com دریافت آخرین نسخه آپتودیت آفلاین

- Type II cysts (1% to 2%) are true divertiuclae of the common bile duct. Recommended treatment is complete excision of the cyst with primary closure of the choledochotomy.
- Type III cysts (<2%) are also known as "choledochodeles" and are local dilations of the distal, intramural (with relation to the duodenum) common bile duct. These are treated by a transduodenal approach with marsupialization or excision of the cyst. In these procedures, identification of the ampulla of Vater is necessary to assure that a formal sphincteroplasty can be performed so that the biliary and pancreatic ducts are appropriately drained.
- Type IV cysts (15%) are often multiple in number and involve both the intrahepatic and extrahepatic ducts. Type V (<1%) cysts involve the intrahepatic ducts. Both Types IV and V are treated on an individual basis with options including resection and drainage with a Roux-en-Y jejunostomy for focal or unilobar disease. Multifocal disease in a bilobar distribution associated with hepatic fibrosis may prove to be impossible to drain.

Common complications of choledochal cyst procedures include cholangitis, stricture formation, choledocholithiaisis, and biliary tract malignancy. Excision of the cysts rather than drainage without excision leads to decreased morbidity with no increase in mortality, and is the preferred option of choledochal cyst management.

References:

Edil BH, Cameron JL, Reddy S, et al. Choledochal cyst disease in children and adults: a 30-year single-institution experience. *J Am Coll Surg.* 2008;206(5):1000–1005; discussion 1005–1008.

Lipsett PA, Pitt HA. Surgical treatment of choledochal cysts. *J Hepatobiliary Pancreat Surg.* 2003;10(5):352–359.

Stain SC, Guthrie CR, Yellin AE, et al. Choledochal cyst in the adult. *Ann Surg.* 1995;222(2):128–133.

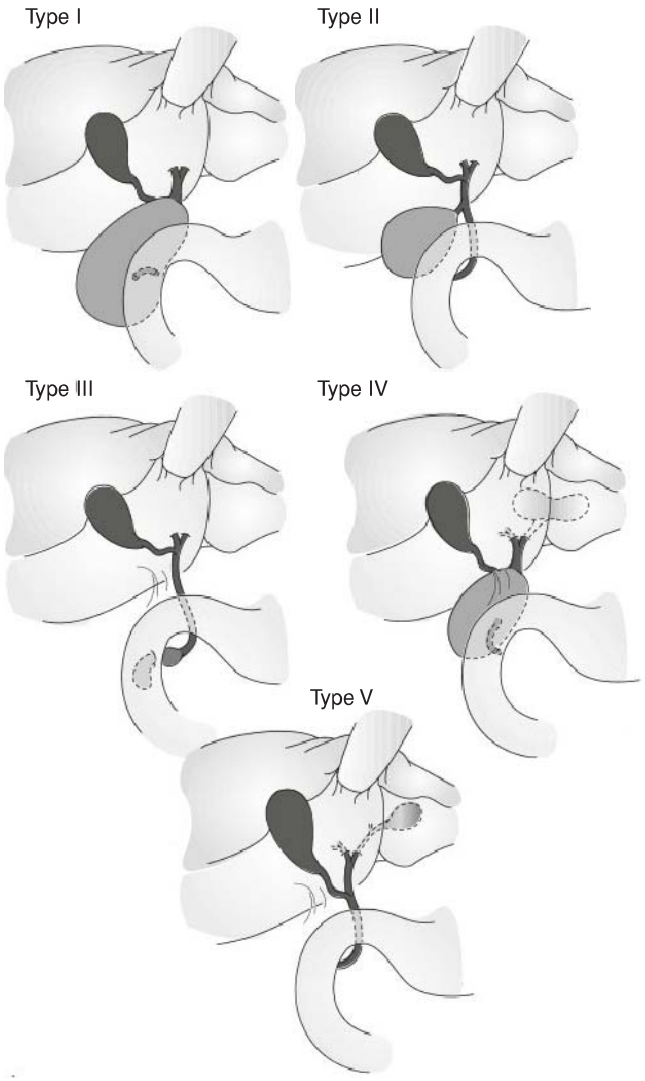

Classification of choledochal cyst. Reprinted with permission from: Sato TT, Oldham KT. Pediatric abdomen. In: Mulholland MW, Lillemoe KD, Doherty GM, Maier RV, Upchurch GR, eds. *Greenfield's Surgery: Scientific Principles & Practice.* 5th ed. Philadelphia, PA: Lippincott Williams & Wilkins, 2011:1937.

۰۲۱-۶۶۱۹۸۵۱۴ www.myuptodate.com دریافت آخرین نسخه آپتودیت آفلاین

1G32

Key word: Unresectable Pancreatic Cancer

Author: Justin B. Maxhimer, MD
Editor: Richard D. Schulick, MD, MBA, FACS

Among the examples given, which patient with pancreatic cancer would most likely be deemed unresectable based upon their abdominal computed tomography scan and laboratory findings? (CA 19–9 refers to Cancer Antigen 19–9.)

(A) 43-year-old male with a central pancreatic mass, CA 19–9 of 150 and tumor abutting the splenic vein

(B) 54-year-old female with a 3-cm mass in the head of the pancreas, CA 19–9 of 150 and encasement of the superior mesenteric vein

(C) 58-year-old female with a central pancreatic mass, CA 19–9 of 200 and adhesion to the ventral surface of the inferior vena cava (IVC)

(D) 67-year-old male with a 5-cm mass in the head of the pancreas, CA 19–9 of 50 and encasement of the superior mesenteric artery

(E) 75-year-old male with a 5-cm mass in the tail of the pancreas, CA 19–9 of 200 and no vessel invasion

Answer: (D) 67-year-old male with a 5-cm mass in the head of the pancreas, CA 19–9 of 50 and encasement of the superior mesenteric artery

Rationale:

As with many other tumors, the major determinant of resectability in pancreatic cancers is the local invasion of the tumor into the vascular structures surrounding the pancreatic head. In cancers of the pancreatic head, the relationship between the cancer and the portal vein, superior mesenteric vein, and the celiac or superior mesenteric artery have been found to be the most important factors in determining resectability. If the cancer has invaded into the portal or superior mesenteric vein, then a potentially curative resection, although more difficult, would require either vein excision or grafting. Often these patients are given preoperative therapy with the goal of shrinking the disease. At some centers, this can be accomplished with minimal additional morbidity. At high-volume centers curative resection with or without venous resection carries a similar prognosis. Limited involvement of the IVC, specifically adhesion to the ventral surface, does allow for possible resection. However, invasion or total encasement of the superior mesenteric artery, the celiac artery, or the IVC, makes an attempt at curative resection highly unlikely, and therefore, is considered a sign of unresectability at most major pancreatic centers.

CA 19–9 is a sialylated oligosaccharide that is most commonly found on circulating mucins in cancer patients. It is also normally present within the cells of the biliary tract and can be elevated in acute or chronic biliary disease. Evaluation of CA 19–9 levels has been used as an adjunct to imaging studies for helping determine the resectability potential of pancreatic carcinoma. Fewer than 4% of patients with a CA 19–9 level of more than 300 units/mL have been found to have resectable tumors.

Reference:

Moertel CG, Frytak S, Hahn RG, et al., Therapy of locally unresectable pancreatic carcinoma: A randomized comparison of high dose (6000 rads) radiation alone, moderate dose radiation (4000 rads + 5-fluorouracil), and high dose radiation +5-fluorouracil. The Gastrointestinal Tumor Study Group. *Cancer.* 1981;48(8):1705–1710.

۰۲۱-۶۶۱۹۸۵۱۴ www.myuptodate.com دریافت آخرین نسخه آپتودیت آفلاین

1G33

Key word: Treatment of Barrett Esophagus with High-grade Dysplasia

Author: Ying Wei Lum, MD
Editors: Stephen M. Cattaneo II, MD, and Robert A. Meguid, MD, MPH

A 60-year-old otherwise healthy male presents with symptoms of reflux disease and undergoes an endoscopic evaluation. The biopsies in the distal esophagus are consistent with high-grade dysplasia associated with Barrett esophagus. What is the appropriate treatment for this patient?

(A) Antireflux surgery
(B) Esophagectomy
(C) *Helicobacter pylori* antimicrobial therapy
(D) Observation with annual endoscopic gastroduodenoscopy
(E) Proton pump inhibitor therapy

Answer: (B) Esophagectomy

Rationale:
Approximately 35% to 40% of patients with the preoperative diagnosis of Barrett esophagus with high-grade dysplasia are found to harbor invasive cancer following pathologic examination after resection. Therefore, high-grade dysplasia warrants surgical intervention. Antireflux surgery is reserved only for patients in whom dysplasia cannot be identified or, more rarely, for those with low-grade dysplasia.

References:
Peters JH, Little VR, Watson TJ. Esophageal anatomy and physiology and gastroesophageal reflux disease. In: Mulholland MW, Lillemoe KD, Doherty GM, Maier RV, Upchurch GR, eds. *Greenfield's Surgery: Scientific Principles & Practice.* 5th ed. Philadelphia, PA: Lippincott Williams & Wilkins; 2011.

Reed MF, Tolis G Jr, Edil BH, et al. Surgical treatment of esophageal high-grade dysplasia. *Ann Thorac Surg.* 2005; 79(4):1110–1115.

1G34

Key word: Treatment of Gastrinoma of the Duodenum

Author: Ying Wei Lum, MD
Editors: Christopher L. Wolfgang, MD, PhD, and Matthew J. Weiss, MD

A 58-year-old female presents with severe refractory peptic ulcer disease that has failed conventional treatment. Her workup includes an endoscopic ultrasound and octreotide scan that localize a 1.8-cm duodenal mass. There are no liver metastases. Laboratory evaluation reveals an elevated serum gastrin level. What is the appropriate surgical management?

(A) Duodenotomy and resection of the mass
(B) Endoscopic mucosal resection
(C) Pancreaticoduodenectomy
(D) Subtotal gastrectomy with truncal vagotomy
(E) Total gastrectomy

Answer: (A) Duodenotomy and resection of the mass

Rationale:
Gastrinomas are now primarily resected following preoperative localization studies. Total gastrectomy or any other antiulcer therapy is of only historical importance in the treatment of gastrinomas. Duodenal tumors less than 2 cm can be resected with primary closure of the duodenal defect.

Duodenal gastrinomas are frequently small (<1 cm) and may not be detected by conventional imaging or routine surgical techniques such as palpation or intraoperative ultrasound. Hence, there is now evidence to suggest that the routine use of duodenotomy increases the short- and long-term cure rates in patients with sporadic gastrinomas.

Between 20% and 25% of all gastrinomas causing Zollinger–Ellison syndrome are associated with MEN I syndrome. A serum calcium level should be checked in all patients suspected of having Zollinger–Ellison syndrome to evaluate for hyperparathyroidism. In this case, the patient should be treated with parathyroidectomy as normalization of the serum calcium can ameliorate the symptoms of peptic ulcer disease.

References:
Norton JA, Alexander HR, Fraker DL, et al. Does the use of routine duodenotomy (DUODX) affect rate of cure, development of liver metastases, or survival in patients with Zollinger-Ellison syndrome? *Ann Surg.* 2004;39:617–626.

Norton JA, Fraker DL, Alexander HR, et al. Surgery increases survival in patients with gastrinoma. *Ann Surg,* 2006; 244(3):410–419.

۰۲۱-۶۶۱۹۸۵۱۴ www.myuptodate.com دریافت آخرین نسخه آپتودیت آفلاین

1G35

Key word: Complications of Hepatic Adenoma

Author: Nikiforos Ballian, MBBS
Editor: Richard D. Schulick, MD, MBA, FACS

A 35-year-old woman who has been on oral contraceptives for 10 years presents with a 6-month history of right upper quadrant discomfort. After a negative workup for cholelithiasis, computed tomography reveals a 6.5-cm tumor of hepatic segment IV. Complications of this tumor include the following.

(A) 30% risk of spontaneous thrombosis

(B) 50% to 65% risk of spontaneous rupture and intraperitoneal hemorrhage

(C) 90% risk of malignant transformation

(D) Compression of the common hepatic duct, leading to obstructive jaundice

(E) Compression of the portal vein, leading to portal hypertension

Answer: (B) 50% to 65% risk of spontaneous rupture and intraperitoneal hemorrhage

Rationale:
This is a classic presentation of hepatic adenoma, a benign tumor of hepatocytes that occurs most commonly in young women who have used oral contraceptives. Malignant transformation of hepatic adenomas is rare. Sixty-five percent of patients with hepatocellular adenoma related to oral contraceptive use will present with spontaneous tumor rupture that may result in life-threatening intraperitoneal hemorrhage. Although hepatic adenomas are vascular tumors, spontaneous thrombosis has not been described. Despite rare case reports of hepatic vein compression by this tumor, compression of portal structures does not occur on a routine basis.

References:
Belghiti J, Pateron D, Panis Y, et al. Resection of presumed benign liver tumours. *Br J Surg.* 1993;80:380–383.
Choi BY, Nguyen MH. The diagnosis and management of benign hepatic tumors. *J Clin Gastroenterol.* 2005;39:401–412.
Kerlin P, Davis GL, McGill DB, et al. Hepatic adenoma and focal nodular hyperplasia: Clinical, pathologic, and radiologic features. *Gastroenterology.* 1983;84:994–1002.
Klatskin G. Hepatic tumors: Possible relationship to use of oral contraceptives. *Gastroenterology.* 1977;73:386–394.
Shortell CK, Schwartz SI. Hepatic adenoma and focal nodular hyperplasia. *Surg Gynecol Obstet.* 1991;173:426–431.
Sobhonslidsuk A, Jeffers LJ, Acosta RC, et al. Budd-Chiari-like presentation of hepatic adenoma. *J Gastroenterol Hepatol.* 2005;20:653–656.

1G36

Key word: Treatment of Chronic Pancreatitis

Author: Jayme E. Locke, MD, MPH
Editors: Timothy M. Pawlik, MD, MPH, PhD, and Matthew J. Weiss, MD

A 45-year-old man with a 20-year history of alcohol dependence presents to your general surgery clinic with complaints of fatty, foul-smelling stools, and chronic intractable pain recalcitrant to narcotic therapy. Routine blood work is significant for a megaloblastic anemia, slightly elevated liver function tests, and high blood glucose level. Computed tomography (CT) scan of the abdomen is notable for a small pancreas containing several calcifications and a pancreatic duct dilated to 10 mm. What is the appropriate therapy for this patient?

(A) Analgesics and oral pancreatic enzymes

(B) Classic pancreaticoduodenectomy

(C) Distal pancreatectomy

(D) Longitudinal pancreaticojejunostomy

(E) Pylorus-preserving pancreaticoduodenectomy

Answer: (D) Longitudinal pancreaticojejunostomy

Rationale:
The description of this patient and associated laboratory and radiologic findings are classic for chronic pancreatitis. Chronic alcoholism is responsible for more than 80% of cases of chronic pancreatitis in developed countries. Recently, a new etiology-based classification system has been proposed for pancreatitis—the TIGAR-O system (toxic-metabolic, idiopathic, genetic, autoimmune, recurrent severe acute pancreatitis, and obstructive).

While analgesics and oral pancreatic enzyme replacement are the first-line treatment for chronic pancreatitis, this patient has clearly failed first-line therapy. Longitudinal pancreaticojejunostomy, or Puestow procedure, is the recommended treatment when the pancreatic duct is dilated ≥7 mm, as it is in this case. The Puestow procedure provides pain relief in approximately 80% of patients. Resection is only indicated in the absence of a dilated pancreatic duct. The type of resection, including distal pancreatectomy, Whipple procedure, or total pancreatectomy, is dependent upon disease location and severity. Distal pancreatectomy is ideal for disease confined to the tail of the pancreas. Most experts believe that it is the inflammatory process in the head that controls both the severity of symptoms and the progression of disease. This is secondary to the fact that 70% to 80% of patients who undergo the Whipple procedure experience complete pain relief. The role for total pancreatectomy remains controversial, but in general, is indicated after failed drainage procedures and in patients with small ducts following distal pancreatectomy. Patients who have undergone total pancreatectomy often become brittle diabetics and develop steatorrhea.

۰۲۱-۶۶۱۹۸۵۱۴ www.myuptodate.com دریافت آخرین نسخه آپتودیت آفلاین

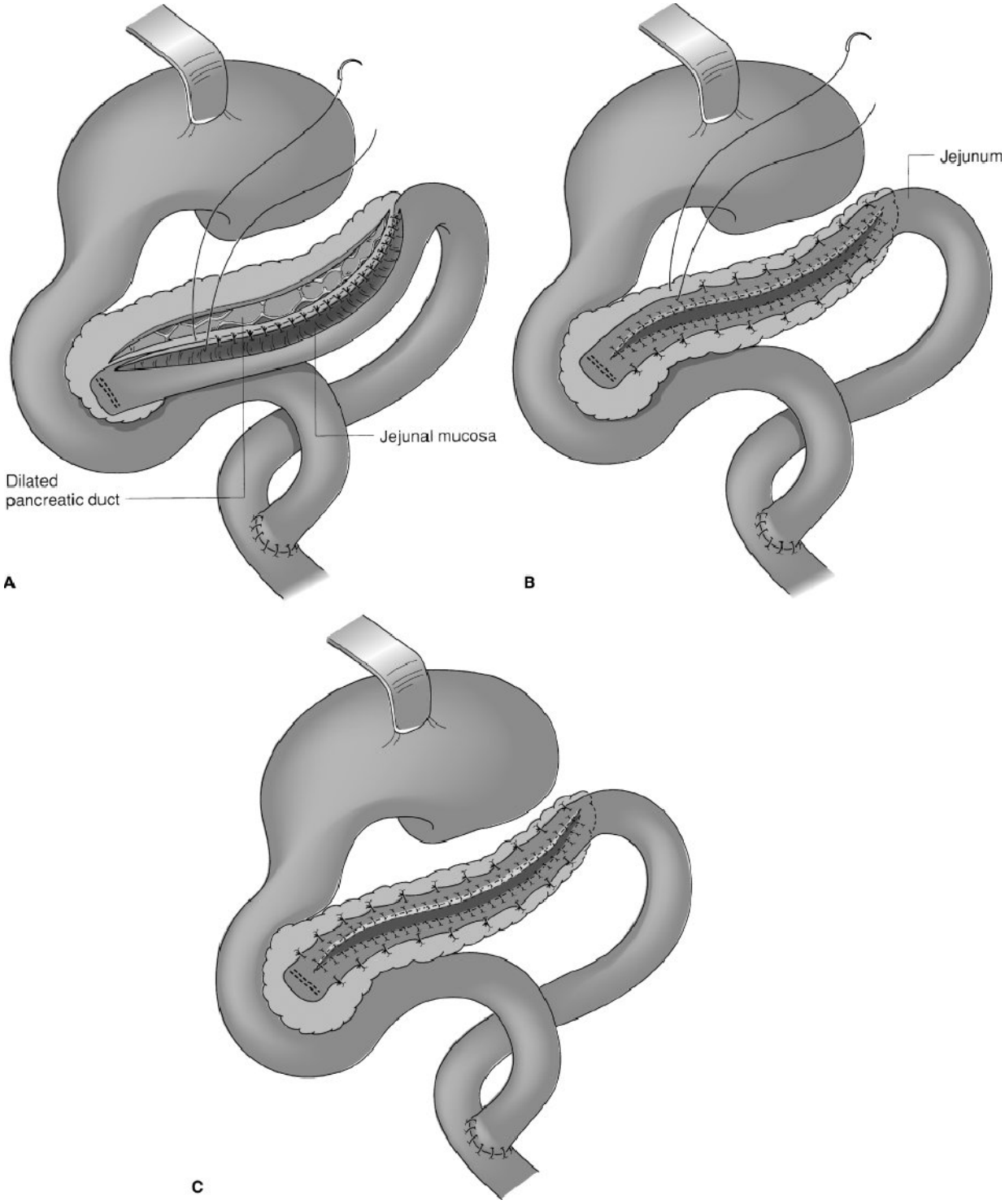

Drawing illustrating longitudinal pancreaticojejunostomy. Reprinted with permission from: Zyromski NJ, Howard TJ. Chronic pancreatitis. In: Mulholland MW, Lillemoe KD, Doherty GM, Maier RV, Upchurch GR, eds. *Greenfield's Surgery: Scientific Principles & Practice*. 5th ed. Philadelphia, PA: Lippincott Williams & Wilkins, 2011:833.

Reference:

Zyromski NJ, Howard TJ. Chronic pancreatitis. In: Mulholland MW, Lillemoe KD, Doherty GM, Maier RV, Upchurch GR, eds. *Greenfield's Surgery: Scientific Principles & Practice.* 5th ed. Philadelphia, PA: Lippincott Williams & Wilkins; 2011.

۰۲۱-۶۶۱۹۸۵۱۴ www.myuptodate.com دریافت آخرین نسخه آپتودیت آفلاین

1G37

Key word: Treatment to Close Fistula Secondary to Crohn Disease

Author: Kelly Olino, MD
Editor: Susan L. Gearhart, MD

A 40-year-old female with a long-standing history of Crohn disease presents with rectal pain, intermittent drainage from her perineum, fevers and chills, tachycardia, and hypotension. On examination under anesthesia, the patient is found to have a perianal fistula above the dentate line involving the sphincter muscles. After stabilization of the patient with supportive therapy and initiation of appropriate antibiotics, what is the next most appropriate treatment?

(A) Anti-TNF antibody
(B) Diverting colostomy
(C) Fistulotomy
(D) Seton placement
(E) Treatment with ciprofloxacin and metronidazole

Answer: (D) Seton placement

Rationale:
Perianal disease affects almost one-third of patients with Crohn disease. Management involves optimization of medical management followed by surgical treatment. A perianal fistula above the dentate line involving the sphincter muscles is complex and optimization of medical management, namely with anti-TNF antibody, is the initial treatment of choice, as fistulotomy risks fecal incontinence. Treatment with ciprofloxacin and metronidazole alone is best used for treatment of noncomplex fistulas lying closer to the anus. Diverting colostomy and rectal advancement flaps are used for more advanced disease that fails medical management. However, in the setting of pelvic sepsis, following initial stabilization and initiation of antibiotics, seton placement is the next step.

Reference:
Michelassi F, Stein SL. Crohn disease. In: Mulholland MW, Lillemoe KD, Doherty GM, Maier RV, Upchurch GR, eds. *Greenfield's Surgery: Scientific Principles & Practice.* 5th ed. Philadelphia, PA: Lippincott Williams & Wilkins; 2011.

1G38

Key word: Treatment of Gastrointestinal Stromal Tumors

Author: Kelly Olino, MD
Editors: Christopher L. Wolfgang, MD, PhD, and Matthew J. Weiss, MD

As part of her workup for anemia, a 60-year-old female undergoes esophagogastroduodenoscopy (EGD), which reveals a 5-cm mass along the greater curvature of the stomach. Biopsy of the mass reveals spindle cells and C-kit expression. A computed tomography (CT) scan shows no other abnormalities. The most appropriate next step for treatment is:

(A) Endoscopic submucosal resection
(B) Total gastrectomy with lymph node resection
(C) Treatment with imatinib followed by total gastrectomy
(D) Wedge resection of gastric mass followed by treatment with imatinib
(E) Wedge resection of the gastric mass

Answer: (D) Wedge resection of the gastric mass followed by treatment with imatinib

Rationale:
Gastrointestinal stromal tumors (GISTs) are tumors of mesenchymal origin thought to arise from the interstitial cells of Cajal. They are usually benign neoplasms that contain spindle cells and express C-kit, a tyrosine kinase receptor. The expression of C-kit helps to distinguish GISTs from other spindle cell neoplasms in the gastrointestinal tract, which include leiomyomas, leiomyosarcomas, solitary fibrous tumors, schwannomas, or neurofibromas. GISTs are found throughout the gastrointestinal tract but most commonly occur within the stomach, followed by small intestine, colon/rectum, and lastly in the esophagus. They are often diagnosed during workup of gastrointestinal bleeding or chronic anemia.

Risk factors for GIST malignancy include size greater than 10 cm, more than 10 mitoses per 50 high-power fields, or size exceeding 5 cm with more than 5 mitoses per 50 high-power fields. GISTs rarely metastasize to lymph nodes and treatment of choice is complete surgical resection. In the stomach, wedge resection is the treatment of choice, especially for tumors where adequate margins can be obtained. Submucosal resection is only indicated for small, early gastric cancers. Imatinib, a tyrosine kinase inhibitor, has been shown to increase recurrence-free survival when used as adjuvant therapy.

References:
DeMatteo RP, Ballman KV, Antonescu CR, et al. Adjuvant imatinib mesylate after resection of localized, primary gastrointestinal stromal tumour: A randomized, double-blind, placebo-controlled trial. *Lancet.* 2009;373(9669):1097–1104.
Efron DT, Lillemoe KD. The current management of gastrointestinal stromal tumors. In: Cameron JL, Evers BM, Fong Y, Herndon D, Langer B, Lillemoe KD, Mannick JA, Wong J, eds. *Advances in Surgery.* Philadelphia, PA: Elsevier Mosby; Volume 39. 2005;193–221.

۰۲۱-۶۶۱۹۸۵۱۴ www.myuptodate.com دریافت آخرین نسخه آپتودیت آفلاین

1G39

Key word: Site of Primary Tumor in Carcinoid Syndrome

Author: Clinton D. Kemp, MD
Editors: Timothy M. Pawlik, MD, MPH, PhD, and Matthew J. Weiss, MD

A 50-year-old man presents with a history of episodic facial flushing, diarrhea, and palpitations. His examination is notable for hepatomegaly. A workup reveals elevated 24-hour urine 5-hydroxyindoleacetic acid. He is diagnosed with carcinoid syndrome, and undergoes a computed tomography (CT) scan to evaluate the extent of his disease. The radiologist reports metastatic tumor to both lobes of his liver. The gastrointestinal site with the highest metastatic potential is the:

(A) Duodenum
(B) Ileum
(C) Jejunum
(D) Rectum
(E) Stomach

Answer: (B) Ileum

Rationale:
Carcinoid tumors are derived from neuroendocrine cells of the fore-, mid-, and hindgut. These tumors are typically indolent and asymptomatic with the vast majority (80%) being discovered as incidental findings on autopsy or in the operating room. These tumors are most often found in the gastrointestinal tract with the appendix the most common location for primary tumors.

As tumors of neuroendocrine origin, carcinoids have the potential to produce and secrete hormones, including serotonin, substance P, corticotropin, histamine, dopamine, neurotensin, gastrin, somatostatin, pancreatic polypeptide, and others. The majority of products produced by carcinoid tumors are degraded into inactive metabolites as they travel through the portal venous system through the liver.

The carcinoid syndrome itself is quite rare, and occurs in less than one in ten patients with carcinoid tumors. The syndrome occurs from tumors whose secreted products escape hepatic metabolism such as those that are metastatic to the liver, or those with direct access to the systemic venous circulation such as bronchial or rectal tumors. The syndrome is characterized by a spectrum of symptoms including cutaneous flushing, diarrhea, and right-sided cardiac valvular lesions.

Malignant potential is based upon the ability of the primary tumor to metastasize, which differs with the site of the primary tumor. The site with the highest malignant potential is the ileum with a 35% metastatic rate, followed by the appendix and the stomach with 3% and 2% rates, respectively.

Treatment involves surgical removal of the primary lesion and any lesions metastatic to the liver that are amenable to resection or ablation. For those lesions not amenable to an operation, hepatic arterial embolization has been utilized. Medical management of these lesions includes the use of somatostatin analogs that may provide relief from symptoms of the carcinoid syndrome.

Reference:
Evers BM. Small intestine. In: Townsend CM, Beauchamp RD, Evers BM, Mattox KL, eds. *Sabiston Textbook of Surgery.* 17th ed. Philadelphia, PA: Elsevier; 2004:1359–1362.

۰۲۱-۶۶۱۹۸۵۱۴ www.myuptodate.com دریافت آخرین نسخه آپتودیت آفلاین

1G40

Key word: Adjuvant Chemotherapy for Sigmoid Carcinoma

Author: Benjamin S. Brooke, MD, PhD
Editor: Michael A. Choti, MD, MBA

A 62-year-old healthy female patient on your service has just undergone successful sigmoid resection. Final pathology reveals the tumor to be stage IIIA moderately differentiated adenocarcinoma. What adjuvant therapy would most commonly be recommended in this patient?

(A) 5-fluorouracil (5-FU) + leucovorin (LV) + irinotecan
(B) 5-FU + LV + oxaliplatin
(C) 5-FU + LV + oxaliplatin + bevacizumab
(D) Adjuvant therapy is not recommended in this setting
(E) Oral capecitabine

Answer: (B) 5-FU + LV + oxaliplatin

Rationale:
In about 50% of patients with stage III colorectal tumors, the presence of microscopic residual disease present at the time of surgery eventually leads to cancer-related mortality. Hence, adjuvant therapy is used to eradicate this residual disease in patients who undergo successful resection of colorectal cancer and improve the chance that an operation will be truly curative. The current standard for stage III is to administer a regimen of 5-FU + LV + oxaliplatin (FOLFOX). This recommendation is based on a large European randomized trial (MOSAIC) comparing FOLFOX to 5-FU–LV, demonstrating superiority to the combination regimen. Monotherapy (5-FU–LV or capecitabine) can be considered in elderly patients or those with comorbidity. Randomized trials have shown inferiority of regimens including irinotecan, though such regimens (FOLFIRI) may be utilized in patients who progress or develop toxicity on oxaliplatin therapy. Trials evaluating the role of the addition of biologic agents such as bevacizumab in combination with FOLFOX as adjuvant therapy are ongoing.

References:
Andre T, Boni C, Mounedji-Boudiaf L, et al. Multicenter International Study of Oxaliplatin/5-Fluorouracil/Leucovorin in the Adjuvant Treatment of Colon Cancer (MOSAIC) Investigators: Oxaliplatin, fluorouracil, and leucovorin as adjuvant treatment for colon cancer. *N Engl J Med.* 2004;350(23):2343–2351.

Chung KY, Saltz LB. Adjuvant therapy of colon cancer: current status and future directions. *Cancer J.* 2007;13(3):192–197.

1G41

Key word: Characteristics of Parastomal Hernias

Author: Eric S. Weiss, MD, MPH
Editor: Susan L. Gearhart, MD

A 50-year-old man with acute diverticulitis requires a colectomy. During the operation, it is noted that there is gross contamination of the peritoneal cavity with fecal material. The decision is made to perform a Hartman procedure and leave the patient with an end-colostomy. Over the next 5 years, the subsequent risk of development of a parastomal hernia in this patient is:

(A) 10%
(B) 20%
(C) 40%
(D) 50%
(E) 85%

Answer: (D) 50%

Rationale:
Parastomal hernias are a common complication of stoma formation. Colostomies have a higher rate of parastomal hernia formation than ileostomies, with a 5-year risk of hernia formation of at least 50%. Both technical factors and patient characteristics are risk factors for hernia formation. Technical factors include creating too large of an opening in the fascia, construction of the stoma in a previous incision, and placing the stoma lateral to the rectus sheath. Patient characteristics such as obesity, malnutrition, chronic obstructive pulmonary disease, sepsis, and age may also contribute to the development of parastomal hernias. Surgical repair of parastomal hernias is usually avoided because of high recurrence rates and because unlike other types of hernias, obstruction and strangulation occur only rarely with parastomal hernias. Fewer than 20% of patients develop a complication requiring repair. Repair generally consists of exploration with closure of the facial defect or relocation of the stoma to another site.

Reference:
Fitzgibbons RJ, Cemaj S, Quinn TH. Abdominal wall hernias. In: Mulholland MW, Lillemoe KD, Doherty GM, Maier RV, Upchurch GR, eds. *Greenfield's Surgery: Scientific Principles & Practice.* 5th ed. Philadelphia, PA: Lippincott Williams & Wilkins; 2011.

۰۲۱-۶۶۱۹۸۵۱۴ www.myuptodate.com دریافت آخرین نسخه آپتودیت آفلاین

1G42

Key word: Treatment of Rectal Adenocarcinoma

Author: Benjamin S. Brooke, MD, PhD
Editors: Christopher L. Wolfgang, MD, PhD, and Matthew J. Weiss, MD

A 64-year-old male presents to clinic complaining of a recent history of bright red blood per rectum with associated constipation and decreased stool caliber. A digital rectal examination is performed and a mass is palpated in the proximal rectal vault. Endorectal ultrasound (EUS) with biopsy reveals a rectal adenocarcinoma invading the subserosa approximately 8 cm from the anal verge and a CT scan reveals no evidence of metastatic disease. Therefore, the stage is IIA (T3, N0, M0). What is the appropriate surgical management of this tumor?

(A) Abdominosacral resection
(B) Diverting colostomy followed by chemotherapy
(C) Low anterior resection (LAR)
(D) No surgery; primary chemotherapy and radiation therapy only
(E) Transanal excision

Answer: (C) Low anterior resection (LAR)

Rationale:
The surgical management of rectal cancer depends on multiple factors, including the distance of the tumor from the anal verge and the tumor mobility within the pelvis. These are important variables in assessing resectability and the type of operation indicated. Tumors located between 8 and 12 cm from the anal verge are in the middle third of the rectum, and considered candidates for either LAR or abdominoperineal resection (APR). LAR is the procedure of choice for early stage tumors, as it does not require resection of the sphincter or permanent colostomy, and is associated with fewer complications and less morbidity than an APR. Complete excision of the mesorectum is essential for oncologic management. However, LAR is contraindicated if the tumor is found to invade the sphincter complex, is fixed to the pelvic floor with spread to adjacent organs, or if it has spread into the lower third of the rectum. Transanal excision of rectal cancers may be considered for stage I (T1–T2, N0, M0), well-differentiated tumors that are less than 8 cm from the anal verge, and that encompass <30% of the bowel wall.

References:
McKensie SP, Barnes SL, Schwartz RW. An update on the surgical management of rectal cancer. *Curr Surg.* 2005;62:407–411.
Morris A. Colorectal cancer. In: Mulholland MW, Lillemoe KD, Doherty GM, Maier RV, Upchurch GR, eds. *Greenfield's Surgery: Scientific Principles & Practice.* 5th ed. Philadelphia, PA: Lippincott Williams & Wilkins; 2011.

1G43

Key word: Treatment of Diverticulum of the Duodenum

Author: Robert A. Meguid, MD, MPH
Editor: Michael A. Choti, MD, MBA

A duodenal diverticulum is seen in a 58-year-old man with recurrent episodes of acute pancreatitis. On endoscopic evaluation, the ampulla of Vater is found to be located just distal to the border of the diverticular opening. What is the most appropriate interventional management of this patient's duodenal diverticulum?

(A) Endoscopic sphincterotomy and stent placement
(B) Inversion and oversewing of the diverticulum
(C) Pancreaticoduodenectomy
(D) Resection with choledochoduodenostomy
(E) Resection with two-layer transverse closure

Answer: (A) Endoscopic sphincterotomy and stent placement

Rationale:
Congenital and acquired duodenal diverticula occur in up to 15% of the population. Diagnosis is usually made incidentally during upper GI contrast studies, esophagogastroduodenoscopy (EGD), or endoscopic retrograde cholangiopancreatography (ERCP). About 70% of diverticula occur in the second portion of the duodenum, usually within 2 cm of the ampulla of Vater, with 20% occurring in the third portion, and 10% occurring in the fourth portion.

Asymptomatic duodenal diverticula should not be resected. Surgical therapy is indicated for symptoms, including chronic pain, cholangitis, and recurrent acute and chronic pancreatitis due to partial ampullary obstruction. Emergency surgery is reserved for perforation or uncontrollable diverticular bleeding.

Even symptomatic duodenal diverticula can be managed nonsurgically in many cases. In this case, the patient can undergo endoscopic sphincterotomy and stent placement to minimize likelihood of ampullary obstruction. However, should the ampulla be located within the diverticulum, the diverticulum should be resected and a choledochoduodenostomy performed. For symptomatic diverticula not involving the ampulla, resection with two-layer transverse closure of the duodenum may be performed. Excision of the diverticulum from the luminal side of the duodenum, through an anterior duodenotomy, is an option when the ampulla is adjacent to the diverticulum, and more conservative measures have already failed. Inversion and oversewing of the diverticulum may be performed. However, this may result in duodenal obstruction. Rarely is pancreaticoduodenectomy indicated.

References:
Gallagher SF, Fabri PJ. Management of diverticulosis of the small bowel. In: Cameron JL, Cameron AM, eds. *Current Surgical Therapy.* 10th ed. Philadelphia, PA: Mosby; 2011:115–117.
Mathis KL, Farley DR. Operative management of symptomatic duodenal diverticula. *Am J Surg.* 2007;193(3):305–308.

۰۲۱-۶۶۱۹۸۵۱۴ www.myuptodate.com دریافت آخرین نسخه آپتودیت آفلاین

1G44

Key word: Anatomy of Replaced Right Hepatic Artery

Author: Susanna M. Nazarian, MD, PhD
Editor: Martin A. Makary, MD, MPH

What is the anatomic origin of a replaced right hepatic artery?

(A) Common hepatic artery
(B) Gastroduodenal artery
(C) Proper hepatic artery
(D) Right hepatic artery
(E) Superior mesenteric artery (SMA)

Answer: **(E)** Superior mesenteric artery (SMA)

Rationale:

Normal hepatic anatomy is present in only about 70% of people. In the classic anatomical pattern (also called Type I), the common hepatic artery branches off the celiac axis, then gives rise to the gastroduodenal artery and proper hepatic artery, which then branches into the right and left hepatic arteries. Cognizance of the existence and frequency of anatomic variants is essential to avoid untoward outcomes.

One of the most common variants is a replaced right hepatic artery (Type III), which exists in 8% to 10% of people. A replaced right hepatic artery arises from the SMA and provides the sole blood supply to the right lobe of the liver.

A distinction should be made between "replaced" and "accessory" hepatic arteries. A "replaced" hepatic artery is the sole arterial supply to the given hepatic lobe. However, if the hepatic lobe is supplied by both a second artery that arises directly from the common hepatic trunk (normal anatomy) and by an artery arising from the SMA, the latter artery is termed "accessory." This distinction is more than semantic: A replaced hepatic artery must always be preserved, whereas an accessory hepatic artery may sometimes be removed provided the other artery to the hepatic lobe has adequate flow. Usually the branch from the hepatic artery is quite diminutive in this scenario, however.

Busuttil and colleagues at UCLA studied the hepatic arterial anatomy of 1,000 livers prepared for orthotopic harvest. They found normal (Type I) anatomy in 75.7% of the livers and a replaced right hepatic artery 10.6% of the time (Type III anatomy). Other variants include a left hepatic artery arising from the left gastric artery (Type II, 9.7%), both replaced right and left hepatic arteries (Type IV, 2.3%), the entire common hepatic artery deriving from the SMA (Type V, 1.5%), and the common hepatic artery originating directly from the aorta (Type VI, 0.2%). Similar results were reported in 2007 in an analysis of 1,324 pancreatoduodenectomy patients from Seoul, South Korea and in a 2007 report on 1,081 transplanted livers from Spain.

See commentary on question 1B33 for figure.

References:

Hiatt JR, Gabbay J, Busuttil RW. Surgical anatomy of the hepatic arteries in 1000 cases. *Ann Surg.* 1994;220(1):50–52.

Netter FH. *Atlas of Human Anatomy.* 2nd ed. Plate 288. East Hanover, NJ: Novartis; 1997.

Rafael LA, Moya A, Montalvá E, et al. Lessons learned from anatomic variants of the hepatic artery in 1081 transplanted livers. *Liver Transpl.* 2007;13:1401–1404.

Schulick RD. Hepatobiliary anatomy. In: Mulholland MW, Lillemoe KD, Doherty GM, Maier RV, Upchurch GR, eds. *Greenfield's Surgery: Scientific Principles & Practice.* 5th ed. Philadelphia, PA: Lippincott Williams & Wilkins; 2011.

Yang SH, Yin YH, Jang JY, et al. Assessment of hepatic arterial anatomy in keeping with preservation of the vasculature while performing pancreatoduodenectomy: An opinion. *World J Surg.* 2007;31(12):2384–2391.

۰۲۱-۶۶۱۹۸۵۱۴ www.myuptodate.com دریافت آخرین نسخه آپتودیت آفلاین

1G45

Key word: Prognostic Test of Liver Function Reserve

Author: Robert A. Meguid, MD, MPH
Editors: Robert A. Montgomery, MD, DPhil, FACS, and Dorry L. Segev, MD, PhD

Which of the following tests is the most prognostic of liver function reserve?

(A) Albumin measurement

(B) Aminopyrine breath test

(C) Bromsulphalein clearance test

(D) Gamma-glutamyl transpeptidase (GGT) measurement

(E) Transferrin measurement

Answer: **(B)** Aminopyrine breath test

Rationale:

The commonly measured laboratory studies for liver function are qualitative when examined individually. These include the liver transaminases, alkaline phosphatase, GGT, leucine aminopeptidase, 5′-nucleotidase, albumin, and transferrin.

Liver transaminase (aspartate aminotransferase [AST] and alanine aminotransferase [ALT]) elevation reflects the severity of hepatic necrosis. However, this does not apply to alcoholic hepatitis, where the low level of liver transaminase is not commensurate with degree of injury.

Alkaline phosphatase elevation is not specific to the liver. It may be elevated due to normal bone growth, pregnancy, bone tumors, in addition to liver tumors and bile duct obstruction. It is also a predictor of metastatic disease to the liver.

GGT elevation is also not specific to the liver. It may be elevated following myocardial infarction, pancreatic disease, neuromuscular disease, in addition to hepatobiliary disease. It is a useful measure of amount of alcohol ingested by the patient.

Leucine aminopeptidase and 5′-nucleotidase, in addition to GGT, parallel alkaline phosphatase elevation in the setting of hepatobiliary disease, may help differentiate the cause for elevation of alkaline phosphatase.

Albumin is a useful measure of synthetic liver function in the setting of chronic liver failure. Transferrin is a more useful measure of synthetic liver function, as it has a shorter half-life than albumin.

Several tests have been developed to assess liver function quantitatively. The aminopyrine breath test is useful in determining prognosis after hepatic injury. Carbon 14-labeled aminopyrine is administered to a patient orally, and CO_2 (including C^{14}-labeled CO_2) in the breath is measured over the following 2 hours. This reflects the efficiency of cytochrome P-450, in turn reflecting the residual viable hepatic tissue. A similar test utilizing C^{14}-labeled caffeine may be performed. While this test is the most prognostic of liver function reserve, it is not commonly used clinically.

Similar quantification of cytochrome P-450 activity can be assessed by injecting lidocaine, and measuring its liver metabolite monoethylglycinexylidide (MEGX). This test has been studied as a predictor of graft survival prior to liver transplantation. In addition, galactose elimination capacity has been used as a quantitative measure of liver function.

Hepatic clearance of the dyes bromsulphalein and indocyanine green after intravenous injection has been used to assess biliary excretion. However, neither is used clinically.

Reference:

Meyers WC. The liver. In: Sabiston DC, Lyerly HK, eds. *Textbook of Surgery.* 15th ed. Philadelphia, PA: W.B. Saunders; 1997:1059–1060.

۰۲۱-۶۶۱۹۸۵۱۴ www.myuptodate.com دریافت آخرین نسخه آپتودیت آفلاین

1G46

Key word: Most Effective Stimulant of Pancreatic Acinar Cells

Author: Robert A. Meguid, MD, MPH
Editor: Martin A. Makary, MD, MPH

Pancreatic acini secrete enzymes that play an important role in the digestion of proteins. What is the most potent stimulant of pancreatic acinar cells?

(A) Acetylcholine
(B) Cholecystokinin (CCK)
(C) Peptide YY
(D) Secretin
(E) Trypsinogen

Answer: (B) Cholecystokinin (CCK)

Rationale:

CCK is the most potent stimulant of enzymatic secretion by acinar cells. CCK is produced by I cells in the mucosa of the small intestine, with highest concentration achieved in the duodenum. CCK secretion is stimulated by protein and fat in the duodenal lumen. CCK potentiates the effects of secretin on bicarbonate secretion. It also functions to stimulate gallbladder contraction.

Secretin, secreted by S cells in the duodenum, is the most potent stimulant of bicarbonate secretion by the pancreatic ductal cells. Secretin secretion is triggered by acid in the duodenal lumen. Secretin is also a weak stimulant of enzymatic secretion by acinar cells.

Acetylcholine, released by vagal nerve fibers, also stimulates enzymatic secretion by acinar cells, but it does so with much less potency compared to CCK.

Trypsinogen is the precursor protein to the enzyme trypsin. It is produced by acinar cells, and functions to cleave arginine and lysine peptide bonds.

Peptide YY is released in the ileum and colon postprandially. It functions to suppress pancreatic enzyme secretion, inhibit gastrointestinal motility, and increase water absorption in the colon, with overall function leading to decreased appetite.

In addition, gastrin is a weak stimulant of enzymatic secretion by acinar cells, and vasoactive intestinal peptide (VIP) is a stimulant of bicarbonate secretion by the pancreatic ductal cells.

References:

Asakawa A, Uemoto M, Ueno N, et al. Peptide YY3–36 and pancreatic polypeptide suppress food intake. *J Gastroenterol Hepatol.* 2006;21(9):1501–1502.

Costanzo LS. *Board Review Series: Physiology.* 2nd ed. Baltimore, MD: Williams & Wilkins; 1998:225–226.

Lee KKW, Durham SJ. Infection and host defences. In: Simmons RL, Steed DL, eds. *Basic Science Review for Surgeons.* St. Louis, MO: W.B. Saunders; 1992:260–266.

1G47

Key word: Findings Associated with Hepatorenal Syndrome

Author: Robert A. Meguid, MD, MPH
Editors: Robert A. Montgomery, MD, DPhil, FACS, and Dorry L. Segev, MD, PhD

A 72-year-old alcoholic man with ascites undergoes emergent colectomy for a lower gastrointestinal bleed. During his postoperative recovery, urine output is consistently low (250 to 475 mL/day), serum creatinine rises progressively but central venous pressure remains normal. Twenty-four-hour urinalysis on postoperative day 4 is as follows:

Volume:	374 cm^3
Color:	Yellow
Micro:	Renal epithelial cells
Urine [Na]:	<10 mEq/L
Urine Specific Gravity:	1.030
Serum Specific Gravity:	1.004
pH:	5.0

What is the most likely diagnosis accounting for this?

(A) Acute tubular necrosis (ATN)
(B) Hepatorenal syndrome
(C) Prerenal azotemia
(D) Type 1 renal tubular acidosis (RTA)
(E) Type 4 RTA

Answer: (B) Hepatorenal syndrome

Rationale:

Hepatorenal syndrome is the "reversible state of renal failure characterized by azotemia, oliguria (<500 mL/day), low urinary sodium excretion (<10 mEq/L), and increased urine–plasma osmolality ratio (U/P > 1) in the absence of urinary sedimentation" (ACS textbook). Histology of renal tissue from patients with hepatorenal syndrome is normal. Hepatorenal syndrome occurs in patients with pre-existing parenchymal liver disease after a precipitating event such as surgery or a hypotensive episode (e.g., gastrointestinal bleed, dialysis, sepsis). The etiology of hepatorenal syndrome is unknown, but likely involves vasodilation, hypovolemia, and further reduction of glomerular filtration by the renin–angiotensin–aldosterone system. Hepatorenal syndrome progresses over days to weeks after the precipitating event, and while initially partly responsive to volume expansion, is ultimately refractory to all interventions except liver transplant.

ATN is common in patients with cirrhosis who have undergone a precipitating event such as hypotension or renal hypoperfusion (e.g., sepsis). ATN inhibits the ability of the tubular system to concentrate the urine, and results in excessive sodium excretion. Hallmarks of ATN are rapid onset after the precipitating event, pigmented casts in the urine, high urinary sodium excretion (>10 mEq/L), isotonic urine, and

۰۲۱-۶۶۱۹۸۵۱۴ www.myuptodate.com دریافت آخرین نسخه آپتودیت آفلاین

variable urine output. Initially, renal function declines, but improves with support.

RTA occurs in patients with cirrhosis, autoimmune liver disease, and primary biliary cirrhosis. Type 1 and Type 2 RTA are characterized by the inability of the renal tubules to appropriately acidify the urine (decreased distal tubule acidification and decreased proximal bicarbonate resorption, respectively), with a urine pH >5.3. Type 4 RTA is characterized by aldosterone deficiency or resistance, and pH <5.3. RTA does not cause renal insufficiency per se.

Prerenal azotemia results from hypoperfusion of the kidneys secondary to hypovolemia. What differentiates hepatorenal syndrome from pre-renal azotemia is normal central venous pressure and unresponsiveness to volume resuscitation seen in hepatorenal syndrome. Significant laboratory values include urine sodium concentration <20 mEq/L and urine osmolarity >400 mOsm/L. Treatment is appropriate fluid resuscitation.

References:

Arnaout WS, Demetriou AA. Hepatic failure. In: Souba WW, Fink MP, Jurkovich GJ, Kaiser LR, Pearce WH, Pemberton JH, Soper NJ, eds. *ACS Surgery: Principles and Practice.* 4th ed. New York, NY: WebMD; 2004:1200–1201.

Cogan MG. Specific renal tubular disorders. In: Wyngaarden JB, Smith LH, eds. *Cecil Textbook of Medicine.* 18th ed. Philadelphia, PA: W.B. Saunders; 1988:622–623.

Lingappa VR. Liver disease. In: McPhee SJ, Lingappa VR, Ganong WF, Lange JD, eds. *Pathophysiology of Disease.* 3rd ed. New York, NY: Lange Medical Books/McGraw-Hill; 2000:354.

Lingappa VR. Renal disease. In: McPhee SJ, Lingappa VR, Ganong WF, Lange JD, eds. *Pathophysiology of Disease.* 3rd ed. New York, NY: Lange Medical Books/McGraw-Hill; 2000:386.

Mutant D, Binns O. Renal facts. In: Fleischer KJ, ed. *Advanced Surgical Recall.* Philadelphia, PA: Williams and Wilkins; 1995:74.

1G48

Key word: Mechanism of Action of Gastrin

Author: Susanna M. Nazarian, MD, PhD
Editor: Mark D. Duncan, MD, FACS

You are about to divide a short gastric artery during a total gastrectomy, when the attending surgeon asks you, "What is the mechanism of action of gastrin?" You answer that it is:

(A) Secreted by the chief cells of the stomach, and stimulates the release of cholecystokinin

(B) Secreted by the G cells of the stomach, and promotes peristalsis

(C) Secreted by the gastrin cells of the stomach, and stimulates parietal cells

(D) Secreted by the parietal cells of the stomach, and promotes mucus release

(E) Secreted by the parietal cells of the stomach, and stimulates the release of insulin from the pancreas

Answer: (C) Secreted by the gastrin cells of the stomach, and stimulates parietal cells

Rationale:

When protein (most effectively the amino acids tryptophan or phenylalanine) passes into the stomach, gastrin is released from the gastrin cells. These pyramidal cells line the antrum of the stomach and release gastrin by exocytic fusion of the secretory granule of the plasma membrane. Of note, neither fat nor glucose stimulates the release of gastrin. In addition, gastric distension due to eating a meal causes activation of cholinergic neurons, leading to gastrin release. A low pH of the stomach lumen inhibits gastrin release, while pH above 3.0 potentiates its release.

Gastrin prompts increased acid secretion from gastric parietal cells and also exerts trophic effects on the gastric mucosa. The high level of gastrin seen in Zollinger–Ellison syndrome prompts hypertrophy of the gastric mucosa. Patients infected with *Helicobacter pylori* produce more inflammatory cytokines, which stimulate gastrin release, and in turn lead to increased acid secretion from gastric parietal cells.

It would be appropriate to obtain a serum gastrin level when concerned about acid hypersecretion or a retained antrum following a gastrectomy. The differential diagnosis for elevated gastrin includes Zollinger–Ellison syndrome, pernicious anemia, use of proton pump inhibitors, gastric outlet obstruction, massive small bowel resection, and hypercalcemia.

۰۲۱-۶۶۱۹۸۵۱۴ www.myuptodate.com دریافت آخرین نسخه آپتودیت آفلاین

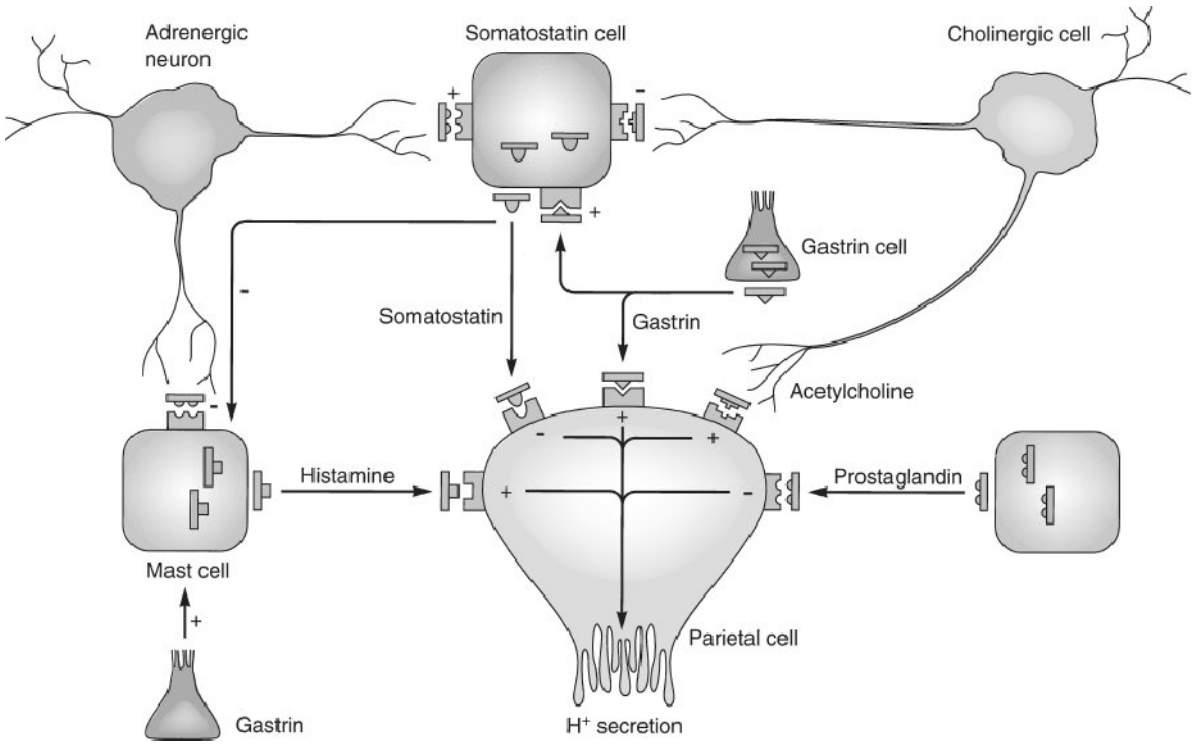

Interactions of cell types that affect parietal cell acid secretion. Reprinted with permission from: Mulholland MW. Gastric anatomy and physiology. In: Mulholland MW, Lillemoe KD, Doherty GM, Maier RV, Upchurch GR, eds. *Greenfield's Surgery: Scientific Principles & Practice.* 5th ed. Philadelphia, PA: Lippincott Williams & Wilkins, 2011:693.

Reference:

Mulholland MW. Gastric anatomy and physiology. In: Mulholland MW, Lillemoe KD, Doherty GM, Maier RV, Upchurch GR, eds. *Greenfield's Surgery: Scientific Principles & Practice.* 5th ed. Philadelphia, PA: Lippincott Williams & Wilkins; 2011.

۰۲۱-۶۶۱۹۸۵۱۴ www.myuptodate.com دریافت آخرین نسخه آپتودیت آفلاین

1G49

Key word: Site of Effect of Motilin

Author: Robert A. Meguid, MD, MPH
Editor: Susan L. Gearhart, MD

Erythromycin can act as a secretagogue for which of the following?

(A) Cholecystokinin (CCK)

(B) Gastrin

(C) Motilin

(D) Secretin

(E) Somatostatin

Answer: (C) Motilin

Rationale:

Motilin is a 22-amino acid peptide, produced by enteroendocrine cells of the muscularis mucosa of the duodenum and proximal jejunum. Luminal acidification initiates release of motilin into the enteric circulation, coinciding with initiation of the migrating motor complex (MMC). The presence of fat in the lumen inhibits motilin release. Therefore, motilin is released during the fasting state, when MMCs are propagated, and is released through a cholinergic-dependent pathway. MMCs originate high in the stomach and propagate toward the distal ileum, with most ending in the mid-ileum. Erythromycin is a motilin secretagogue, increasing gastrointestinal motility.

Somatostatin is a 14-amino acid peptide produced by D cells of the stomach, pancreas, and small intestine, as well as neurons. It is secreted in response to meals, and decreases gastric acid, pepsin, and biliary secretion, while inhibiting gastrointestinal motility. Somatostatin also decreases splanchnic and portal blood flow.

Secretin is a 27-amino acid peptide produced by S cells of the duodenum and jejunum. Secreted in response to luminal acidification (pH < 4), secretin stimulates release of bicarbonate from biliary and pancreatic ductal epithelium and from Brunner glands. It does not affect gastrointestinal motility directly.

CCK is an enteric hormone produced predominantly by endocrine cells of the duodenal and jejunal mucosa in response to presence of proteins and fats. CCK stimulates acinar cells to release pancreatic enzymes into the lumen of the pancreatic acini. It weakly stimulates bicarbonate secretion, but acts to potentiate the effects of secretin on bicarbonate secretion. CCK stimulates contraction of the gallbladder.

Gastrin is a 34-amino acid peptide produced by G cells of the gastric antrum. Stimulants of gastrin release are the presence of amino acids and small peptides in the gastric lumen, chronic elevation of antral pH (e.g., pernicious anemia, atrophic gastritis), and vagal stimulation. Inhibitors of gastrin release are antral pH <3 and somatostatin. Gastrin stimulates parietal cells to secrete HCl, propagates growth of oxyntic mucosal cells, and decreases gastrointestinal motility.

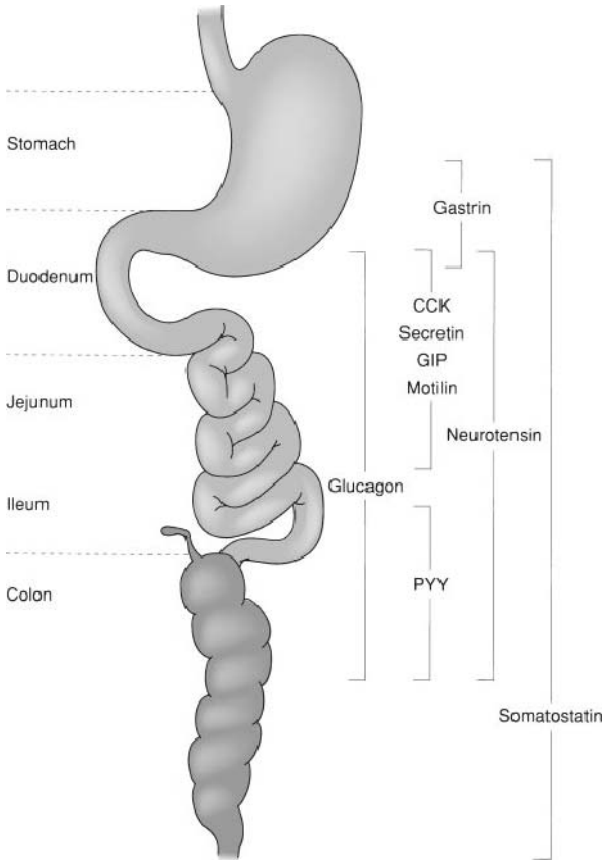

Distribution of peptide hormones in the gastrointestinal tract. Reprinted with permission from: Kimchi ET, Gusani NJ, Kaifi JT. Anatomy and physiology of the small intestine. In: Mulholland MW, Lillemoe KD, Doherty GM, Maier RV, Upchurch GR, eds. *Greenfield's Surgery: Scientific Principles & Practice.* 5th ed. Philadelphia, PA: Lippincott Williams & Wilkins, 2011:740.

References:

Kimchi ET, Gusani NJ, Kaifi JT. Anatomy and physiology of the small intestine. In: Mulholland MW, Lillemoe KD, Doherty GM, Maier RV, Upchurch GR, eds. *Greenfield's Surgery: Scientific Principles & Practice.* 5th ed. Philadelphia, PA: Lippincott Williams & Wilkins; 2011.

Udekwu AO. Gastrointestinal physiology. In: Simmons RL, Steed DL, eds. *Basic Science Review for Surgeons.* St. Louis, MO: W.B. Saunders; 1992:234–235, 244–245.

۰۲۱-۶۶۱۹۸۵۱۴ www.myuptodate.com دریافت آخرین نسخه آپتودیت آفلاین

1G50

Key word: Ligation of Artery in Bleeding Duodenal Ulcer

Author: Susanna M. Nazarian, MD, PhD
Editor: Richard D. Schulick, MD, MBA, FACS

A 64-year-old man in the intensive care unit has hematemesis and melena. The patient has undergone unsuccessful endoscopic attempts to stop the bleeding of an ulcer in the duodenal bulb. He is now hemodynamically unstable and intubated. The ligation of which artery during surgery is most likely to stop the bleeding?

(A) Gastroduodenal artery (GDA)

(B) Posterior superior pancreaticoduodenal artery

(C) Right gastric artery

(D) Right gastroepiploic artery

(E) Supraduodenal artery

Answer: (A) Gastroduodenal artery (GDA)

Rationale:

Patients with bleeding duodenal ulcers in whom endoscopic or interventional radiographic attempts have failed may require urgent surgical intervention. Ulceration through the posterior wall of the duodenum can erode the GDA as well as other neighboring vessels such as the right gastroepiploic, inferior pancreaticoduodenal, anterior superior pancreaticoduodenal, and posterior–superior pancreaticoduodenal arteries.

A longitudinal duodenotomy/pyloroplasty incision should be performed to obtain control of the bleeding by suture ligation. Next the gallbladder is taken down and a biliary balloon catheter is inserted for protection of the common bile duct. Suture ligatures are placed proximal and distal to the ulcer, incorporating the GDA. The transverse pancreatic branches (inferior pancreaticoduodenal, anterior superior, and posterior–superior pancreaticoduodenal arteries) can be occluded with a U-stitch placed medial to the bleeding ulcer. The longitudinal incision across the duodenum is then closed transversely in a Heineke–Mikulicz fashion.

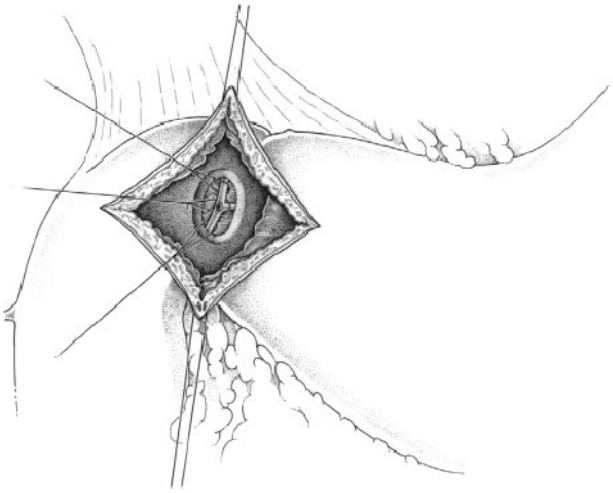

Proper suture ligation of a bleeding ulcer arising from the gastroduodenal artery requires a three-suture ligation. The proximal and distal branches of the gastroduodenal artery are transfixed. A third suture, U type in configuration, is necessary to transfix the transverse pancreatic branch of the artery. Reprinted with permission from: Schirmer BD. Bleeding duodenal ulcer. In: Fischer JF, Bland KI, eds. *Mastery of Surgery.* 5th ed. Philadelphia, PA: Lippincott Williams & Wilkins, 2007:885.

References:

Netter FH. *Atlas of Human Anatomy.* 2nd ed. Plates 282–285. East Hanover, NJ: Novartis; 1997.

Schirmer BD. Bleeding duodenal ulcer. In: Fischer JE, Bland KI, eds. *Mastery of Surgery.* 5th ed. Philadelphia, PA: Lippincott Williams & Wilkins; 2007:882–885.

۰۲۱-۶۶۱۹۸۵۱۴ www.myuptodate.com دریافت آخرین نسخه آپتودیت آفلاین

1G51

Key word: Diagnosis of Biliary Dyskinesia

Author: Susanna M. Nazarian, MD, PhD
Editor: Anne O. Lidor, MD, MPH

A 50-year-old woman presents to your outpatient clinic with a 4-week history of postprandial right upper quadrant pain. A right upper quadrant ultrasound does not show any evidence of cholelithiasis or cholecystitis. You should next:

(A) Admit her for hydration and pain control and schedule a laparoscopic cholecystectomy for the following day

(B) Arrange for an endoscopic retrograde cholangiopancreatography (ERCP)

(C) Obtain a noncontrast computed tomography (CT) scan

(D) Obtain an upper endoscopy

(E) Obtain cholecystokinin-cholescintigraphy (CCK-CS)

Answer: (E) Obtain cholecystokinin-cholescintigraphy (CCK-CS)

Rationale:

Biliary dyskinesia is characterized by right upper quadrant pain in the absence of cholelithiasis and a gallbladder ejection fraction of <40% on CCK-CS, also known as CCK-HIDA (hepatobiliary iminodiacetic acid) scan. The cutoff for gallbladder ejection fraction to achieve the diagnosis remains under debate. In the definitive paper by Yap, an ejection fraction of 40% after a 45-minute infusion of CCK was determined to be three standard deviations below the mean for normal. The pathophysiology of this condition is not entirely clear. A narrow cystic duct may contribute by preventing complete gallbladder emptying.

Cholecystectomy is the ultimate treatment for biliary dyskinesia but should not be performed until a confirmatory CCK-CS is obtained. A meta-analysis published in 2005 compared surgical versus nonsurgical therapy and found five studies that met their inclusion criteria. They reported pooled results of 98% symptomatic relief after surgical therapy compared with 32% for nonoperative management, P <0.0001. Patients undergoing surgery for biliary dyskinesia were 2.79 times more likely to have symptomatic relief compared with nonsurgical therapy.

References:

Ponsky TA, Desagun R, Brody F. Surgical therapy for biliary dyskinesia: a meta-analysis and review of the literature. *J Laparoendosc Adv Surg Tech A*. 2005;15(5):439–442.

Yap L, Wycherley AG, Morphett AD, et al. Acalculous biliary pain: cholecystectomy alleviates symptoms in patients with abnormal cholescintigraphy. *Gastroenterology.* 1991;101: 786–793.

1G52

Key word: Characteristics of Lipid Digestion and Absorption

Author: Robert A. Meguid, MD, MPH
Editor: Andrew M. Cameron, MD, PhD

Which of the following statements regarding lipid metabolism is correct?

(A) Fatty acids are used to synthesize glucose in times of starvation

(B) Fatty acids enter the tricarboxylic acid cycle as either acetyl-CoA or succinyl-CoA

(C) Glucagon and epinephrine act to promote fatty acid synthesis

(D) Insulin induces release of fatty acids from adipocytes

(E) Lipid oxidation occurs in the cytoplasm

Answer: (B) Fatty acids enter the tricarboxylic acid cycle as either acetyl-CoA or succinyl-CoA

Rationale:

Lipid metabolism is an important source of energy in humans. Triglycerides can be broken down into glycerol and fatty acids, and yield more energy than carbohydrates or proteins. However, while the body can utilize pyruvate (converted from glycerol) to generate glucose via gluconeogenesis, fatty acids cannot be utilized for this purpose. Insulin acts to promote fatty acid synthesis, while glucagon and epinephrine induce the release of fatty acids into circulation from adipocytes. Subsequently, these free fatty acids are taken up in peripheral tissues. While the cytoplasm is the location of fatty acid synthesis, lipid oxidation occurs in the outer mitochondrial membrane. Fatty acids enter the tricarboxylic acid cycle as either acetyl-CoA or succinyl-CoA, depending on whether they have even or odd numbers of carbons, respectively.

Reference:

Simmons RS, Steed DL, eds. *Basic Science Review for Surgeons.* St. Louis, MO: W.B. Saunders, 1992:113–115.

۰۲۱-۶۶۱۹۸۵۱۴ www.myuptodate.com دریافت آخرین نسخه آپتودیت آفلاین

1G53

Key word: Lower Esophageal Sphincter Pressure during Swallowing

Author: Clinton D. Kemp, MD
Editors: Stephen M. Cattaneo II, MD, and Robert A. Meguid, MD, MPH

A 52-year-old woman is referred to you after a several year history of progressive dysphagia that began with liquids and then progressed to include solid foods. She describes a sensation that her food is "sticking" and will not pass into her stomach. Barium swallow evaluation demonstrates diffuse dilation and a narrow tapering of the distal esophagus. Esophageal manometry reveals lower esophageal sphincter (LES) pressures that remain constant throughout a swallow test. You make the diagnosis of achalasia and discuss treatment options with her. Which of the following is true regarding the LES in healthy patients?

(A) Gastric distension causes decreased LES tone

(B) LES pressure decreases during the initiation of a swallow

(C) The LES can be visualized by upper endoscopy

(D) The LES is a specific anatomic sphincter

(E) The LES serves to prevent air from entering the stomach during a swallow

Answer: (B) LES pressure decreases during the initiation of a swallow

Rationale:

The esophagus is an approximately 25-cm long muscular tube that serves to allow passage of swallowed materials from the oropharynx into the stomach. Histologically it is comprised of an inner mucosal layer, a deep layer of circular muscle surrounded by a layer of longitudinal muscle, and an outer layer of adventitia without a serosa.

The upper esophageal sphincter (UES) is a 2.5- to 4.5-cm area of constriction in the cervical esophagus produced by contraction of the cricopharyngeus muscle. This muscle is tonically contracted with an average pressure of 42 mm Hg, producing an UES that remains closed at rest and serves to prevent air from entering the stomach during inspiration.

The LES is not an anatomic sphincter, but rather a geographic zone of 3 to 5 cm of distal esophagus with average pressures of 10 to 20 mm Hg whose function is to prevent reflux of gastric contents into the esophagus. This zone of pressure cannot be visualized on upper endoscopy, and is determined by pressure measurements during esophageal manometry. There are many hormonal, pharmacologic, and physiologic factors that affect LES pressures. Gastric distension after a meal increases LES tone.

During initiation of a normal swallow, pressures in the distal esophagus decrease with relaxation of the LES. Peristaltic waves that originate in the proximal esophagus propel food from the upper esophagus down toward the stomach, through the relaxed LES. Following passage of food, the LES contracts again and returns to its baseline pressure.

Patients with achalasia present with gradually progressive dysphagia for solids then liquids, and may experience regurgitation of undigested food from their esophagus or weight loss from decreased caloric intake. This condition results from decreased peristalsis and failure of relaxation of the LES, which in turn, leads to an inability of food to pass into the stomach. Histologically these patients demonstrate a loss of ganglionic cells in the Auerbach myenteric plexus. Radiographically on barium swallow examination a classic "birds beak" pattern may be present with a dilated proximal esophagus that tapers to a narrow opening into the stomach. On esophageal manometry one may see failure of the LES to relax normally and decreased peristaltic pressures during swallowing. Treatment includes administration of nitrates and calcium channel blockers for muscle relaxation, botulinum toxin injection, mechanical dilation, or surgical procedures designed to disrupt the circular layer of the muscular esophagus.

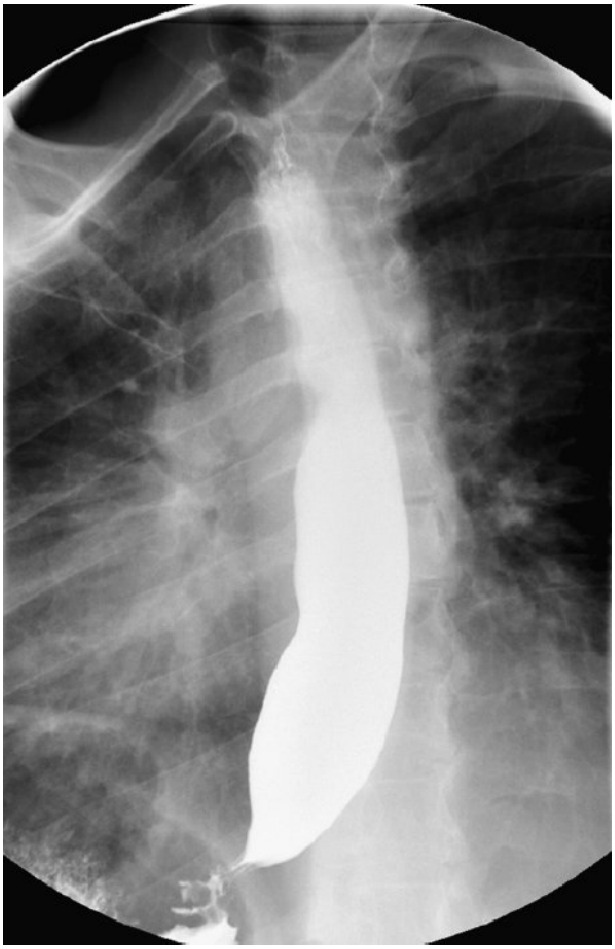

Barium esophagogram demonstrating achalasia, with classic "bird's beak" narrowing at esophagogastric junction. Proximal esophagus is aperistaltic and dilated. Reprinted with permission from: Dimick JB, Upchurch GR, Sonnenday CJ, eds. *Clinical Scenarios in Surgery*. Philadelphia: Lippincott Williams & Wilkins, 2012.

Reference:

Zwischenberger JB, Savage C. Esophagus. In: Townsend CM, Beachamp RD, Evers BM, Mattox KL, eds. *Sabiston Textbook of Surgery.* 17th ed. Philadelphia, PA: Elsevier; 2004:1091–1101.

۰۲۱-۶۶۱۹۸۵۱۴ www.myuptodate.com دریافت آخرین نسخه آپتودیت آفلاین

1G54

Key word: Most Accurate Diagnostic Imaging in Meckel Diverticulum

Author: Nikiforos Ballian, MBBS
Editors: Timothy M. Pawlik, MD, MPH, PhD, and Matthew J. Weiss, MD

A 2-year-old boy with no significant past medical history presents with a 1-month history of episodic, painless rectal bleeding. Findings on physical examination, including rectal examination, are unremarkable. The most useful imaging study in this situation is:

(A) ^{99m}Tc-pertechnetate scan
(B) Abdominal computed tomography (CT) scan
(C) Abdominal ultrasound scanning
(D) Barium enema
(E) Selective mesenteric angiography

Answer: (A) ^{99m}Tc-pertechnetate scan

Rationale:
Meckel diverticulae occur in approximately 2% of the population and are commonly asymptomatic. A Meckel diverticulum can manifest clinically at any age. Common presentations include abdominal pain secondary to diverticulitis, intestinal obstruction secondary to intussusception or volvulus, and painless bleeding. In children who present with painless bleeding secondary to a Meckel diverticulum, the prevalence of ectopic gastric mucosa approaches 100%. Ultrasound, barium enema, CT scanning, and angiography are rarely diagnostic. However, ^{99m}Tc-pertechnetate scintigraphy (Meckel scan)—which relies on selective uptake of the isotope by eutopic and ectopic gastric mucosa—is able to accurately identify a Meckel diverticulum.

References:
Emamian SA, Shalaby-Rana E, Majd M. The spectrum of heterotopic gastric mucosa in children detected by Tc-99 m pertechnate scintigraphy. *Clin Nucl Med.* 2001; 26(6):529–535.
Evers BM. Small intestine. In: Townsend CM, Beauchamp RD, Evers BM, Mattox KL, eds. *Sabiston Textbook of Surgery.* 17th ed. Philadelphia, PA: Saunders; 2004:1323–1380.
Park JJ, Wolff BG, Tollefson MK, et al. Meckel diverticulum: the Mayo Clinic experience with 1476 patients (1950–2002). *Ann Surg.* 2005;241:529–533.
Sai Prasad TR, Chui CH, Singaporewalla FR, et al. Meckel's diverticular complications in children: is laparoscopy the order of the day? *Pediatr Surg Int.* 2007; 23:141–147.
Swaniker F, Soldes O, Hirschl RB. The utility of technetium 99 m pertechnate scintigraphy in the evaluation of patients with Meckel's diverticulum. *J Pediatr Surg.* 1999;34: 760–764.

1G55

Key word: Organism Associated with Multiple Liver Abscesses

Author: Susanna M. Nazarian, MD, PhD
Editors: Robert A. Montgomery, MD, DPhil, FACS, and Dorry L. Segev, MD, PhD

A 48-year-old former alcoholic man is now 10 weeks status post liver transplantation. He has experienced several weeks of episodic fevers with leukocytosis, overall malaise, and failure to thrive. In addition, his liver enzymes have increased over the past several days. His blood cultures are positive but he has no central venous lines. His urine culture is negative for pathogens. Computed tomography (CT) of his abdomen reveals multiple liver abscesses. Which of the following organisms is most likely causing this condition?

(A) Echinococcus
(B) *Entamoeba histolytica*
(C) *Klebsiella pneumoniae*
(D) *Schistosoma mansoni*
(E) *Staphylococcus aureus*

Answer: (C) *Klebsiella pneumoniae*

Rationale:
Over the past 20 years, the etiology of hepatic abscesses has shifted from appendicitis and intraperitoneal infections to those derived from invasive procedures and stents for the biliary tree, pancreas, and liver. Currently, the most common sources of hepatic abscesses are obstructive biliary malignancies and stone disease.

Although infrequent, pyogenic liver abscesses (those of bacterial origin) are potentially lethal, and usually occur in the right lobe. Those at highest risk of mortality include patients with multiple abscesses, those with non-*K. pneumoniae* pathogens, those with mixed bacterial and fungal abscesses, those with abscesses ≥5 cm, and patients with respiratory symptoms. Men over the age of 50, liver transplant patients, those with diabetes, and those with malignancies are at greatest risk for the development of pyogenic abscesses. Gram-negative aerobes are found in two-thirds of pyogenic liver abscesses, including *Escherichia coli, K. pneumonia,* and Proteus species. Anaerobes, such as *Bacteroides fragilis* account for the other 30%. Up to 60% of patients have concordant positive blood cultures. In a liver transplant patient, a liver abscess is often associated with occlusion of the hepatic artery, with resulting biliary necrosis and abscess formation, and/or a biliary stricture.

Amebic liver abscesses are caused by *E. histolytica,* a protozoan. While up to 50% of the population in tropical and subtropical regions may be infected, the prevalence of infection in the United States is highest in the South (10%). However, abscesses develop in only 3% to 7% of those infected. Men who have sex with men, Native Americans living in reservations, military personnel, institutionalized individuals, and travelers to endemic areas are most at risk. Ingested amebic

۰۲۱-۶۶۱۹۸۵۱۴ www.myuptodate.com دریافت آخرین نسخه آپتودیت آفلاین

cysts pass through the stomach and into the intestine, where they multiply in the colon and eventually traverse the portal vein to the liver, leading to "anchovy paste"-filled cavities.

Echinococcus is endemic in the Mediterranean, particularly among sheep-rearing communities. Their definitive host is the dog, with humans serving as an intermediate host. Presenting symptoms include abdominal pain, jaundice, and biliary obstruction as the cysts enlarge. Finally, schistosomes may also cause liver abscesses.

Reference:

Subramanian A, Gurakar A, Klein A, et al. Hepatic infection and acute hepatic failure. In: Mulholland MW, Lillemoe KD, Doherty GM, Maier RV, Upchurch GR, eds. *Greenfield's Surgery: Scientific Principles & Practice.* 5th ed. Philadelphia, PA: Lippincott Williams & Wilkins; 2011.

۰۲۱-۶۶۱۹۸۵۱۴ www.myuptodate.com دریافت آخرین نسخه آپتودیت آفلاین

1G56

Key word: Metabolic Condition Associated with Gastric Outlet Obstruction

Author: Kashif A. Zuberi, MBBCh, MRCSI
Editors: Thomas H. Magnuson, MD, and Kenzo Hirose, MD, FACS

A 65-year-old woman is referred by her primary care provider for a 2-month history of progressive nausea, vomiting, palpitations, anorexia, and lethargy. A computed tomography (CT) scan is performed and reveals a mass in the first portion of the duodenum. The diagnosis of gastric outlet obstruction secondary to pancreatic cancer is made. She is admitted to hospital for further preoperative evaluation. What metabolic abnormalities require monitoring in this patient?

(A) Euvolemic, normokalemia, respiratory acidosis, normochloremia

(B) Hypervolemia, hyperkalemia, metabolic acidosis, hyperchloremia

(C) Hypovolemia, hyperkalemia, metabolic acidosis, normochloremia

(D) Hypovolemia, hypokalemia, metabolic alkalosis, hypochloremia

(E) Hypovolemia, normokalemia, metabolic alkalosis, normochloremia

Answer: (D) Hypovolemia, hypokalemia, metabolic alkalosis, hypochloremia

Rationale:
Gastric outlet obstruction is an anatomical pathology that may have several etiologies, including pyloric hypertrophy, pyloric gastric ulcer, pyloric mass, duodenal mass, pancreatic mass, large retroperitoneal sarcoma, duodenal ulcer, annular pancreas, and/or common bile duct mass. The protracted vomiting causes large amounts of fluid loss rich in acid (H^+ ion) and chloride, leading to a hypochloremic metabolic alkalosis. This volume of fluid loss can cause dehydration rapidly, manifested by loss of total body water and total body sodium. Furthermore, the loss of gastric contents and hypovolemia both promote renal K^+ excretion, which is augmented by aldosterone release.

References:
Singer GG. Fluid and electrolyte management. In: Ahya S, Flood K, Paranjothi S, eds. *The Washington Manual of Medical Therapeutics.* 30th ed. Philadelphia, PA: Lippincott Williams & Wilkins; 2001:69–75.

Wait RB, Alouidor R. Fluids, electrolytes, and acid-base balance. In: Mulholland MW, Lillemoe KD, Doherty GM, Maier RV, Upchurch GR, eds. *Greenfield's Surgery: Scientific Principles & Practice.* 5th ed. Philadelphia, PA: Lippincott Williams & Wilkins; 2011.

1G57

Key word: Characteristics of Primary Hyperaldosteronism

Authors: Susanna M. Nazarian, MD, PhD, and Eric S. Weiss, MD, MPH
Editor: Pamela A. Lipsett, MD, MHPE, FACS, FCCM

Which of the following characteristics is specific to the diagnosis of primary hyperaldosteronism?

(A) Adrenal tumor

(B) Aldosterone excess

(C) Edema

(D) Hypertension

(E) Hypokalemia

Answer: (A) Adrenal tumor

Rationale:
Hypertension accompanied by hypokalemia should raise suspicion for hyperaldosteronism, in which excessive aldosterone is secreted by the adrenal gland(s). Primary hyperaldosteronism is characterized by hyperaldosteronism due to an adrenal source with suppressed plasma renin. In contrast, patients with secondary hyperaldosteronism have elevated plasma renin. Primary hyperaldosteronism affects women twice as frequently as men, with peak incidence between the ages of 30 and 50. It is the cause of 5% to 15% of essential hypertension. Conn syndrome is caused by an aldosterone-producing adrenal adenoma and accounts for 60% to 70% of cases of primary hyperaldosteronism. Causes of excess aldosterone other than adrenal adenoma include idiopathic bilateral adrenal hyperplasia, adrenocortical carcinoma, and familiar forms of primary hyperaldosteronism such as autosomal dominant glucocorticoid-suppressible hyperaldosteronism.

Patients with hyperaldosteronism manifest the effects of sodium retention and elevated excretion of potassium and hydrogen ions. Eighty to ninety percent have hypokalemia, often leading to symptoms of fatigue, weakness, polyuria, and polydipsia. Differentiation between adrenal adenoma versus idiopathic hyperplasia is critical, because the former is treated surgically while the latter is managed medically. The contrast-enhanced CT scan and plasma aldosterone:plasma renin activity ratio (PAC/PRA) are helpful diagnostic tools. Patients with essential hypertension have a PAC/PRA ratio of 4 to 10, whereas those with primary hyperaldosteronism have a ratio >30. Confirmation of the diagnosis is gained through 24-hour urine collection after 3 days of salt loading: Patients with primary hyperaldosteronism will continue to secrete excess aldosterone in this setting. Adrenal vein sampling of cortisol and aldosterone after ACTH administration may be helpful to localize the source when there is no discernable abnormality on CT.

Surgical removal of the adenoma results in normalization of blood pressure and potassium levels in 70% to 90% of patients, with laparoscopy as the preferred approach. Poorer outcomes are seen in those with long-standing hyperaldosteronism, men, those over age 50, and in patients whose adrenal glands have multiple nodules.

۰۲۱-۶۶۱۹۸۵۱۴ www.myuptodate.com دریافت آخرین نسخه آپتودیت آفلاین

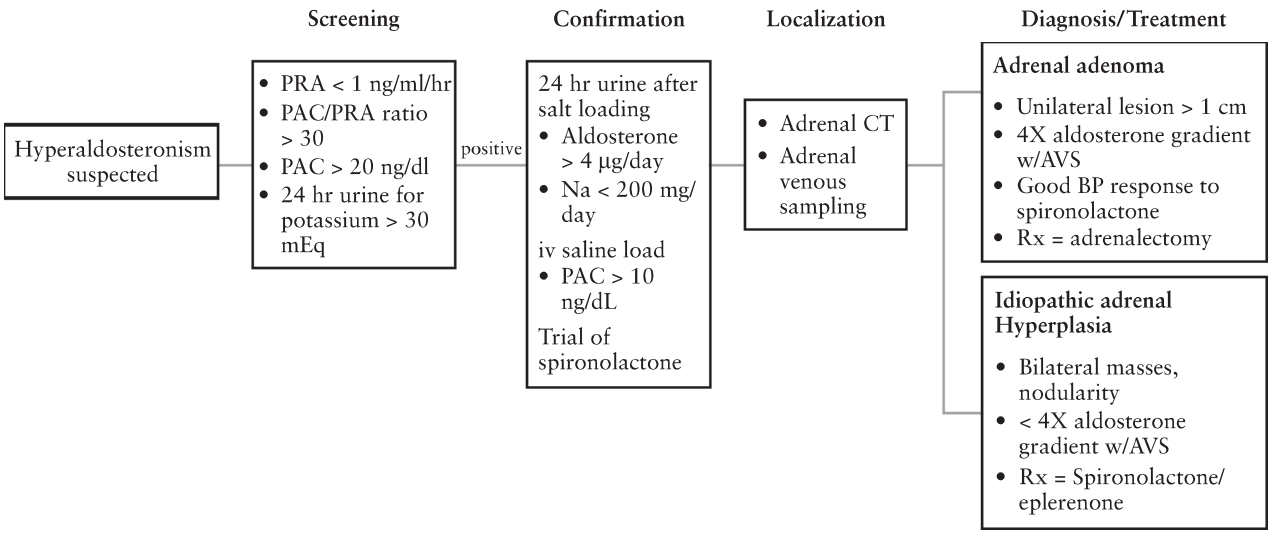

Diagnosis and management of hyperaldosteronism. PRA, plasma renin activity; PAC, plasma aldosterone concentration; CT, computed tomography; AVS, bilateral adrenal venous sampling. Reprinted with permission from: Olson JA, Scheri RP. Adrenal gland. In: Mulholland MW, Lillemoe KD, Doherty GM, Maier RV, Upchurch GR, eds. *Greenfield's Surgery: Scientific Principles & Practice.* 5th ed. Philadelphia, PA: Lippincott Williams & Wilkins, 2011:1333.

References:

Olson JA, Scheri RP. Adrenal gland. In: Mulholland MW, Lillemoe KD, Doherty GM, Maier RV, Upchurch GR, eds. *Greenfield's Surgery: Scientific Principles & Practice.* 5th ed. Philadelphia, PA: Lippincott Williams & Wilkins; 2011.

Stowasser M. Primary aldosteronism in 2011: Towards a better understanding of causation and consequences. *Nat Rev Endocrinol.* 2011;8(2):70–72.

۰۲۱-۶۶۱۹۸۵۱۴ www.myuptodate.com دریافت آخرین نسخه آپتودیت آفلاین

1G58

Key word: Pancreatic Enzyme Secretion

Author: Robert A. Meguid, MD, MPH
Editor: Anne O. Lidor, MD, MPH

Pancreatic enzymes are secreted as zymogens to prevent inappropriate activation within the pancreas. Which of the following enzymes can autoactivate to produce the active form of the enzyme?

(A) Carboxypeptidase A

(B) Chymotrypsin

(C) Elastase

(D) Enterokinase

(E) Trypsin

Answer: (E) Trypsin

Rationale:

Trypsinogen is the zymogen form of trypsin secreted by the exocrine pancreas. It undergoes activation predominantly by cleavage of its amino-terminal octapeptide by enterokinase in the lumen of the duodenum. Under conditions of low pH (~6) and high calcium levels (>1 mM) such as those of the duodenal lumen, autoactivation of trypsinogen to trypsin occurs.

Active trypsin then activates the other zymogen products of the pancreas, converting chymotrypsinogen to chymotrypsin, proelastase to elastase, kallikreinogen to kallikrein, procarboxypeptidase A and B to carboxypeptidase A and B, and prophospholipase A_2 to phospholipase A_2. However, none of these other zymogens can autoactivate.

Enterokinase is produced by the duodenal mucosa.

Reference:

Lee KKW, Durham SJ. Physiology of the exocrine pancreas. In: Simmons RL, Steed DL, eds. *Basic Science Review for Surgeons.* Philadelphia, PA: W.B. Saunders; 1992:263.

1G59

Key word: Treatment of Pancreatic Fistula

Author: Eric S. Weiss, MD, MPH
Editor: Richard D. Schulick, MD, MBA, FACS

A 68-year-old man presents with progressive onset of painless jaundice due to an adenocarcinoma located in the pancreatic head. He undergoes a pylorus-preserving pancreaticoduodenectomy without intraoperative complications. A peripancreatic drain is placed intraoperatively. Postoperative course is unremarkable and on postoperative day 4, he is advanced to a regular diet. Upon resuming this regular diet, it is noticed that the patient's peripancreatic drain begins to produce moderate volumes of murky fluid. An amylase level is sent from this fluid, which returns at 2,000 units/L (normal 23 to 85 units/L). The patient is kept in the hospital and the drain output over the next 3 days is 85 mL/24 hrs, 73 mL/24 hrs, and 65 mL/24 hrs. During this time, the patient looks and feels well, is able to tolerate a regular diet, and has no fever or elevation of white blood cell count. Which of the following is the most appropriate way to manage this problem?

(A) Continued hospitalization with continued drainage

(B) Delayed removal of drain over course of weeks with continuation of diet

(C) Removal of pancreatic drain and patient discharge

(D) Reoperative exploration

(E) Total parenteral nutrition with continued drainage

Answer: (B) Delayed removal of drain over course of weeks with continuation of diet

Rationale:

Pancreatic fistulas occur with an incidence of 5% to 12% in patients who have undergone a pancreaticoduodenectomy. Pancreatic trauma and surgery for pancreatic necrosis can often lead to fistulas as well. Diagnosis of a pancreatic fistula is confirmed by high amylase levels measured in drains following surgery. When fistulas are low output (e.g., less than 200 mL/day) they can be managed conservatively. The main principle of conservative management includes management of the tract by steadily removing the intraoperatively placed drain to limit spillage of pancreatic secretions into the abdomen, once drainage is less than 30 mL/day. Other important aspects of care include drainage by interventional radiology techniques of any major intra-abdominal fluid collections, antibiotics as needed to limit and treat systemic infection, and skin care for excoriations if some of the fistulous output comes around drains or through the wound. Most pancreatic fistulae will close spontaneously over time with this technique and the need for reoperation is quite rare. When the drain output falls to 20 to 30 cm^3/day, the drain can be safely removed.

Conservative management is of course predicated on the fact that the patient appears well clinically. If the patient displays signs of acute illness such as fever, white blood cell count elevation, hemodynamic instability, or if the fistula output remains high (>200 mL/day), maintenance of regular diet

۰۲۱-۶۶۱۹۸۵۱۴ www.myuptodate.com دریافت آخرین نسخه آپتودیت آفلاین

may not be an option. In these cases, a trial of NPO with total parenteral nutrition may be a good alternative. In addition, some authors have advocated the use of the somatostatin analog octreotide to aid in the closure of postsurgical pancreatic fistulas.

Reference:

Sohn TA, Yeo CJ. Pancreatic and periampullary carcinoma (nonendocrine). In: Turcotte JG, ed. *Shackelford's Surgery of the Alimentary Tract.* 5th ed. Vol. 3, Philadelphia, PA: W.B. Saunders; 2002:79–80.

1G60

Key word: Treatment of Cancer at the Hepatic Flexure

Authors: Kashif A. Zuberi, MBBCh, MRCSI, and Susanna M. Nazarian, MD, PhD
Editor: Mark D. Duncan, MD, FACS

A 58-year-old male presents complaining of constipation, nausea, loss of appetite, right-sided flank pain, and postural dizziness. A complete blood count (CBC) is drawn and reveals hemoglobin of 6.8 g/dL and slightly elevated WBC count of 12,000. Colonoscopy reveals a circumferential narrowing at the hepatic flexure that bleeds easily when biopsied. Computed tomography (CT) shows some enlarged mesenteric lymph nodes and a normal liver. The patient is referred for surgery. Which procedure would best benefit this patient?

(A) Extended right hemicolectomy

(B) Right hemicolectomy

(C) Subtotal colectomy with primary anastomosis

(D) Total colectomy with ileorectal anastomosis

(E) Total proctocolectomy with ileal-pouch anal anastomosis

Answer: **(A)** Extended right hemicolectomy

Rationale:

The current mainstay of treatment for colonic tumors is surgical resection, as this is the only therapy that can offer a cure. There is also a role for both chemotherapy and radiotherapy as adjuvant therapy in the treatment of advanced disease. The most appropriate management of colonic tumors is radical excision of the affected section of the colon and 5 cm of normal large intestine proximal and distal to the pathology. The vascular pedicle and accompanying lymphatic drainage must be removed as well.

This patient described has a T3 N1/2 lesion and is stage IIIB or IIIC. T3 tumors invade through the muscularis propria into the subserosa and may invade into (but not through) the serosa. N1 refers to 1 to 3 regional lymph nodes involved, while N2 indicates ≥4 nodes involved. Tumors at the hepatic flexure require an extended right hemicolectomy with ligation of the middle colic artery. Perfusion of the remaining colon is therefore based on the left colic artery.

۰۲۱-۶۶۱۹۸۵۱۴ www.myuptodate.com دریافت آخرین نسخه آپتودیت آفلاین

TNM Staging Classification of Colorectal Cancer

Primary Tumor (T)			
TX	Primary tumor cannot be assessed		
T0	No evidence of primary tumor		
T_{IS}	Carcinoma in situ: Intraepithelial or invasion of the lamina propria without invasion through the muscularis mucosae into the submucosa		
T1	Tumor invades submucosa		
T2	Tumor invades muscularis propria		
T3	Tumor invades through the muscularis propria into the subserosa or into nonperitonealized pericolic or perirectal tissues		
T4a	Tumor penetrates to the surface of the visceral peritoneum		
T4b	Tumor directly invades or is adherent to other organs or structures		
Regional Lymph Nodes (N)			
NX	Regional lymph nodes cannot be assessed		
N0	No regional lymph node metastasis		
N1	Metastasis in one to three regional lymph nodes		
N1a	Metastasis in one regional lymph node		
N1b	Metastasis in two to three regional lymph nodes		
N1c	Tumor deposit(s) in the subserosa, mesentery, or nonperitonealized pericolic or perirectal tissues without regional nodal metastases		
N2	Metastasis in four or more regional lymph nodes		
N2a	Metastasis in four to six regional lymph nodes		
N2b	Metastasis in seven or more regional lymph nodes		
Distant Metastases (M)			
MX	Distant metastasis cannot be assessed		
M0	No distant metastasis		
M1	Distant metastases present		
M1a	Metastasis confined to one organ or site (e.g., liver, lung, ovary, nonregional node)		
M1b	Metastases in more than one organ/site or the peritoneum		
Stage Grouping			
0	Tis	N0	M0
I	T1	N0	
	T2	N0	M0
IIA	T3	N0	M0
IB	T4a	N0	M0
IIC	T4b	N0	M0
IIA	T1–T2	N1/N1c	M0
	T1	N2a	M0
IIIB	T3–T4a	N1/N1c	M0
	T2–T3	N2a	M0
	T1–T2	N2b	M0
IIC	T4 a	N2a	M0
	T3–T4a	N2b	M0
	T4b	N1–N2	M0
IVA	Any T	Any N	M1a
IVB	Any T	Any N	M1b

Reprinted with permission from Silberfein EJ, Chang GJ, You YQN, et al. Cancer of the colon, rectum, and anus. In: Feig BW, Ching CD, eds. *The MD Anderson Surgical Oncology Handbook*, 5th ed. Philadelphia, PA: Lippincott Williams & Wilkins, 2012:361.

۰۲۱-۶۶۱۹۸۵۱۴ www.myuptodate.com دریافت آخرین نسخه آپتودیت آفلاین

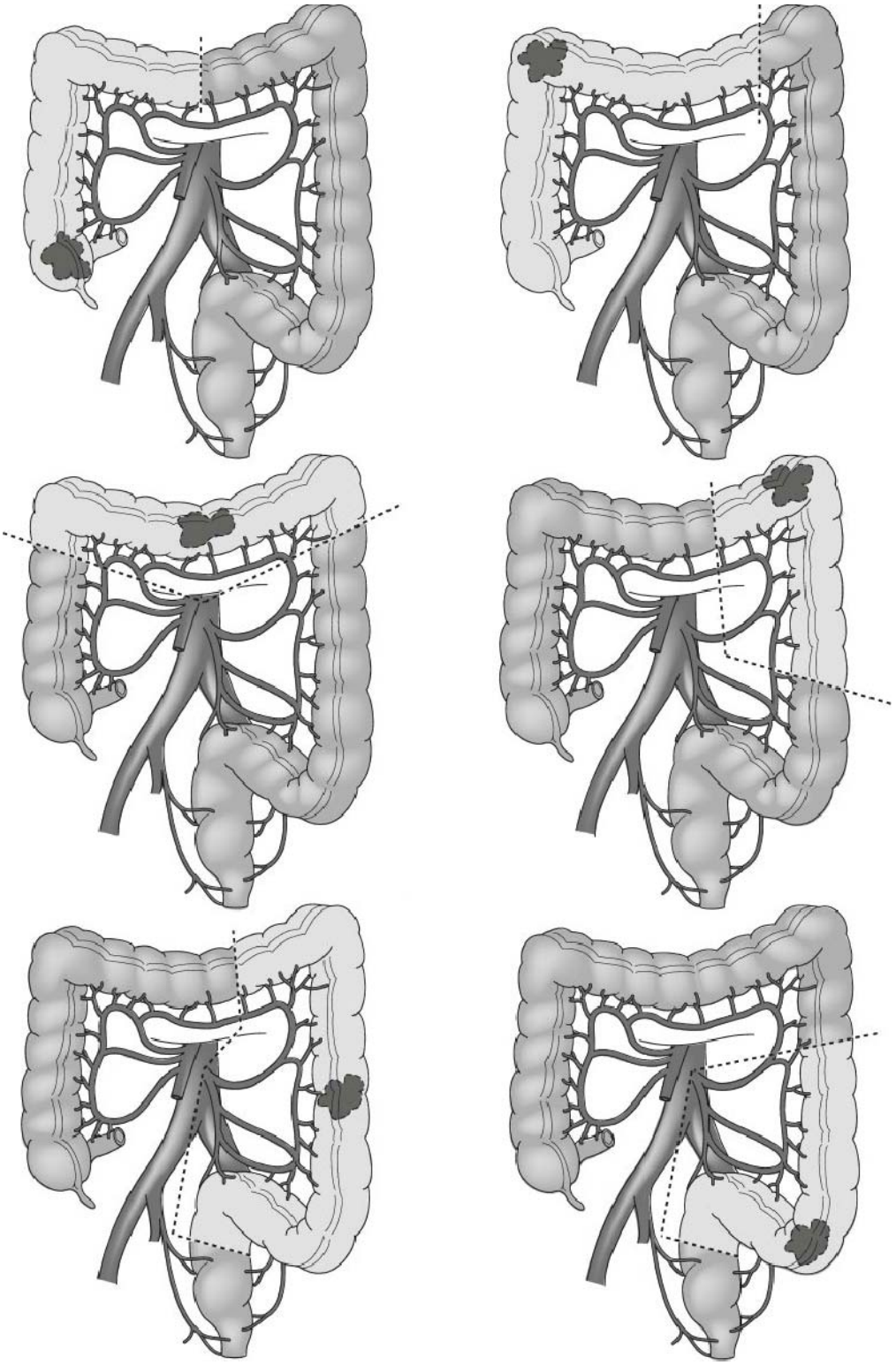

Segmental resections for cancers of the colon and upper third of the rectum. Reprinted with permission from: Morris A. Colorectal cancer. In: Mulholland MW, Lillemoe KD, Doherty GM, Maier RV, Upchurch GR, eds. *Greenfield's Surgery: Scientific Principles & Practice*. 5th ed. Philadelphia, PA: Lippincott Williams & Wilkins, 2011:1110.

۰۲۱-۶۶۱۹۸۵۱۴ www.myuptodate.com دریافت آخرین نسخه آپتودیت آفلاین

Reference:
Morris A. Colorectal cancer. In: Mulholland MW, Lillemoe KD, Doherty GM, Maier RV, Upchurch GR, eds. *Greenfield's Surgery: Scientific Principles & Practice.* 5th ed. Philadelphia, PA: Lippincott Williams & Wilkins; 2011.

1G61

Key word: Patients with the Highest Rate of Breast Cancer

Author: Eric S. Weiss, MD, MPH
Editors: Julie R. Lange, MD, ScM, FACS, and Mehran Habibi, MD, MBA

Which of the following risk factors predicts the highest risk of developing breast cancer?

(A) Age greater than 55

(B) Biopsy-proven lobular carcinoma in situ (LCIS)

(C) BRCA-1 or BRCA-2 (breast cancer 1 or breast cancer 2) mutation

(D) Mother with breast cancer

(E) Nulliparity

Answer: (C) BRCA-1 or BRCA-2 (breast cancer 1 or breast cancer 2) mutation

Rationale:
All of the above are significant risk factors for the development of breast cancer. However, with a lifetime risk of approximately 70%, carriers of BRCA-1 or BRCA-2 (breast cancer 1 or breast cancer 2) mutations have the highest risk of developing breast cancer. The genes, located on chromosome 17 and 13 respectively, dramatically increase both breast and ovarian cancer risk when mutated. In the absence of a known deleterious mutation, women older than 55 have a two-fold increase in the risk of developing breast cancer. Having a mother with breast cancer increases the risk three-fold.

The management of the high-risk patient is complicated and includes close observation with semiannual breast examinations and annual mammograms beginning at age 25 for persons with known BRCA abnormalities. In general, mammography should commence 10 years prior to the age of diagnosis in affected relatives. Consideration should be given for chemoprevention with the estrogen antagonist tamoxifen. Finally, in the case of BRCA mutations or if the patient choice dictates, bilateral prophylactic mastectomies are a viable treatment option.

Reference:
Iglehart JD, Kaelin CM. Diseases of the breast. In: Townsend CM, Beauchamp RD, Evers BM, Mattox KL, eds. *Sabiston Textbook of Surgery: The Biological Basis of Modern Surgical Practice.* 17th ed. Philadelphia, PA: Elsevier Saunders; 2004:867–927.

۰۲۱-۶۶۱۹۸۵۱۴ www.myuptodate.com دریافت آخرین نسخه آپتودیت آفلاین

1G62

Key word: Characteristics of T3 Colon Cancer

Author: Robert A. Meguid, MD, MPH
Editors: Timothy M. Pawlik, MD, MPH, PhD, and Matthew J. Weiss, MD

Which of the following is a characteristic of T3 colon cancer?

(A) Lesion invading through the muscularis propria into the serosa

(B) Lesion invading through the serosa into adjacent organs

(C) Lesion invading through the serosa into the free peritoneal cavity

(D) Lesion invading through the submucosa into the muscularis propria

(E) Lesion not penetrating the submucosa

Answer: **(A)** Lesion invading through the muscularis propria into the serosa

Rationale:
See commentary on question 1G60 for colorectal cancer staging table. According to the American Joint Committee on Cancer (AJCC), tumor-node-metastasis (TNM) staging classification for colorectal cancer, T3 lesions invade completely through the muscularis propria into the subserosa but not to any neighboring organs or tissues. Answer choice **(B)** is T4b, **(C)** is T4a, **(D)** is T2, and **(E)** is T1.

Reference:
Silberfein EJ, Chang GJ, You Y-QN, et al. Cancer of the colon, rectum, and anus. In: Feig BW, Ching CD, eds. *The M.D. Anderson Surgical Oncology Handbook*. 5th ed. Philadelphia, PA: Lippincott Williams & Wilkins; 2012.

۰۲۱-۶۶۱۹۸۵۱۴ www.myuptodate.com دریافت آخرین نسخه آپتودیت آفلاین

دریافت آخرین نسخه آپتودیت آفلاین www.myuptodate.com ۰۲۱-۶۶۱۹۸۵۱۴

3
CARDIOVASCULAR AND RESPIRATORY

CONTENTS:

Number:	Key Word:	Page:
1C01	Angioplasty Site with Long Patency	166
1C02	Common Complications of Popliteal Aneurysms	166
1C03	Advantage of Lytic Therapy for Lower-extremity Ischemia	167
1C04	Treatment of Embolus Post-myocardial Infarction	168
1C05	Etiology of Late Hemorrhage of Vascular Grafts	169
1C06	Diagnosis of *Staphylococcus Epidermidis* Graft Infection	170
1C07	Classification of Endoleaks	171
1C08	Etiology of Late Death after Heart Transplant	173
1C09	Adjuncts to Improve Vascular Graft Patency	173
1C10	Characteristics of Thoracic Outlet Syndrome	174
1C11	Treatment of Occlusion of the Common Iliac Artery in Patients with COPD	175
1C12	Treatment of Air Embolus	176
1C13	Hypovolemic Shock	177
1C14	Treatment of Plantar Ulcer	178
1C15	Treatment of Superior Vena Cava Syndrome	179
1C16	Treatment of Pulmonary Contusion	180
1C17	Characteristics of Rest Pain	181
1C18	Preferred Route for Central Venous Access	182
1C19	Treatment of Cardiac Tamponade	182
1C20	Indications for Thoracotomy after Gunshot Wound to the Chest	183
1C21	Diagnostic Test for "Tearing" Chest Pain	183
1C22	Treatment of Hepatic Artery Aneurysm	184
1C23	Characteristics of Splenic Artery Aneurysms	185
1C24	Treatment of Tachyarrhythmias	186
1C25	Anatomy of Scalenus Anticus Muscle	187
1C26	Determination of Cardiac Output and Systemic Vascular Resistance	188
1C27	Treatment of Carotid Fibromuscular Dysplasia	189
1C28	Most Common Site of Lung Abscess	190
1C29	Likely Etiology of Acute Pulseless Leg	190
1C30	Characteristics of Normal Lower-extremity Venous Pressure Studies	191
1C31	Renal Effects of PEEP	192
1C32	Effect of AV Fistula on Cardiac Performance	192
1C33	Findings by Pulmonary Artery Catheter in a Patient with an Acute Myocardial Infarction	193
1C34	Contraindications to Pneumonectomy	194
1C35	Treatment of Adenocarcinoma of the Lung	194
1C36	Characteristics of Extralobar Pulmonary Sequestration	198
1C37	Effect of Inspiration Phase of Mechanical Ventilation on Cardiac Dynamics	199

۰۲۱-۶۶۱۹۸۵۱۴ www.myuptodate.com دریافت آخرین نسخه آپتودیت آفلاین

1C01

Key word: Angioplasty Site with Long Patency

Author: Robert A. Meguid, MD, MPH
Editor: William A. Baumgartner, MD

A 76-year-old man with aortoiliac occlusive disease undergoes percutaneous transluminal angioplasty of his left common iliac artery. What is the patency rate for patients who undergo angioplasty for iliac occlusive disease?

(A) 10% at 5 years
(B) 20% at 5 years
(C) 30% at 5 years
(D) 60% at 5 years
(E) 80% at 5 years

Answer: (D) 60% at 5 years

Rationale:
Percutaneous transluminal angioplasty for stenotic lesions in peripheral arteries is considered a viable option for patients thought to be at high risk for surgery. The use of angioplasty instead of vascular bypass avoids the risks and complications of anesthesia, and is associated with shortened hospital stays and more rapid return to normal activities. The overall patency of angioplasty for stenotic lesions is 70% to 80% at 1 year and 50% to 60% at 5 years. Complications specific to angioplasty include vascular dissection, vessel rupture, and distal embolization, which may occur up to 4% of the time.

References:
Abularrage CJ, Conrad MF. Aortoiliac occlusive disease. In: Cameron JL, Cameron AM, eds. *Current Surgical Therapy.* 10th ed. Philadelphia, PA: Mosby; 2011:769–779.
Kudo T, Chandra FA, Ahn SS. Long-term outcomes and predictors of iliac angioplasty with selective stenting. *J Vasc Surg.* 2005;42:466–475.

1C02

Key word: Common Complications of Popliteal Aneurysms

Author: Robert A. Meguid, MD, MPH
Editors: G. Melville Williams, MD, FACS, and Christopher J. Abularrage, MD

A 68-year-old man presents with pain in his left leg. Examination and workup confirm diagnosis of a popliteal aneurysm. What is the most common complication that would result in the patient's leg pain?

(A) Aortic aneurysm rupture
(B) Nerve impingement by the popliteal aneurysm
(C) Popliteal aneurysm rupture
(D) Thromboembolic events associated with the popliteal aneurysm
(E) Venous obstruction by the popliteal aneurysm

Answer: (D) Thromboembolic events associated with the popliteal aneurysm

Rationale:
Fifty to eighty percent of patients with popliteal aneurysms present with symptoms most commonly due to ischemia. Ischemia develops due to thrombosis of the aneurysm, distal embolization to the tibial or pedal arteries, or a combination of these. The resulting ischemia may manifest itself in a range from mild claudication to gangrene depending on the extent of thrombosis and embolization. Thromboembolism ultimately occurs in up to 35% of popliteal aneurysms if left untreated.

Less common complications of popliteal aneurysms include venous obstruction and nerve impingement due to local compression by the aneurysm. Popliteal aneurysm rupture is rare, occurring in less than 5% of patients.

Popliteal aneurysms are the most frequent site of peripheral arterial aneurysms. Ninety-five percent are caused by atherosclerosis, and they occur bilaterally 40% to 60% of the time. Of note, there is a high incidence of other concurrent aneurysms, so examination must be inclusive for abdominal, iliac, and femoral artery aneurysms. The incidence of concomitant abdominal aortic aneurysm is approximately 25%.

Diagnosis is initially clinical, with popliteal aneurysms palpable as a pulsatile or, in the case of thrombosis, firm mass. Confirmation of diagnosis on physical examination is made via ultrasound or computed tomography (CT) angiography.

References:
Makhoul RG. Popliteal artery aneurysms. In: Sabiston DC, Lyerly HK eds. *Textbook of Surgery.* 15th ed. Philadelphia, PA: W.B. Saunders; 1997:1675–1677.
Messiner R, Han DC. Popliteal and femoral artery aneurysms. In: Cameron JL, Cameron AM eds. *Current Surgical Therapy.* 10th ed. Philadelphia, PA: Mosby; 2011:793–798.

۰۲۱-۶۶۱۹۸۵۱۴ www.myuptodate.com دریافت آخرین نسخه آپتودیت آفلاین

1C03

Key word: Advantage of Lytic Therapy for Lower-extremity Ischemia

Author: Robert A. Meguid, MD, MPH
Editors: James H. Black III, MD, FACS, and Christopher J. Abularrage, MD

A 68-year-old man with atrial fibrillation presents to the emergency room with a cool, pulseless right foot. Sensation is intact. Duplex ultrasound of the right leg reveals multiple femoral stenoses and tibioperoneal thrombosis with poor tibial flow. What is the most appropriate management?

(A) Amputation

(B) Diagnostic angiography

(C) Intra-arterial site-directed thrombolysis

(D) Percutaneous embolectomy under local anesthesia

(E) Systemic anticoagulation only

Answer: (C) Intra-arterial site-directed thrombolysis

Rationale:

Thrombolysis is indicated for patients with no or only mild sensorimotor deficits. Furthermore, this technique is useful when complete clot evacuation is unlikely using surgical embolectomy, or when the distal vessels are also occluded preventing inflow patency. A confirmatory angiography should be performed following intra-arterial site-directed thrombolysis.

Arterial narrowing may preclude balloon catheter placement for surgical embolectomy in some patients. In these cases, a guidewire can be passed into and through the clot, followed by an infusion catheter. Arteriography can be performed to confirm the extent of clot and to guide catheter placement. Then, lytic agents can be injected through side holes in the catheter, perfusing the clot from within.

Intra-arterial site-directed thrombolysis allows simultaneous identification of the nature of the lesion via angiography, suggesting stenting or balloon dilation of stenoses. In addition, this allows for the monitoring of progress in thrombolysis. If thrombolysis is not progressing, surgical therapy may be indicated. Thrombolysis should not be used for common femoral artery emboli.

Absolute contraindications to lytic therapy include active internal bleeding, cerebrovascular accident within 2 months, and intracranial disease. Relative contraindications include surgery or trauma within 10 days, likelihood of left heart thrombus, episodes of serious gastrointestinal bleeding within 90 days, hypertension, pregnancy, bacterial endocarditis, and diabetic hemorrhagic retinopathy.

References:

Henke PK, Wakefield TW. Hemostasis. In: Mulholland MW, Lillemoe KD, Doherty GM, Maier RV, Upchurch GR, eds. *Greenfield's Surgery: Scientific Principles & Practice.* 5th ed. Philadelphia, PA: Lippincott Williams and Wilkins; 2011.

Owings JT. Venous thromboembolism. In: Souba WW, Fink MP, Jurkovich GJ, Kaiser LR, Pearce WH, Pemberton JH, Soper NJ, eds. *ACS Surgery: Principles and Practice.* 4th ed. New York, NY: WebMD; 2004:719–737.

Pamoukian VN, Shortell CK. Pulseless extremity and atheroembolism. In: Souba WW, Fink MP, Jurkovich GJ, Kaiser LR, Pearce WH, Pemberton JH, Soper NJ, eds. *ACS Surgery: Principles and Practice.* 4th ed. New York, NY: WebMD; 2004:696–707.

۰۲۱-۶۶۱۹۸۵۱۴ www.myuptodate.com دریافت آخرین نسخه آپتودیت آفلاین

1C04

Key word: Treatment of Embolus Post-myocardial Infarction

Author: Robert A. Meguid, MD, MPH
Editor: William A. Baumgartner, MD

A 73-year-old man has developed a pulseless left lower leg 8 days after experiencing a myocardial infarction (MI) requiring cardiopulmonary resuscitation. On examination, he has diminished sensation in his left foot. What is the most appropriate definitive treatment?

(A) Amputation

(B) Anticoagulation using intravenous heparin

(C) Intra-arterial site-directed thrombolysis

(D) Percutaneous embolectomy under local anesthesia

(E) Surgical bypass

Answer: **(D)** Percutaneous embolectomy under local anesthesia

Rationale:

The most common cause of peripheral arterial embolization is atrial fibrillation, accounting for 66% to 75% of all cases. The second most common cause (20%) is MI resulting in embolization of left ventricular wall thrombus. Peripheral arterial embolization occurs in 5% of patients with mural wall thrombus, and occurs most frequently between 3 and 28 days after MI.

Treatment for the acutely ischemic limb is guided by category of limb ischemia. Initial workup includes history and physical examination, Doppler ultrasound evaluation of the threatened limb, and prompt initiation of heparin anticoagulation. Current recommendations for unfractionated heparin are an initial bolus of 80 units/kg IV, followed by infusion of 18 units/kg/hr, titrating to a goal aPTT ratio of 2. Determination of the category of limb ischemia is by physical examination and ultrasonography or angiography. Category I is occlusion of a narrowed artery with good collateral perfusion. Treatment is limited to anticoagulation. Category II is a threatened limb that may be salvaged after embolectomy. Category III is a nonsalvageable limb, requiring amputation.

Appropriate management of category II acute limb ischemia is either through emergent surgical embolectomy or intra-arterial site-directed thrombolysis. The risks of thrombolytic agents must be evaluated, especially in patients who have undergone recent cardiopulmonary resuscitation. In addition, thrombolytic agents are not indicated in patients who have sensorimotor deficits. Left heart thrombus is a relative contraindication to lytic therapy.

Embolectomy with or without revascularization is indicated in patients with sensorimotor deficits. This may be performed percutaneously or surgically. Of note, in patients having suffered recent MI, the risk of intraoperative or postoperative repeat MI is greatly increased; therefore, percutaneous embolectomy under local anesthesia is favored.

Reference:

Tucker SW, Pamoukian VN, Shortell CK. Chapter 65: Pulseless extremity and atheroembolism. In: Souba WW, Fink MP, Jurkovich GJ, Kaiser LR, Pearce WH, Pemberton JH, Soper NJ, eds. *ACS Surgery: Principles and Practice.* 6th ed. New York, NY: WebMD; 2007. Accessed October 12, 2011. Online Edition.

۰۲۱-۶۶۱۹۸۵۱۴ www.myuptodate.com دریافت آخرین نسخه آپتودیت آفلاین

1C05

Key word: Etiology of Late Hemorrhage of Vascular Grafts

Authors: Robert A. Meguid, MD, MPH, and Susanna M. Nazarian, MD, PhD
Editor: Julie A. Freischlag, MD

Eighteen months after undergoing an aortobifemoral artery bypass, a 74-year-old man presents with a painful swelling in his left groin. Ultrasound demonstrates a pseudoaneurysm at the site of the distal anastomosis with surrounding fluid. What is the likely underlying cause of this finding?

(A) Atheroembolism
(B) Graft failure
(C) Graft infection
(D) Graft thrombosis
(E) Suture failure

Answer: (C) Graft infection

Rationale:

Anastomotic disruption is the cause of delayed hemorrhage in vascular grafts. While the exact cause of disruption is usually unknown, graft infection is suspected in most cases.

Infection by virulent bacteria usually results in graft infections within 4 months of surgery. Patients develop signs of sepsis as well as evidence of local infection. Bacteria contributing to early graft infection include *Staphylococcus aureus,* Proteus, Klebsiella, Enterobacter, and Pseudomonas, all of which produce proteases and break down the arterial wall adjacent to the anastomosis. This results in separation of the graft from the host artery, creating a pseudoaneurysm. These may rupture, thrombose, or embolize. Less virulent bacteria such as *Staphylococcus epidermidis* may cause delayed graft infections. Infection of the graft may originate from septic emboli, usually from mitral or aortic valves, or from direct contamination of the graft during initial surgery. Successful treatment of graft infection includes systemic antibiotics and frequently, graft removal and revision.

Poor suture technique has been suspected as a cause of graft failure. However, studies have shown that most cases of anastomotic disruption are due to graft infection. Graft failure due to graft dilation was associated with ultra lightweight knitted Dacron grafts used in the early 1970s. This prosthetic has since been abandoned by manufacturers. Suture failure was previously found with silk sutures in vascular anastomoses. Anastomoses are currently created with more durable suture material such as polypropylene or monofilament expanded polytetrafluroethylene (ePTFE).

In a review of 307 patients who underwent abdominal aortic aneurysm (AAA) repair between 1957 and 1990 at the Mayo Clinic, 9.4% of patients had a graft-related complication. At a mean follow-up of 5.8 years, the rates of complications were as follows: Anastomotic pseudoaneurysm (3%), graft thrombosis (2%), graft-enteric erosion/fistula (1.6%), graft infection (1.3%), anastomotic hemorrhage (1.3%), colon ischemia (0.7%), and atheroembolism (0.3%). In this study, there were no complications attributable to graft failure such as dilation or rupture.

References:

Brady CM, Chaikof EL. Management of infected vascular grafts. In: Cameron JL, Cameron AM, eds. *Current Surgical Therapy.* 10th ed. Philadelphia, PA: Mosby; 2011: 857–861.

Clagett GP. Vascular infections. In: Mulholland MW, Lillemoe KD, Doherty GM, Maier RV, Upchurch GR, eds. *Greenfield's Surgery: Scientific Principles & Practice.* 5th ed. Philadelphia, PA: Lippincott Williams and Wilkins; 2011.

Hallett JW, Marshall DM, Petterson TM, et al. Graft-related complications after abdominal aortic aneurysm repair: Reassurance from a 36-year population-based experience. *J Vasc Surg.* 1997;25(2):277–286.

Moneta GL, Porter JM. Arterial substitutes. In: Sabiston DC, Lyerly HK, eds. *Textbook of Surgery.* 15th ed. Philadelphia, PA: W.B. Saunders; 1997:1634–1635.

Montreuil B, Morrison L, Rosenberg L, et al. Vascular and peritoneal access. In: Souba WW, Fink MP, Jurkovich GJ, Kaiser LR, Pearce WH, Pemberton JH, Soper NJ, eds. *ACS Surgery: Principles and Practice.* 4th ed. New York, NY: WebMD; 2004:835.

۰۲۱-۶۶۱۹۸۵۱۴ www.myuptodate.com دریافت آخرین نسخه آپتودیت آفلاین

1C06

Key word: Diagnosis of *Staphylococcus Epidermidis* Graft Infection

Author: Robert A. Meguid, MD, MPH
Editors: James H. Black III, MD, FACS, and Christopher J. Abularrage, MD

Eighteen months after undergoing an aortobifemoral artery bypass, a 69-year-old woman presents with a draining, cellulitic wound in her right groin, with exposed polytetrafluoroethylene (PTFE) graft. What is the most likely pathogen infecting this graft?

(A) *Enterobacter cloacae*

(B) *Klebsiella pneumoniae*

(C) *Pseudomonas aeruginosa*

(D) *Staphylococcus aureus*

(E) *Staphylococcus epidermidis*

Answer: (E) *Staphylococcus epidermidis*

Rationale:

S. epidermidis is the most common pathogen associated with infection of implanted medical devices. Characteristically, it causes local chronic infection, but not systemic infection. *S. epidermidis* produces exopolysaccharides that coat the infected area. This "slime" or "biofilm" protects the bacteria from host defenses and antibiotics, allowing the *S. epidermidis* to propagate.

Infection by virulent bacteria usually results in graft infection within 4 months of surgery. Bacteria contributing to early graft infection include *S. aureus,* Proteus, Klebsiella, Enterobacter, and Pseudomonas. Less virulent bacteria such as *S. epidermidis* may cause delayed graft infections, often presenting over 1 year after surgery. Infection of the graft may originate from septic emboli from mitral or aortic valves, or from direct contamination of the graft during initial surgery.

Patients may present with signs of sepsis, as well as evidence of local infection, including cellulitis, draining tracts, and pulsatile masses (indicating mycotic pseudoaneurysms). Exposed graft should be assumed to be infected. In the case of aortic grafts, patients may present with sentinel gastrointestinal bleeding or major hemorrhage due to an aortoenteric fistula. Alternately, graft-enteric erosion may occur, when the graft erodes into the bowel, but the graft or anastomosis does not rupture. These patients present with chronic anemia, fever, and occult blood positive stool due to ulceration of the bowel.

Blood culture and graft culture may ultimately be positive for the infectious pathogen, but should not delay treatment. Successful treatment of graft infection includes systemic antibiotics and frequently, muscle coverage or graft excision.

References:

Brady CM, Chaikof EL. Management of infected vascular grafts. In: Cameron JL, Cameron AM, eds. *Current Surgical Therapy.* 10th ed. Philadelphia, PA: Mosby; 2011: 857–861.

Clagett GP. Vascular infections.In: Mulholland MW, Lillemoe KD, Doherty GM, Maier RV, Upchurch GR, eds. *Greenfield's Surgery: Scientific Principles & Practice.* 5th ed. Philadelphia, PA: Lippincott Williams and Wilkins; 2011.

Moneta GL, Porter JM. Arterial substitutes. In: Sabiston DC, Lyerly HK, eds. *Textbook of Surgery.* 15th ed. Philadelphia, PA: W.B. Saunders; 1997:1634–1635.

Montreuil B, Morrison L, Rosenberg L, et al. Vascular and peritoneal access. In: Souba WW, Fink MP, Jurkovich GJ, Kaiser LR, Pearce WH, Pemberton JH, Soper NJ, eds. *ACS Surgery: Principles and Practice.* 4th ed. New York, NY: WebMD; 2004:835.

۰۲۱-۶۶۱۹۸۵۱۴ www.myuptodate.com دریافت آخرین نسخه آپتودیت آفلاین

1C07

Key word: Classification of Endoleaks

Author: Babak J. Orandi, MD, MSc
Editor: Christopher J. Abularrage, MD

A 64-year-old man undergoes endovascular repair of a 5.9-cm infrarenal abdominal aortic aneurysm with bilateral iliac artery involvement. The patient does well postprocedurally and is discharged home 4 days later. A 6-month follow-up CT reveals contrast extravasation into the aneurysm sac at the proximal aspect of the aneurysm and an interval increase in the aneurysm size to 6.3 cm. What type of endoleak is described, and what is the best management?

(A) Type I endoleak; observation

(B) Type I endoleak; urgent endovascular repair

(C) Type II endoleak; urgent open surgical repair

(D) Type III endoleak; observation

(E) Type III endoleak; urgent endovascular repair

Answer: **(B)** Type I endoleak; urgent endovascular repair

Rationale:

Endovascular aortic aneurysm repair (EVAR) has the advantage of sparing patients a major operation; however, the trade-off is that patients require closer surveillance and more frequent interventions. This is particularly true for patients who develop endoleak, which is defined as the persistent pressurization of the aneurysm sac that permits continued aneurysm growth and potential rupture. Endoleaks can be classified as type I to type IV and endotension, which is sometimes referred to as a type V endoleak. Type I endoleak results from an incomplete seal between the stent graft and the native vessel. Type IA is a proximal leak, while a type IB is a distal leak. Type II endoleak occurs when there is persistent flow through the aneurysm sac via branch vessels, most commonly from the inferior mesenteric artery or lumbar arteries. A separation between stent graft components that permits blood flow into the aneurysm sac is a type III endoleak. Type IV endoleak occurs when blood is able to flow through porous graft material. This type of endoleak is rarely seen with more modern stent graft devices. Endotension refers to persistent pressurization of the aneurysm sac in the absence of radiographic evidence of types I to IV endoleak.

The endoleak classification schema helps determine treatment and urgency. The type of endoleak is typically confirmed by digital subtraction angiography as this allows real time assessment of flow. Types I and III, because of the risk of aneurysm growth and rupture, typically require urgent intervention. Balloon angioplasty may help approximate the graft to the vessel wall in the case of type I endoleak. If not, a Palmaz balloon expandable stent can be placed proximally to complete the seal. Alternatively, an extension aortic cuff (type IA) or iliac extension limb (type IB) may be deployed. Type III endoleaks are repaired by deploying a stent within the current stent or utilizing a cuff if the endoleak is in the distal aspect of the stent graft. The management of type II endoleak is controversial—some have advocated a conservative approach because of the low risk of aneurysm rupture. More recent research suggests that persistent type II endoleaks (>6 months) in the presence of aneurysm sac expansion require treatment via embolization of the offending vessels or, rarely, via open ligation. Type IV endoleak typically resolves with the discontinuation of anticoagulation and is rare in the modern era of EVAR. Endotension is rarely encountered and is typically treated with either open surgical repair or deploying another stent graft into the current one if symptoms of aneurysm growth are present. For all types of endoleak, continued aneurysm growth or symptoms, such as back or abdominal pain, mandate treatment. In this question, the patient has type IA endoleak with aneurysm growth, mandating urgent intervention.

Endoleak Classification Scheme

Endoleak Type	Description of Source
I	Ineffective seal at fixation zones
A	Proximal end
B	Distal end
II	Branch vessels (e.g., intercostals, bronchials)
A	Single vessel (simple)
B	Two or more vessels creating a circuit (complex)
III	Structural endograft failure
A	Junctional separation (of modular components)
B	Endograft fracture or holes
IV	Through the stent grafts caused by porosity (<30 days)
V	Endotension (growth of aneurysm sac despite no identifiable source)

Reprinted with permission from: Lee TC, Hughes C. Complications of thoracic endovascular stent grafts. In: Franco KL, Thourani VH, eds. *Cardiothoracic Surgery Review.* Philadelphia, PA: Lippincott Williams & Wilkins; 2012:584.

References:

Abularrage CJ, Patel VI, Conrad MF, et al. Improved results using Onyx glue for the treatment of persistent type 2 endoleak after endovascular aneurysm repair. *J Vasc Surg.* 2012;56(3):630–636.

Buth J, Harris PL, van Marrewijk C, et al. The significance and management of different types of endoleaks. *Semin Vasc Surg.* 2003;16(2):95–102.

Chuter TAM, Schneider D. Abdominal aortic aneurysms–endovascular treatment. In: Cronenwett JL, Johnston KW, eds. *Rutherford's Vascular Surgery.* 7th ed. Philadelphia, PA: Saunders; 2010:1972–1993.

Heikkinen MA, Arko FR, Zarins CK. What is the significance of endoleaks and endotension? *Surg Clin North Am.* 2004;84(5):1337–1352.

Liaw JV, Clark M, Gibbs R, et al. Update: Complications and management of infrarenal EVAR. *Eur J Radiol.* 2009; 71(3):541–551.

۰۲۱-۶۶۱۹۸۵۱۴ www.myuptodate.com دریافت آخرین نسخه آپتودیت آفلاین

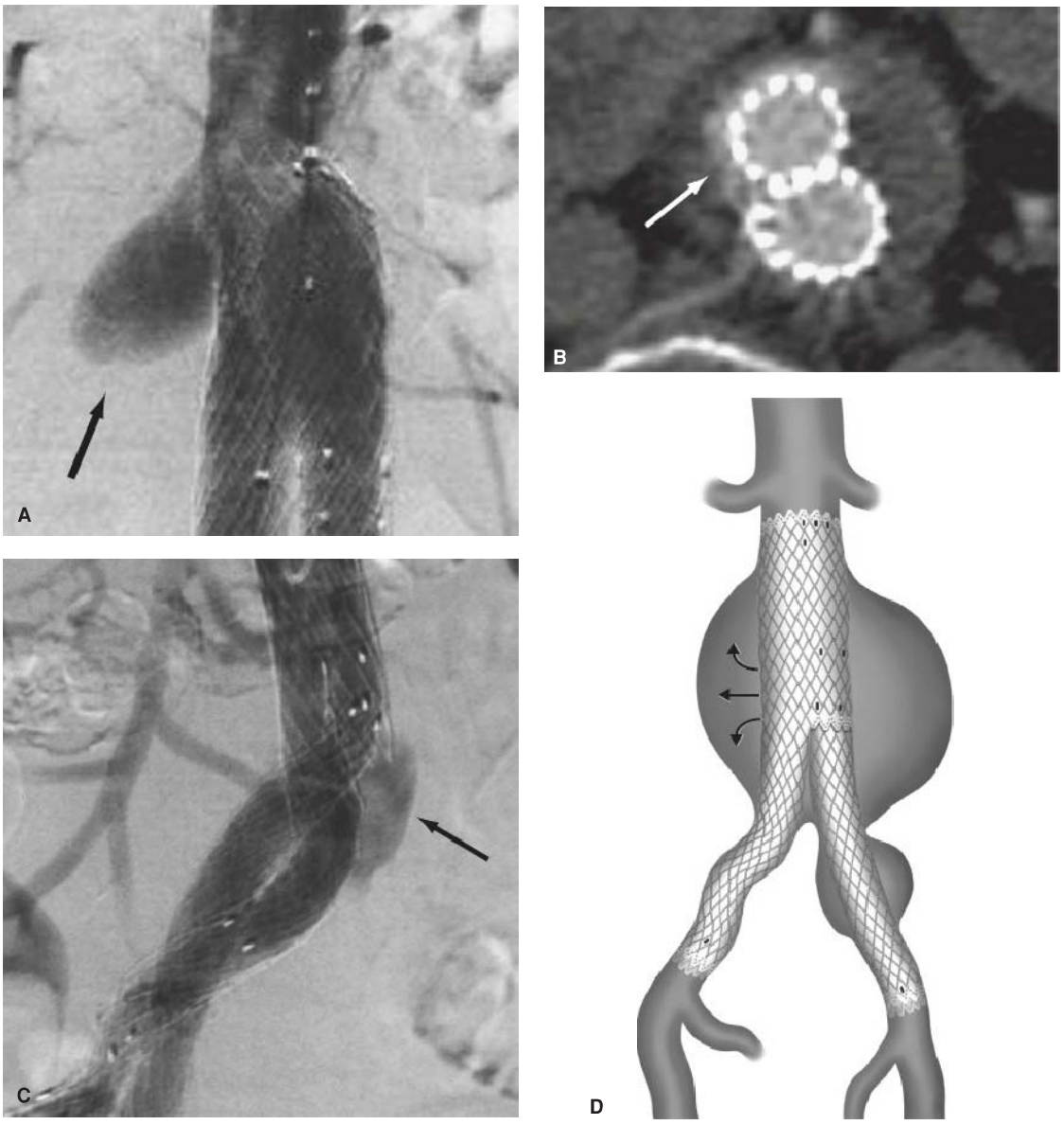

The various endoleaks are demonstrated. **A:** Type 1 leaks originate at either the proximal or distal attachment sites. Note the large blush of contrast outside of the graft lumen at the proximal fixation site. **B:** Type 2 leaks are from the collateral circulation originating in the lumbar or inferior mesenteric arteries. Note the contrast-filled limbs of the graft and the rim of contrast outside the limbs of the graft, but within the lumen of the aorta. The other computed tomography images demonstrated that the leak originated from the inferior mesenteric artery. **C:** Type 3 leaks are caused by fabric tears or problems at the graft interfaces of the modular devices. Note the contrast blush outside of the lumen of the graft at the modular interface. **D:** Type 4 leaks are usually transient (<24 hours) trans-graft extravasations and can result from the porosity of the graft and needle holes. Reprinted with permission from: Huber TS, Lee WA. Abdominal aortic aneurysms. In: Mulholland MW, Lillemoe KD, Doherty GM, Maier RV, Upchurch GR, eds. *Greenfield's Surgery: Scientific Principles & Practice*. 5th ed. Philadelphia, PA: Lippincott Williams & Wilkins; 2011:1743.

۰۲۱-۶۶۱۹۸۵۱۴ www.myuptodate.com دریافت آخرین نسخه آپتودیت آفلاین

1C08

Key word: Etiology of Late Death after Heart Transplant

Author: Robert A. Meguid, MD, MPH
Editor: William A. Baumgartner, MD

What is the most common cause of late death after heart transplant?

(A) Acute graft rejection

(B) Accelerated atherosclerosis

(C) Cytomegalovirus (CMV) infection

(D) Fungal infection

(E) Ventilator-associated pneumonia

Answer: (B) Accelerated atherosclerosis

Rationale:

While acute graft rejection is the most common cause of death within the first year after cardiac transplantation, accelerated atherosclerosis leading to myocardial infarction is the most common cause of death thereafter.

CMV infection is associated with accelerated atherosclerosis, but itself is not the cause of death. Fungal infections occur in 7% to 15% of cardiac transplantations, characteristically within the first few months. The death rate from ventilator-associated pneumonia early after transplant is approximately 20% to 30% in ventilated patients.

References:

Hruban RH, Gao SZ, Baldwin WM, et al. Accelerated graft arteriosclerosis. In: Baumgartner WA, Reitz BA, Kasper EK, Theodore J, eds. *Heart and Lung Transplantation.* Philadelphia, PA: WB Saunders; 2001:387.

Munoz P, Rodriguez C, Bouza E. Heart transplant patients. In: Cohen J, Powderly WG, eds. *Infectious Diseases.* 2nd ed, online. Edinburgh: Elsevier; 2004. Accessed October 16, 2006.

Willerson JT. Acute myocardial infarction. In: Wyngaarden JB, Smith LH, eds. *Cecil Textbook of Medicine.* 18th ed. Philadelphia, PA: W.B. Saunders; 1988:330.

1C09

Key word: Adjuncts to Improve Vascular Graft Patency

Author: Susanna M. Nazarian, MD, PhD
Editor: Julie A. Freischlag, MD

A 72-year-old man is seen in clinic preoperatively to prepare for his upcoming femoral–tibial artery bypass for vascular insufficiency. The duplex scan demonstrates poor candidates for venous conduits, so the use of synthetic graft is anticipated. The long-term outcome for this patient could be improved by:

(A) Clopidogrel use for the first 3 months after surgery

(B) Daily use of 81-mg aspirin indefinitely

(C) Low-molecular-weight heparin injections for the first 6 weeks after surgery

(D) The use of support stockings

(E) Warfarin use with a goal International Normalization Ratio (INR) of 1.5

Answer: (B) Daily use of 81-mg aspirin indefinitely

Rationale:

Aspirin has demonstrated efficacy in maintaining graft patency following infrainguinal prosthetic bypass in multiple randomized clinical trials. In addition, statins may enhance graft patency following bypass surgery. Anticoagulation with warfarin should be reserved for patients at high risk for clotting, while the use of clopidogrel after prosthetic grafting remains undefined. Preliminary data suggest that aspirin in combination with clopidogrel may provide superior patency results, though further studies are necessary.

The multicenter, prospective Dutch Bypass Oral Anticoagulants or Aspirin (BOA) trial randomized 2,690 lower-extremity bypass patients to anticoagulation to INR 3 to 4.5 or 80-mg aspirin daily. In subgroup analysis for prosthetic grafts, patients receiving aspirin had improved graft patency compared with patients receiving anticoagulation. Conversely, vein graft patients fared better in the anticoagulation arm. In combined analysis for both prosthetic and vein, the patency rates were not significantly different for the two therapies. A Veterans Affairs Cooperative trial compared aspirin to aspirin and warfarin (goal INR 1.4 to 2.8), and found no improvement in those receiving the additional warfarin. Predictably, patients receiving warfarin in both studies suffered twice as many hemorrhagic events. Statins were found to decrease the risk of vein graft failure by 3.2 times in a retrospective study of 172 patients.

Five-year patency rates for infrainguinal bypass are inferior to those seen with aortofemoral bypasses, ranging from 15% for bypasses to the tibial artery using prosthetic graft, to 80% for bypasses to the popliteal artery using saphenous vein.

۰۲۱-۶۶۱۹۸۵۱۴ www.myuptodate.com دریافت آخرین نسخه آپتودیت آفلاین

References:
Dagher NN, Modrall JG. Pharmacotherapy before and after revascularization: Anticoagulation, antiplatelet agents, and statins. *Seminars in Vascular Surgery.* 2007;20:10–14.
Jackson AJ, Coats P, Orr DJ, et al. Pharmacotherapy to improve outcomes in infrainguinal bypass graft surgery: A review of current treatment strategies. *Annals of Vascular Surgery.* 2010;24:562–572.
Liem TK, Silver D. Role of antithrombotic drugs in maintaining graft patency. In: Ernst CB, Stanley JC, eds. *Current Therapy in Vascular Surgery.* 4th ed. St. Louis, MO: Mosby; 2001:546–548.

1C10

Key word: Characteristics of Thoracic Outlet Syndrome

Author: Robert A. Meguid, MD, MPH
Editor: Julie A. Freischlag, MD

A 28-year-old female professional violinist presents with headaches, neck pain, and hand clumsiness in her right hand. She also reports occasional numbness in the hand and right-sided chest pain. Which of the following is the likely cause of her symptoms?

(A) Carpal tunnel syndrome
(B) Coronary artery disease
(C) Osteoarthritis
(D) Paget–Schroetter syndrome
(E) Thoracic outlet syndrome (TOS)

Answer: (E) Thoracic outlet syndrome (TOS)

Rationale:
All of the symptoms described in the question are due to TOS. TOS is a constellation of neurovascular symptoms attributed to compression of the subclavian artery and vein, as well as the brachial plexus and sympathetic chain as they run over the first rib. The structures that may cause compression include the scalenus anticus and medius, pectoralis minor, and subclavius muscles, costocoracoid ligament, costoclavicular membrane, and cervical ribs.

Symptoms are attributed to nerve compression, arterial compression, sympathetic compression, and/or venous compression. Ninety-five percent of patients present with pain and paresthesias, of which most involve the ulnar nerve. Arterial compression may present as an incidental finding, and is associated with aneurysm proximal to the outlet compression. Alternately, patients may present with thrombosis and distal embolization, requiring surgical intervention. Sympathetic compression results in chest, neck, shoulder, arm, and hand pain. This often simulates angina pectoris, and is termed "pseudoangina." Additional potential symptoms resulting from sympathetic compression include Raynaud phenomenon and reflex sympathetic dystrophy. Venous compression (Paget–Schroetter Syndrome) is rare, results in effort thrombosis of the axillary subclavian vein, and occurs due to repetitive muscular activity or trauma.

Initial treatment of neurologic symptoms entails conservative measures including physical therapy. Failure of conservative treatment in the face of persisting symptoms necessitates surgery. Patients with neurologic complaints should undergo nerve conduction velocity (NCV) studies of the ulnar or median nerve across the thoracic outlet. Normal values are greater than 85 m/sec. Patients with values of 60 to 85 m/sec should respond to conservative therapy consisting of physical therapy; however, patients with NCVs less than 60 m/sec usually require surgery.

Arterial compression should be confirmed with ultrasonography and arteriography. Patients with aneurysms should

۰۲۱-۶۶۱۹۸۵۱۴ www.myuptodate.com دریافت آخرین نسخه آپتودیت آفلاین

undergo first or cervical rib resection, and thrombectomy and/or embolectomy, aneurysm repair, and dorsal sympathectomy as necessary.

In diagnosing sympathetic compression resulting in "pseudoangina," workup includes ruling out coronary artery disease via coronary angiogram. First rib resection for neurovascular symptoms usually resolves pain and other associated symptoms from sympathetic compression.

Treatment of venous compression is resection of the first rib, costoclavicular ligament medially, and the scalenus anticus muscle.

Reference:

Urschel H. Thoracic outlet syndrome. In: Yang SC, Cameron DE, eds. *Current Therapy in Thoracic and Cardiovascular Surgery.* Philadelphia, PA: Mosby; 2004:272–275.

1C11

Key word: Treatment of Occlusion of the Common Iliac Artery in Patients with COPD

Author: Robert A. Meguid, MD, MPH
Editor: Julie A. Freischlag, MD

An 82-year-old man with a history of severe chronic obstructive pulmonary disease (COPD) presents with claudication and is found to have occlusive disease localized to the left common iliac artery. Which of the following procedures is the most appropriate for management of this patient's disease?

(A) Anticoagulation using intravenous heparin

(B) Aortobifemoral artery bypass with synthetic graft

(C) Conservative treatment

(D) Femoral to femoral artery bypass with venous autograft

(E) Percutaneous transluminal angioplasty (PTA) under local anesthesia

Answer: (E) Percutaneous transluminal angioplasty (PTA) under local anesthesia

Rationale:

COPD is the fifth leading cause of death in the United States. It is associated with multiple perioperative complications, including failure to extubate postoperatively and prolonged postoperative mechanical ventilation.

Patients with iliac arterial occlusion present with absent pulses in the ipsilateral leg, as well as claudication-type pain. Diagnosis is confirmed with arteriography. While a bypass graft may be indicated in a healthier patient, it would be prudent to avoid an operation necessitating intubation in this scenario.

PTA under local anesthesia, with or without placement of a stent into the artery, would be a viable option here. The average success rate of PTA for treatment of total occlusion of the iliac artery is 65% with a 2- to 4-year patency rate of 75% to 100%.

Anticoagulation using intravenous heparin is inadequate definitive therapy for the occlusion of the iliac artery. Aortobifemoral artery bypass with PTFE graft would be indicated in a patient with occlusive disease of the abdominal aorta and/or bilateral iliac arteries. In this example, aortobifemoral artery bypass would not be the best option given the patient's comorbidities and the limited extent of disease.

References:

Henke PK, Wakefield TW. Hemostasis. In: Mulholland MW, Lillemoe KD, Doherty GM, Maier RV, Upchurch GR, eds. *Greenfield's Surgery: Scientific Principles & Practice.* 5th ed. Philadelphia, PA: Lippincott Williams and Wilkins; 2011.

Perez JA, Breisch AJ, Davis RD. Percutaneous transluminal angioplasty. In: Sabiston DC, Lyerly HK, eds. *Textbook of Surgery.* 15th ed. Philadelphia, PA: W.B. Saunders; 1997: 1703–1704.

Sabiston DC. Iliac arterial occlusion. In: Sabiston DC, Lyerly HK, eds. *Textbook of Surgery.* 15th ed. Philadelphia, PA: W.B. Saunders; 1997:1691.

۰۲۱-۶۶۱۹۸۵۱۴ www.myuptodate.com دریافت آخرین نسخه آپتودیت آفلاین

Sundaresan RS, Cooper JD. Lung transplantation. In: Sabiston DC, Lyerly HK, eds. *Textbook of Surgery.* 15th ed. Philadelphia, PA: W.B. Saunders; 1997:487.

Tucker SW, Pamoukian VN, Shortell CK. Chapter 65: Pulseless extremity and atheroembolism. In: Souba WW, Fink MP, Jurkovich GJ, Kaiser LR, Pearce WH, Pemberton JH, Soper NJ, eds. *ACS Surgery: Principles and Practice.* 6th ed. New York, NY: WebMD; 2007. http://www.acssurgery.com/acssurgery/institutional/instTableOfContent.action. Accessed October 14, 2011. Online Edition.

1C12

Key word: Treatment of Air Embolus

Author: Babak J. Orandi, MD, MSc
Editor: Christopher M. Sciortino, MD, PhD

A previously healthy 63-year-old woman began to complain of increased shortness of breath and chest pain while undergoing a root canal. After stopping the procedure, her symptoms resolved, and the oral surgeon resumed drilling. She began experiencing right facial pain and periorbital and neck swelling and subsequently complained of severe dyspnea. The patient's blood pressure then became undetectable. An emergent ECG showed nonspecific ST wave changes. Her pulse oximeter revealed an oxygen saturation of 89% to 90% throughout the procedure. *Immediate* action should be?

(A) Administration of intravenous fluids

(B) Bilateral tube thoracostomy placement

(C) Initiation of intravenous antibiotics

(D) Intravenous heparin therapy and/or thrombolytic therapy

(E) Position the patient in left lateral decubitus Trendelenburg position

Answer: **(E)** Position the patient in left lateral decubitus Trendelenburg position

Rationale:

Venous gas embolism (VGE) occurs when gas is introduced into the systemic venous circulation. This requires that the pressure gradient be such that air entry into the vessel is promoted over the egress of blood. A rare occurrence, VGE is typically iatrogenic, and while room air is the most common agent, any gas used medically can be causative (CO_2, NO_2, N_2, etc.).

Once in the venous circulation, the gas embolism travels to the right heart and enters the pulmonary arterial circulation, leading to impaired gas exchange, dysrhythmias, and pulmonary hypertension. The latter can cause acute right heart strain and subsequent heart failure. The classic scenario in which VGE occurs is in the placement or use of central venous or hemodialysis catheters, though it can be seen in a variety of other situations, including trauma, childbirth, and craniotomy. Auscultation may demonstrate the classic finding of a churning murmur ("mill-wheel" murmur) that is present throughout systole and diastole. Other signs include jugular venous distension, dyspnea, chest pain, mental status changes, and cardiovascular collapse.

In the instance of mental status changes or any neurologic signs, it must be assumed that the patient developed a paradoxical embolism, most commonly through a patent foramen ovale, with conversion of the VGE to an arterial gas embolism (AGE). While treatment for both involves prevention of further embolization, supportive care, resuscitation, intubation, 100% oxygen administration, and a possible role for hyperbaric oxygen therapy, the immediate positioning of the patient differs based on whether or not the embolism is venous or

۰۲۱-۶۶۱۹۸۵۱۴ www.myuptodate.com دریافت آخرین نسخه آپتودیت آفلاین

arterial in nature. VGE patients should immediately be placed in the left lateral decubitus and Trendelenburg (head down) position, with the goal of maintaining the embolus in the right ventricle and preventing it from traveling into the pulmonary circulation. Because arterial flow is stronger, this position will not prevent AGE from traveling distally to the heart and brain where it will disrupt flow. The Trendelenburg position may also exacerbate cerebral swelling associated with AGE to the brain; accordingly, the preferred position for AGE is in the flat supine position.

Isolated case reports and some animal experiments have suggested that for patients with VGE, evacuation of the embolism may be possible through a central venous catheter, though this is typically only done if the patient already has a catheter in place; rarely is the volume evacuated sufficient to achieve clinical improvement.

References:

Jorens PG, Van Marck E, Snoeckz A, et al. Nonthrombotic pulmonary embolism. *Eur Respir J.* 2009;34(2):452–474.

Muth CM, Shank ES. Gas embolism. *N Engl J Med.* 2000; 342(7):476–482.

Palmon SC, Moore LE, Lundberg J, et al. Venous air embolism: A review. *J Clin Anesth.* 1997;9:251–257.

1C13

Key word: Hypovolemic Shock

Author: Susanna M. Nazarian, MD, PhD
Editors: Duke E. Cameron, MD, and Christopher M. Sciortino, MD, PhD

A 24-year-old man presents to the emergency department after sustaining two gunshots through his chest. Which of the following would suggest that he has lost 30% to 40% of his blood volume?

(A) HR 90, normal blood pressure, normal or increased pulse pressure, urine output >30 mL/hr

(B) HR 110, normal blood pressure, increased pulse pressure, urine output >30 mL/hr

(C) HR 110, normal blood pressure, narrowed pulse pressure, urine output 20 to 30 mL/hr

(D) HR > 120, decreased blood pressure, very decreased pulse pressure, respiratory rate 30 to 40, urine output 5 to 15 mL/hr

(E) HR > 140, very decreased blood pressure, respiratory rate >35, negligible urine output

Answer: (D) HR >120, decreased blood pressure, very decreased pulse pressure, respiratory rate 30 to 40, urine output 5 to 15 mL/hr

Rationale:

This patient is in stage III hypovolemic shock, having lost 30% to 40% of his blood volume. A 70-kg man is estimated to have 4,900 mL of blood volume, or 70-mL blood per kg of ideal body weight. The hypovolemic shock classification helps guide treatment and prognostication.

- Stage I: ≤15% blood volume lost (≤750 mL), HR < 100, normal BP, normal pulse pressure, respiratory rate 14 to 20, urine output >30 mL/hr. Slightly anxious, pale, cool skin. **Treat with crystalloid.**
- Stage II: 15% to 30% blood volume lost (750 to 1,500 mL), HR > 100, normal blood pressure, narrowed pulse pressure, orthostasis, respiratory rate 20 to 30, urine output 20 to 30 mL/hr. Anxious. **Treat with crystalloid.**

Classification of Hemorrhagic Shock

	Class I	Class II	Class III	Class IV
Blood loss (mL)	Up to 750	750–1,500	1,500–2,000	>2,000
Blood loss (%)	Up to 15	15–30	30–40	40
Heart rate	<100	>100	>120	>140
Blood pressure	Normal	Normal	Decreased	Decreased
Pulse pressure	Normal	Decreased	Decreased	Decreased
Respiratory rate	14–20	20–30	30–40	>35
Urine output (mL/h)	>30	20–30	5–15	Minimal
Mental status	Normal	Mildly anxious	Anxious and confused	Confused and lethargic
Fluid replacement	Crystalloid	Crystalloid	Crystalloid and blood	Crystalloid and blood

Reprinted with permission from: Cuschieri J. Shock. In: Mulholland MW, Lillemoe KD, Doherty GM, Maier RV, Upchurch GR, eds. *Greenfield's Surgery: Scientific Principles & Practice.* 5th ed. Philadelphia, PA: Lippincott Williams & Wilkins; 2011:151.

۰۲۱-۶۶۱۹۸۵۱۴ www.myuptodate.com دریافت آخرین نسخه آپتودیت آفلاین

- Stage III: 30% to 40% blood volume lost (1,500 to 2,000 mL), HR > 120, decreased blood pressure, very decreased pulse pressure, respiratory rate 30 to 40, urine output 5 to 15 mL/hr. Anxious and confused. Decreased perfusion of vital organs such as kidneys, liver, and intestines. **Treat with blood and crystalloid.**
- Stage IV: >40% lost (>2,000 mL), HR >140, very decreased blood pressure, respiratory rate >35, negligible urine output. Confused and lethargic. Decreased perfusion of the brain and heart. **Treat with blood and crystalloid.**

Other types of shock include neurogenic, cardiogenic, and vasogenic shock. At the cellular level, shock is characterized by insufficient oxygen delivery (inadequate end-organ perfusion). An adrenergic response ensues within minutes, leading to tachycardia, vasoconstriction (i.e., decreased pulse pressure), and decreased renal blood flow (leading to low urine output).

Reference:

Cuschieri J. Shock. In: Mulholland MW, Lillemoe KD, Doherty GM, Maier RV, Upchurch GR, eds. *Greenfield's Surgery: Scientific Principles & Practice.* 5th ed. Philadelphia, PA: Lippincott Williams and Wilkins; 2011.

1C14

Key word: Treatment of Plantar Ulcer

Author: Susanna M. Nazarian, MD, PhD
Editors: James H. Black III, MD, FACS, and Christopher J. Abularrage, MD

A 67-year-old woman with long-standing diabetes presents to clinic stating that she has noticed some breakdown of the skin on the bottom of her right foot. Examination of the foot reveals a shallow ulcer overlying the area of the metatarsal heads with surrounding erythema. Radiograph of the foot reveals no bony involvement. How should you counsel her?

(A) She should be admitted to the hospital for aggressive wound care

(B) She should clean the wound with warm soaks and then put on clean socks

(C) She should obtain well-fitting shoes

(D) She will likely need a distal arterial bypass

(E) She will need a transmetatarsal amputation

Answer: (A) She should be admitted to the hospital for aggressive wound care

Rationale:

Diabetic patients suffer plantar ulcers on their feet, often overlying their metatarsal heads or the heel. They should be counseled on the importance of good foot care and daily foot checks, as diabetic neuropathy often prevents their sensing of minor skin breakdown or foot injury. Thus, a minor cut may blossom into a limb-threatening infection in a diabetic patient, particularly in the setting of persistent hyperglycemia.

Given the potential for massive wound complications requiring serial amputations, patients with diabetic ulcers should be treated aggressively. Patients with minor ulcers may undergo treatment in the outpatient setting. However, patients with severe ulcers or gross infection should be admitted to the hospital for wound management until the wound improves and the team is convinced the patient has adequate social structures for home wound care. This is especially true for diabetic patients in whom minor cellulitis can rapidly progress. Subsequently, the patient should obtain a well-fitting shoe for the other foot, to eliminate pressure over the metatarsal heads. It is premature to suggest a transmetatarsal amputation, until the patient fails optimal conservative treatment. The patient may require a distal bypass if there is poor perfusion identified on noninvasive imaging.

During the hospital admission, necrotic tissue should be removed, and topical products (enzymatic debridement agents, antibiotics, colloids, gels) may prove helpful. The wound should be kept moist, and substances toxic to tissue such as povidone iodine and hydrogen peroxide should be avoided.

Reference:

Kerstein MD. Cutaneous ulcers in the ischemic diabetic foot. In: Ernst CB, Stanley JC, eds. *Current Therapy in Vascular Surgery.* 4th ed. St. Louis, MO: Mosby; 2001:552–554.

۰۲۱-۶۶۱۹۸۵۱۴ www.myuptodate.com دریافت آخرین نسخه آپتودیت آفلاین

1C15

Key word: Treatment of Superior Vena Cava Syndrome

Author: Susanna M. Nazarian, MD, PhD
Editors: G. Melville Williams, MD, FACS, and Christopher J. Abularrage, MD

A 30-year-old man presents with facial swelling, engorged neck veins, and complaints of dizziness for the prior 3 months. Two years previously, he was diagnosed with unresectable malignant thymoma, but completed only two rounds of radiotherapy. How should you proceed with treatment?

(A) Balloon angioplasty and endovascular stenting of the superior vena cava (SVC)

(B) Exploratory thoracotomy

(C) Extra-anatomic bypass from the internal jugular to the femoral vein

(D) Inpatient heparinization until therapeutic on warfarin

(E) Internal jugular to right atrial bypass

Answer: **(A)** Balloon angioplasty and endovascular stenting of the superior vena cava (SVC)

Rationale:

SVC syndrome results from the occlusion of the SVC, usually by a neoplastic process. The most common causes include bronchogenic carcinoma, metastatic pulmonary processes, and mediastinal malignancy. In fact, 3.8% of lung cancer patients have SVC obstruction at the time of diagnosis. Benign disease accounts for only 22% of cases, with half of these originating from mediastinal fibrosis. However, the increased use of indwelling central venous catheters and cardiac pacemakers over the past decade has increased the incidence of benign SVC obstruction.

Patients with SVC syndrome present with head and neck fullness, dyspnea on exertion, orthopnea, and occasionally dizziness. Engorged collateral veins on the chest wall may be seen on examination. Patients may also present with rapidly developing emergencies including airway compromise and hemodynamic instability.

Treatment of SVC syndrome remains controversial and depends in part on the underlying cause of the occlusion. Patients with malignant disease are best suited for the minimally invasive approach of balloon angioplasty and endovascular stenting. This approach is particularly appropriate in patients whose malignant disease is unresponsive to chemotherapy or radiation. The endovascular approach is successful in 90% to 100% of patients, with short-term patency rates of up to 85% at 1 year. Endovascular treatment also has the benefit of a minimally invasive approach in a patient population that frequently has limited life expectancy.

However, endovascular stenting may require revisions to maintain stent patency over a longer time frame, such as encountered in a benign setting. For instance, an article from 2003 from the Mayo Clinic reported secondary interventions for all three patients who underwent primary endovascular treatment for SVC syndrome, with mean duration of follow-up for patency of 2 years.

Surgery is best suited for those with benign disease, and has excellent long-term results. A recent study from the Mayo Clinic reported 90% long-term patency rates in 23 vein grafts over mean follow-up of 5.3 years, similar to the 88% patency rate at mean follow-up of 10.9 years reported previously. Solutions for alternative conduits for blood flow between the internal jugular and right atrium include using conduits such as polytetrafluoroethylene (PTFE), superficial femoral vein or spiraled saphenous vein grafts (to increase graft length). Extra-anatomic, prosthestic, subcutaneous bypasses between the internal jugular and femoral vein have been reported, but are associated with poor primary patency due to the length of the bypass.

Patients may be treated with radiation therapy to the mediastinum to shrink the tumor, including in the emergency setting. Chemotherapy for chemo-responsive malignancies such as small-cell lung cancer or lymphoma remains another possibility.

Complications unique to the treatment of SVC (or IVC) occlusion include large fluid shifts and increased venous return in the hours following definitive treatment.

References:

Baltayiannis N, Magoulas D, Anagnostopoulos D, et al. Percutaneous stent placement in malignant cases of superior vena cava syndrome. *J BUON.* 2005;10(3):377–380.

Dhaliwal RS, Das D, Luthra S, et al. Management of superior vena cava syndrome by internal jugular to femoral vein bypass. *Ann Thorac Surg.* 2006;82(1):310–312.

Kalra M, Gloviczki P, Andrews JC, et al. Open surgical and endovascular treatment of superior vena cava syndrome caused by nonmalignant disease. *J Vasc Surg.* 2003;38(2):215–223.

Kwok Y, DeYoung C, Garofalo M, et al. Radiation oncology emergencies. *Hematol Oncol Clin North Am.* 2006;20(2):505–522.

Williams DM. Endovascular treatment of chronic venous occlusion. In: Ernst CB, Stanley JC, eds. *Current Therapy in Vascular Surgery.* 4th ed. St. Louis, MO: Mosby; 2001:851–852.

۰۲۱-۶۶۱۹۸۵۱۴ www.myuptodate.com دریافت آخرین نسخه آپتودیت آفلاین

1C16

Key word: Treatment of Pulmonary Contusion

Author: Robert A. Meguid, MD, MPH
Editor: Pamela A. Lipsett, MD, MHPE, FACS, FCCM

Following a motor vehicle collision, the 34-year-old male nonbelted driver complains of mild shortness of breath and has blood-tinged sputum. Admission chest radiograph appears normal except for a right fifth rib fracture and a left sixth rib fracture. Repeat chest radiograph after 4 hours reveals new onset of a patchy opacity in the middle of the lung fields bilaterally. Oxygen saturation is maintained at 94% on 2-L nasal cannula supplementation. Appropriate treatment includes which of the following?

(A) Immediate intubation and full ventilatory support

(B) Initiation of broad-spectrum antibiotics

(C) Placement of bilateral chest tubes

(D) Termination of intravenous fluid resuscitation and administration of diuretics

(E) Use of incentive spirometry

Answer: **(E)** Use of incentive spirometry

Rationale:

Pulmonary contusion usually results from blunt trauma or low-velocity penetrating trauma sustained to the chest. Patients may present with dyspnea and hemoptysis. Characteristic signs on chest radiograph, usually appearing several hours after injury, are patchy opacities in the lung fields. Pulmonary contusions are often associated with rib fractures and even a flail chest. The use of optimal analgesia and aggressive chest physiotherapy should be applied to minimize the likelihood of respiratory failure. Epidural catheter is the preferred mode of analgesia delivery in severe flail chest injury. Paravertebral analgesia may be equivalent to epidural analgesia and may be appropriate in certain situations when epidural analgesia is contraindicated.

Treatment of pulmonary contusion includes intubation and ventilatory support for those with severe injuries and evidence of hypoxia (PaO_2 < 60 mm Hg). A trial of mask continuous positive airway pressure should be considered in alert patients with marginal respiratory status. Otherwise, management of pulmonary contusion is based on aggressive pulmonary toilet, including use of incentive spirometry and ambulation, and surveillance for development of pneumonia, which usually occurs several days after injury.

In the absence of pleural effusions or hemo- or pneumothorax, chest tube insertion is not indicated. While over-resuscitation with fluids should be avoided due to exacerbation of pulmonary edema, avoidance of fluid resuscitation and administration of diuretics is not indicated and may prove deleterious. Prophylactic treatment with antibiotics is not indicated.

References:

Simon B, Ebert J, Bokhari F, et al. Eastern association for the surgery of trauma. Management of pulmonary contusion and flail chest: An eastern association for the surgery of trauma practice management guideline. *J Trauma Acute Care Surg.* 2012;73(5 suppl 4):S351–S361.

Wanek SM, Mayberry JC, Trunkey DD. Flail chest and pulmonary contusion. In: Yang SC, Cameron DE, eds. *Current Therapy in Thoracic and Cardiovascular Surgery.* Philadelphia, PA: Mosby; 2004:50–56.

۰۲۱-۶۶۱۹۸۵۱۴ www.myuptodate.com دریافت آخرین نسخه آپتودیت آفلاین

1C17

Key word: Characteristics of Rest Pain

Author: Benjamin S. Brooke, MD, PhD
Editors: G. Melville Williams, MD, FACS, and Christopher J. Abularrage, MD

A 78-year-old female with a history of transient ischemic attacks and coronary disease presents to the emergency department complaining of pain in her distal right lower extremity. She describes the pain as a dull, aching sensation in her toes that is worse at night when she lies flat in bed, and therefore she often sleeps in a chair. A careful inspection of the extremity does not reveal any signs of necrosis or gangrene. The forefoot is purple-red when the foot is down while seated and very white when the foot is elevated. To assess the severity of this patient's disease, an ankle–brachial index (ABI) is performed at the bedside. What is the most likely ABI value range to be found in this patient?

(A) Between 0.1 and 0.2
(B) Between 0.3 and 0.4
(C) Between 0.5 and 0.6
(D) Between 0.6 and 0.7
(E) Between 0.7 and 0.9

Answer: (B) Between 0.3 and 0.4

Rationale:
Rest pain represents the progression of ischemic disease in the lower extremity. The pain occurs at rest, is localized to the lower leg or foot, is made worse by elevation (upright), and is relieved by the dependent (recumbent) position. Rest pain may start as a dull, aching sensation in the toes and forefoot and progress to a severe burning pain at night when the patient is lying supine. Patients may describe hanging a foot or limb over the bed or sleeping in a chair to obtain relief. The purple-red skin color reflects vasodilation of the superficial vascular bed. Blanching on elevation indicates that the circulation cannot be sustained against gravity. This sign, called dependent rubor and pallor of elevation, is a strong indicator of severe vascular disease.

The ABI is the most common and reliable bedside procedure to confirm the presence of arterial disease. It is a quick, noninvasive, cost-effective, and readily available means to establish or refute the diagnosis of peripheral arterial insufficiency and has been validated by numerous studies. This test is performed by placing an appropriately sized pneumatic cuff around the limb and inflating it to a level above the resting systolic blood pressure. While the cuff is being slowly deflated, a handheld Doppler probe positioned over the artery a few inches distal to the cuff is used to detect the systolic pressure at which Korotkoff sounds returns. In the upper extremity, the brachial artery is used for Doppler signal detection, whereas either the dorsalis pedis (DP) or posterior tibial (PT) signals can be detected at the ankle for comparison. The ABI is then calculated by dividing the higher ankle systolic pressure (DP or PT) by the higher of two arm systolic pressures.

The interpretation of ABI values must always be made taking the entire clinical scenario into consideration. Patients with diabetes mellitus and renal insufficiency are known to have falsely elevated ABIs due to calcification of the arteries and their resulting inability to be compressed by the blood pressure cuff. However, a standardized scale can usually be used to categorize the severity of vascular insufficiency. A value between 1.0 and 1.2 is expected in a normal individual, while a threshold value of 0.90 and less is used to indicate abnormal vascular perfusion and define the presence of peripheral arterial disease. Mild arterial occlusive disease is typically characterized by ABI values between 0.7 and 0.9, moderate disease by values between 0.4 and 0.7, and severe disease by values less than 0.4. Classic rest pain is normally associated with ABI values less than 0.4 to 0.5, while gangrene is usually found with values less than 0.2. Because numerical values can occasionally be inflated by heavily calcified vessels, the arterial waveform pattern should also be considered.

Reference:
Khan NA, Rahim SA, Anand SS, et al. Does the clinical examination predict lower extremity peripheral arterial disease? *JAMA.* 2006:295;536–546.

۰۲۱-۶۶۱۹۸۵۱۴ www.myuptodate.com دریافت آخرین نسخه آپتودیت آفلاین

1C18

Key word: Preferred Route for Central Venous Access

Author: Jacqueline Garonzik-Wang, MD, PhD
Editor: Julie A. Freischlag, MD

A 45-year-old man is admitted to the intensive care unit with presumed sepsis. After the patient is stabilized, the decision is made to place a central venous catheter. The patient's platelets, INR, and PTT ratio are within normal limits. He is breathing at a rate of 20 on room air with an oxygen saturation of 99%. He has no other significant past medical history. The preferred location for central venous access is:

(A) Left femoral vein
(B) Left internal jugular vein
(C) Left subclavian vein
(D) Right femoral vein
(E) Right internal jugular vein

Answer: (C) Left subclavian vein

Rationale:
There are multiple risks and complications associated with central venous catheterization, and some access sites are better suited to certain patients. A subclavian approach is preferred in any patient who will likely require central catheterization for greater than 3 days as it has the lowest infection rate. The subclavian approach is contraindicated in any patient with coagulopathy or severe thrombocytopenia, as the vein is not easily compressible in this location. Instead, the internal jugular vein using ultrasound localization is the preferred site for the hypocoagulable patient. Subclavian access is also contraindicated if pneumothorax would represent a devastating and unacceptable complication (i.e., in patients with severe hypoxia or who require a large amount of positive-pressure ventilation). The femoral approach is associated with a significantly higher infection rate and should only be utilized if other approaches are contraindicated, if attempts at subclavian and jugular catheterization have failed, or in emergent settings.

Reference:
Timsit JF. What is the best site for central venous catheter insertion in critically ill patients? *Crit Care.* 2003;7(6):397–399.

1C19

Key word: Treatment of Cardiac Tamponade

Author: Justin B. Maxhimer, MD
Editor: William A. Baumgartner, MD

A 19-year-old male is brought to a rural emergency department after experiencing penetrating trauma to the left chest by farm equipment. His initial set of vital signs after 2 L of fluid are heart rate 107 beats per minute and blood pressure 80/50 mm Hg. He is able to tell you what happened, but you are not able to hear heart sounds and breath sounds are distant on the left. What should be your next step?

(A) Chest x-ray while preparing a thoracostomy set
(B) Emergency thoracotomy in the operating room
(C) Emergent pericardiocentesis
(D) Intubation
(E) Large volume resuscitation

Answer: (C) Emergent pericardiocentesis

Rationale:
Immediate recognition of cardiac tamponade is vital to improving the chance of survival. Tamponade can present with Beck triad (jugular venous distention, hypotension, and muffled heart sounds) or hypotension and tachycardia without elevated jugular venous distension if associated hemorrhage is outside the pericardial sac. Pulsus paradoxus can also be seen. Other physical examination findings can include cyanosis and varying degrees of consciousness. Both echocardiogram and chest x-ray can help aid in the diagnosis, but may cause an unwarranted delay in treatment if they are not immediately available. In most urban centers, a focused ultrasound examination would reveal the presence or absence of pericardial fluid. Pericardiocentesis is the treatment of choice, and the traditional approach is the subxiphoid technique. This technique avoids injury to the coronary arteries. However, thoracotomy and pericardiotomy may be required in the emergency department if the patient has rapid deterioration or cardiac arrest.

Reference:
Bastian A, Meissner A, Lins M, et al. Pericardiocentesis: Differential aspects of a common procedure. *Intensive Care Med.* 2000; 26(5):572–576.

۰۲۱-۶۶۱۹۸۵۱۴ www.myuptodate.com دریافت آخرین نسخه آپتودیت آفلاین

1C20

Key word: Indications for Thoracotomy after Gunshot Wound to the Chest

Author: Matthew J. Weiss, MD
Editors: Edward E. Cornwell III, MD, FACS, WACS, FCCM, and Albert Chi, MD

A 23-year-old man presents to the emergency department with a single gunshot wound to the left chest. The patient is able to phonate but has severely decreased breath sounds on the left side, and therefore a 36-French thoracostomy tube is placed. Which of the following is an indication for operative management?

(A) 1,000 mL of sanguineous chest tube output upon insertion

(B) 300 mL of sanguineous chest tube output over the next 3 hours

(C) A small air leak in the chest tube that remains for 24 hours

(D) Hemodynamic instability on presentation to the emergency department

(E) The presence of gastric contents in the chest tube effluent

Answer: (E) The presence of gastric contents in the chest tube effluent

Rationale:
Hemorrhage is one indication for operative management of a penetrating thoracic injury. Although the diagnosis of hemorrhage can be subjective, it is commonly agreed that ≥1,500 mL of blood upon chest tube insertion, or ongoing bleeding of ≥200 mL/hr for 4 hours is an indication for thoracotomy. In addition, a continuous air leak with inability to expand the lung completely and inadequate tidal volumes often requires surgical intervention, but the same is not true for small air leaks. The presence of gastric or esophageal contents in the chest tube collection systems indicates an esophageal disruption that requires surgical intervention. Hemodynamic instability on presentation to the emergency department is not an indication for thoracotomy by itself. If hemodynamic instability persists despite resuscitation efforts and chest tube insertion, thoracotomy may be indicated (i.e., for pericardial tamponade).

Reference:
Kincaid EH, Meredith JW. Injuries to the chest. In: Souba WW, ed. *ACS Surgery: Principles and Practice.* New York, NY: WebMD; 2005. Online Edition.

1C21

Key word: Diagnostic Test for "Tearing" Chest Pain

Author: Matthew J. Weiss, MD
Editors: James H. Black III, MD, FACS, and Christopher J. Abularrage, MD

A 65-year-old man with a history of severe atherosclerosis, hypertension, and bicuspid aortic valve presents to the emergency department in acute distress complaining of sudden onset of tearing chest pain directly below his sternum. The patient is hypertensive (196/110 mm Hg) and appears very anxious with an overwhelming sense of doom. Which of the following tests or interventions is *contraindicated* in this patient?

(A) Administration of antihypertensive medications

(B) Computed tomography (CT) scan of the chest with contrast injection

(C) Echocardiogram

(D) Electrocardiogram

(E) Thrombolytic treatment of a myocardial infarction

Answer: (E) Thrombolytic treatment of a myocardial infarction

Rationale:
Aortic dissections typically present as sudden onset of excruciating, tearing chest pain. Risk factors for this condition include: Atherosclerosis, bicuspid aortic valves, hypertension, aortic coarctation, trauma, and a number of connective tissue disorders. In this patient, both his presenting symptoms and medical history require a workup for aortic dissection immediately and could be life saving (50% of patients die within 48 hours). The initial assessment should include a thorough history and physical examination followed by diagnostic tests to evaluate the aorta. An ECG can be performed easily in the emergency department setting and should be performed immediately.

Although as many as 20% of patients with aortic dissections will have a normal chest radiograph, this study is recommended in all patients presenting with acute chest pain. The chest radiograph can show widening of the mediastinum or displacement of aortic wall calcifications. CT of the chest with contrast injection is less expensive, faster, and safer than aortography and the sensitivity is 90%, although the specificity may be slightly lower than in magnetic resonance imaging or transesophageal echocardiography in the setting of ascending aortic aneurysm. An echocardiogram is advantageous because it is readily available and can detect coronary artery involvement, pericardial effusions, the degree of aortic regurgitation and left ventricular function, but this study may miss dissections in the distal aorta (sensitivity is 60% to 85%). CT is the test of choice due to its availability in the emergency department as well as its ability to assess the entire aorta. TEE may be more sensitive for ascending dissection, but it can be

۰۲۱-۶۶۱۹۸۵۱۴ www.myuptodate.com دریافت آخرین نسخه آپتودیت آفلاین

logistically challenging and time-consuming to get performed in the acute setting.

In a patient with hypertension and suspected aortic dissection, blood pressure control is crucial for prevention of rupture and should be administered immediately. Treatment of ascending aortic dissection is open cardiac surgery with ascending aortic replacement. Treatment of descending aortic dissection is antihypertensive therapy, except in cases of malperfusion where revascularization is indicated. If the presenting symptoms are mistaken for a myocardial infarction and any type of anticoagulation or thrombolytic therapy is given, this could precipitate a life-threatening bleed and could be catastrophic.

Reference:

Jacobs JE, Koo CW, White RD, et al. Acute chest pain—suspected aortic dissection. American college of radiology, ACR appropriateness criteria. Reston, VA; revised 2011. http://www.guidelines.gov/content.aspx?id=35134. Accessed March 8, 2013.

1C22

Key word: Treatment of Hepatic Artery Aneurysm

Author: Matthew J. Weiss, MD
Editor: Richard D. Schulick, MD, MBA, FACS

A 54-year-old man presents to his gastroenterologist complaining of 3 weeks of right upper quadrant pain, jaundice, and intermittent hemobilia. An ultrasound and duplex scan are performed, showing a 2.5-cm intrahepatic artery aneurysm in the left lobe of the liver. The best option for treatment is:

(A) Coil embolization of the aneurysm with radiologic guidance

(B) Left hepatectomy

(C) Open surgical ligation

(D) Resection of the aneurysm and reconstruction of the hepatic arterial tree

(E) Serial radiologic studies to evaluate for expansion over time

Answer: (A) Coil embolization of the aneurysm with radiologic guidance

Rationale:

Hepatic artery aneurysms are the second most common splanchnic aneurysm. They have a higher incidence in men and usually present with the triad of right upper quadrant pain, jaundice, and hemobilia. Treatment of hepatic artery aneurysm includes embolization, reconstructive surgery, or ligation depending on the size and location of the lesion. Generally, it is believed that aneurysms with a diameter greater than 2 cm should be treated because of the risk for rupture. Embolization is currently the accepted treatment for intrahepatic aneurysms. If embolization fails, hepatectomy may be indicated. For recipients of liver transplants who develop hepatic artery anuerysms, the possibility of a mycotic etiology requires open surgical intervention. Extrahepatic aneurysms proximal to the gastroduodenal artery can usually be treated with surgical ligation or embolization after the documentation of collateral flow via the gastroduodenal or right gastric artery.

Reference:

Schick C, Ritter RG, Balzar JO, et al. Hepatic artery aneurysm: Treatment options. *Eur Radiol.* 2004;14(1):157–159.

۰۲۱-۶۶۱۹۸۵۱۴ www.myuptodate.com دریافت آخرین نسخه آپتودیت آفلاین

1C23

Key word: Characteristics of Splenic Artery Aneurysms

Author: Robert A. Meguid, MD, MPH
Editor: Christopher J. Abularrage, MD

Which of the following is a characteristic of splenic artery aneurysms?

(A) Calcification of the aneurysm is thought to be associated with a decreased risk of rupture

(B) Elective surgery is indicated for aneurysms >1.5 cm in diameter

(C) Incidence is increased in female patients, multiparity, and portal hypertension

(D) Male to female ratio of 4:1

(E) Most patients present with symptoms consistent with splenic artery aneurysm rupture

Answer: (C) Incidence is increased in female patients, multiparity, and portal hypertension

Rationale:

Splenic artery aneurysms account for 60% of arterial aneurysms occurring in the splanchnic circulation. Their overall incidence is less than 1% in the general population; however, there is a predilection toward a four times greater occurrence in females than males. Patients with systemic arterial fibrodysplasia are more likely to develop splenic artery aneurysms. In addition, splenic artery aneurysms are found in 10% to 30% of patients with portal hypertension and splenomegaly. A large proportion of women with splenic artery aneurysms (40% to 45%) have a history of six or more pregnancies. Therefore, it is speculated that hormonal and hemodynamic effects of pregnancy contribute to splenic artery aneurysm development. Finally, chronic pancreatitis, history of blunt and penetrating abdominal trauma, and intravenous drug use are associated with development of splenic artery aneurysms, the latter association specifically relating to mycotic lesions.

Most splenic artery aneurysms are less than 2 cm in diameter when detected, and are found incidentally on angiography, computed tomography (CT), ultrasonography, and magnetic resonance imaging (MRI). Most patients with splenic artery aneurysms do not present with symptoms ascribed to the aneurysm. Less than 10% of patients with splenic artery aneurysms present with rupture, which is a surgical emergency.

Rupture of splenic artery aneurysms during pregnancy occurs most frequently in the third trimester, and mortality is in excess of 70% for the mother and fetus. However, mortality is less than 25% for operative intervention of ruptured splenic artery aneurysms in nonpregnant patients. Elective surgery for splenic artery aneurysms is typically indicated for aneurysms greater than 2 cm in diameter when the procedural risk is thought to be acceptably low.

Surgical treatment of splenic artery aneurysms entails resection with arterial reconstruction for proximal aneurysms. Alternatively, simple ligation–exclusion without arterial reconstruction can be performed for any aneurysm regardless of its position along the splenic artery. More recently, endovascular embolization has been performed with increasing success. Treatment includes embolization of normal artery both proximally and distally to the aneurysm, thus excluding it from flow. Rarely, splenic infarction or pancreatitis may occur after embolization of a distal splenic artery aneurysm.

Reference:

Rockman CB, Maldonado TS. Splanchnic artery aneurysms. In: Rutherford RB, ed. *Vascular Surgery.* 7th ed. Philadelphia, PA: Elsevier; 2010:2140–2155.

۰۲۱-۶۶۱۹۸۵۱۴ www.myuptodate.com دریافت آخرین نسخه آپتودیت آفلاین

1C24

Key word: Treatment of Tachyarrhythmias

Author: Susanna M. Nazarian, MD, PhD
Editor: William A. Baumgartner, MD

A 54-year-old man with atrial fibrillation refractory to multiple cardioversions and antiarrhythmic agents underwent attempted endocardial catheter ablation by a cardiac electrophysiologist. After unsuccessful catheter ablation, he is referred to a cardiac surgeon for evaluation. Which of the following is true regarding the modified Maze procedure?

(A) It is possible to perform the modified Maze procedure off cardiopulmonary bypass

(B) Sinus rhythm at 5 years is sustained in 80% to 90% of patients undergoing the modified Maze procedure

(C) Success in restoring sinus rhythm ranges from 40% to 50% with the modified Maze procedure

(D) The modified Maze procedure is not indicated in patients at risk for stroke

(E) The myocardium around the tricuspid valve is cut then sewn back together to interrupt aberrant circuits in the modified Maze procedure

Answer: (A) It is possible to perform the modified Maze procedure off cardiopulmonary bypass

Rationale:
The Maze procedure is a surgical alternative for patients with refractory atrial fibrillation, in which myocardium surrounding the pulmonary veins is electrically interrupted to disrupt the aberrant circuitry. Its name derives from the electrical path it establishes via a set of lesions with one site of entry (the sinoatrial node) into the left atrium and then one site of exit (the atrioventricular node). The Maze procedure has evolved since its introduction in the 1980s to include the use of cryolesions, radiofrequency, or microwave rather than surgical incisions. This allows surgeons to carry out the procedure using minimally invasive techniques, including off cardiopulmonary bypass. Success rates are approximately 80% in restoring sinus rhythm; sinus rhythm is sustained in 53% of patients at 5 years.

Atrial fibrillation afflicts 1% of the adult population, including 6% of those over age 65. The resulting health care and financial burden is impressive: 1.4 million outpatient visits and 227,000 hospitalizations, costing $6.6 billion annually. Atrial fibrillation results in loss of true atrial contraction, leading to impaired heart function and stasis of blood in the left atrium, putting the patient at increased risk for embolic events. In addition, the palpitations lead to patient discomfort and anxiety. Catheter ablation by cardiac electrophysiologists is a less-invasive and highly successful method of curing atrial fibrillation with similar results to the surgical approach.

References:
Beukema WP, Sie HT, Ramdat Misier AR, et al. Predictive factors of sustained sinus rhythm and recurrent atrial fibrillation after a radiofrequency modified Maze procedure. *Eur J Cardiothorac Surg.* 2008;34:771–775.

Cox JL. Surgical treatment of supraventricular tachyarrhythmias. In: Cohn LH, Edmunds LH, eds. *Cardiac Surgery in the Adult.* 2nd ed. New York, NY: McGraw-Hill; 2003: 1271–1286.

Cox JL, Ad N, Palazzo T, et al. Current status of the Maze procedure for the treatment of atrial fibrillation. *Semin Thorac Cardiovasc Surg.* 2000;12(1):15–19.

Sundt T. The society of thoracic surgeons patient information Website, http://www.sts.org/doc/4511. Accessed November 4, 2006.

۰۲۱-۶۶۱۹۸۵۱۴ www.myuptodate.com دریافت آخرین نسخه آپتودیت آفلاین

1C25

Key word: Anatomy of Scalenus Anticus Muscle

Author: Robert A. Meguid, MD, MPH
Editor: Julie A. Freischlag, MD

Which of the following statements regarding the scalenus muscle is true?

(A) The anterior body inserts into the first rib posterior to the subclavian vein

(B) The middle body inserts into the first rib anterior to the brachial plexus

(C) The muscle originates from the transverse processes of C1 through C6

(D) The phrenic nerve crosses the anterior body medial to lateral

(E) The phrenic nerve crosses the medial body medial to lateral

Answer: (A) The anterior body inserts into the first rib posterior to the subclavian vein

Rationale:
The scalenus muscles, divided into anterior (anticus), middle (medius), and posterior bodies, originate from the transverse processes of vertebrae C2 through C6 bilaterally. The anterior body inserts onto the first rib between the subclavian vein (anteriorly) and the subclavian artery and brachial plexus (posteriorly). The middle body inserts onto the first rib posterior to the subclavian artery and brachial plexus. The posterior body inserts onto the second rib posterior to the subclavian artery and brachial plexus.

The phrenic nerve crosses the anterior body of the scalenus muscle from lateral to medial aspects, and the thoracic duct inserts into the junction of the jugular and subclavian veins anterior to the anterior body of the muscle on the left only. The scalenus muscles are innervated by branches off the cervical nerve roots.

Surgically, the anterior body of the scalenus muscle may be resected in treatment of thoracic outlet syndrome, as it may compress the local neurovascular structures if it becomes hypertrophic.

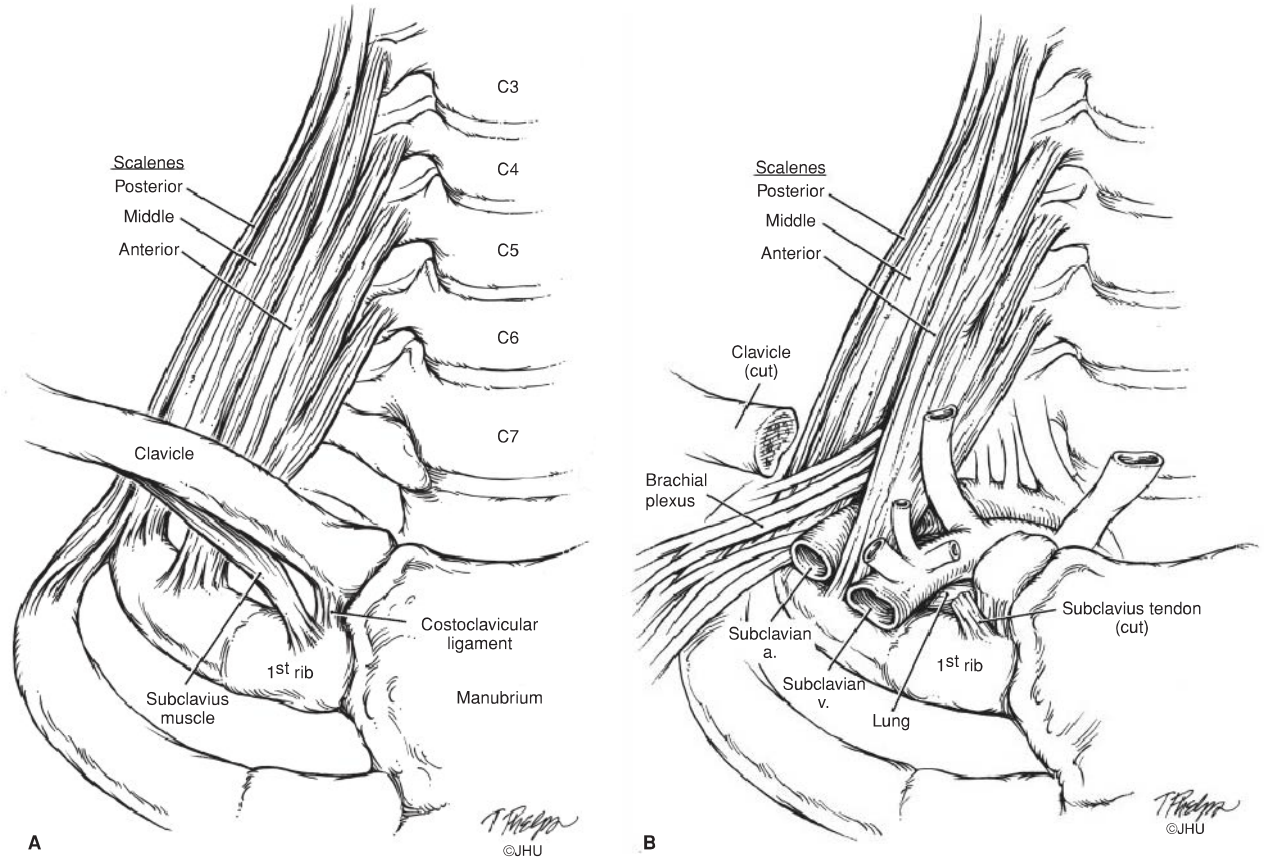

A: Musculoskeletal anatomy of the thoracic outlet. The thoracic outlet has been described as a triangle with the apex pointing toward the manubrium with the first rib and clavicle as its lower and upper limbs. The point where these two structures overlap serves as a fulcrum where dynamic changes occur during arm movement that can lead to injury of the nerves, arteries, and veins that run through the thoracic outlet. The origins and insertions of the anterior, middle, and posterior scalene muscles are also depicted here. **B:** Anatomy with clavicle removed. Moving medial to lateral, one first encounters the subclavian vein (v), which is usually positioned adjacent to the apex of the anatomic triangle where the first rib and clavicle come together to form a fibrocartilaginous joint with the manubrium. Lateral to the vein is the anterior scalene muscle. The subclavian artery (a) is then found deep, lateral, and cephalad to the anterior scalene and subclavian vein. The C4 to C6 (oriented superiorly) and C7 to T1 (oriented inferiorly) nerve roots of the brachial plexus are the next structures encountered. Posterior and lateral to the plexus, the middle scalene inserts on the first rib. **A, B** copyright Johns Hopkins University.

۰۲۱-۶۶۱۹۸۵۱۴ www.myuptodate.com دریافت آخرین نسخه آپتودیت آفلاین

References:
Netter FH. *Atlas of Human Anatomy.* 2nd ed. Plate 182. East Hanover, NJ: Novartis; 1997.
Reddy RM. Chest wall, pleura, mediastinum, and nonneoplastic lung disease. In: Mulholland MW, Lillemoe KD, Doherty GM, Maier RV, Upchurch GR, eds. *Greenfield's Surgery: Scientific Principles & Practice.* 5th ed. Philadelphia, PA: Lippincott Williams and Wilkins; 2011.

1C26

Key word: Determination of Cardiac Output and Systemic Vascular Resistance

Author: Christopher M. Sciortino, MD, PhD
Editor: Pamela A. Lipsett, MD, MHPE, FACS, FCCM

A 65-year-old man is in the surgical intensive care unit 24 hours after an emergent exploration and Hartmann procedure for perforated diverticulitis. He has remained hemodynamically labile and oliguric despite 14 L of volume resuscitation. The EKG is unremarkable except for sinus tachycardia. The patient has a known history of moderate tricuspid regurgitation. The patient is intubated and sedated and has the following hemodynamic and laboratory values: Temperature 37.9°C, pulse 104 beats per minute, blood pressure 90/45 mm Hg, SaO_2 100% on 50% FiO_2, MvO_2 58%, CVP 10 mm Hg, BSA 2 m^2, Hbg 10 g/dL. Based on this information, calculate the cardiac output (CO) and systemic vascular resistance (SVR).

(A) CO 2.5 L/min, SVR 1,600 $dyn \cdot s \cdot cm^{-5}$
(B) CO 5 L/min, SVR 800 $dyn \cdot s \cdot cm^{-5}$
(C) CO 7.5 L/min, SVR 200 $dyn \cdot s \cdot cm^{-5}$
(D) CO 10 L/min, SVR 400 $dyn \cdot s \cdot cm^{-5}$
(E) CO 10 L/min, SVR 800 $dyn \cdot s \cdot cm^{-5}$

Answer: (B) CO 5 L/min, SVR 800 $dyn \cdot s \cdot cm^{-5}$

Rationale:
Patients undergoing emergent operations can be difficult to manage in the postoperative setting, and an understanding of the CO and SVR can greatly aid in decisions for further management. Central venous catheter systems can be used to determine CO and SVR in the intensive care unit setting. However, there are situations where these catheter systems are inaccurate or contraindicated. As an example, tricuspid regurgitation can lead to inaccurate CO calculations using the thermodilution method. Other situations where the thermodilution method cannot be used to calculate CO are the inability to properly position pulmonary artery catheters (such as in the presence of a mechanical tricuspid valve), with continuous flow ventricular assist devices, or in the presence of a central venous thrombosis.

The Fick equation can also be utilized to determine the CO. The equation:

$$\text{Cardiac output} = \frac{\text{Oxygen consumption}}{\text{Hemoglobin-corrected arteriovenous oxygen content difference}}$$

$$\text{Cardiac output (L/min)} = \frac{135 \text{ mL } O_2/\text{min/M} \times \text{BSA}^2}{13.6 \times \text{Hgb} \times (SaO_2 - MvO_2)}$$

where BSA is body surface area, Hbg is hemoglobin, SaO_2 is arterial saturation, and MvO_2 is mixed venous saturation. Oxygen consumption can be measured using a metabolic cart or simply estimated, as is done above.

Mean arterial pressure (MAP) is [(2 × diastolic pressure) + systolic pressure]/3 in mm Hg.

۰۲۱-۶۶۱۹۸۵۱۴ www.myuptodate.com دریافت آخرین نسخه آپتودیت آفلاین

SVR can then be calculated by rearrangement of Ohm's Law (V = IR) as:

$$SVR = \frac{(MAP - CVP) \times 80 \text{ in dyn} \cdot s \cdot cm^5}{CO}$$

References:

Bojar RM. *Cardiovascular Management, Manual of Perioperative Care in Adult Cardiac Surgery.* 4th ed. Oxford: Blackwell Publishing; 2005.

Haft JW. Ischemic heart disease. In: Mulholland MW, Lillemoe KD, Doherty GM, Maier RV, Upchurch GR, eds. *Greenfield's Surgery: Scientific Principles & Practice.* 5th ed. Philadelphia, PA: Lippincott Williams and Wilkins; 2011.

Mavromatis K, Samady H. Cardiac catheterization, coronary angiography, and fractional flow reserve. In: Franco KL, Thourani VH, eds. *Cardiothoracic Surgery Review.* Philadelphia, PA: Lippincott Williams and Wilkins; 2012.

1C27

Key word: Treatment of Carotid Fibromuscular Dysplasia

Author: Robert A. Meguid, MD, MPH
Editors: G. Melville Williams, MD, FACS, and Christopher J. Abularrage, MD

A 67-year-old, otherwise healthy woman referred to you after arteriographic workup for multiple left hemispheric ischemic attacks reveals a "string of beads" appearance in the distal left internal carotid artery, proximal to the carotid canal at the base of the skull. There is no further evidence of narrowing at the bifurcation on the left side, or of any disease of the right internal carotid artery. What is the most appropriate management of this patient?

(A) Carotid artery interposition graft

(B) Chronic anticoagulation with regular observation

(C) High, internal carotid endarterectomy

(D) Open transluminal balloon dilation with stent placement

(E) Percutaneous transluminal balloon angioplasty

Answer: **(E)** Percutaneous transluminal balloon angioplasty

Rationale:

Fibromuscular dysplasia (FMD) is a rare, chronic vascular process involving the internal carotid, renal, external iliac, splenic, and hepatic arteries. Medial fibroplasia is usually the pathologic process that occurs in the carotid artery, seen as a "string of beads" on arteriography. This condition occurs in women more frequently than men, and occurs in the carotid arteries bilaterally in 40% to 85% of cases. Of note, lesions due to FMD often occur more distally than atherosclerotic plaques, and as a result, may be missed on routine carotid duplex ultrasound. Therefore, arteriography is considered the gold standard of diagnosis of carotid artery FMD.

Surgical intervention is indicated for patients if their carotid artery FMD has caused an ipsilateral cerebral ischemic event. Previously, open, graduated, rigid dilation of the affected internal carotid artery was the treatment of choice. However, as surgeons have gained greater confidence in percutaneous transluminal balloon angioplasty, this procedure has become an acceptable alternative to open surgery. This minimally invasive approach is usually not accompanied by stent placement due to the fact that lesion length tends to be long, and disease is frequently in a tortuous section of the artery or near the skull base. Endarterectomy is reserved for atherosclerotic plaques which occur in 20% of patients, and may be performed concurrent with dilation of FMD should the two types of lesion occur simultaneously.

Reference:

Schneider PA. Carotid artery disease: Fibromuscular dysplasia. In: Rutherford RB, ed. *Vascular Surgery.* 7th ed. Philadelphia, PA: Saunders Elsevier; 2010:1487–1496.

۰۲۱-۶۶۱۹۸۵۱۴ www.myuptodate.com دریافت آخرین نسخه آپتودیت آفلاین

1C28

Key word: Most Common Site of Lung Abscess

Author: Robert A. Meguid, MD, MPH
Editors: Malcolm V. Brock, MD, FACS, and Robert A. Meguid, MD, MPH

Which of the following is the most common site of lung abscesses?

(A) Left lower lobe, posterior basal segment

(B) Lingula

(C) Right lower lobe, anterior basal segment

(D) Right middle lobe, lateral segment

(E) Right upper lobe, posterior segment

Answer: **(E)** Right upper lobe, posterior segment

Rationale:

Lung abscesses are most frequently caused by aspiration of anaerobic bacteria. The most commonly isolated organisms are *Staphylococcus aureus, Beta-hemolytic streptococci,* Pseudomonas, and *Klebsiella pneumoniae.*

Involvement occurs in a segmental distribution, and as most patients are recumbent at the time of aspiration of the infectious organisms, dependent parenchyma is most commonly affected. Lung abscesses most frequently occur in the right lung, and in the posterior segments of upper lobes and the superior segments of lower lobes. Therefore, the posterior segment of the right upper lobe, and the superior segment of the right lower lobe are most at risk.

In prone patients, the lingual and right middle lobes are the most common sites of lung abscess formation.

References:

Netter FH. *Atlas of Human Anatomy.* 2nd ed. Plate 191. East Hanover, NJ: Novartis; 1997.

Vigneswaran WT. Lung abscess. In: Yang SC, Cameron DE, ed. *Current Therapy in Thoracic and Cardiovascular Surgery.* Philadelphia, PA: Mosby; 2004:225–226.

1C29

Key word: Likely Etiology of Acute Pulseless Leg

Author: Eric S. Weiss, MD, MPH
Editors: James H. Black III, MD, FACS, and Christopher J. Abularrage, MD

A 72-year-old man with a history of hypertension, hyperlipidemia, diabetes mellitus, and an irregular heart rhythm presents in the emergency department with acute onset of unremitting right leg pain below the knee. He denies trauma and states that he regularly walks a block to the grocery store without difficulty. On physical examination, the leg appears white and cool to touch and is noticeably painful to palpation. In addition, no dorsalis pedis or posterior tibial pulse can be palpated nor can a signal be identified with use of the Doppler probe. The most likely etiology for this patient's peripheral ischemia is:

(A) Acute thrombosis

(B) Chronic atherosclerotic disease

(C) Drug-induced ischemia

(D) Embolic disease

(E) Vasculitis

Answer: **(D)** Embolic disease

Rationale:

Without appropriate treatment, the rate of limb loss can approach 22% for acute lower-extremity ischemia. The most common cause of acute ischemia is embolic disease, such as that resulting from this patient's atrial fibrillation. Other causes include cardiac emboli from cardiomyopathies or prosthetic valves and emboli originating from anuerysmal disease. Acute thrombosis in the setting of chronic peripheral vascular disease can cause a pulseless leg but is usually preceded by prior history of claudication or appreciated trophic limb changes, which are often bilateral. Drugs and vasculitis are not likely to cause acute ischemia of the lower extremity.

Reference:

Belkin M, Whittemore AD, Donaldson MC, et al. Peripheral arterial occlusive disease. In: Townsend CM, Beauchamp RD, Evers BM, Mattox KL, eds. *Sabiston Textbook of Surgery.* 17th ed. Philadelphia, PA: Elsevier Saunders; 2004: 1989–2029.

۰۲۱-۶۶۱۹۸۵۱۴ www.myuptodate.com دریافت آخرین نسخه آپتودیت آفلاین

1C30

Key word: Characteristics of Normal Lower-extremity Venous Pressure Studies

Author: Robert A. Meguid, MD, MPH
Editor: Julie A. Freischlag, MD

A 62-year-old woman presents to your clinic with complaints of progressive leg swelling throughout the day. Which of the following is the best method for assessing venous valvular competency?

(A) Arteriography

(B) Duplex Doppler ultrasonography

(C) Impedance plethysmography

(D) Venography

(E) Venography with direct venous cannulation

Answer: (B) Duplex Doppler ultrasonography

Rationale:

The "venous pump" is composed of skeletal muscles, and superficial and deep veins connected by intramuscular venous sinusoids. Valves in the veins help ensure directional blood flow. Muscular contraction generates force to drive blood flow toward the deep veins and ultimately to the heart. Venous pressures in the lower extremities can reach 100 mm Hg due to stasis when a person is standing. However, muscle contraction can generate pressures between 20 and 200 mm Hg, from activity as minimal as shifting weight up to the stronger force generated by calf muscle contraction. This "venous pump" reduces edema.

In the event of incompetent venous valves, muscle contraction results in retrograde, as well as antegrade, propulsion of blood. Venous pressure is never relieved, and edema and stasis ulcers may form. Venous ulceration may result from incompetence of valves in the deep, superficial, or perforating veins.

Assessment of venous competency may be performed by physical examination, venography, direct venous cannulation, plethysmography, and duplex Doppler ultrasonography. Physical examination alone is often inaccurate in assessing venous competency. Venography enables assessment of venous integrity through visualization of the venous system. Direct venous cannulation permits measurement of ambulatory venous pressure, but is uncomfortable to the patient, costly, and time-consuming. Plethysmography measures the rate of calf vein emptying following release of proximal pressure, enabling the quantification of venous obstruction and resistance. Impedance plethysmography and photoplethysmography techniques have been developed as well. Impedance plethysmography is only accurate for proximal occlusive venous thrombi.

Currently, the gold standard in assessment of venous incompetence is duplex Doppler ultrasonography. This combines B-mode anatomic ultrasonography with color flow duplex ultrasonography to assess location and size of veins as well as direction of blood flow. Diagnosis of valvular incompetence may be made if release of calf muscle compression shows retrograde blood flow. Ultrasonography and venography are the only venous assessment techniques that enable visualization of the variable venous anatomy.

Reference:

Flye MW. Venous disorders. In: Sabiston DC, Lyerly HK, eds. *Textbook of Surgery.* 15th ed. Philadelphia, PA: W.B. Saunders; 1997:1581–1593.

۰۲۱-۶۶۱۹۸۵۱۴ www.myuptodate.com دریافت آخرین نسخه آپتودیت آفلاین

1C31

Key word: Renal Effects of PEEP

Author: Kashif A. Zuberi, MBBCh, MRCSI
Editors: Robert A. Montgomery, MD, DPhil, FACS, and Dorry L. Segev, MD, PhD

A 70-year-old male with a 60 pack-year smoking history undergoes a Whipple operation for pancreatic adenocarcinoma. Intubated overnight in the surgical intensive care unit, his serial arterial blood gases show marked hypoxemia. The positive end-expiratory pressure (PEEP) is increased from 5-cm H_2O to 10-cm H_2O. The patient's urine output starts to decline thereafter and he receives several boluses of fluid throughout the night. The next morning, he is edematous and still intubated. What is the most likely etiology for his falling urine output?

(A) Acute tubular necrosis (ATN)
(B) Decrease in intra-abdominal pressure
(C) Increase in intrathoracic pressure
(D) Kinked urinary catheter
(E) Reduced renal blood flow

Answer: (E) Reduced renal blood flow

Rationale:
Patients on positive-pressure ventilation with PEEP have increased intra-thoracic pressure as well as increased intra-abdominal pressure. The increase in intra-abdominal pressure may augment fluid retention (due to decreased venous return) and lead to impaired renal function. These renal effects of PEEP are thought to occur through reduced renal blood flow, with a corresponding reduction in urinary output and sodium excretion. This reduced renal blood flow may be secondary to a reduction in cardiac output, or increased renal venous pressure and redistribution of renal blood flow from cortical to medullary regions. The release of renin by sympathetic activation, either directly by nerve stimulation on the nephrons or indirectly by circulating catecholamines, may also play a role in this pathophysiology.

Another cause of decreased urine output is ATN **(A),** which results from an acute insult on the kidneys but is also manifested with a sudden elevation in serum creatinine and blood urea nitrogen. There is usually mention of an inciting event before ATN develops. A kinked urinary catheter **(D)** can cause sudden anuria over a short period of time, but is usually corrected by manipulating or flushing the catheter.

References:
Lefrant JY, Juan JM, Bruelle P, et al. Regional blood flows are affected differently by PEEP when the abdomen is open or closed: An experimental rabbit model. *Can J Anaesth.* 2002;49:302–308.
Sharkey RA, Mulloy EM, Long M, et al. The effect of continuous positive airway pressure (CPAP) on renal vascular resistance: The influence of renal denervation. *Crit Care.* 1999;3(3):33–37.

1C32

Key word: Effect of AV Fistula on Cardiac Performance

Author: Nikiforos Ballian, MBBS
Editor: Andrew M. Cameron, MD, PhD

Four years after surgery for a gunshot injury to the right thigh, a 26-year-old man with no other significant past medical history is referred to your clinic due to a thrill and bruit over his right thigh discovered during a routine physical examination. Which of the following findings might you find in this patient?

(A) Blood pressure 160/90 mm Hg
(B) Cardiac output of 3.2 L/min
(C) Heart rate of 55 beats per minute
(D) Left ventricular hypertrophy
(E) Mixed venous oxygen saturation (SvO_2) of 55%

Answer: (D) Left ventricular hypertrophy

Rationale:
Arteriovenous fistulae (AVF) can occur following penetrating trauma to the abdomen or extremities. They are usually asymptomatic, especially in young patients, but can present with high-output cardiac failure due to AV shunting and/or ischemia distal to the lesion secondary to a "steal" phenomenon. Local findings on physical examination include a thrill and bruit over the lesion. The cardiovascular effects of an AVF depend on size, duration, and patient age and can persist after surgical interruption of the communication between artery and vein. Left-to-right shunting of oxygenated blood caused by AVFs will cause elevated mixed venous oxygen saturation and can lead to high-output cardiac failure, characterized by left ventricular hypertrophy and/or dilation, tachycardia, and decreased blood pressure. Compression of the artery proximal to an AVF causes reflex bradycardia and raises systemic blood pressure, known as the Branham–Nicoladoni sign. Conventional angiography remains the gold standard for diagnosis, although computed tomographic angiography may be superior. Color flow Doppler studies may also be diagnostic. Prompt treatment of AVFs is recommended to prevent local and systemic effects such as limb swelling and cardiac failure. AVFs are amenable to treatment by open surgery or endovascular techniques.

References:
Chen JK, Johnson PT, Fishman EK. Diagnosis of clinically unsuspected posttraumatic arteriovenous fistulas of the pelvis using CT angiography. *AJR Am J Roentgenol.* 2007;188:W269–W273.
Ilijevski N, Radak D, Radevic B, et al. Popliteal traumatic arteriovenous fistulas. *J Trauma.* 2002;52:739–744.

۰۲۱-۶۶۱۹۸۵۱۴ www.myuptodate.com دریافت آخرین نسخه آپتودیت آفلاین

1C33

Key word: Findings by Pulmonary Artery Catheter in a Patient with an Acute Myocardial Infarction

Author: Susanna M. Nazarian, MD, PhD
Editor: William A. Baumgartner, MD

You are caring for a 75-year-old man in the surgical intensive care unit who is postoperative day 3 from an open cholecystectomy for a necrotic gallbladder. The patient is 10 L fluid positive since surgery and is producing only 10 cm^3 of urine per hour. You decide to insert a pulmonary artery catheter. What findings would suggest that the patient has suffered an acute myocardial infarction in the left anterior descending coronary artery distribution?

Key:

SBP = systemic blood pressure
CO = cardiac output
HR = heart rate
SV = stroke volume
SVR = systemic vascular resistance
CVP = central venous pressure
PCWP = pulmonary capillary wedge pressure

(A) ⇑ SBP, ⇓ CO, ⇑ HR, ⇑ SV, ⇑ SVR, ⇓ CVP, ⇓ PCWP
(B) ⇓ SBP, ⇓ CO, ⇓ HR, ⇓ SV, ⇑ SVR, normal CVP, ⇑ PCWP
(C) ⇓ SBP, ⇓ CO, ⇓ HR, ⇓ SV, ⇑ SVR, ⇑ CVP, ⇑ PCWP
(D) ⇓ SBP, normal CO, ⇓ HR, ⇑ SV, ⇑ SVR, ⇓ CVP, ⇑ PCWP
(E) ⇓ SBP, ⇓ CO, ⇑ HR, ⇓ SV, ⇑ SVR, ⇑ CVP, ⇑ PCWP

Answer: (E) ⇓ SBP, ⇓ CO, ⇑ HR, ⇓ SV, ⇑ SVR, ⇑ CVP, ⇑ PCWP

Rationale:
Patients who have suffered an acute myocardial infarction may develop cardiogenic shock. This is characterized by lower systemic blood pressure, diminished cardiac output, elevated heart rate, fall in stroke volume, and elevated (or normal) systemic vascular resistance. The changes in pulmonary artery pressure and pulmonary capillary wedge pressure depend on the anatomic location of the infarct. Left ventricular failure, such as that following an infarction in the left anterior descending artery territory, would result in lower pulmonary artery pressure (PAP) but elevated PCWP. The PCWP is an estimation of left heart pressure and would rise in left heart failure.

Reference:
Davies RR, Coady MA. Mechanical complications of myocardial infarction. In: Yuh DD, Vricella LA, Baumgartner WA, eds. *The Johns Hopkins Manual of Cardiothoracic Surgery.* New York, NY: McGraw Hill; 2007:494–495.

Hemodynamic Measurements with Different Etiologies of Shock

	Cardiogenic Shock								
	Biventricular Failure	LV Failure	RV Failure	Septic	Anaphylactic	Hypovolemic or Hemorrhagic	Pericardial Tamponade	Tension Pneumothorax	Massive Pulmonary Embolism
BP	⇓	⇓	⇓	⇓	⇓	⇓	⇓	⇓	⇓
CO/CI	⇓⇓	⇓⇓	⇓⇓	⇑⇑ or normal	⇑ or normal	⇓	⇓	⇓	⇓⇓
HR	⇑	⇑	⇑	⇑	⇑	⇑	⇑	⇑	⇑
SV	⇓	⇓	⇓	⇑ or normal	⇑ or normal	⇑ or normal	⇓⇓	⇓	⇓
SVR	⇑ or normal	⇑ or normal	⇑ or normal	⇓⇓	⇓⇓	⇑ or normal	⇑	⇑	⇑
CVP	⇑	⇑ or normal	⇑⇑	⇓ or normal	⇓ or normal	⇓⇓	⇑⇑	⇑	⇑⇑
PAP	⇑	⇓	⇓	⇓	⇓	⇓	⇑⇑	⇓	⇑⇑
PCWP	⇑	⇑⇑	normal or ⇓	⇓ or normal	⇓ or normal	⇓⇓	⇑⇑	⇓	normal or ⇓

LV, left ventricular; RV, right ventricular; BP, blood pressure; CO, cardiac output; CI, cardiac index; HR, heart rate; SV, stroke volume; SVR, systemic vascular resistance; CVP, central venous pressure; PAP, pulmonary artery pressure; PCWP, pulmonary capillary wedge pressure.

Reprinted with permission from: Davies RR, Coady MA. Mechanical complications of myocardial infarction. In: Yuh DD, Vricella LA, Baumgartner WA, eds. *The Johns Hopkins manual of cardiothoracic surgery.* New York, NY: McGraw-Hill; 2007:495.

۰۲۱-۶۶۱۹۸۵۱۴ www.myuptodate.com دریافت آخرین نسخه آپتودیت آفلاین

1C34

Key word: Contraindications to Pneumonectomy

Author: Jacqueline Garonzik-Wang, MD, PhD
Editors: Stephen M. Cattaneo II, MD, and Robert A. Meguid, MD, MPH

A 64-year-old man with a new diagnosis of lung cancer is scheduled for preoperative pulmonary function tests to determine if he is a candidate for surgical pneumonectomy. Which of the following results would confirm him as a good candidate for the proposed surgical procedure?

(A) Diffusing capacity of the lung for carbon monoxide (DLCO) of 85% the predicted value

(B) Predicted postoperative forced expiratory volume in 1 second (FEV1) of 0.7 L

(C) Preoperative PCO_2 of 48 mm Hg on room air

(D) Preoperative PO_2 of 48 mm Hg on room air

(E) VO_2 max (maximal oxygen consumption) of 10 mL/kg/min

Answer: (A) Diffusing capacity of the lung for carbon monoxide (DLCO) of 85% the predicted value

Rationale:
Prior to pneumonectomy, the surgeon must ensure that the patient will be able to appropriately ventilate and oxygenate with the remaining lung. Relative contraindications to pneumonectomy include the following.

- FEV_1 <0.8 L
- PCO_2 >45 mm Hg
- PO_2 <50 mm Hg
- DLCO <60% of the predicted value
- VO_2 max (maximal oxygen consumption) <15 mL/kg/min

Values below these thresholds are associated with diminished pulmonary function and increased mortality following pulmonary resection.

Reference:
Datta D, Kahiri B. Preoperative evaluation of patients undergoing lung resection surgery. *Chest.* 2003;123(6):2096–2103.

1C35

Key word: Treatment of Adenocarcinoma of the Lung

Author: Clinton D. Kemp, MD
Editors: Malcolm V. Brock, MD, FACS, and Robert A. Meguid, MD, MPH

A 63-year-old female with a 30 pack-year history of smoking presents complaining of a persistent cough and a 4.54-kg (10-lb) weight loss, but is otherwise physically active. Chest computed tomography (CT) demonstrates a solitary, spiculated, 2.8-cm mass in the periphery of the right upper lobe without evidence of spread to mediastinal lymph nodes or to the contralateral lung. Fine-needle biopsy is consistent with non–small-cell adenocarcinoma of the lung. Integrated Positron Emission Tomography and Computed Tomography (PET–CT) demonstrates disease confined to the known right upper lobe lesion. She is referred to you for further management. What is the preferred treatment for this patient?

(A) Chemotherapy alone

(B) Chemotherapy plus radiation therapy

(C) Lobectomy and mediastinal lymphadenectomy

(D) Pneumonectomy and mediastinal lymphadenectomy

(E) Wedge resection of the tumor

Answer: (C) Lobectomy and mediastinal lymphadenectomy

Rationale:
Lung cancer is the second most common cancer in both males and females and is the leading cause of death from cancer in both sexes. Over 200,000 new cases of lung cancer are diagnosed each year, and the survival rates remain dismal with an overall 14% 5-year survival for patients of all stages. Cigarette smoking remains the primary risk factor for development of lung cancer, but other environmental exposures such as chemical carcinogens, asbestos, secondary tobacco smoke exposure, and radiation exposure have been implicated in the pathogenesis of lung cancer.

Lung cancer is categorized as either small-cell lung cancer (SCLC) or non–small-cell lung cancer (NSCLC). Fifteen percent of lung cancers fall into the SCLC group, and there is some evidence to suggest that the incidence of SCLC in the United States has been decreasing in recent years. These tumors are typically located centrally in the lung parenchyma and originate from neuroendocrine cells. They are very aggressive and tend to metastasize early and widely to lymph nodes, lung, liver, bone, and brain. The treatment of choice for this SCLC is primarily chemotherapy with palliative radiation therapy as needed. The 5-year survival rate for these tumors is just 5%.

NSCLC can be further subdivided into adenocarcinoma, squamous cell carcinoma, large cell, and bronchioloalveolar carcinoma. Adenocarcinoma is the most common subtype of NSCLC, comprised of nearly half of it. This tumor arises from the glandular epithelium. Squamous cell carcinoma of the lung accounts for approximately one-third of all lung cancers. Bronchioloalveolar carcinoma is a more indolent subtype of adenocarcinoma, and tends to spread along alveolar walls, termed lepidic spread.

۰۲۱-۶۶۱۹۸۵۱۴ www.myuptodate.com دریافت آخرین نسخه آپتودیت آفلاین

The patient described presents with an early stage non–small-cell adenocarcinoma of the lung. Based on the tumor size (<3 cm) and absence of involvement in mediastinal lymph nodes or metastases on CT and PET–CT, the clinical stage of the lesion is T1N0M0, or stage IA.

Refinements in treatment of NSCLC have been ongoing over many decades, and are continuing to evolve. Currently, general principles include anatomic resection (i.e., lobectomy) of tumors confined to the lung with ≥2-cm margins from the carina and without known lymph node disease, use of adjuvant chemotherapy and possibly radiation therapy when lymph node involvement is discovered following primary tumor resection, and use of neoadjuvant chemotherapy and possibly radiation therapy where ipsilateral bronchopulmonary and hilar (N1) and mediastinal (N2) lymph node involvement is identified prior to tumor resection. In the setting of contralateral mediastinal or any supraclavicular lymph node involvement (N3) or metastatic disease, chemotherapy and radiation therapy are the primary treatment. Exceptions to this are presence of local invasion into adjacent structures, or isolated metastases to the lung, brain, and adrenal glands, where multimodality therapy may include surgery as evaluated on a case-by-case basis.

Radiation therapy is not the preferred treatment for low-stage NSCLC in a patient who will tolerate surgical resection. It is used in conjunction with chemotherapy in some neoadjuvant and adjuvant protocols, and for patients who are deemed not to be surgical candidates due to advanced disease or presence of comorbidities precluding surgery.

When surgical resection is indicated, formal anatomic resection (i.e., lobectomy) with mediastinal lymph node dissection is the operation of choice for NSCLC. Wedge resections are performed initially for diagnosis of solitary pulmonary nodules and for pathologic evaluation of benign disease. If a wedge resection confirms malignancy, a formal lobectomy with mediastinal lymph node dissection is indicated. Pneumonectomies are not the operation of choice for peripheral adenocarcinoma, unless there is spread into contiguous lobes preventing lobectomy alone.

TNM Descriptors and Staging for NSCLC

Primary Tumor (T)	
Tx	Primary tumor cannot be assessed or tumor proven by the presence of malignant cells in sputum or bronchial washings but not visualized by imaging or bronchoscopy
T0	No evidence of primary tumor
Tis	Carcinoma in situ
T1	Tumor ≤3 cm in greatest dimension, surrounded by lung or visceral pleura, without bronchoscopic evidence of invasion more proximal than the lobar bronchus[a] (i.e., not in the main bronchus)
T1a	Tumor ≤2 cm in greatest dimension
T1b	Tumor >2 cm but ≤3 cm in greatest dimension
T2	Tumor >3 cm but ≤7 cm or tumor with any of the following features: T2 tumors with these features are classified as T2a if ≤5 cm Involves main bronchus, >2 cm distal to the carina Invades visceral pleura (PL1 or PL2) Associated with atelectasis or obstructive pneumonitis that extends to the hilar region but does not involve the entire lung
T2a	Tumor >3 cm but ≤5 cm in greatest dimension
T2b	Tumor >5 cm but ≤7 cm in greatest dimension
T3	Tumor >7 cm or one that directly invades any of the following: Parietal pleural (PL3) chest wall (including superior sulcus tumors), diaphragm, phrenic nerve, mediastinal pleura, parietal pericardium; or tumor in the main bronchus (<2 cm distal to the carina[b] but without involvement of the carina; or associated atelectasis or obstructive pneumonitis of the entire lung or separate tumor nodule(s) in the same lobe
T4	Tumor of any size that invades any of the following: Mediastinum, heart, great vessels, trachea, recurrent laryngeal nerve, esophagus, vertebral body, carina, separate tumor nodule(s) in a different ipsilateral lobe
Regional Lymph Nodes (N)	
Nx	Regional lymph nodes cannot be assessed
N0	No regional lymph node metastasis
N1	Metastasis to ipsilateral peribronchial and/or ipsilateral hilar lymph nodes, and intrapulmonary nodes involved by direct extension of the primary tumor
N2	Metastasis to ipsilateral mediastinal and/or subcarinal lymph nodes(s)
N3	Metastasis to contralateral mediastinal, contralateral hilar, ipsilateral or contralateral scalene, or supraclavicular lymph node(s)
Distant Metastasis (M)	
M0	No distant metastasis (no pathologic M0; use clinical M to complete stage group)
M1	Distant metastasis present
M1a	Separate tumor nodule(s) in a contralateral lobe; tumor with pleural nodules or malignant pleural (or pericardial) effusion
M1b	Distant metastasis

(*continued*)

۰۲۱-۶۶۱۹۸۵۱۴ www.myuptodate.com دریافت آخرین نسخه آپتودیت آفلاین

TNM Descriptors and Staging for NSCLC (*Continued*)

Stage Classification

CLINICAL is denoted with c, Pathologic is denoted with p, and y descriptor is used for patients after neoadjuvant therapy

Group	T	N	M
Occult	TX	N0	M0
0	Tis	N0	M0
IA	T1a	N0	M0
	T1b	N0	M0
IB	T2a	N0	M0
IIA	T2b	N0	M0
	T1a	N1	M0
	T1b	N1	M0
	T2a	N1	M0
IIB	T2b	N1	M0
	T3	N0	M0
IIIA	T1a	N2	M0
	T1b	N2	M0
	T2a	N2	M0
	T2b	N2	M0
	T3	N1	M0
	T3	N2	M0
	T4	N0	M0
	T4	N1	M0
IIIB	T1a	N3	M0
	T1b	N3	M0
	T2a	N3	M0
	T2b	N3	M0
	T3	N3	M0
	T4	N2	M0
	T4	N3	M0
IV	Any T	Any N	M1a
	Any T	Any N	M1b

Additional Descriptors:

Histologic grade (G)

(*AKA overall grade*)

Grading System	Grade
2 grade system	Grade I or 1
3 grade system	Grade II or 2
4 grade system	Grade III or 3
Not available	Grade IV or 4

Lymph-Vascular Invasion (LVI)

LVI (absent)/Not identified

LVI Present/Identified

Not applicable

Unknown/Indeterminate

Residual Tumor (R)

RX Presence of residual tumor cannot be assessed

R0 No residual tumor

R1 Microscopic residual tumor

R2 Macroscopic residual tumor

[a]The uncommon superficial spreading tumor of any size with its invasive component limited to the bronchial wall, which may extend proximally to the main bronchus, is also classified as T1a.

[b]Most pleural (and pericardial) effusions with lung cancer are due to tumor. In a few patients, however, multiple cytopathologic examinations of pleural (pericardial) fluid are negative for tumor, and the fluid is nonbloody and is not an exudate. Where these elements and clinical judgment dictate that the effusion is not related to the tumor, the effusion should be excluded as a staging element and the patient should be classified as M0.

Reprinted with permission from: Blackmon SH, Vaporciyan AA. Thoracic malignancies. In: Feig BW, Ching CD, eds. *The MD Anderson Surgical Oncology Handbook*. 5th ed. Philadelphia, PA: Lippincott Williams & Wilkins; 2012:225–227.

۰۲۱-۶۶۱۹۸۵۱۴ www.myuptodate.com دریافت آخرین نسخه آپتودیت آفلاین

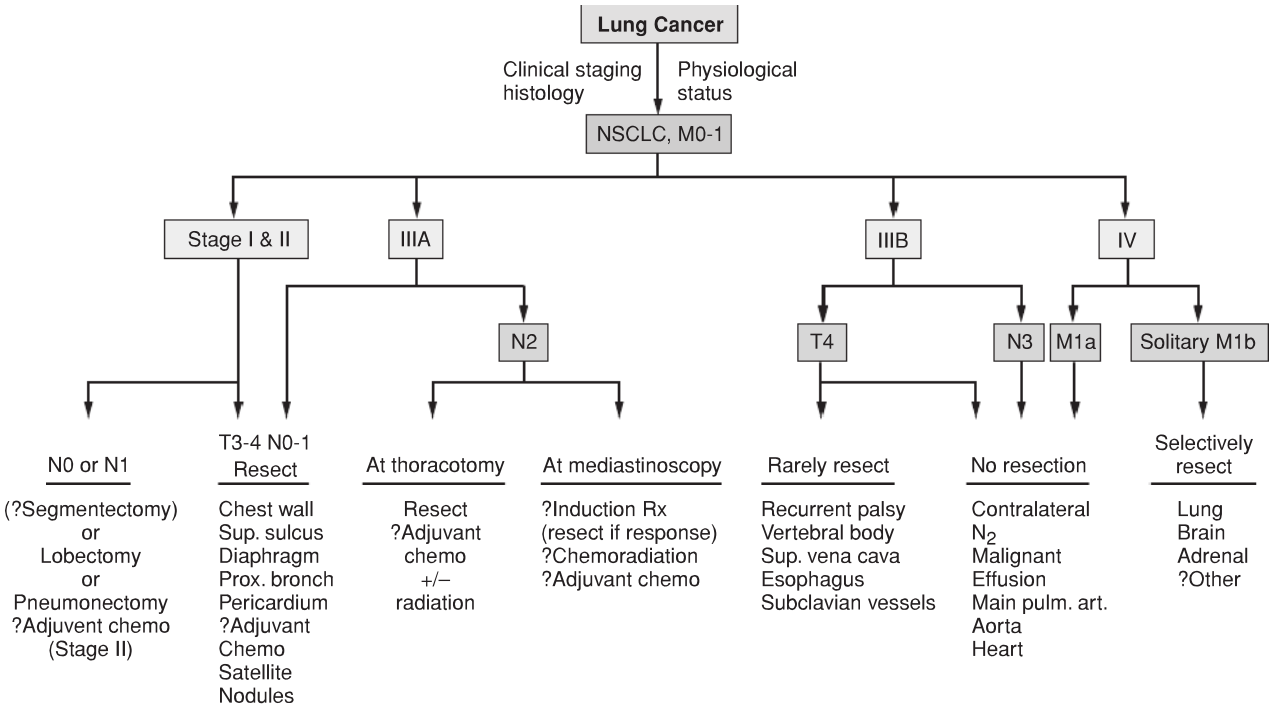

Reprinted with permission from: Schrump DS, Carter D, Kelsey CR, et al. Non-Small Cell Lung Cancer. In: Devita VT, Lawrence TS, Rosenberg SA, eds. *Cancer: Principles & Practice of Oncology.* 9th ed. Philadelphia, PA: Lippincott Williams & Wilkins; 2011:814.

References:

Blackmon SH, Valporciyan AA. Thoracic malignancies. In: Feig BW, Ching CD, eds. *The M.D. Anderson Surgical Oncology Handbook.* 5th ed. Philadelphia, PA: Lippincott Williams and Wilkins; 2012.

Schrump DS, Carter D, Kelsey CR, et al. Non-small-cell lung cancer. In: DeVita VT, Lawrence TS, Rosenberg SA, eds. *Cancer Princilpes and Practice of Oncology.* 9th ed. Philadelphia, PA: Lippincott, Williams and Wilkins; 2011: 799–847.

Siegel R, Naishadham D, Jemal A. Cancer statistics, 2013. *CA Cancer J Clin.* 2013;63:11–30.

Tomaszek SC, Wigle DA. Surgical management of lung cancer. *Semin Respir Crit Care Med.* 2011;32(1):69–77.

۰۲۱-۶۶۱۹۸۵۱۴ www.myuptodate.com دریافت آخرین نسخه آپتودیت آفلاین

1C36

Key word: Characteristics of Extralobar Pulmonary Sequestration

Authors: Robert A. Meguid, MD, MPH, and Susanna M. Nazarian, MD, PhD
Editors: Stephen M. Cattaneo II, MD, and Robert A. Meguid, MD, MPH

A 6-year-old boy referred to your clinic after workup for recurrent pneumonia reveals extralobar pulmonary sequestration (PS). Which of the following characteristics is most commonly associated with the patient's diagnosis?

(A) Abnormal tissue surrounded by normal lung parenchyma

(B) Arterial supply from the abdominal aorta

(C) Ebstein anomaly

(D) Usually occurs in upper lobes

(E) Venous drainage via the inferior pulmonary ligament

Answer: (B) Arterial supply from the abdominal aorta

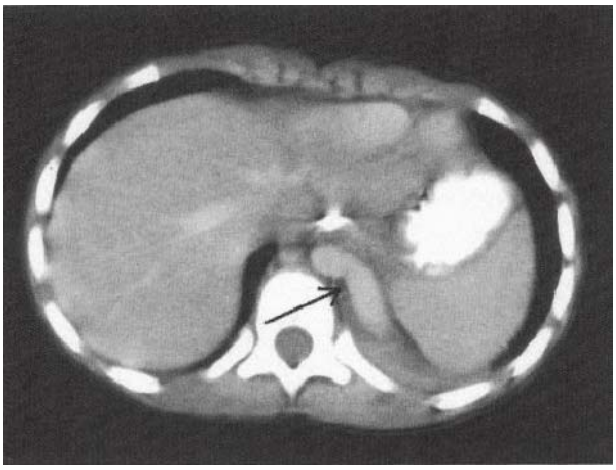

CT of pulmonary sequestration on the left side, demonstrating the infradiaphragmatic aortic blood supply to the mass, which continues into the left thoracic cavity (*arrow*). Reprinted with permission from: Kling KM. Congenital pulmonary anomalies. In: Yuh DD, Vricella LA, Baumgartner WA, eds. *The Johns Hopkins manual of cardiothoracic surgery.* New York, NY: McGraw-Hill; 2007:126.

Rationale:

PS of the lung is characterized by lung tissue surrounded by its own pleura and not connected with the tracheobronchial tree. PS accounts for 30% of all bronchopulmonary-foregut malformations, and show a 1.5:1 male:female predominance. The sequestered tissue is remnant nonfunctioning embryonic lung.

PS may be extralobar or intralobar. If the sequestration arises prior to complete development of the visceral pleura, the PS will be contained within the pleura and will, therefore. be intralobar. Extralobar sequestrations, in contrast, develop after the continuity of the visceral pleura is established.

The arterial supply of the extralobar sequestration does not arise from the pulmonary arteries, but instead from the systemic circulation. Most commonly, the sequestration is supplied from a branch off the abdominal aorta, and venous drainage occurs via the azygos or hemiazygos vein. Extralobar sequestration of the lung usually occurs in the posterior sulcus between the lower lobe and diaphragm. They are seen more commonly on the left than the right side although they can occur bilaterally.

Extralobar sequestration of the lung usually presents in children with recurrent episodes of pneumonia or a chronic cough. Rarely, erosion into vessels due to abscess and chronic exposure to systemic blood pressure occurs, leading to massive hemoptysis or hemothorax. Workup of associated anomalies sometimes reveals the presence of extralobar PS. These associated anomalies include pectus excavatum, cervical vertebral anomalies, structural cardiac disease, pulmonary vascular hypoplasia, arteriovenous malformations, intestinal duplications, esophageal diverticula, and diaphragmatic hernia.

Diagnosis starts with a plain chest film to look for consolidation, given that PS is not aerated. Other possible signs on plain film include mass effect or lung abscess. Ultrasound can then confirm PS by demonstrating aberrant blood supply. Other ancillary tests such as a CT scan or arteriogram are possible, but may be difficult in children. Treatment consists of surgical resection: Lobectomy for intralobar PS during a quiescent phase and simple excision of extralobar PS. Outcomes are excellent provided the sequestration is not associated with other anomalies.

Ebstein anomaly is the most common isolated congenital tricuspid valve lesion. It is characterized by a low-sitting valve within the right ventricle, with the septal and posterior leaflets originating from the right ventricular wall and a large anterior leaflet. Patients have severe tricuspid regurgitation and decreased cardiac output.

References:

Fleischer KJ. Cardiac surgery. In: Fleischer KJ, ed. *Advanced Surgical Recall.* Philadelphia, PA: Williams and Wilkins; 1997:675–676, 689.

Fleischer KJ. Thoracic surgery. In: Fleischer KJ, ed. *Advanced Surgical Recall.* Philadelphia, PA: Williams and Wilkins; 1997:1057–1058.

Kling KM. Congenital pulmonary anomalies. In: Yuh DD, Vricella LA, Baumgartner WA, eds. *The Johns Hopkins Manual of Cardiothoracic Surgery.* New York, NY: McGraw-Hill; 2007:126–128.

۰۲۱-۶۶۱۹۸۵۱۴ www.myuptodate.com دریافت آخرین نسخه آپتودیت آفلاین

1C37

Key word: Effect of Inspiration Phase of Mechanical Ventilation on Cardiac Dynamics

Author: Robert A. Meguid, MD, MPH
Editor: Elliott R. Haut, MD, FACS

You are caring for an intubated patient in the intensive care unit who is hypovolemic but has normal left ventricular function. Which of the following is an effect of the inspiration phase of positive-pressure mechanical ventilation?

(A) Decreased cardiac output
(B) Decreased intrathoracic pressure
(C) Increased cardiac output
(D) Increased ventricular distensibility
(E) Reverse pulsus paradoxus

Answer: (A) Decreased cardiac output

Rationale:
In patients with hypovolemia and normal left ventricular function, the inspiratory phase of positive-pressure mechanical ventilation results in decreased cardiac output. There are numerous mechanisms accounting for this effect.

1. Decreased venous return from a lower pressure gradient between the thoracic portions of the superior and inferior venae cavae and the extra-thoracic venous system
2. Decreased ventricular distensibility and ventricular filling due to increased extra-cardiac pressure on the ventricles
3. Decreased ejection fraction and decreased return from the pulmonary beds due to compression and increased vascular resistance of the pulmonary vessels

In the event of adequate intravascular volume, positive-pressure mechanical ventilation results in reverse pulsus paradoxus. The heightened intrathoracic pressure in the normovolemic state amplifies the stroke volume, causing increased systolic blood pressure.

In patients with impaired left ventricular function and elevated left ventricular filling pressure, positive-pressure mechanical ventilation effectively decreases afterload, and reduces the dilated ventricular wall radius, cumulatively increasing cardiac output.

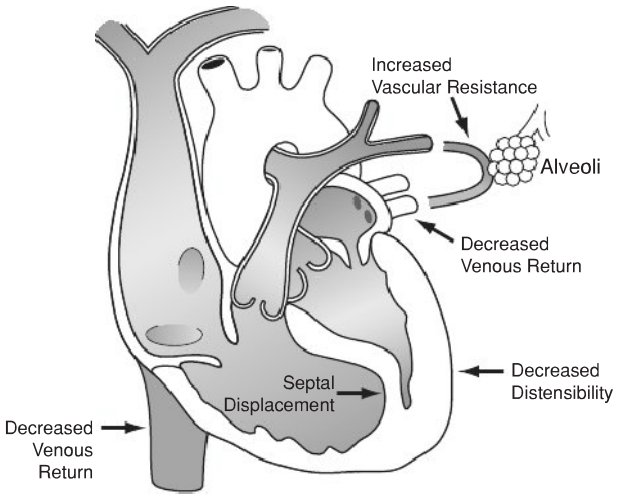

The mechanisms whereby positive-pressure ventilation can decrease ventricular filling (preload). Reprinted with permission from: Marino PL. Principles of mechanical ventilation. *The ICU Book*. 3rd ed. Philadelphia, PA: Lippincott Williams & Wilkins; 2007:460.

References:

Marino PL. Principles of mechanical ventilation. In: *The ICU Book*. 3rd ed. Philadelphia, PA: Lippincott, Williams and Wilkins; 2007:457–471.

Pietropaoli AP. Approach to mechanical ventilation. In: Apostolakos MJ, Papadakos PJ, eds. *The Intensive Care Manual*. New York, NY: McGraw Hill; 2001:71–102.

۰۲۱-۶۶۱۹۸۵۱۴ www.myuptodate.com دریافت آخرین نسخه آپتودیت آفلاین

دریافت آخرین نسخه آپتودیت آفلاین www.myuptodate.com ۰۲۱-۶۶۱۹۸۵۱۴

4
MISCELLANEOUS (GENITOURINARY, HEAD AND NECK, SKIN, MUSCLE, AND NERVOUS SYSTEM)

CONTENTS:

Number:	Key Word:	Page:
1M01	Characteristics of Donor Nephrectomy	202
1M02	Characteristics of Merkel Cell Cancer	202
1M03	Characteristics of Lymphatic Malformation of the Skin	203
1M04	Treatment of Inadvertent Intraoperative Ureteral Injury	203
1M05	Nerve Injury Resulting from Calf Fasciotomy	204
1M06	Treatment of Squamous Cell Carcinoma of the Lower Lip	204
1M07	Nerve Injury Associated with Anterior Dislocation of the Humerus	205
1M08	Donor-site Healing in Split-thickness Skin Grafts	206
1M09	Characteristics of Split-thickness Skin Grafts	207
1M10	Treatment of Metastatic Ovarian Cancer	207
1M11	Treatment of Syndrome of Inappropriate ADH Secretion (SIADH)	208
1M12	Treatment of a Supracondylar Fracture of the Humerus in a Child	209
1M13	Most Important Component in the Glasgow Coma Scale	210
1M14	Treatment of Epidermoid Cancer of Neck Lymph Nodes	211
1M15	Optimal Cerebral Perfusion Pressure	211
1M16	Treatment of Necrotizing Fasciitis	212
1M17	Treatment of Parotid Mass	213
1M18	Treatment of Buccal Squamous Cell Carcinoma	215
1M19	Diagnostic Test for a Solitary Neck Mass	216
1M20	Treatment of Rectal Bleeding after Laminectomy	216
1M21	Treatment of Penetrating Renal Trauma	217
1M22	Inhibition of Keloid Formation	217
1M23	Treatment of Pelvic Fractures	218
1M24	Prophylaxis against Venous Thrombosis	219
1M25	Characteristics of Sentinel Lymph Node Biopsy	220
1M26	Poorest Prognosis in Cerebral Trauma	221
1M27	Anatomy of the Right Renal Artery	221
1M28	Rationale for Delayed Primary Wound Closure	222
1M29	Diagnosis of an Infected Burn Wound	222
1M30	Treatment of 1.7-mm Melanoma of the Trunk	223
1M31	Earliest Symptom of Compartment Syndrome	225
1M32	Fracture Associated with Pain in the Anatomic Snuffbox	226

۰۲۱-۶۶۱۹۸۵۱۴ www.myuptodate.com دریافت آخرین نسخه آپتودیت آفلاین

1M01

Key word: Characteristics of Donor Nephrectomy

Author: Matthew J. Weiss, MD
Editors: Robert A. Montgomery, MD, DPhil, FACS, and Dorry L. Segev, MD, PhD

A 27-year-old male with idiopathic renal failure on hemodialysis is awaiting a kidney transplant. Multiple family members and friends have presented to the transplant center for evaluation of possible live donor transplantation. The recipient's brother volunteers to donate his kidney and is found to have a favorable human leukocyte antigen (HLA) match. Which of the following conditions is *least likely* to be considered a contraindication for live kidney donation?

(A) Current cocaine usage
(B) HIV infection
(C) Type II diabetes mellitus
(D) Uncontrollable hypertension
(E) Unilateral duplicated collecting system

Answer: (E) Unilateral duplicated collecting system

Rationale:
Live kidney donors are exposed to medical and surgical risk for the benefit of another without a countervailing personal medical benefit. As such, it is particularly important to be as sure as possible that the risk to the donor is minimal. Centers perform routine screening on all potential donors that includes the presence of medical disease, infection, malignancy, and procedure-specific risks. Hypertension or diabetes puts donors at a higher risk of future kidney disease; all centers consider hypertension a relative contraindication (and some consider it an absolute contraindication), and almost all centers consider diabetes an absolute contraindication. HIV predisposes a patient to developing HIV-associated nephropathy and as a result is considered an absolute contraindication to donation; furthermore, transplantation of organs infected with HIV currently violates congressional law. Current drug dependency is also at least a relative contraindication for donation. As surgical techniques evolve, comfort with anatomic variations such as multiple blood vessels or duplicated urinary collecting systems is increasing; currently, a duplicated urinary collecting system is not considered a contraindication.

Reference:
Koller H, Mayer G. Evaluation of the living kidney donor. *Nephrol Dial Transplant.* 2004;19(Suppl 4):41–44.

1M02

Key word: Characteristics of Merkel Cell Cancer

Author: Michele A. Manahan, MD
Editors: Paul N. Manson, MD, FACS, Gedge D. Rosson, MD, and Pablo A. Baltodano, MD

Which of the following is a characteristic of Merkel cell carcinoma?

(A) Early distant metastases
(B) Frequently cured with wide local excision alone
(C) Histologically similar to squamous cell carcinoma
(D) Locally aggressive tumor with low chance of distant spread
(E) Slow growing, well-defined cutaneous lesion

Answer: (A) Early distant metastases

Rationale:
Merkel cell tumors are histologically similar to basal cell carcinomas but are both locally aggressive and commonly demonstrate distant metastases to nodes, viscera, and bone. On hematoxylin and eosin (H and E) staining, they appear as deeply basophilic cell clusters in the dermis with nuclei that do not demonstrate severe atypia. They may stain positive for enolase, allowing differentiation between Merkel cell tumors and basal cell carcinomas. In addition, using keratin antibodies, a distinct perinuclear dot pattern is seen with aggregation of antibodies at the nuclear border. CT or MRI should be used to evaluate for distant metastatic disease. They are difficult to treat, but common therapy consists of surgery (with 2- to 3-cm margins when possible), elective regional lymphadenectomy or sentinel lymph node biopsy, and radiation. Radiation therapy is useful as adjuvant therapy for both local and regional control and can also be used when surgery is not an option. Chemotherapy is currently under investigation.

References:
Dinh V, Feun L, Elgart G, et al. Merkel cell carcinomas. *Hematol Oncol Clin North Am.* 2007;21(3):527–544.
Stal S, Spira M. Basal and squamous cell carcinoma of the skin. In: Aston SJ, Beasley RW, Thorne CHM, eds. *Grabb and Smith's Plastic Surgery.* 5th ed. Philadelphia, PA: Lippincott-Raven; 1997:117.

۰۲۱-۶۶۱۹۸۵۱۴ www.myuptodate.com دریافت آخرین نسخه آپتودیت آفلاین

1M03

Key word: Characteristics of Lymphatic Malformation of the Skin

Author: Michele A. Manahan, MD
Editor: Anthony P. Tufaro, DDS, MD, FACS

Which of the following is a characteristic of a cutaneous lymphatic malformation?

(A) Bluish mass with overlying telangiectasias
(B) Cystic mass with overlying vesicles
(C) Firm, nodular mass
(D) Irregular mass fixed to the underlying tissues
(E) Pulsatile ballotable mass

Answer: (B) Cystic mass with overlying vesicles

Rationale:
Cutaneous lymphatic malformations often present as cystic masses with overlying vesicles. A lymphatic mass would not be associated with telangiectasias, it would not be nodular or pulsatile, and it would not be fixed to underlying tissues.

Reference:
Mulliken J. Vascular anomalies. In: Aston SJ, Beasley RW, Thorne CHM, eds. *Grabb and Smith's Plastic Surgery.* 5th ed. Philadelphia, PA: Lippincott-Raven; 1997:199.

1M04

Key word: Treatment of Inadvertent Intraoperative Ureteral Injury

Author: Eric S. Weiss, MD, MPH
Editor: Arthur L. Burnett, MD, MBA, FACS

During resection of a pelvic tumor, the left ureter is inadvertently transected below the level of the pelvic brim. The *immediate* treatment of this problem is:

(A) Delayed repair and percutaneous drainage of urinoma
(B) Diversion with ureteroenterostomy
(C) Primary repair
(D) Primary repair with ureteral stent
(E) Ureterocystostomy

Answer: (E) Ureterocystostomy

Rationale:
Ureteral injuries are a common and feared complication of pelvic surgery. The common ways that ureters are injured include crushing injury by inadvertent clamping, electrocautery injury, and inadvertent resection as part of a specimen. In cases where the ureter is ligated, pressure hydronephrosis develops which can lead to urosepsis. In addition, the pressure can lead to necrosis of the remaining ureteral wall, which can rupture and allow urine to freely extravasate into the abdomen leading to urinoma formation.

The treatment of ureteral injury depends on the injury type. For minor injuries, where there is a partial transection, the ureter can be closed primarily over a stent. For complete transections, in which the ureter is completely transected, primary closure (ureteroureterostomy) should be attempted. In cases of injury below the pelvic brim, ureteroureterostomy can be difficult and a ureterocystostomy is the procedure of choice to re-establish continuity with the urinary tract.

Reference:
Wessells H, McAninch JW. Injuries to the urogenital tract. In: Souba WW, Fink MP, Jurkovich GJ, Kaiser LR, Pearce WH, Pemberton JH, Soper NJ, eds. *ACS Surgery: Principles and Practice.* 4th ed. New York, NY: WebM.D.; 2004:962–964.

۰۲۱-۶۶۱۹۸۵۱۴ www.myuptodate.com دریافت آخرین نسخه آپتودیت آفلاین

1M05

Key word: Nerve Injury Resulting from Calf Fasciotomy

Author: Robert A. Meguid, MD, MPH
Editor: Anthony P. Tufaro, DDS, MD, FACS

A 32-year-old male is brought to the emergency department after his left leg was pinned between two cars. Upon examination, his left leg is swollen and tense below the knee and you suspect compartment syndrome. Which nerve is most commonly injured during fasciotomy of the lower leg?

(A) Deep peroneal nerve
(B) Lateral femoral cutaneous nerve
(C) Saphenous nerve
(D) Superficial peroneal nerve
(E) Tibial nerve

Answer: (D) Superficial peroneal nerve

Rationale:
Fasciotomy of the four compartments of the lower leg may be performed through one or two skin incisions, although the two-incision technique is more common. The lateral incision is placed 2 cm anterior to the head of the fibula. Through this incision, the anterior and lateral compartments are released. The second incision is placed 2 cm posterior to the posterior medial edge of the tibia, releasing the superior and deep posterior compartments. Both incisions should span the length of the leg. The correct placement of these two incisions will leave an 8- to 10-cm skin bridge that will be unlikely to necrose.

Injury to the superficial peroneal nerve may occur while performing the lateral fasciotomy, as this nerve travels relatively superficially along the fascia between the anterior and lateral compartments.

The tibial and deep peroneal nerves are both deep to the incisions needed for fascial release, and less likely to be transected. The saphenous nerve travels along the lateral border of the tibia, and as such runs parallel and anterior to the posterior skin incision. The lateral femoral cutaneous nerve innervates the lateral aspect of the thigh.

References:
Blackbourne LH. Surgical anatomy. In: Fleischer KJ, ed. *Advanced Surgical Recall.* Philadelphia, PA: Williams and Wilkins; 1995: 47.
Netter FH. *Atlas of Human Anatomy.* 2nd ed. Plates 481–487. East Hanover, NJ: Novartis; 1997.
Shackford SR, Rich NH. Peripheral vascular injury. In: Feliciano DV, Moore EE, Mattox KL, eds. *Trauma.* 3rd ed. Stamford, CT: Appleton and Lange; 1996:841.

1M06

Key word: Treatment of Squamous Cell Carcinoma of the Lower Lip

Author: Robert A. Meguid, MD, MPH
Editor: Anthony P. Tufaro, DDS, MD, FACS

A 56-year-old man presents to your clinic with a 5-mm wide lesion confined to the middle of his lower lip. Biopsy confirms squamous cell carcinoma. What is the most appropriate management?

(A) Radiation therapy alone
(B) Radiation therapy followed by surgical resection with 5-mm margin and primary repair
(C) Surgical resection with 1-cm margin and primary repair
(D) Surgical resection with 1-cm margin and primary repair, followed by radiation therapy
(E) Surgical resection with 5-mm margin and primary repair

Answer: (C) Surgical resection with 1-cm margin and primary repair

Rationale:
Surgical resection alone is appropriate for management of T1 lesions on the lips. However, radiation therapy alone has an equal outcome. A 1-cm margin should be taken and primary repair performed. Five-year survival is greater than 90%. If a T1 lesion is located in the labial commissure (corner of the lips), it can be treated with resection and immediate reconstruction. Radiation may be used as the sole modality of treatment for commissural lesions but presents unique challenges.

T2 and greater stage lesions on the lips should be treated with surgical excision and immediate reconstruction, followed by radiation therapy.

Of note, mental nerve invasion is associated with lymph node involvement in 80% of cases. The 5-year survival for these is 35%.

Staging of oral cavity tumors:
Primary Tumor (T) stage:
Tis: Carcinoma in situ
T1: Tumor ≤2 cm
T2: Tumor >2 cm but ≤4 cm
T3: Tumor >4 cm
T4: Tumor invading adjacent structures

۰۲۱-۶۶۱۹۸۵۱۴ www.myuptodate.com دریافت آخرین نسخه آپتودیت آفلاین

American Joint Committee on Cancer Staging System for Head and Neck Cancers

Stage Grouping	
Stage I	T1, N0, M0
Stage II	T2, N0, M0
Stage III	T3, N0, M0
	T1–T3, N1, M0
Stage IV	T4, N0 or N1, M0
	Any T, N2 or N3, M0
	Any T, any N, M1
Primary Tumor (T) Dependent on Anatomic Location	
Regional Lymph Nodes (N)	
N0	No regional lymph node metastasis
N2a	Metastasis in single ipsilateral lymph node >3 cm but <6 cm
N2b	Metastasis in multiple ipsilateral lymph nodes, none >6 cm
N2c	Metastasis in bilateral or contralateral lymph nodes, none >6 cm
N3	Metastasis in a lymph node >6 cm
Metastatic Disease	
M0	No evidence of distant metastasis
M1	Evidence of distant metastasis

Adapted from: Edge SB, Byrd DR, Compton CC, eds. *AJCC Cancer Staging Manual.* 7th ed. New York, NY: Springer, 2010.

Reference:

Newkirk KA, Holsinger FC. Cancers of the head and neck. In: Feig BW, Ching CD, eds. *The M.D. Anderson Surgical Oncology Handbook.* 5th ed. Philadelphia, PA: Lippincott Williams and Wilkins; 2012.

1M07

Key word: Nerve Injury Associated with Anterior Dislocation of the Humerus

Author: Robert A. Meguid, MD, MPH
Editor: Frank J. Frassica, MD

A 17-year-old male presents to the emergency department after a right shoulder injury sustained while playing football. Plain radiographs reveal the humeral head displaced medial to the glenoid fossa. Which nerve is most likely injured in this type of dislocation?

(A) Axillary nerve
(B) Median nerve
(C) Radial nerve
(D) Suprascapular nerve
(E) Sural nerve

Answer: (A) Axillary nerve

Rationale:

Anterior dislocation of the humeral head can occur when force is applied to an abducted arm, further extending it. These are classic "football injuries." Anterior–posterior shoulder radiographs reveal the humeral head displaced inferior to the coracoid process and medial to the glenoid fossa. This injury is associated with tear of the anterior shoulder joint capsule, compression fracture of the humeral head posteriolaterally, and possible damage to the axillary nerve as it is stretched around the humeral neck. Axillary nerve deficit presents as sensory loss over the anterolateral aspect of the proximal shoulder.

Recurrent dislocations should be treated with surgical correction. Posterior dislocation is not associated with a specific nerve injury but with seizures. The sural nerve innervates the posterolateral aspect of the lower leg.

References:

Duthie RB, Hoaglund FT. Orthopaedics. In: Schwartz SI, Shires GT, Spencer FC, eds. *Principles of Surgery.* 5th ed. New York, NY: McGraw-Hill; 1989:1948–1949.
Netter FH. *Atlas of Human Anatomy.* 2nd ed. East Hanover, NJ: Novartis; 1997: plates 443, 445.

۰۲۱-۶۶۱۹۸۵۱۴ www.myuptodate.com دریافت آخرین نسخه آپتودیت آفلاین

1M08

Key word: Donor-site Healing in Split-thickness Skin Grafts

Author: Justin B. Maxhimer, MD
Editors: Paul N. Manson, MD, FACS, Gedge D. Rosson, MD, Anne J.W. Tong, MBBS, and Pablo A. Baltodano, MD

A 32-year-old female requires a split-thickness skin graft after being involved in a car accident. A 12- × 6-cm site is harvested from her lateral thigh and is implanted on her scalp without complications. The healing rate at the donor site is most related to:

(A) Amount of moisture kept on the donor site

(B) Epithelial appendages and thickness of graft

(C) Epithelial appendages and width of the site

(D) Quality of semi-occlusive dressing

(E) Thickness of graft and moisture on donor site

Answer: (B) Epithelial appendages and thickness of graft

Rationale:

Split-thickness skin grafts may be harvested from any surface of the body, but sites should be chosen that are easily concealed in clothing. Common sites include the upper anterior and lateral thigh. The buttocks may be used as a donor site, but the patient may require assistance caring for the wound. The scalp is used for resurfacing areas of the face too large for a full-thickness graft and is especially useful in severe burns with limited donor-site availability. Because of its thickness, scalp skin may be repeatedly harvested with almost no risk of alopecia or subsequent hair growth at the recipient site. For hand wounds, the upper inner arm is a cosmetically appealing donor site.

The donor site also must be dressed appropriately at the conclusion of a skin graft operation. Full-thickness donor sites closed primarily are dressed as are other wounds closed primarily. For split-thickness graft donor sites, achieving hemostasis can be facilitated with the application of a moist gauze containing epinephrine solution.

Donor sites for split-thickness grafts heal spontaneously from epithelial cells remaining in epithelial appendages within the dermis and at the wound edges. Healing begins within 24 hours of harvesting, and the rate of healing is directly proportional to the number of epithelial appendages remaining and inversely proportional to the thickness of graft harvested. When the epidermis has regenerated, it may be reharvested; however, each harvest may remove a portion of dermis that is not regenerated. The initial epithelium that is regenerated is very delicate and is easily disrupted by dressing changes. This is rationale to use a semi-occlusive dressing that does not need to be removed until healing is complete. Finally, hyperpigmentation may persist for many months following donor-site healing, and some individuals may develop hypertrophic scarring or even keloids at the site.

References:

Kilinc H, Sensoz O, Ozdemir R, et al. Which dressing for split-thickness skin graft donor sites? *Ann Plast Surg.* 2001;46(4):409–414.

Petruzzelli GJ, Johnson JT. Skin grafts. *Otolaryngol Clin North Am.* 1994;27(1):25–37.

۰۲۱-۶۶۱۹۸۵۱۴ www.myuptodate.com دریافت آخرین نسخه آپتودیت آفلاین

1M09

Key word: Characteristics of Split-thickness Skin Grafts

Author: Robert A. Meguid, MD, MPH
Editor: Anthony P. Tufaro, DDS, MD, FACS

Which of the following characteristics is an advantage of full-thickness skin grafts (FTSGs) over split-thickness skin grafts (STSGs)?

(A) Appropriate for larger defects

(B) Better for contaminated tissue beds

(C) Better resistance to infection

(D) Less nutritional demand

(E) Lower incidence of contractures

Answer: **(E)** Lower incidence of contractures

Rationale:
FTSGs have the advantage of lower incidence of contractures compared with STSGs. In addition, FTSGs from similar areas as the defect will afford superior color match compared to STSGs. For instance, periauricular skin serves as a close color match for a nasal defect. However, FTSGs have less resistance to infection than STSGs, and are generally less useful for coverage of large areas. Due to the nature of FTSGs, which have a higher nutritional demand and fewer cut vessels with which to absorb nutrients from the wound bed, they require more blood supply than STSGs. STSGs are generally more useful for coverage of larger wounds, bacterial-contaminated surfaces, and granulation bed.

Reference:
Bollinger RR. Autotransplantation. In: Sabiston DC, Lyerly HK, eds. *Textbook of Surgery.* 15th ed. Philadelphia, PA: W.B. Saunders; 1997:497–498.

1M10

Key word: Treatment of Metastatic Ovarian Cancer

Author: Susanna M. Nazarian, MD, PhD
Editor: Anne O. Lidor, MD, MPH

You are performing a laparoscopic cholecystectomy on a 64-year-old woman with a history of cholelithiasis and vague abdominal pain. As you insert the camera through the supraumbilical trocar, you are surprised to find white cake-like tumor spreading from the left pelvis across much of the large intestine. You should:

(A) Perform a biopsy, convert to an open procedure, and perform complete surgical staging

(B) Perform a biopsy, convert to an open procedure, and remove all involved organs

(C) Perform a left oophorectomy

(D) Take a biopsy of the tumor, close, and await the pathology report to plan open surgery

(E) Take a biopsy of the tumor, remove the gallbladder, and finish the case

Answer: **(D)** Take a biopsy of the tumor, close, and await the pathology report to plan open surgery

Rationale:
Ovarian cancer is the number one cause of death from a gynecologic malignancy in North America. Part of this fatality stems from late diagnosis, as most women present only after the cancer has spread well beyond their reproductive systems. Some cases are discovered only incidentally, as in this scenario.

In the setting described, it would be wisest to obtain a biopsy and end the operation. The surgical treatment of metastatic ovarian cancer mandates maximal debulking and possible multiorgan resection, as the extent of surgical debulking directly affects patient curability. For this reason, it is advisable to close the patient and discuss the implications and risks of the treatment, and possibilities such as permanent colostomy. The patient should also be referred to a gynecologic oncologist for primary surgery, as they are more experienced with disease-specific considerations such as the placement of an intraperitoneal port for intraperitoneal chemotherapy.

Intraoperatively, the goal of surgical debulking should be the removal of all visible tumor. If all visible tumor cannot be safely excised, then a surgical objective of leaving no residual tumor nodule measuring >1 cm in maximal diameter should be attempted. For women with advanced-stage epithelial ovarian cancer, overall survival is inversely proportional to the maximal diameter of residual disease, with patients left with no gross residual having the best survival outcome and chance of cure. Radical debulking may entail multiple bowel resections and removal of all pelvic contents *en masse* in an extraperitoneal, ventral-to-dorsal technique: Bladder, uterus, adnexae, and rectosigmoid. Splenectomy, omentectomy, hepatic resection, and diaphragm stripping may be warranted.

۰۲۱-۶۶۱۹۸۵۱۴ www.myuptodate.com دریافت آخرین نسخه آپتودیت آفلاین

Some surgeons advocate second-look procedures to assess for further tumor, although the practice is controversial.

Reference:

Cannistra SA, Gershenson DM, Recht A. Ovarian cancer, fallopian tube carcinoma, and peritoneal carcinoma. In: DeVita VT, Lawrence TS, Rosenberg SA, eds. *Cancer Principles and Practice of Oncology.* 9th ed. Philadelphia, PA: Lippincott, Williams and Wilkins; 2011:1368–1391.

1M11

Key word: Treatment of Syndrome of Inappropriate ADH Secretion (SIADH)

Author: Jonathan A. Forbes, MD
Editor: Martin A. Makary, MD, MPH

A 22-year-old male (65 kg) is seen in the emergency department after a motorcycle accident that resulted in significant head and maxillofacial trauma. Following initial evaluation and stabilization, he is admitted to the intensive care unit with lactated Ringer (LR) solution running at 125 mL/hr. During the first 60 hours of his stay, his urine output gradually declines to 25 mL/hr and his serum sodium drops from 136 to 127 mEq/L. His vital signs remain stable. Urine osmolarity is found to be 548 mOsm/L. Which of the following is the next best intervention?

(A) Add demeclocycline 600 mg BID

(B) Convert his fluids from LR to 3% normal saline

(C) Increase his fluids to maintain urine output >0.5 mL/kg/hr

(D) Start fludrocortisone 0.1 mg QDay

(E) Stop his fluids entirely

Answer: (B) Convert his fluids from LR to 3% normal saline

Rationale:

This young man is suffering from acute onset of the syndrome of inappropriate antidiuretic hormone (ADH) secretion (SIADH). This disorder is characterized by the unsolicited release of ADH independent of the body's usual mechanisms for osmostat regulation. Acute onset of SIADH results in hyponatremia secondary to free water retention. Chronic SIADH results in hyponatremia secondary to free water retention *and* eventual volume expansion and natriuresis. SIADH does not affect the body's ability to regulate sodium handling and intravascular volume.

Treatment of SIADH is centered upon free water restriction and, when necessary, salt administration. Careful monitoring of fluid status, urine output, and serum sodium is essential, such that over- or under-correction does not ensue. In the asymptomatic hyponatremic patient with chronic SIADH, free water restriction is the mainstay of therapy and is often sufficient by itself. In refractory cases of chronic SIADH, daily salt tablets and a loop diuretic (which lowers urine osmolality by direct interference with the countercurrent concentrating mechanism) are often the next best step. In the rare patient with chronic SIADH in whom the aforementioned interventions are not effective, agents that act directly on the collecting tubule to diminish its responsiveness to ADH—including demeclocycline (300 to 600 mg BID) and lithium—are considered.

In both acute and chronic SIADH, it is important to remember that—as a rough approximation—the osmolarity of fluid administered enterally and parenterally must exceed that of the urine for the serum sodium concentration to rise. The trauma patient described above is suffering from acute

۰۲۱-۶۶۱۹۸۵۱۴ www.myuptodate.com دریافت آخرین نسخه آپتودیت آفلاین

onset of SIADH and is dependent on parenteral replacement of electrolytes and fluid. We are told his urine osmolarity is 548 mOsm/L. From this (remembering sodium handling and volume regulation remain intact), we can roughly approximate that the electrolytes he receives in every liter of LR (osmolarity of 274 mOsm/L) will be excreted in approximately 500 mL of urine. Thus, for every liter of LR he receives, he will retain 500 cm^3 of free water at his present level of ADH release. Converting his IVF to 3% normal saline will provide him with 1,026 mOsm of electrolytes (513 mEq each of sodium and chloride) in every liter of fluid he is given. Assuming ADH release and urine osmolarity remain constant, he will excrete this volume of electrolytes in approximately 1,872 cm^3 of fluid. In this manner, he will lose 872 cm^3 of free water with every liter bolus of 3% normal saline he receives and his serum sodium level will rise appropriately.

The presence or absence of neurologic symptoms secondary to hyponatremia and the severity of these symptoms will help to determine the goal rate of correction. Overly rapid correction should be avoided, as it can result in central pontine myelinolysis.

References:

Adrogue HJ, Madias NE. Hyponatremia. *N Engl J Med.* 2000; 342:1581–1589.

Decaux G, Waterlot Y, Genette F, et al. Treatment of the syndrome of inappropriate secretion of antidiuretic hormone with furosemide. *N Engl J Med.* 1981;304:329–330.

Forrest JN, Cox M, Hong C, et al. Superiority of demeclocycline over lithium in the treatment of chronic syndrome of inappropriate secretion of antidiuretic hormone. *N Engl J Med.* 1978;298:173–177.

Rose BD. New approach to disturbances in the plasma sodium concentration. *Am J Med.* 1986;81:1033–1040.

Rose BD, Post TW. *Clinical Physiology of Acid-Base and Electrolyte Disorders.* 5th ed. New York, NY: McGraw-Hill; 2001:729–733.

Verbalis JG. Pathogenesis of hyponatremia in an experimental model of the syndrome of inappropriate antidiuresis. *Am J Physiol.* 1994;267:1617–1625.

1M12

Key word: Treatment of a Supracondylar Fracture of the Humerus in a Child

Author: Eric S. Weiss, MD, MPH
Editor: Frank J. Frassica, MD

The appropriate treatment for an 8-year-old with a completely displaced supracondylar fracture of the humerus (Gartland type III) is:

(A) Closed reduction and immobilization

(B) Closed reduction and internal fixation

(C) Elbow replacement

(D) Intramedullary rod placement

(E) Splinting and immobilization

Answer: (B) Closed reduction and internal fixation

Rationale:

Unlike adults, supracondylar fractures are common in children. A supracondylar fracture is located on the humerus, proximal to the growth plate. Management of these fractures depends on the severity of the injury. The Gartland classification exists for characterization of supracondylar fractures. Specifically, Gartland type I fractures are nondisplaced, Gartland type II fractures are partially displaced, and Gartland type III are totally displaced. For nondisplaced fractures, conservative treatment (casting and immobilization) is sufficient. However, for displaced fractures, closed reduction and percutaneous pin fixation in the operating room is necessary to ensure a proper reduction and stabilization.

Reference:

Moehring HD. Orthopedic surgery. In: Mulholland MW, Lillemoe KD, Doherty GM, Maier RV, Upchurch GR, eds. *Greenfield's Surgery: Scientific Principles & Practice.* 4th ed. Philadelphia, PA: Lippincott Williams and Wilkins; 2006:2030–2032.

۰۲۱-۶۶۱۹۸۵۱۴ www.myuptodate.com دریافت آخرین نسخه آپتودیت آفلاین

1M13

Key word: Most Important Component in the Glasgow Coma Scale

Author: Eric S. Weiss, MD, MPH
Editors: Edward E. Cornwell III, MD, FACS, WACS, FCCM, and Albert Chi, MD

On initial assessment the most important predictor of return of function in a patient with a severe head injury is:

(A) Intracranial pressure greater than 15 mm Hg

(B) Overall Glasgow Coma Scale (GCS) score

(C) Poor eye opening score component of the GCS

(D) Poor motor score component of the GCS

(E) Poor verbal score component of the GCS

Answer: (D) Poor motor score component of the GCS

Rationale:

The GCS was developed in 1974 as a way to assess patients in severe coma. It has subsequently been applied to the initial assessment of head injury in the trauma patient. Although the GCS is used as a prognostic indicator, it is not clear to what degree initial GCS correlates with subsequent return of function. As a result, several studies have considered the prognosis for recovery from neurologic injury sustained in trauma. It has become clear that functional status post injury does not correlate linearly with overall GCS; there is variable improvement independent of initial GCS score. Mortality, however, does appear to correlate with GCS score to some degree. The reason for imperfect correlation is that other factors present in trauma patients can act as confounding variables lowering the GCS unrelated to head injury. These factors include, but are not limited to, hypotension, hypoxemia, and the presence of illicit drugs. When evaluating specific components of GCS, it appears that initial motor function is the best component for predicting postoperative outcome both for survival and functional status. It should be noted that the prognostic ability of even this component alone is imperfect and not absolute. Intracranial pressure measurements do correlate with head injury severity but do not make up part of the *initial* trauma assessment.

Glasgow Coma Scale (GCS)

Eye Opening	
Spontaneous	4
To voice	3
To pain	2
None	1
Verbal Response	
Oriented	5
Confused	4
Inappropriate words	3
Incomprehensible sounds	2
None	1
Motor Response	
Obeys commands	6
Purposeful movement (pain)	5
Withdraw (pain)	4
Flexion (pain)	3
Extension (pain)	2
None	1
GCS Subtotal	3–15

Reprinted with permission from: Bulger EM. Prehospital and resuscitation care. In: Mulholland MW, Lillemoe KD, Doherty GM, Maier RV, Upchurch GR, eds. *Greenfield's Surgery: Scientific Principles & Practice*. 5th ed. Philadelphia, PA: Lippincott Williams & Wilkins; 2011:332.

References:

Teasdale G, Jennett B. Assessment of coma and impaired consciousness: A practical scale. *Lancet.* 1974;2:81–84.

Udekwu P, Kromhout-Schiro S, Vaslef S, et al. Glasgow Coma Scale score, mortality, and functional outcome in head-injured patients. *J Trauma.* 2004;56(5):1084–1089.

۰۲۱-۶۶۱۹۸۵۱۴ www.myuptodate.com دریافت آخرین نسخه آپتودیت آفلاین

1M14

Key word: Treatment of Epidermoid Cancer of Neck Lymph Nodes

Author: Susanna M. Nazarian, MD, PhD
Editor: Anthony P. Tufaro, DDS, MD, FACS

For an oral squamous cell carcinoma with 4-mm depth of invasion without palpable lymph nodes, the appropriate surgical treatment entails:

(A) Excision plus supraomohyoid neck dissection
(B) Local excision alone
(C) Radiation therapy
(D) Radical neck dissection
(E) Sentinel lymph node biopsy using blue dye

Answer: (A) Excision plus supraomohyoid neck dissection

Rationale:
Patients with an oral cavity mucosal lesion of 3 to 5 mm thickness and no palpable lymph nodes have a 30% change of occult nodal disease. These patients should undergo supraomohyoid neck dissection in addition to wide local excision. However, morbidity for this procedure can approach 30%, spurring the development of ultraselective lymphadenectomy. The use of blue dye or technetium-labeled colloid assists in the identification of the sentinel lymph node(s), as in breast cancer surgery or melanoma. The use of sentinal node biopsy to select patients with oral cavity cancer for neck dissection is under investigation.

Reference:
Gallegos-Hernández JF, Hernández-Hernández DM, Flores-Díaz R, et al. The number of sentinel nodes identified as prognostic factor in oral epidermoid cancer. *Oral Oncol.* 2005;41(9):947–952.

1M15

Key word: Optimal Cerebral Perfusion Pressure

Author: Eric S. Weiss, MD, MPH
Editor: David T. Efron, MD, FACS

The cerebral perfusion pressure (CPP) in a patient with head injury should ideally be greater than:

(A) 30 mm Hg
(B) 50 mm Hg
(C) 70 mm Hg
(D) 90 mm Hg
(E) 110 mm Hg

Answer: (C) 70 mm Hg

Rationale:
CPP equals mean arterial pressure (MAP) minus intracranial pressure (ICP). CPP is the main determinant of cerebral blood flow. CPP should be 60 mm Hg to 75 mm Hg, and ICP 20 mm Hg to 25 mm Hg. In traumatic brain injuries, secondary ischemia due to low blood flow is further injurious to the neuronal tissue. For this reason it is vital to keep the CPP at a level adequate for good cerebral perfusion, particularly in the setting of increased ICP. Alternatively, treatments that lower ICP such as maintaining a hyperosmolar state are sometimes beneficial.

Reference:
American College of Surgeons Committee on Trauma. Head trauma. *ATLS: Advanced Trauma Life Support for Doctors (Student Course Manual).* 8th ed. Chicago, IL: American College of Surgeons; 2008.

۰۲۱-۶۶۱۹۸۵۱۴ www.myuptodate.com دریافت آخرین نسخه آپتودیت آفلاین

1M16

Key word: Treatment of Necrotizing Fasciitis

Author: Eric S. Weiss, MD, MPH
Editor: Andrew M. Cameron, MD, PhD

A 78-year-old African American female with hypertension and diabetes mellitus falls in her kitchen and lacerates her right great toe. Three hours later, her family brings her to the emergency department because she has developed severe erythema migrating up her leg, fever to 40°C (104°F), and a marked change in her mental status. Examination of the wound reveals severe edema of the surrounding skin, marked erythema proceeding up the leg, and crepitus to palpation. Her laboratory values show a lactate of 6.7 mmol/L. What is the most appropriate course of treatment?

(A) Gram-negative antibiotic coverage, IV fluid resuscitation, surgical debridement

(B) Gram-positive antibiotic coverage, IV fluid resuscitation, surgical debridement

(C) Immediate surgical debridement, IV fluid resuscitation, broad-spectrum antibiotics

(D) IV fluid resuscitation, broad-spectrum antibiotics, observation

(E) Observation, IV fluid resuscitation, surgical debridement after complete manifestation of disease (days)

Answer: **(C)** Immediate surgical debridement, IV fluid resuscitation, broad-spectrum antibiotics

Rationale:

Necrotizing soft tissue infections are some of the most severe infections encountered in medical practice. Infections generally involve the superficial and deep fascia with mortality rates as high as 40%. Clinical manifestations generally include erythema and necrosis of the infected area, grayish "dishwater" fluid emanating from the wound, blebs, severe pain, and signs of hemodynamic compromise. Early presentation or disease in patients with immunosuppressed states may lack these more overt clinical signs, though often have severe pain out of proportion to examine the findings. Patients with underlying diseases such as diabetes mellitus or malignancy may suffer from necrotizing fasciitis in higher proportions. Infections tend to be polymicrobial in nature with gram-positive organisms such as staphylococci and streptococci (aerobic and anaerobic), gram-negative enteric bacteria, and gram-negative anaerobes being frequently identified.

Early recognition is essential, followed by prompt, aggressive, and extensive surgical debridement to remove all devitalized and infected tissue. In addition, broad-spectrum antibiotics, IV fluid resuscitation, hemodynamic monitoring, and nutritional support afford patients the best chance of survival. Surgical debridement is often mutilating with resection of several centimeters of grossly normal, healthy tissue beyond all signs of infection. Observation of any kind is never appropriate with a suspected necrotizing soft tissue infection.

References:

Dellinger EP. Surgical infections. In: Mulholland MW, Lillemoe KD, Doherty GM, Maier RV, Upchurch GR, eds. *Greenfield's Surgery: Scientific Principles & Practice.* 5th ed. Philadelphia, PA: Lippincott Williams and Wilkins; 2011.

Gibran N. Burns. In: Mulholland MW, Lillemoe KD, Doherty GM, Maier RV, Upchurch GR, eds. *Greenfield's Surgery: Scientific Principles & Practice.* 5th ed. Philadelphia, PA: Lippincott Williams and Wilkins; 2011.

۰۲۱-۶۶۱۹۸۵۱۴ www.myuptodate.com دریافت آخرین نسخه آپتودیت آفلاین

1M17

Key word: Treatment of Parotid Mass

Authors: Benjamin S. Brooke, MD, PhD, and Michele A. Manahan, MD
Editor: Anthony P. Tufaro, DDS, MD, FACS

A 59-year-old healthy female presents complaining of a palpable mass along the junction between the angle of her mandible and neck on the left side. A history and physical examination reveals no other symptoms. An ultrasound study shows a 2-cm mass in the superficial lobe of the parotid gland. A fine-needle aspiration biopsy is performed, which shows a mixture of epithelial and mesenchymal cells consistent with a diagnosis of benign pleomorphic adenoma. How should this parotid mass be managed?

(A) Close observation for change in size or development of symptoms

(B) Radiation therapy

(C) Simple enucleation of the mass

(D) Superficial parotidectomy with adjuvant radiation therapy

(E) Superficial parotidectomy with preservation of the facial nerve

Answer: **(E)** Superficial parotidectomy with preservation of the facial nerve

Rationale:
While salivary gland tumors (parotid, submandibular, and sublingual gland) are relatively uncommon, 75% to 80% are found in the parotid gland. The majority of parotid gland tumors are benign and asymptomatic when diagnosed.

Fine-needle aspiration has 95% sensitivity in detecting salivary gland neoplasms. Parotid duct intubation and sentinel lymph node biopsy do not have roles in initial operative planning for parotid masses. Incisional and excisional biopsies are technically more complicated and have higher risks of negative outcomes than does fine-needle aspiration.

Parotidectomy is the mainstay of treatment for benign tumors, with the location and size of tumor determining the extent of resection. While most tumors can be removed with a superficial parotidectomy, a total parotidectomy is usually necessary if the lesion is deep or cannot be resected with a cuff of normal tissue. Care is taken to not injure or sacrifice the facial nerve during these procedures. Simple enucleation of the tumor is usually not recommended because of the high incidence of local recurrence.

Common Salivary Neoplasms

Benign
Pleomorphic adenoma (benign mixed tumor)
Warthin tumor (papillary cystadenoma lymphomatosum)
Basal cell adenoma
Oncocytoma
Malignant
Mucoepidermoid carcinoma
Adenoid cystic carcinoma
Acinic cell carcinoma
Salivary ductal adenocarcinoma
Carcinoma ex pleomorphic adenoma
Adenocarcinoma NOS

Reprinted with permission from: Miller MC, Moyer JS, Teknos TN. Head and neck. In: Mulholland MW, Lillemoe KD, Doherty GM, Mayer RV, Upchurch GR, eds. *Greenfield's Surgery: Scientific Principles & Practice*. 5th ed. Philadelphia, PA: Lippincott Williams & Wilkins; 2011:615.

Reference:
Miller MC, Moyer JS, Teknos TN. Head and Neck. In: Mulholland MW, Lillemoe KD, Doherty GM, Maier RV, Upchurch GR, eds. *Greenfield's Surgery: Scientific Principles & Practice.* 5th ed. Philadelphia, PA: Lippincott Williams and Wilkins; 2011.

۰۲۱-۶۶۱۹۸۵۱۴ www.myuptodate.com دریافت آخرین نسخه آپتودیت آفلاین

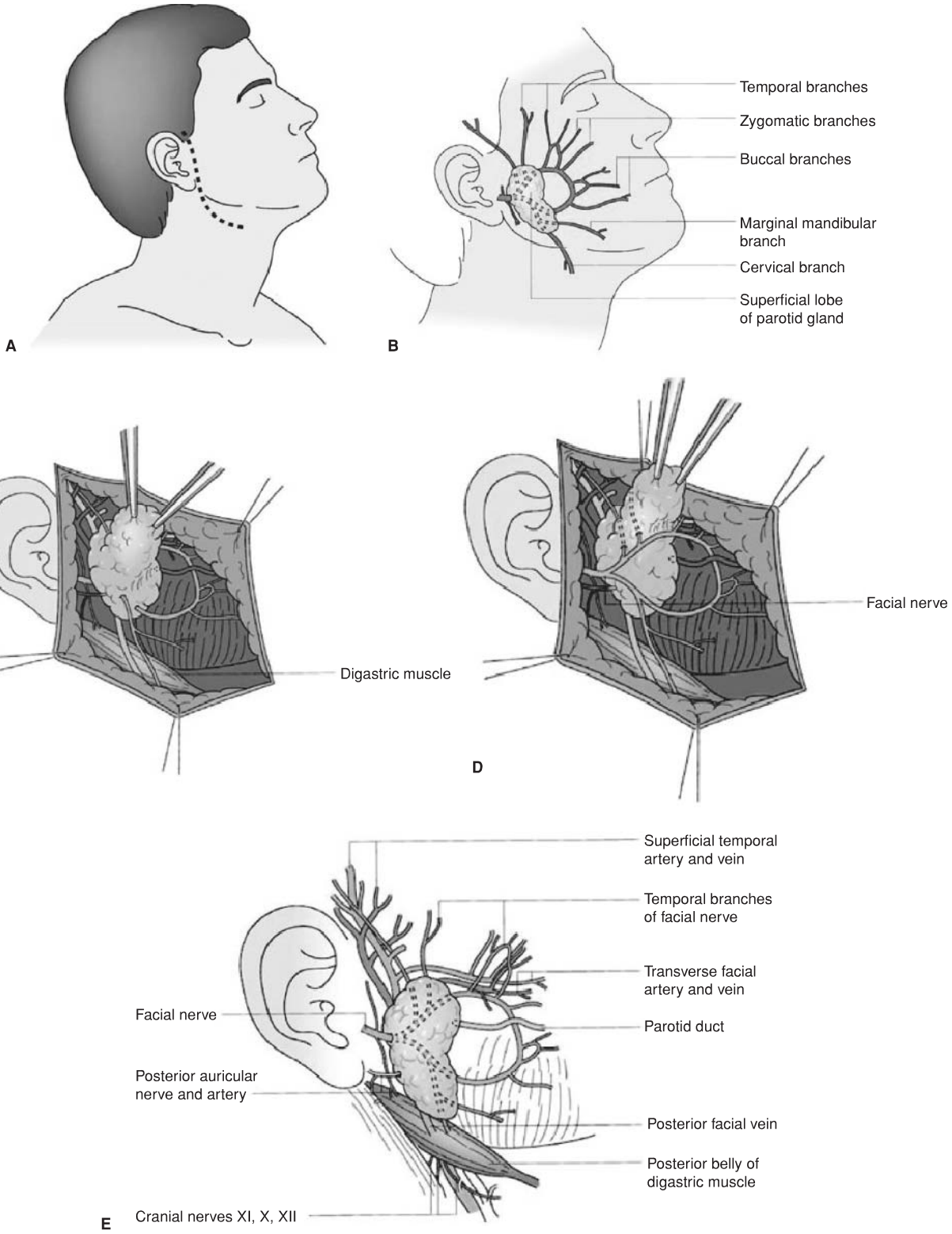

Superficial parotidectomy. **A:** The standard Blair incision or the cosmetically superior rhytidectomy incision may be used. **B:** Branches of the facial nerve course between the superficial and deep lobes of the parotid. **C:** The main trunk of the facial nerve is identified 8 mm deep to the tympanomastoid suture line and at the same level as the digastric muscle. **D:** The nerve is then dissected distally, separating it from the substance of the parotid. **E:** Schematic representation of the relationship between the parotid and surrounding structures. Reprinted with permission from: Miller MC, Moyer JS, Teknos TN. Head and neck. In: Mulholland MW, Lillemoe KD, Doherty GM, Maier RV, Upchurch GR, eds. *Greenfield's Surgery: Scientific Principles & Practice*. 5th ed. Philadelphia, PA: Lippincott Williams & Wilkins; 2011:616.

۰۲۱-۶۶۱۹۸۵۱۴ www.myuptodate.com دریافت آخرین نسخه آپتودیت آفلاین

1M18

Key word: Treatment of Buccal Squamous Cell Carcinoma

Authors: Robert A. Meguid, MD, MPH, and Susanna M. Nazarian, MD, PhD
Editor: Anthony P. Tufaro, DDS, MD, FACS

A 57-year-old woman presents with a biopsy-proven 4.5-cm buccal mucosa squamous cell carcinoma (SCC) of her right cheek, with no lymph nodes palpable or visible on computed tomography. What is the most appropriate management?

(A) Local excision

(B) Radiation therapy

(C) Wide resection with modified radical neck dissection and postoperative radiation

(D) Wide resection with radical neck dissection

(E) Wide resection with supraomohyoid neck dissection

Answer: (E) Wide resection with supraomohyoid neck dissection

Rationale:

SCC of the buccal mucosa comprises only 10% of all oral SCCs. In Western Europe and the United States, smoking and alcohol are the prime risk factors for SCC of the buccal mucosa, whereas betel nuts are a cause of much of the disease in Southeast Asia.

Staging for buccal SCC follows that for other head and neck cancers, with a tumor more than 4 cm in greatest dimension representing a T3 lesion. Combined with a clinically negative neck, the patient in this scenario is stage III.

Treatment is based on staging, with stage I to stage II buccal SCC treated with local excision (0.5- to 1-cm margins). More advanced SCC warrants local resection with locoregional neck dissection in the event of a clinically negative neck (N_0 neck), as in this scenario. Therapeutic neck dissection is indicated for clinically palpable lymph nodes (N+ neck). A supraomohyoid neck dissection includes levels I, II, and III: the submental and submandibular lymph nodes, upper jugular lymph nodes, and middle jugular lymph nodes respectively.

Postoperative radiation is indicated for patients who do not undergo a neck dissection, those with multiple lymph node metastases, and those with extranodular spreading. In addition, postoperative radiation may be helpful to those with perineural or perivascular growth.

See staging table from 1M06.

References:

Coppen C, de Wilde PC, Pop LA, et al. Treatment results of patients with a squamous cell carcinoma of the buccal mucosa. *Oral Oncol.* 2006;42(8):795–799.

Iseli TA, Rosenthal EL. Skin lesions: Evaluation, diagnosis, and management. In: Cameron JL, Cameron AM, eds. *Current Surgical Therapy.* 10th ed. Philadelphia, PA: Mosby; 2011: 621–625.

Newkirk KA, Holsinger FC. Cancers of the head and neck. In: Feig BW, Ching CD, eds. *The M.D. Anderson Surgical Oncology Handbook.* 5th ed. Philadelphia, PA: Lippincott Williams and Wilkins; 2012.

Patel SG, Shah JP. TNM staging of the head and neck: striving for uniformity among diversity. *CA Cancer J Clin.* 2005;55:242–258.

Sabel MS, Johnson TM, Bichakjian CK. Cutaneous neoplasms. In: Mulholland MW, Lillemoe KD, Doherty GM, Maier RV, Upchurch GR, eds. *Greenfield's Surgery: Scientific Principles & Practice.* 5th ed. Philadelphia, PA: Lippincott Williams and Wilkins; 2011.

۰۲۱-۶۶۱۹۸۵۱۴ www.myuptodate.com دریافت آخرین نسخه آپتودیت آفلاین

1M19

Key word: Diagnostic Test for a Solitary Neck Mass

Author: Eric S. Weiss, MD, MPH
Editors: Paul N. Manson, MD, FACS, Gedge D. Rosson, MD, and Pablo A. Baltodano, MD

A 58-year-old man presents with an asymptomatic right anterior neck mass in the thyroid region. What is the most appropriate diagnostic test for this man?

(A) Exploratory surgery
(B) Fine-needle aspiration (FNA)
(C) History and physical examination
(D) Scintigraphy
(E) Ultrasound

Answer: (B) Fine-needle aspiration (FNA)

Rationale:
The most common solitary anterior neck mass is a thyroid nodule. The first step in the workup of any solitary neck mass is to perform a complete history and physical examination. Key aspects include age, history of radiation treatment, stridor, unintentional weight loss, family history, and dysphagia. In addition, thyroid function tests should be ordered including a serum TSH concentration. FNA biopsy remains the initial diagnostic test of choice for solitary thyroid masses, and serves several functions. First, it allows the examiner to determine if a solid or cystic mass is present. Second, cytologic evaluation of the tissue allows determination of malignant status. When nodules are suspicious for neoplasm, scintigraphy can be further performed to assess for malignancy properties. Functional nodules are rarely malignant. When neck masses are present that do not appear to originate from the thyroid gland, a CT scan can also be useful for diagnosis.

Reference:
McIntyre RC, Haugen BR. Thyroid nodule. In: Norton LW, Eiseman B, Stiegmann GV, eds. *Surgical Decision Making.* 4th ed. Philadelphia, PA: W.B. Saunders Company; 2000: 218–219.

1M20

Key word: Treatment of Rectal Bleeding after Laminectomy

Author: Susanna M. Nazarian, MD, PhD
Editor: Frank J. Frassica, MD

A 58-year-old woman is experiencing bright red rectal bleeding after undergoing a lumbar laminectomy 3 days ago. She has been stable and was transferred out of the intensive care unit the morning following her surgery, but she continues to report a significant amount of back pain. What is the most likely etiology of her rectal bleeding?

(A) Constipation
(B) Injury to the median sacral artery during surgery
(C) Injury to the middle rectal artery during surgery
(D) Injury of the sacral plexus during surgery
(E) Rectal cancer

Answer: (A) Constipation

Rationale:
Heavy narcotic use, often associated with spinal surgery, can lead to constipation and anal fissures from straining. Patients should be administered a stool softener along with narcotics to prevent this complication.

Once a patient is experiencing constipation, adequate hydration should be ensured. Although effective, suppositories are contraindicated if the patient is experiencing rectal bleeding secondary to anal fissures. Laxatives such as magnesium citrate increase the water content in stool via an osmotic effect. The polysaccharides lactulose and sorbitol function similarly. Caution should be exercised in administering these agents in the postoperative setting, as they can promote bloating, flatulence, and fluid loss. Bisacodyl and senna promote peristalsis of the colon by stimulating parasympathetic nerves.

Other drugs that can lead to delayed transit of feces include anticholinergics, calcium- or aluminum-based compounds, iron, anticonvulsants, antidepressants, antihistamines, barium, bismuth, medications for Parkinson disease, muscle relaxants, and psychotropic drugs. A patient who suffered arterial or nerve injuries during surgery would have presented much earlier with hematomas, bowel ischemia, or corresponding deficits.

Rectal bleeding demands digital and anoscopic examination to rule out tumors. However, a more likely etiology of the bleeding in this scenario is bleeding from anal fissures or hemorrhoids.

References:
Keighley MRB. Functional bowel disorders. In: Fischer JE, Bland KI, eds. *Mastery of Surgery.* 5th ed. Philadelphia, PA: Lippincott Williams and Wilkins; 2007:1638.
Micromedex, Bisacodyl. http://www.micromedexsolutions.com/micromedex2/librarian/ Accessed March 1, 2013.
Wick EC. Colonic and rectal anatomy and physiology. In: Mulholland MW, Lillemoe KD, Doherty GM, Maier RV, and Upchurch GR, eds. *Greenfield's Surgery: Scientific Principles & Practice.* 5th ed. Philadelphia, PA: Lippincott Williams and Wilkins; 2011.

۰۲۱-۶۶۱۹۸۵۱۴ www.myuptodate.com دریافت آخرین نسخه آپتودیت آفلاین

1M21

Key word: Treatment of Penetrating Renal Trauma

Author: Robert A. Meguid, MD, MPH
Editor: Arthur L. Burnett, MD, MBA, FACS

A 24-year-old male is brought to the emergency room after being stabbed in the right flank. Urine is grossly positive for blood, and computed tomography (CT) shows contrast extravasation from the superior pole of the right kidney. Operative exploration confirms cortical injury, but no injury is noted to the hilum or pelvis. How should this kidney be managed?

(A) Debride devitalized tissue and repair it primarily
(B) Divert the right ureter to the left ureter
(C) Perform a partial right nephrectomy
(D) Perform a right nephrectomy
(E) Washout and pack the right kidney

Answer: (A) Debride devitalized tissue and repair it primarily

Rationale:
Renal trauma is divided into minor and major injuries to the kidney. Minor injuries are subclassified into (1) contusion of the parenchyma, (2) shallow laceration of the cortex, and (3) forniceal disruption. Major injuries are subclassified as (1) injury to the renal pedicle, (2) injury to the renal pelvis or ureter, (3) deep injury of the parenchyma with intact capsule, (4) deep injury of the parenchyma with disrupted capsule, (5) shattered kidney with intact capsule, and (6) shattered kidney with disrupted capsule.

Management of trauma to the kidney, blunt or penetrating, is dictated by the intent to preserve the affected kidney and maintain renal function. If possible, preoperative arteriography should be obtained. In the operating room, vascular pedicle control should be obtained before opening Gerota capsule.

Hilar injuries usually necessitate nephrectomy. Injury to the renal pelvis or proximal ureter should be debrided and attempts made for primary repair. Devitalized, nonfunctional renal segments should be debrided, but any vascularized functional tissue should be preserved if possible. Therefore, in the example given, a partial or total nephrectomy should be avoided, and the injured tissue debrided and repaired primarily.

Of note, almost all renal injuries due to gunshot wounds are associated with concomitant intra-abdominal injuries (90% to 100%), and most due to stab wounds as well (60% to 75%). Eighty-five percent of renal injuries are minor and may be managed expectantly. Ten percent of renal injuries require immediate operative intervention due to extensive hemorrhaging. Sequelae of these injuries include late bleeding, hypertension, abscess formation, and secondary nephrectomy. Five percent of renal injuries fall in between clear indications for either immediate operative intervention or observation, and may be managed either operatively or nonoperatively, including angiographic embolization.

Reference:
Jurkovich GJ, Carrico CJ. Trauma. In: Sabiston DC, Lyerly HK, eds. *Textbook of Surgery.* 15th ed. Philadelphia, PA: W.B. Saunders; 1997:328–329.

1M22

Key word: Inhibition of Keloid Formation

Author: Robert A. Meguid, MD, MPH
Editors: Paul N. Manson, MD, FACS, Gedge D. Rosson, MD, Anne J.W. Tong, MBBS, and Pablo A. Baltodano, MD

A 24-year-old African American woman presents to your clinic for excision of a suspicious skin lesion on her chest. She reports a history of keloid formation, as evidenced by a hypertrophic midline incision for a cesarean section 6 months ago. Which of the following techniques has the most favorable results for inhibiting keloid formation?

(A) Intralesional steroid injection following keloid excision
(B) Radiotherapy following keloid excision
(C) Tissue necrosis factor-alpha (TNF-α) injection following keloid excision
(D) Tocopherol (Vitamin E) topical application following keloid excision
(E) Tretinoin ointment application following keloid excision

Answer: (A) Intralesional steroid injection following keloid excision

Rationale:
Keloids are the abnormal development of scar tissue that projects beyond the original wound margins. Keloids should be distinguished from hypertrophic scars, which are raised and thick but do not grow beyond the margins. Hypertrophic scars are much less likely to recur after surgical excision than keloids. Inherited in an autosomal dominant manner, keloids are seen most commonly in darkly pigmented patients and occur 5% to 10% of the time following injury of the dermis. Keloids and other hypertrophic scars are characterized by excess production of fibroblast-derived extracellular matrix proteins, especially collagen, exceeding the activity of collagenase. Scars develop within 6 to 8 weeks of reepithelialization, maturing at 6 to 18 months. Avoidance of scar formation is ideal, especially in the above-mentioned at-risk patients.

Intralesional corticosteroid injection, following surgical excision (if scars already exist), is considered the most typical first-line therapy for keloids. Initial injections into the healing wound are made either intraoperatively or at the time of suture removal, followed by weekly injections for 2 to 5 weeks, and subsequently monthly injections for 4 to 6 months. Response is between 92% and 95%, and recurrence rates range from 9% to 50%. The mechanism of effect is thought to be via inhibition of leukocyte and monocyte migration, vasoconstriction of the wound bed, and inhibition of keratinocyte and fibroblast proliferation. Side effects of steroid injection include pain from injection, hypopigmentation of scars, skin atrophy, and rebound effects from steroid use. Of note, the recurrence rate after surgical excision alone has been reported to be between 45% and 100%.

Silicone gel application to healing wounds has been found to decrease hypertrophic scar recurrence. Silicone gel sheets or silicone gel itself are applied to wounds 2 weeks after healing begins, and left on for 12 to 24 hours until scar maturation occurs. While these help prevent hypertrophic scarring, they

۰۲۱-۶۶۱۹۸۵۱۴ www.myuptodate.com دریافت آخرین نسخه آپتودیت آفلاین

can result in widened and atrophic scars. No level I studies support silicone gel application for hypertrophic scars.

The standard of care for treatment of hypertrophic scars at many burn centers is currently pressure therapy. Elastic garments are used to apply pressure to wounds to both prevent and treat hypertrophic scars. However, the evidence to support their use is controversial and largely based on anecdote and case study. No level I or II studies support pressure therapy for hypertrophic scars.

While thought to be promising, laser therapy for destruction of hypertrophic scars is associated with high recurrence rates. Likewise, radiotherapy as an alternative to steroid injection has met with mixed results, but can be valuable for patients who have failed prior excision attempts.

TNF-α is experimental therapy, used in the treatment of melanoma. Tretinoin is a Vitamin A preparation used to treat acne. Tocopherol, or Vitamin E, has been anecdotally used to minimize scar formation after surgery, in topical preparations. However, at present, no conclusive evidence exists to support the use of Vitamin E for treatment of hypertrophic scars or keloids.

While true keloids recur in up to 100% of cases, the two most common, standard treatments that have been demonstrated to have reasonable efficacy are steroid injection following surgical excision, and silicone gel sheet application prior to keloid formation. Some recent studies have demonstrated the potentially positive effects of topical or intralesional antineoplastic agents, such as interferon, bleomycin, mitomycin C, and 5-fluorouracil. Unfortunately, molecular mechanisms behind keloid development and treatment effect are still poorly understood, and this topic should be considered in evolution.

References:

Atiyeh BS. Nonsurgical management of hypertrophic scars: evidence-based therapies, standard practices, and emerging methods. *Aesthetic Plast Surg.* 2007;31:468–492.

Donkor P. Head and neck keloid: treatment by core excision and delayed intralesional injection of steroid. *J Oral Maxillofac Surg.* 2007;65:1292–1296.

Durani P, Bayat A. Levels of evidence for the treatment of keloid disease. *J Plast Reconstr Aesthet Surg.* 2008;61(1):4–17.

Jalali M, Bayat A. Current use of steroids in management of abnormal raised skin scars. *Surgeon.* 2007;3:175–180.

Robles DT, Berg D. Abnormal wound healing: keloids. *Clin Dermatol.* 2007;25:26–32.

Shridharani SM, Magarakis M, Manson PN, et al. The emerging role of antineoplastic agents in the treatment of keloids and hypertrophic scars: a review. *Ann Plast Surg.* 2010;64(3):355–361.

1M23

Key word: Treatment of Pelvic Fractures

Author: Robert A. Meguid, MD, MPH
Editor: Frank J. Frassica, MD

A 23-year-old male pedestrian is brought to the emergency department after he was pinned between a truck and a telephone pole. He complains of infraumbilical, pelvic, and hip pain. Pelvic plain radiographs reveal an open-book fracture with bilateral sacroiliac dislocation. Which of the following is the most appropriate initial management of this patient?

(A) External fixation of the pelvis when he becomes hemodynamically unstable

(B) Immediate open reduction and internal fixation while he is hemodynamically stable

(C) Immediate placement of two 16-gauge peripheral IVs

(D) Nonoperative management of the pelvic fracture, with extended bed rest while he is hemodynamically stable

(E) Placement of a pneumatic antishock garment when he becomes hemodynamically unstable

Answer: (C) Immediate placement of two 16-gauge peripheral IVs

Rationale:

When a trauma patient has the combination of a pelvic fracture and hemodynamic instability, it is paramount that the source of bleeding is rapidly determined. Active external, intraperitoneal, or intrapleural bleeding must be controlled prior to contained bleeding into the retroperitoneum, extremities, or retropleural space. Management is always initiated by obtaining large-bore IV access, bolus administration of intravenous crystalloid fluid, and obtaining type O negative packed red blood cells, fresh frozen plasma, and platelets for possible transfusion.

Following this, the major source of hemorrhage must be identified. Pelvic fractures with possible pelvic hemorrhage often result in intra-abdominal hemorrhage as well. After ruling out external and intrathoracic hemorrhage, intraperitoneal and retroperitoneal bleeding must be considered. This can be accomplished by performing a deep peritoneal lavage (DPL) supraumbilically or more commonly today, a focused abdominal sonogram for trauma (FAST) examination. Angiography may be both diagnostic and therapeutic (via embolization of bleeding pelvic vessels) but may not be possible immediately.

Operative intervention is indicated if the patients demonstrate hemodynamic instability that does not respond to aggressive resuscitation methods, if angiography is unsuccessful at controlling arterial bleeding, if the source of bleeding is venous or cancellous bone, and/or in the presence of an open pelvic fracture.

While external fixation of the pelvis (or application of a pneumatic antishock garment) is recommended by some to control fracture-related hemorrhage, it may delay angiography and limit the surgeon's ability to adequately place the

۰۲۱-۶۶۱۹۸۵۱۴ www.myuptodate.com دریافت آخرین نسخه آپتودیت آفلاین

appropriate incisions for open reduction and internal fixation of the pelvic fractures.

Hemodynamically stable patients should undergo elective open reduction and internal fixation within 3 to 10 days of the injury, after they have been fully resuscitated and had a thorough and complete trauma evaluation. Unstable pelvic fractures, including those with sacroiliac dislocation, are best managed with operative treatment. Temporary stabilization is done with a pelvic binder in the emergency room.

Reference:

Cryer HG, Johnson E. Pelvic fractures. In: Feliciano DV, Moore EE, Mattox KL, eds. *Trauma.* 3rd ed. Stamford, CT: Appleton and Lange; 1996:635–660.

1M24

Key word: Prophylaxis against Venous Thrombosis

Author: Bonnie E. Lonze, MD, PhD
Editors: James H. Black III, MD, FACS, and Christopher J. Abularrage, MD

Current guidelines for prophylaxis against venous thromboembolism call for risk stratification before determining a prophylaxis strategy for a particular patient. The group of patients with the highest risk for venous thromboembolism includes those undergoing hip arthroplasty, major trauma, spinal cord injury, and those with a history of prior venous thromboembolism. What is the approximate incidence of deep venous thrombosis (DVT) in this group of patients?

(A) 1% to 10%

(B) 10% to 20%

(C) 40% to 50%

(D) 50% to 60%

(E) 70% to 80%

Answer: **(B)** 10% to 20%

Rationale:

Venous thromboembolism is one of the most common postoperative complications observed in surgical patients. The overall incidence of DVT in surgical patients varies widely based on the method of study and the patient population evaluated. The American College of Chest Physicians devised a widely accepted risk stratification system, grouping patients into low, moderate, high, and highest risk for venous thromboembolism. Factors that contribute to a particular patient's risk include the following: Age, type of surgery, trauma, spinal cord injury, immobilization, history of previous venous thromboembolism, malignancy, hypercoagulable state (including pregnancy or thrombophilia), and obesity. The approximate risk of proximal venous thromboembolism without thromboprophylaxis stratified by category is:

- Low risk (young patient, minor surgery): 0.4%
- Moderate risk (older patient, minor surgery or young patient, minor surgery): 2% to 4%
- High risk (older patient, major surgery): 4% to 8%
- Highest risk (major trauma, spinal cord injury, hip/knee arthroplasty, hip fracture surgery, patients with malignancy, thrombophilia, or history of prior venous thromboembolism): 10% to 20%

The risk in postoperative patients without prophylaxis is even more staggering when considering venous thromboembolism in any location, not just those that are proximally located.

- Low risk <10%
- Moderate risk 10% to 40%
- High risk 40% to 80%

The recommendations for the method of prophylaxis are also based on the risk stratification system. Nonpharmacologic methods such as early ambulation, compression

۰۲۱-۶۶۱۹۸۵۱۴ www.myuptodate.com دریافت آخرین نسخه آپتودیت آفلاین

stockings, and pneumatic compression devices are generally sufficient for low-risk patients. For moderate and high-risk patients, a combination of nonpharmacologic and pharmacologic methods such as low-dose unfractionated heparin is recommended. For highest-risk patients, low-molecular-weight heparin and occasionally warfarin are recommended.

References:

Geerts WH, Bergqvist D, Pineo GF, et al. Prevention of venous thromboembolism: American College of Chest Physicians evidence-based clinical practice guidelines (8th edition). *Chest.* 2008;133:381S–453S.

Kaboli P, Henderson MC, White RH. DVT prophylaxis and anticoagulation in the surgical patient. *Med Clin North Am.* 2003;87:77–110.

1M25

Key word: Characteristics of Sentinel Lymph Node Biopsy

Authors: Michele A. Manahan, MD, and Robert A. Meguid, MD, MPH
Editors: Julie R. Lange, MD, ScM, FACS, and Mehran Habibi, MD, MBA

A 74-year-old former gardener presents with a suspicious, irregular mole on his left upper arm. Of note, there is no evidence of ulceration. Which of the following scenarios would warrant a sentinel lymph node biopsy?

(A) 0.5-mm thick melanoma of the arm with no clinical nodal metastases

(B) 0.8-mm thick melanoma of the arm with ulceration with no clinical nodal metastases

(C) 2-mm thick melanoma of the arm with axillary lymphadenopathy

(D) 3-mm thick melanoma of the arm with pulmonary metastases

(E) 4.5-mm thick melanoma of the arm with known metastasis to the brain

Answer: **(B)** 0.8-mm thick melanoma of the arm with ulceration with no clinical nodal metastases.

Rationale:

The goal of sentinel lymph node biopsy is to improve accuracy of disease staging, in order to more appropriately determine treatment. Sentinel lymph node biopsy is recommended for melanomas ≥1 mm thick without clinical evidence of regional nodal involvement or distant metastases. Sentinel node biopsy can also be considered for melanomas <1 mm in thickness if the primary site shows histologic ulceration, a deep Clark level, or has an elevated mitotic rate.

References:

Balch CM, Houghton AN, Sober AJ, et al. *Cutaneous Melanoma.* 3rd ed. St. Louis, MO: Quality Medical Publishing; 1998:229.

Balch CM, Cascinelli N. Sentinel-node biopsy in melanoma. *N Engl J Med.* 2006;355(13):1370–1371.

Morton DL, Thompson JF, Cochran AJ. et al. Sentinel-node biopsy or nodal observation in melanoma. *N Engl J Med.* 2006;355(13):1307–1317. Erratum in: New England Journal of Medicine. 2006 Nov 2;355(18):1944.

۰۲۱-۶۶۱۹۸۵۱۴ www.myuptodate.com دریافت آخرین نسخه آپتودیت آفلاین

1M26

Key word: Poorest Prognosis in Cerebral Trauma

Author: Jonathan A. Forbes, MD
Editor: David T. Efron, MD, FACS

A 58-year-old woman is rushed to the emergency department following an explosion in her basement that resulted in a shower of metallic shrapnel and multiple penetrating injuries. Her Glasgow Coma Scale (GCS) on arrival is 8. Noncontrast computed tomography (CT) of the head reveals one of the metallic fragments to have penetrated the inner table of the skull. Which of the following characteristics of this scenario portends the poorest prognosis, given her preresuscitation GCS score?

(A) Age >55
(B) Blast injury
(C) Female gender
(D) Penetrating mechanism of injury
(E) Time of transportation

Answer: (D) Penetrating mechanism of injury

Rationale:
In a study published in 2004, Demetriades et al. evaluated 7,764 head injuries over the course of a 10-year period in an attempt to identify characteristics influencing mortality following head trauma. They found that the prognostic value of GCS was altered significantly in certain situations. Specifically, given identical preresuscitation GCS scores:

1. Individuals whose mechanism of head injury was penetrating in nature were 4.8 times as likely to die as those who had experienced blunt head injury.
2. Individuals older than the age of 55 were 3.3 times as likely to die as those under the age of 55.
3. Individuals of female gender were 1.5 times likely to die as those of male gender.

Thus, **(D)** is the correct answer.

Reference:
Demetriades D, Kuncir E, Murray J, et al. Mortality prediction of head Abbreviated Injury Score and Glasgow Coma Scale: Analysis of 7,764 head injuries. *J Am Coll Surg.* 2004;199:216–222.

1M27

Key word: Anatomy of the Right Renal Artery

Author: Robert A. Meguid, MD, MPH
Editor: Arthur L. Burnett, MD, MBA, FACS

Which of the following statements is correct regarding the anatomy of the renal vasculature?

(A) The left renal artery is longer than the right renal artery.
(B) The left renal artery is superior to the left renal vein.
(C) The left renal vein lies posterior to the aorta.
(D) The right renal artery lies posterior to the inferior vena cava (IVC).
(E) The right renal vein is anterior to the aorta.

Answer: (D) The right renal artery lies posterior to the inferior vena cava (IVC).

Rationale:
The IVC lies to the right of the aorta and slightly anterior to it. The renal veins are anterior and slightly superior to the renal arteries. Therefore, the right renal artery passes posterior to the IVC as it courses toward the right kidney. The right renal artery is longer than the left renal artery, as is the left renal vein compared to the right renal vein.

Reference:
Netter FH. *Atlas of Human Anatomy.* 2nd ed. Plate 314. East Hanover, NJ: Novartis; 1997.

۰۲۱-۶۶۱۹۸۵۱۴ www.myuptodate.com دریافت آخرین نسخه آپتودیت آفلاین

1M28

Key word: Rationale for Delayed Primary Wound Closure

Author: Michele A. Manahan, MD
Editors: Paul N. Manson, MD, FACS, and Gedge D. Rosson, MD

A negative side effect of delayed primary wound closure compared with healing by secondary intention includes which of the following?

(A) Increased width of scar
(B) Longer time to epithelialization
(C) Painful dressing changes
(D) Prolonged dressing changes
(E) Risk of delayed abscess/wound infection

Answer: (E) Risk of delayed abscess/wound infection

Rationale:
Primary wound healing refers to reapproximation of wound edges by surgical methods. Delayed primary wound closure decreases the width of the scar, shortens time to epithelialization, and decreases dressing changes (time and pain) when compared to healing by secondary intention. However, there is a risk of delayed abscess or surgical-site infection. Healing by secondary intention refers to re-epithelialization by migration of epithelial cells across the wound from the wound edges and retained epidermal elements such as sweat glands and hair follicles in the base of the wound. Myofibroblasts play a significant role in wound contraction that occurs during the healing process in healing by secondary intention.

Reference:
Glat P, Longaker M. Wound healing. In: Aston SJ, Beasley RW, Thorne DHM, eds. *Grabb and Smith's Plastic Surgery.* 5th ed. Philadelphia, PA: Lippincott-Raven Publishers; 1997:3.

1M29

Key word: Diagnosis of an Infected Burn Wound

Author: Justin B. Maxhimer, MD
Editors: Paul N. Manson, MD, FACS, Gedge D. Rosson, MD, Anne J.W. Tong, MBBS, and Pablo A. Baltodano, MD

A 35-year-old man is admitted with thermal burns resulting from the explosion of a gas cylinder at his factory. The man suffered 75% total body surface area burns, including his face, neck, chest, abdomen, back, arms, hands, and legs. More than 50% of his burn area was deep dermal in nature. Resuscitation was initiated with crystalloids and dry sterile dressings were placed over his wounds. Within 12 hours of admission, he developed respiratory distress, a high-grade temperature, and hypotension. Subsequent management should include which of the following?

(A) Allow burn wounds to demarcate
(B) Initiate antibiotics based upon the white blood count and fever
(C) Initiate total parenteral nutrition (TPN)
(D) Obtain a quantified wound biopsy
(E) Stop all enteral feeds

Answer: (D) Obtain a quantified wound biopsy

Rationale:
Infection is a major factor in recovery outcomes following burn injury. The risk of infection is proportional to the extent of the burn and is facilitated by direct disruption of the skin's protective function as well as generalized immune suppression from the systemic inflammatory response. Consequences of infection can be mitigated by early wound debridement and the use of topical and systemic antibiotics.

Suggestive clinical signs of burn wound infection include changes in the physical characteristics of the wound as well as refractory sepsis otherwise unexplained. Confirmation is by quantification of microbial invasion of viable tissue from a wound biopsy. The white blood cell count is of little specific value in the diagnosis of burn wound infection and may be elevated, within the reference range, or decreased (with or without a left shift).

Treatment depending upon the biopsy results is as follows:

Bacterial infections
Treatment requires daily application of topical and systemic antibiotic therapy until the infection resolves. Penicillins are used if the most likely source is Group A Streptococcus. If specific cultures and sensitivities are not known, a broad-spectrum beta-lactam is appropriate. Bacterial colonization of nonviable tissue requires debridement down to viable tissue, followed by the application of silver sulfadiazine cream every 12 hours. Infections that can be excised completely should be covered with an allograft or autograft.

۰۲۱-۶۶۱۹۸۵۱۴ www.myuptodate.com دریافت آخرین نسخه آپتودیت آفلاین

Fungal infections
Fungal colonization is most commonly caused by Candida and treated with an antifungal cream. Invasive colonization is usually caused by Aspergillus and requires debridement. If systemic infection is suspected, treatment with Amphotericin B is advised.

The basal metabolic rate is increased 100% above the reference range in patients with burns of greater than 40% of their total body surface area. Enteral feeding of a high-caloric diet through a nasogastric tube should be instituted within the first 12 hours after injury. The feedings should include a high-protein component (2 g/kg/day) and 3 to 10 times the recommended daily allowance of vitamins and minerals, particularly zinc (7 mg/day).

References:

Gibran NS, Heimbach DM. Current status of burn wound pathophysiology. *Clin Plast Surg.* 2000;27(1):11–22.

Pruitt BA, McManus AT, Kim SH, et al. Burn wound infections: current status. *World J Surg.* 1998;22(2):135–145.

1M30

Key word: Treatment of 1.7-mm Melanoma of the Trunk

Authors: Susanna M. Nazarian, MD, PhD, and Robert A. Meguid, MD, MPH
Editors: Charles M. Balch, MD, FACS, and Lisa K. Jacobs, MD

A 63-year-old woman is referred to your clinic for management of a biopsy-proven 1.7-mm thick nonulcerative melanoma on the center of her back. Lymph nodes are normal to palpation. What is an appropriate surgical margin to take during excision to minimize local recurrence?

(A) 5 mm
(B) 1 cm
(C) 2 cm
(D) >2 cm
(E) None

Answer: (C) 2 cm

Rationale:
The American Joint Committee on Cancer (AJCC) revised the staging system for cutaneous melanoma in 2001, using a 13-center, 17,600 patient database with prognostic factors for validation. This tumor-node-metastasis (TNM) system provides marked prognostic improvements over previous systems. The most important prognostic factor is thickness (Breslow thickness).

T Classification	Thickness	Ulceration Status
T1	≤1 mm	a: Without ulceration and level II/III b: With ulceration or level IV/V
T2	1.01–2 mm	a: Without ulceration b: With ulceration
T3	2.01–4 mm	a: Without ulceration b: With ulceration
T4	>4 mm	a: Without ulceration b: With ulceration
N Classification	**Number of Metastatic Nodes**	**Nodal Metastatic Mass**
N1	1 node	a: Micrometastasis[a] b: Macrometastasis[b]
N2	2–3 nodes	a: Micrometastasis[a] b: Macrometastasis[b] c: In transit met(s)/satellite(s) without metastatic nodes
N3	4 or more metastatic nodes, or matted nodes, or in transit met(s)/satellite(s) with metastatic node(s)	
M Classification	**Site**	**Serum Lactate Dehydrogenase**
M1a	Distant skin, subcutaneous, or nodal mets	Normal
M1b	Lung metastases	Normal
M1c	All other visceral metastases Any distant metastasis	Normal Elevated

[a]Micrometastases are diagnosed after sentinel or elective lymphadenectomy.

[b]Macrometastases are defined as clinically detectable nodal metastases confirmed by therapeutic lymphadenectomy or when nodal metastasis exhibits gross extracapsular extension.

۰۲۱-۶۶۱۹۸۵۱۴ www.myuptodate.com دریافت آخرین نسخه آپتودیت آفلاین

As can be seen above, the T classification depends on tumor thickness (in mm) and the presence or absence of ulceration. Ulceration is evaluated histopathologically and is defined as the absence of epidermis overlying a major portion of the primary melanoma. The presence of ulceration is a poor prognostic factor in all T categories; survival rates for patients with ulcerated melanoma are similar to nonulcerated melanoma survival rates in the next highest T category. Tumor thickness and ulceration are the most predictive prognostic factors for outcome.

These characteristics lead to the following staging system:

	Clinical Staging[a]			Pathologic Staging[b]		
	T	N	M	T	N	M
0	Tis	N0	M0	Tis	N0	M0
IA	T1a	N0	M0	T1a	N0	M0
IB	T1b	N0	M0	T1b	N0	M0
	T2a	N0	M0	T2a	N0	M0
IIA	T2b	N0	M0	T2b	N0	M0
	T3a	N0	M0	T3a	N0	M0
IIB	T3b	N0	M0	T3b	N0	M0
	T4b	N0	M0	T4a	N0	M0
IIC	T4b	N0	M0	T4b	N0	M0
III[c]	Any T	N1	M0			
		N2				
		N3				
IIIA				T1–4a	N1a	M0
				T1–4a	N2a	M0
IIIB				T1–4b	N1a	M0
				T1–4b	N2a	M0
				T1–4a	N1b	M0
				T1–4a	N2b	M0
				T1–4a/b	N2c	M0
IIIC				T1–4b	N1b	M0
				T1–4b	N2b	M0
				Any T	N3	M0
IV	Any T	Any N	Any M1	Any T	Any N	Any M1

[a]Clinical staging includes microstaging of the primary melanoma and clinical/radiologic evaluation for metastases. By convention, it should be used after complete excision of the primary melanoma with clinical assessment for regional and distant metastases.

[b]Pathologic staging includes microstaging of the primary melanoma and pathologic information about the regional lymph nodes after partial or complete lymphadenectomy. Pathologic stage 0 or stage 1A patients are the exception; they do not require pathologic evaluation of their lymph nodes.

[c]There are no stage III subgroups for clinical staging.

The patient in this scenario has a nonulcerated, 1.7-mm melanoma. A nonulcerated 1.7-mm melanoma is T2a and stage IB, whereas an ulcerated lesion of this same thickness would be T2b and stage IIA. Although there are no palpable lymph nodes, the patient would benefit from lymphatic mapping and sentinel node excision for staging purposes. If <4 metastases are identified in the regional lymph node(s), this would elevate the patient to stage IIIa if the metastases arise from a nonulcerated primary melanoma or a stage IIIb if it arises from an ulcerated primary melanoma. The patient is most likely M0, since there was no clinical evidence of distant metastases in the skin, subcutaneous areas, or in distant nodes. Patients with metastases in these distant locations, or in lung or visceral sites, are stage IV.

Analysis of 15-year survival by stage revealed significant differences between groups.

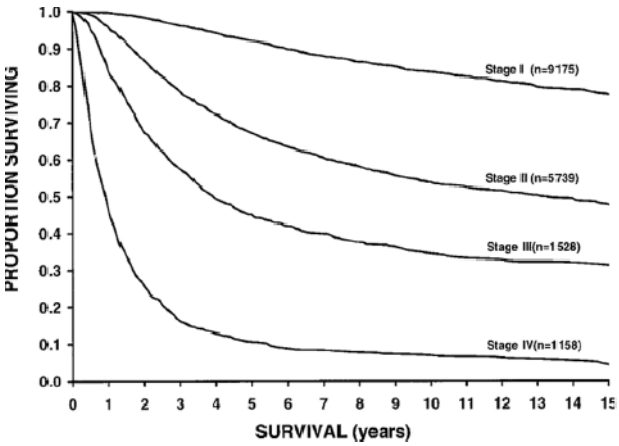

Reprinted with permission from: Balch CM, Buzaid AC, Soong SJ, et al. Final version of the American Joint Committee on Cancer staging system for cutaneous melanoma. *J Clin Oncol.* 2001;19:3635–3648.

Numerous randomized surgical trials since the 1970s have addressed the question of the appropriate margin of excision for primary melanoma. The collective findings of these trials lead to the following current recommendations:

Tumor Thickness (mm)	Excision Margin (cm)
In situ	0.5–1
0–1	1
1–2	1 or 2[a]
2–4	2
>4	At least 2 cm

[a]A 1-cm margin is appropriate in anatomically restricted areas; otherwise a 2 cm margin is preferable.

Adapted from: Table 10-12, Ross MI, Balch CM, Cascinelli N, et al. Excision of primary melanoma. In: Balch CM, Houghton AN, Sober AJ, Soong SJ, eds *Cutaneous Melanomas*. 4th ed. St. Louis, MO: Quality Medical Publishing, 2003:218–22.

The patient in this scenario should therefore receive a 2-cm margin on her 1.7-mm melanoma on her trunk. However, it should be noted that no study has been adequately statistically powered to address rigorously the outcome difference in 1-cm versus 3-cm margins. Moreover, no study has directly compared 1-cm versus 2-cm margins. There were nonsignificant trends in survival benefit for the 3-cm margin in two trials comparing that with with 1 cm, leading to the recommendation for a 2-cm margin when anatomically feasible.

۰۲۱-۶۶۱۹۸۵۱۴ www.myuptodate.com دریافت آخرین نسخه آپتودیت آفلاین

References:
Balch CM, Buzaid AC, Soong SJ, et al. Final version of the American Joint Committee on Cancer staging system for cutaneous melanoma. *J Clin Oncol.* 2001;19:3635–3648.
Balch CM, Soong SJ, Gershenwald JE, et al. Prognostic factors analysis of 17,600 melanoma patients: validation of the American Joint Committee on Cancer melanoma staging system. *J Clin Oncol.* 2001;19:3622–3634.
Balch CM, Soong SJ, Smith T, et al. Long-term results of prospective surgical trial comparing 2 cm vs. 4 cm excision margins for 740 patients with 1–4 mm melanomas. *Ann Surg Oncol.* 2001;8(2):101–108.
Balch CM, Urist MM, Karkousis CP, et al. Efficacy of 2-cm surgical margins for intermediate-thickness melanomas (1 to 4 mm). Results of a multi-institutional randomized surgical trial. *Ann Surg.* 1993;218:262–267.
Gershenwalk JE, Balch CM, Soong S-J, et al. Prognostic factors and natural history. In: Balch CM, Houghton AN, Sober AJ, Soong SJ, eds. *Cutaneous Melanomas.* 4th ed. St. Louis, MO: Quality Medical Publishing; 2003:25–54.
Ross MI, Balch CM, Cascinelli N, et al. Excision of primary melanoma. In: Balch CM, Houghton AN, Sober AJ, Soong SJ, eds. *Cutaneous Melanomas.* 4th ed. St. Louis, MO: Quality Medical Publishing; 2003:218–222.

1M31

Key word: Earliest Symptom of Compartment Syndrome

Author: Bonnie E. Lonze, MD, PhD
Editor: Frank J. Frassica, MD

A 54-year-old female with a low rectal cancer undergoes an abdominoperineal resection in what proves to be a challenging case that lasts 9 hours. Which of the following would be the earliest indicator of compartment syndrome in the lower extremities?

(A) Pain
(B) Pallor
(C) Paralysis
(D) Paresis
(E) Pulselessness

Answer: (A) Pain

Rationale:
Compartment syndromes occur when the pressure within a closed fascial compartment exceeds that of capillary perfusion pressure, resulting in ischemia, and ultimately tissue death. Causes of limb compartment syndrome include fractures, soft tissue compression injuries, gunshot wounds, intracompartmental bleeding, intracompartmental extravasation of intravenous fluids, reperfusion injury, and external compression from casts or other devices, including operative positioning devices. Pain, especially on passive movement of the affected extremity, is usually the earliest indication of a compartment syndrome. Interestingly, local nerve block and epidural anesthesia have been associated with a higher incidence of compartment syndromes, presumably due to a masking of pain symptoms with these patients' forms of analgesia. The other signs and symptoms listed above can all be seen in compartment syndromes but tend to occur after the onset of pain. Pulselessness and paralysis occur very late and by this time end organ damage and tissue death are nearly inevitable. Compartment syndrome is a clinical diagnosis. Pain out of proportion to the injury is the hallmark symptom. Compartment pressure measurements can be performed but the pressure levels at which compartment syndromes occur varies from patient to patient, and therefore compartment pressure measurements alone cannot constitute a diagnosis of compartment syndrome but rather are used for confirmation in difficult cases.

Reference:
Owings JT, Kennedy JP, Blaisdell FW. Injuries to the extremities. In: Souba WW, Fink MP, Jurkovich GJ, Kaiser LR, Pearce WH, Pemberton JH, Soper NJ, eds. *ACS Surgery: Principles and Practice.* 4th ed. New York, NY: WebM.D.; 2004:985–987.

۰۲۱-۶۶۱۹۸۵۱۴ www.myuptodate.com دریافت آخرین نسخه آپتودیت آفلاین

1M32

Key word: Fracture Associated with Pain in the Anatomic Snuffbox

Author: Kashif A. Zuberi, MBBCh, MRCSI
Editor: Frank J. Frassica, MD

A 75-year-old female falls while getting up from an unlocked wheelchair and subsequently complains of numbness in her index finger and thumb as well as difficulty in moving her thumb. Further questioning reveals a history of rheumatoid arthritis. She has tenderness on the dorsal aspect of her wrist, and at the base of her thumb. She also has a noticeable "dinner fork" deformity. Her findings are suggestive of which of the following diagnosis?

(A) Bennett fracture

(B) Colles fracture

(C) Lunate dislocation

(D) Scaphoid fracture

(E) Smith fracture

Answer: (B) Colles fracture

Rationale:

The hallmark of a Colles fracture is posterior angulation and displacement of the distal radius, with or without avulsion of the ulnar styloid. There can also be proximal shift of the distal radial fragment. This is a common fracture seen in postmenopausal women with osteoporosis. Rheumatoid arthritis and osteoarthritis are degenerative joint diseases that increase the risk of this fracture and make operative and nonoperative management more difficult. The physical appearance of a Colles fracture resembles a "dinner fork" when the wrist is viewed in pronation (the fingers are the forks prongs). This fracture should be reduced manually and placed in a dorsal plaster splint, and serial x-rays should be carried out to assess the adequacy of the reduction. If a loss of reduction occurs after the swelling subsides, repeat closed reduction or open reduction, and internal fixation should be considered. Closed reduction with percutaneous K-wires is another alternative operative procedure for fracture stabilization and fixation.

When a person falls on an outstretched hand with their forearm pronated, the force of impact radiates from the carpal bones through the forearm and terminates in the clavicle. The scaphoid is the most commonly fractured bone in the wrist, and usually occurs when the fall is broken with the palmar surface of the hand in an abducted position. Fracture of the scaphoid is characterized by tenderness in the anatomical snuffbox. Tenderness can also be manifested over the anterior aspect of the wrist, over the tubercle of the scaphoid. The scaphoid fractures at its narrowest point, the waist of the bone leaving a proximal and distal piece. As the blood supply of the scaphoid is obtained by a nutrient artery entering from its distal end, this fracture results in avascular necrosis of the proximal piece if left untreated. Treatment is with application of a thumb spica cast and/or screw fixation depending on displacement.

Perilunate dislocations are uncommon and usually signify high-force injury to the wrist with significant ligamentous injury in the carpus. Most perilunate dislocations are associated with disruption of the carpal ligaments causing the wrist to dislocate around the lunate, which can be considered the most fixed structure in the wrist. Perilunate dislocations will inevitably compress the median nerve in the carpal tunnel and must be reduced closed and/or treated operatively.

Other fractures in the wrist and hand include Smith fracture which is characterized by the distal radial fragment angulated anteriorly. Manipulation is carried out with the forearm in supination. These fractures are not as common as Colles fractures and usually unstable requiring fixation. Bennett fracture is a carpometacarpal fracture–dislocation of the thumb. It is treated with reduction/internal fixation and cast application for 4 to 6 weeks.

References:

Collier J, Longmore JM, Duncan Brown TJ, eds. Orthopedics and trauma. *Oxford Handbook of Clinical Specialties.* 5th ed. Oxford: Oxford University Press; 1999:700–707.

Moore KL, ed. The upper limb. *Clinically Oriented Anatomy.* 3rd ed. Baltimore, MD: Lippincott Williams and Wilkins; 1992:591–592.

۰۲۱-۶۶۱۹۸۵۱۴ www.myuptodate.com دریافت آخرین نسخه آپتودیت آفلاین

5
ENDOCRINE, HEMATIC, LYMPHATIC, AND BREAST

CONTENTS:

Number:	Key Word:	Page:
1E01	Treatment of Metastatic VIPoma	228
1E02	Characteristics of Solid and Cystic Cancer of the Thyroid	228
1E03	Conditions Associated with Tertiary Hyperparathyroidism	229
1E04	Treatment of Phyllodes Tumor of the Breast	230
1E05	Etiology of Cushing Syndrome	231
1E06	Treatment of Lobular Carcinoma In Situ of the Breast	232
1E07	Increased Cancer Incidence with Tamoxifen Therapy	232
1E08	Characteristics of Gastrinomas	233
1E09	Rate of Nerve Regeneration	234
1E10	Etiology of Post Femoral–Tibial Arterial Bypass Swelling	235
1E11	Treatment of Atypical Ductal Hyperplasia of the Breast	236
1E12	Radiation Associated with Thyroid Cancer	237
1E13	Treatment of Inflammatory Breast Cancer	238
1E14	Indications for Splenectomy	238
1E15	Diagnostic Test of Possible Abdominal Lymphoma	239
1E16	Workup of Thyroid Nodule	239
1E17	Treatment of Intraductal Papilloma of the Breast	240
1E18	Interpretation of Thyroid FNA	241
1E19	Sequence of Treatment in Multiple Endocrine Neoplasia	242
1E20	Adrenal Incidentaloma	243
1E21	Characteristics and Treatment of Multiple Endocrine Neoplasia	244
1E22	Indications for Surgery in Primary Hyperparathyroidism	245
1E23	Interpretation of Intraoperative Parathyroid Hormone Assay	246
1E24	Lymphadenopathy in Thyroid Cancer	246
1E25	Characteristics of Addisonian Crisis	247
1E26	Diagnosis of Insulinoma	248
1E27	Effect of Superior Laryngeal Nerve Injury	248
1E28	Prognostic Factors for Thyroid Cancer	249
1E29	Treatment of "Missing" Parathyroid	250
1E30	Treatment of Insulinoma of the Pancreatic Head	251
1E31	Characteristics of ITP Treatment	251
1E32	Contraindications to TRAM Flap Reconstruction	252
1E33	Characteristics of Hypoaldosteronism	253
1E34	Distribution of Insulinomas	254
1E35	Patient at Highest Risk of Postsplenectomy Sepsis	254
1E36	Diagnosis and Treatment of Insulinomas	255

۰۲۱-۶۶۱۹۸۵۱۴ www.myuptodate.com دریافت آخرین نسخه آپتودیت آفلاین

1E01

Key word: Treatment of Metastatic VIPoma

Author: Justin B. Maxhimer, MD
Editor: Anne O. Lidor, MD, MPH

A 39-year-old female presents to the emergency department with complaints of watery diarrhea and upper abdominal pain for the past 2 weeks. On workup, she is found to have a small mass in the body of the pancreas on computed tomography scanning. Laboratory abnormalities include a hemoglobin of 8.7 mg/dL, white blood cell count of 10.1, hypokalemia, and a metabolic acidosis. She is subsequently scheduled to have an exploratory laparotomy. Intraoperatively, the mass is removed from her pancreas and multiple small nodules are found in her liver. Considering the most likely diagnosis, what are her best treatment options?

(A) 5-fluorouracil and interferon-alpha
(B) Intravenous steroids alone
(C) No further treatment is indicated
(D) Octreotide and glucocorticoids
(E) Repetitive embolization of the hepatic artery

Answer: (A) 5-fluorouracil and interferon-alpha

Rationale:
In 1958, Verner and Morrison described a syndrome of watery diarrhea, hypokalemia, and achlorhydria (WDHA). These have subsequently been named VIPomas, after the excess of the hormone Vasoactive Intenstinal Peptide. VIPomas in adults are usually neuroendocrine islet cell tumors of the pancreas that produce high amounts of VIP. Other secreted hormones may include secreted gastrin and pancreatic polypeptide. Clinical diagnosis is based on a history of approximately 10 watery stools per day. Fecal losses while fasting are at least 20 mL/kg/day but exceed 50 mL/kg/day in most cases. Fecal loss of large amounts of potassium and bicarbonate cause hypokalemia, acidosis, and volume depletion.

Surgical exploration with tumor resection leads to cure in 50% of patients. In patients with metastatic disease, there are a number of treatment options. In advanced stages of the disease, tumor debulking may relieve symptoms but is not effective in all cases. In adults, selected patients have had orthotopic liver transplantation. Serum VIP levels may normalize within an hour after curative tumor resection. Repetitive embolization of the hepatic artery may provide palliation over a long period for patients with liver metastases but is not curative. Somatostatin analogs and conventional chemotherapy regimens have been effective in controlling some of the symptoms but were not effective on VIPoma syndrome and tumor progression. The combination of 5-fluorouracil and interferon-alpha has been found to result in major clinical improvement associated with tumor regression.

References:
Doherty GM. Rare endocrine tumours of the GI tract. *Best Pract Res Clin Gastroenterol.* 2005;19:807–817.
Marks IN, Bank S, Louw JH. Islet cell tumor of the pancreas with reversible watery diarrhea and achylorhydria. *Gastroenterology.* 1967;52(4):695–708.

1E02

Key word: Characteristics of Solid and Cystic Cancer of the Thyroid

Author: Robert A. Meguid, MD, MPH
Editors: Martha A. Zeiger, MD, FACS, and Konstantinos I. Makris, MD

A 52-year-old woman presents to your clinic with a palpable thyroid nodule. Ultrasound shows a 3-cm lesion in the right thyroid lobe with solid and cystic components. Ultrasound-guided fine-needle aspiration (FNA) reveals a thyroid cancer. Which of the following is the most likely diagnosis?

(A) Anaplastic carcinoma
(B) Follicular carcinoma
(C) Medullary carcinoma
(D) Papillary carcinoma
(E) Parathyroid adenocarcinoma

Answer: (D) Papillary carcinoma

Rationale:
Thyroid cancer may be divided histologically into (1) well-differentiated (papillary, follicular variant of papillary, follicular, and Hürthle cell) carcinoma, (2) medullary carcinoma, and (3) undifferentiated or anaplastic carcinoma.

Papillary carcinoma constitutes 80% of all thyroid cancers. On histology, the tumor cells have the characteristic "Orphan Annie eye" (empty-appearing nuclei) appearance, and psammoma bodies are typically present. Papillary carcinoma is multifocal at presentation 75% of the time. Therefore, treatment of lesions 1 cm or larger consists of total thyroidectomy. Central (level VI) neck lymph node dissection is added if suspicious nodes are present or the estimated risk of recurrence is high (prophylactic central neck dissection is advocated by many endocrine surgeons as well). Patients are usually treated with ^{131}I postoperatively based on their estimated risk of recurrence. Papillary carcinoma is associated with a 90% 10-year survival.

Follicular carcinoma constitutes approximately 15% of well-differentiated thyroid cancers. FNA results may be suggestive of a follicular neoplasm, but a diagnosis of cancer can only be made on final histopathology with documentation of vascular or capsular invasion. Treatment is total thyroidectomy followed by postoperative ^{131}I. Ten-year survival is estimated at 85%.

Medullary carcinoma constitutes less than 1% of all thyroid cancers, and arises from the neuroendocrine parafollicular C cells. Fifteen percent of cases are associated with MEN 2A and IIb syndromes. FNA is diagnostic with positive immunostaining for calcitonin. Medullary carcinoma should be treated with total thyroidectomy and central neck dissection at a minimum. Modified radical neck dissection is indicated for lateral cervical lymphadenopathy. The overall 10-year survival is 50%.

References:
Cooper DS, Doherty GM, Haugen BR, et al. Revised American Thyroid Association management guidelines for patients

۰۲۱-۶۶۱۹۸۵۱۴ www.myuptodate.com دریافت آخرین نسخه آپتودیت آفلاین

with thyroid nodules and differentiated thyroid cancer. *Thyroid.* 2009;19(11):1167–1214.
Sulibur J, Delbridge L. Surgical management of well-differentiated thyroid cancer: State of the art. *Surg Clin North Am.* 2009;89(5):1171–1191.

1E03

Key word: Conditions Associated with Tertiary Hyperparathyroidism

Author: Robert A. Meguid, MD, MPH
Editors: Martha A. Zeiger, MD, FACS, and Konstantinos I. Makris, MD

A 55-year-old woman presents to your clinic with the new diagnosis of tertiary hyperparathyroidism. Which of the following operations has she most likely previously undergone?

(A) Colectomy with resection of terminal ileum
(B) Parathyroidectomy
(C) Renal transplantation
(D) Right middle lung lobectomy
(E) Thyroidectomy

Answer: (C) Renal transplantation

Rationale:
Tertiary hyperparathyroidism is persistent abnormal hypersecretion of parathyroid hormone (PTH) after correction of causes of secondary hyperparathyroidism. *Primary* hyperparathyroidism is due to inappropriate secretion of PTH caused by a parathyroid adenoma or parathyroid hyperplasia. *Secondary* hyperparathyroidism is a result of compensatory increase of PTH secretion in response to hypocalcemia from nonparathyroid cause. This is most commonly due to renal failure, which causes hyperphosphatemia, hypovitaminosis D, and resultant hypocalcemia.

Classically, tertiary hyperparathyroidism is seen in the setting of a patient with long-standing secondary hyperparathyroidism, who has had a renal transplant for dialysis-dependent renal failure. The compensatory hypersecretion of PTH of secondary hyperparathyroidism persists after correction of the renal failure and becomes autonomous (tertiary hyperparathyroidism) as a result of parathyroid hyperplasia or new parathyroid adenoma. Patients usually present with normal to high calcium levels, and elevated PTH levels.

Indications for surgery in tertiary hyperparathyroidism include severe hypercalcemia (>11.5 mg/dL), persistent hypercalcemia (>10.2 mg/dL) for more than 3 months to 1 year after renal transplant, and severe osteopenia and persistent symptoms of hyperparathyroidism (bone and joint pain, pathologic fractures, generalized muscular weakness, fatigue, renal stones, mental status changes, peptic ulcer disease, pancreatitis, and calciphylaxis).

Surgical management is either subtotal (three and a half glands) parathyroidectomy or total parathyroidectomy with autotransplantation.

۰۲۱-۶۶۱۹۸۵۱۴ www.myuptodate.com دریافت آخرین نسخه آپتودیت آفلاین

References:
Guerrero MA, Rahbari R, Kebebew E. Secondary and tertiary hyperparathyroidism. In: Cameron JL, Cameron AM eds. *Current Surgical Therapy.* 10th ed. Philadelphia, PA: Mosby; 2011:617–620.
Irvin GL 3rd, Solorzano CC, Carneiro DM. Quick intraoperative parathyroid hormone assay: Surgical adjunct to allow limited parathyroidectomy, improve success rate, and predict outcome. *World J Surg.* 2004;28(12):1287–1292.
Pitt SC, Sippel RS, Chen H. Secondary and tertiary hyperparathyroidism, state of the art surgical management. *Surg Clin North Am.* 2009;89(5):1227–1239.

1E04

Key word: Treatment of Phyllodes Tumor of the Breast

Author: Nikiforos Ballian, MBBS
Editors: Theodore N. Tsangaris, MD, and Mehran Habibi, MD, MBA

A 47-year-old woman presents with a rapidly enlarging 5-cm right breast mass without palpable axillary nodes. Fine-needle aspiration (FNA) is nondiagnostic. Core biopsy is performed and results are reported as equivocal, but suggestive of a phyllodes neoplasm. The appropriate next step in management is:

(A) Close follow-up
(B) Simple mastectomy
(C) Tumor enucleation
(D) Tumor excision with a 1-cm margin
(E) Tumor excision with a 2-cm margin and sentinel node biopsy

Answer: (D) Tumor excision with a 1-cm margin

Rationale:
Phyllodes tumors are breast neoplasms composed of an epithelial component, which is always benign, and a stromal component that can be benign (60%), borderline (15%), or frankly malignant (25%). They account for less than 1% of all breast tumors and share morphologic similarities with fibroadenomas, but their peak incidence is in the fourth and fifth decades of life. Phyllodes neoplasms present as breast masses, sometimes rapidly enlarging, but rarely cause additional symptoms. Mammography and ultrasound cannot reliably distinguish fibroadenoma from phyllodes tumor, while fine-needle aspiration is diagnostic only in a minority of cases. Core-needle biopsy is more accurate, although recent studies have failed to yield consistent recommendations regarding its use.

Due to rapid growth and potential for malignancy, surgical treatment of phyllodes tumors is mandatory. Simple tumor enucleation is insufficient due to high recurrence rates, even for benign tumors. There is no role for sentinel node biopsy because malignant phyllodes tumors behave like sarcomas, rarely causing lymph node metastases. Recent data suggest that wide local excision with a 1-cm margin is adequate even for malignant tumors, yielding the same survival despite higher local recurrence rates.

References:
Ben Hassouna J, Damak T, Gamoudi A, et al. Phyllodes tumors of the breast: A case series of 106 patients. *Am J Surg.* 2006;192:141–147.
Chen WH, Cheng SP, Tzen CY, et al. Surgical treatment of phyllodes tumors of the breast: Retrospective review of 172 cases. *J Surg Oncol.* 2005;91:185–194.

۰۲۱-۶۶۱۹۸۵۱۴ www.myuptodate.com دریافت آخرین نسخه آپتودیت آفلاین

Foxcroft LM, Evans EB, Porter AJ. Difficulties in the preoperative diagnosis of phyllodes tumours of the breast: A study of 84 cases. *Breast.* 2007;16:27–37.

Iglehart JD, Kaelin CM. Diseases of the breast. In: Townsend CM, Beauchamp RD, Evers BM, Mattox KL, eds. *Sabiston Textbook of Surgery.* 17th ed. Philadelphia, PA: Elsevier; 2004:867–928.

Macdonald OK, Lee CM, Tward JD, et al. Malignant phyllodes tumor of the female breast: Association of primary therapy with cause-specific survival from the Surveillance, epidemiology, and end results (SEER) program. *Cancer.* 2006;107:2127–2133.

1E05

Key word: Etiology of Cushing Syndrome

Author: Robert A. Meguid, MD, MPH
Editor: Alan P.B. Dackiw, MD, PhD, BSc, BSc(Med), FACS, FRCSC

A 38-year-old woman is referred to your clinic after an elevated 24-hour urine cortisol measurement. She is not on any steroids. What is the most likely cause of this patient's disease?

(A) Adrenal adenoma

(B) Adrenal carcinoma

(C) Factitious insulin use

(D) Ovarian cancer

(E) Pituitary adenoma

Answer: **(E)** Pituitary adenoma

Rationale:

Cushing syndrome is the condition resulting from excessive glucocorticoid exposure. Causes can be divided into iatrogenic or noniatrogenic, and adrenocorticotropic hormone (ACTH)-dependent or ACTH-independent categories.

Iatrogenic Cushing syndrome is due to high-dose exogenous glucocorticoid administration, usually for treatment of nonendocrine disorders.

ACTH-dependent causes include ACTH-secreting pituitary adenoma and ectopic ACTH syndrome. ACTH-secreting pituitary adenoma, or Cushing disease, constitutes 68% of noniatrogenic Cushing syndrome. Most patients are female and 20 to 40 years of age. The disease progresses slowly, and clinical features include hirsutism and acne. Ectopic ACTH syndrome constitutes 15% of noniatrogenic Cushing syndrome. Most patients are female and of 40 to 60 years of age. ACTH is usually secreted by small-cell carcinomas of the lung, and bronchial carcinoid tumors, but may also be secreted by other carcinoid tumors, pheochromocytomas, pancreatic islet cell tumors, medullary thyroid, and ovarian cancers. The disease progresses rapidly, associated with the primary cancer, and clinical features include hypertension, weakness and hypokalemia, glucose intolerance, and hyperpigmentation.

ACTH-independent causes include functioning adrenocorticoid tumors, with adrenal adenomas accounting for 9% of noniatrogenic Cushing syndrome, and adrenal carcinomas for 8%. Most patients are female and of 35 to 40 years of age. In the case of adrenal adenomas secreting cortisol, onset is usually gradual. For adrenal carcinomas, onset is rapid.

Diagnosis is made via a 24-hour urine cortisol measurement or a dexamethasone suppression test. Localization is via CT or MRI; however, due to the microadenomatous nature of most pituitary adenomas, frequently none are seen on imaging.

Reference:

McPhee SJ. Disorders of the hypothalamus and pituitary gland. In: McPhee SJ, Lingappa VR, Ganong WF, Lange JD, eds. *Pathophysiology of Disease.* 3rd ed. New York, NY: Lange Medical Books/McGraw-Hill; 2000:509–517.

۰۲۱-۶۶۱۹۸۵۱۴ www.myuptodate.com دریافت آخرین نسخه آپتودیت آفلاین

1E06

Key word: Treatment of Lobular Carcinoma In Situ of the Breast

Author: Jacqueline Garonzik-Wang, MD, PhD
Editors: Julie R. Lange, MD, ScM, FACS, and Mehran Habibi, MD, MBA

A 40-year-old premenopausal woman is seen by her physician for evaluation of a breast nodule. Physical examination confirms the presence of a 1-cm movable mass; mammogram and ultrasound evaluation are both found to be consistent with a fibroadenoma. A core biopsy confirms this diagnosis. The lesion is excised at the patient's request. Pathology results reveal a fibroadenoma with a small area of lobular carcinoma in situ (LCIS) in the surrounding breast tissue, focally extending to one margin. The next step in management is:

(A) A partial mastectomy with sentinel lymph node biopsy

(B) Counsel the patient about their future breast cancer risk and screening options

(C) Remove further tissue from the positive margin side

(D) Remove further tissue from the positive margin side with axillary node dissection

(E) Sentinel lymph node biopsy alone

Answer: (B) Counsel the patient about their future breast cancer risk and screening options

Rationale:
LCIS can be found incidentally on biopsy performed for other reasons. This finding, sometimes referred to as lobular neoplasia, is considered to be a marker of increased risk of subsequent breast cancer development. The implied risk extends over all breast tissue, bilaterally. Women should receive counseling about their increased risk of breast cancer, which can be approximately 25% over their lifetime. The simplest management option is careful screening with annual mammography and clinical examination. Some women may consider chemoprevention with a 5-year course of tamoxifen, which is expected to lower the risk of invasive breast cancer by about half. Postmenopausal women, particularly those with osteoporosis, may consider raloxifene for similar risk reduction. Bilateral prophylactic mastectomy is a more aggressive risk-reduction measure and is sometimes considered by women who have breasts that are difficult to screen or those with high levels of anxiety, or in women with other strong risk factors such as known deleterious BRCA mutation or a strong family history of breast cancer.

References:
McAuliffe PF, Andtbacka RHI, Robinson EK, et al. Noninvasive breast cancer. In: Feig BW, Ching CD, eds. *The M.D. Anderson Surgical Oncology Handbook.* 5th ed. Philadelphia, PA: Lippincott Williams and Wilkins; 2012.

Wang TN, Bland KI. Ductal and lobular carcinoma in situ of the breast. In: Cameron JL, Cameron AM, eds. *Current Surgical Therapy.* 10th ed. Philadelphia, PA: Mosby; 2011:542–546.

1E07

Key word: Increased Cancer Incidence with Tamoxifen Therapy

Author: Jonathan A. Forbes, MD
Editors: Julie R. Lange, MD, ScM, FACS, and Mehran Habibi, MD, MBA

A 64-year-old postmenopausal woman with Estrogen Receptor Positive (ER+), stage I breast cancer presents following lumpectomy, and radiation therapy, now on therapy with tamoxifen. She asks about the risks of tamoxifen therapy. You tell her that:

(A) Tamoxifen decreases the likelihood of developing all types of cancer

(B) Tamoxifen has been linked to an increased risk of developing endometrial adenocarcinoma and uterine sarcoma

(C) Tamoxifen increases bone resorption, increasing risk of long bone and pelvic fractures due to osteoporosis

(D) Tamoxifen increases the likelihood of developing breast cancer in the contralateral breast

(E) Tamoxifen is associated with a modest, but significant increase in the risk of cardiovascular events seen in postmenopausal women with coronary artery disease

Answer: (B) Tamoxifen has been linked to an increased risk of developing endometrial adenocarcinoma and uterine sarcoma

Rationale:
Tamoxifen is a selective estrogen receptor modulator (SERM) that acts as an estrogen agonist in certain organs of the body (uterus, bone) and an estrogen antagonist in others (breast). The most commonly recognized serious risks of tamoxifen therapy include development of deep venous thrombosis (DVT) and resulting pulmonary emboli, and development of endometrial hyperplasia and endometrial cancer. The risks of venous thrombosis and endometrial cancer in women on tamoxifen therapy are higher in postmenopausal women than in premenopausal women. Other, less threatening risks associated with tamoxifen therapy include hot flashes and mood changes.

Postmenopausal women who take tamoxifen are approximately two to three times more likely than those not taking tamoxifen to develop endometrial cancer. This risk appears to increase with duration of tamoxifen therapy. The Surveillance Epidemiology and End Results (SEER) database of the National Cancer Institute has recently shown that tamoxifen exposure increases the risk of uterine sarcomas (especially malignant mixed müllerian tumors [MMMT]), in addition to endometrial adenocarcinomas. Because the risks of tamoxifen therapy increases with time and the benefits of tamoxifen therapy beyond 5 years have not yet been demonstrated, the American College of Obstetricians and Gynecologists currently recommends to limit tamoxifen use to no longer than 5 years. Tamoxifen use is associated with lower risk of developing a primary breast cancer in the contralateral breast and

۰۲۱-۶۶۱۹۸۵۱۴ www.myuptodate.com دریافت آخرین نسخه آپتودیت آفلاین

in some circumstances can be offered to women at high risk of breast cancer as a risk-reduction measure.

Tamoxifen provides some protection against postmenopausal bone loss. However, the increase in bone density (measured at approximately 1.2% in the lumbar spine at 2 years) is much less than the increase in bone density seen with bisphosphonates (measured at approximately 6% at 2 years with alendronate).

While results of the Early Breast Cancer Trialists' Collaborative Group overview analysis did suggest a modest though significant reduction in cardiac events, trials like the National Surgical Adjuvant Breast and Bowel Project (NSABP) P-1 and the "Myocardial infarction risk and tamoxifen therapy for breast cancer" have failed to show a benefit in reduction of cardiovascular events in postmenopausal women with coronary artery disease. The current consensus is that, in postmenopausal women both with and without coronary artery disease, the use of tamoxifen does not have a significant impact on cardiovascular morbidity and mortality.

References:

American College of Obstetricians and Gynecologists. *Tamoxifen and endometrial cancer: ACOG Committee Opinion 336.* ACOG June 2006;Washington, DC.

Braithwaite RS, Chlebowski RT, Lau J. Meta-analysis of vascular and neoplastic events associated with tamoxifen. *J Gen Intern Med.* 2003;18:937.

Curtis RE, Freedman DM, Sherman ME, et al. Risk of malignant mixed mullerian tumors after tamoxifen therapy for breast cancer. *J Natl Cancer Inst.* 2004;96:70.

Levine MN. Adjuvant therapy and thrombosis: How to avoid the problem? *Breast.* 2007;16(Supplement 2):169–174.

Powles TJ, Hickish T, Kanis, JA. Effect of tamoxifen on bone mineral density measured by dual-energy x-ray absorptiometry in healthy premenopausal and postmenopausal women. *J Clin Oncol.* 1996:14:78.

Reis SE, Costantino JP, Wickerham DL. Cardiovascular effects of tamoxifen in women with and without heart disease: Breast cancer prevention trial. *J Natl Cancer Inst.* 2001;93:16.

1E08

Key word: Characteristics of Gastrinomas

Author: Ying Wei Lum, MD
Editor: Anne O. Lidor, MD, MPH

A 48-year-old male presents with persistent peptic ulcers that have been refractory to proton-pump inhibitors. His workup includes a positive secretin stimulation test. His underlying tumor is:

(A) Associated with hypoglycemia

(B) Associated with MEN 2A

(C) Associated with Whipple triad

(D) Frequently located in the tail of the pancreas

(E) Likely to be sporadic

Answer: **(E)** Likely to be sporadic

Rationale:

The clinical scenario describes a patient with a gastrinoma. The secretin stimulation test is a provocative test measuring gastrin levels in response to an intravenous bolus of secretin after an overnight fast. It is positive if gastrin levels increase to greater than 200 pg/mL.

Seventy-five percent of gastrinomas are sporadic; the remainder are associated with MEN 1 syndrome. All other choices in the question are associated with insulinoma.

Gastrinomas are more frequently located in the "gastrinoma triangle," which is bordered by the cystic duct–common bile duct junction, the junction of the second and third portion of the duodenum and the junction between the head and neck of the pancreas.

Gastrinoma

Parameter	Description
Symptoms	Peptic ulcer disease
	Diarrhea
	Esophagitis
Diagnostic tests	Serum gastrin measurement
	Gastric acid analysis (or pH testing)
	Secretin stimulation test
Anatomic localization	Duodenum and head of pancreas (gastrinoma triangle)

Reprinted with permission from: Kennedy EP, Brody JR, Yeo CJ. Neoplasms of the endocrine pancreas. In: Mulholland MW, Lillemoe KD, Doherty GM, Maier RV, Upchurch GR, eds. *Greenfield's Surgery: Scientific Principles & Practice.* 5th ed. Philadelphia, PA: Lippincott Williams & Wilkins; 2011:864.

۰۲۱-۶۶۱۹۸۵۱۴ www.myuptodate.com دریافت آخرین نسخه آپتودیت آفلاین

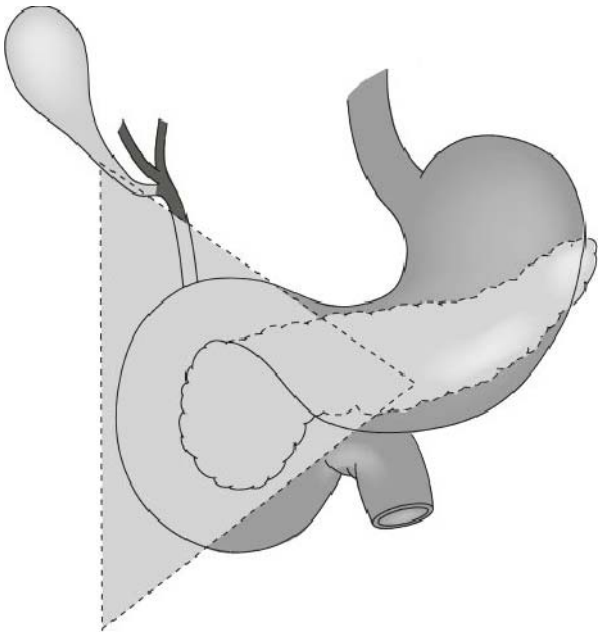

Most gastrinomas are found within the gastrinoma triangle. Adapted from: Stabile BE, Morrow DJ, Passaro E. The gastrinoma triangle: Operative implications. *Am J Surg*. 1984;147:26.

Reference:

Kennedy EP, Brody JR, Yeo CJ. Neoplasms of the endocrine pancreas. In: Mulholland MW, Lillemoe KD, Doherty GM, Maier RV, Upchurch GR, eds. *Greenfield's Surgery: Scientific Principles & Practice.* 5th ed. Philadelphia, PA: Lippincott Williams and Wilkins; 2011.

1E09

Key word: Rate of Nerve Regeneration

Author: Justin B. Maxhimer, MD
Editors: Paul N. Manson, MD, FACS, and Gedge D. Rosson, MD

A 25-year-old male sustains a superficial gunshot wound to his left proximal, lateral thigh, near the anterior superior iliac spine. His initial neurologic examination in the emergency department reveals no motor deficits but numbness in the region of the left lateral cutaneous nerve of the thigh. When should surgery for repair of the suspected nerve injury be performed?

(A) 1 to 2 weeks
(B) 2 to 3 months
(C) 6 months to 1 year
(D) Immediately
(E) Never

Answer: (B) 2 to 3 months

Rationale:

Surgical timing is very important after an injury resulting in nerve damage. Immediate primary repair may be indicated in clean lacerating injuries in which the nerve ends are visible or when clinical examination reveals obvious motor and sensory deficits. Contaminated or complicated transections are best treated by delayed repair. Knife wounds may be explored early—either immediately if there are also some other structures that need to be repaired, or over the next few weeks if there are no other urgent reasons to take the patient to the operating room. Ballistic injuries generally have surrounding damage and are best explored 2 to 3 months after the injury. In gunshot wounds, nerve injury typically results from the blast effect rather than the trajectory of the projectile itself. Hence, gunshot wounds are considered blunt rather than sharp nerve injuries. It is for this reason that a delayed repair (i.e., 2 to 3 months) is recommended.

For injuries to motor nerves, repair should be performed within 3 to 6 months to give the best chance for the axons to regenerate all the way to the motor endplates before they atrophy. For injuries to sensory nerves, repair can actually be performed at any time, as the sensory end organs can be reinnervated many years later.

Sunderland described three fundamental types of nerve injury: (1) A transient interruption of nerve conduction without loss of axonal continuity (i.e., neuropraxia, conduction block), (2) transection of axons (or conditions leading to loss of axonal integrity) with preservation of the endoneurium during wallerian degeneration (i.e., axonotmesis), and (3) complete disruption of the nerve fiber with loss of the normal architecture (i.e., neurotmesis). The third level of injury can be further subdivided to include perineurial disruption (class IV injury) or epineurial transection (class V injury); all injuries that include neurotmesis may result in aberrant regrowth of axons into the wrong endoneurial tubes.

۰۲۱-۶۶۱۹۸۵۱۴ www.myuptodate.com دریافت آخرین نسخه آپتودیت آفلاین

The response of the injured nerve in the first 12 to 48 hours includes wallerian degeneration, which is degeneration of the distal axon to the motor endplate and of the proximal axon to the first node of Ranvier, axonal edema, and retraction of myelin. From 48 to 72 hours, the axons break into twisted fragments and by the second week after injury, all traces of the axon are usually lost. The distal nerve fibers can be stimulated for approximately 72 hours after injury, an essential time frame to consider when contemplating exploration of traumatic nerve injuries, particularly for small, critical motor nerves such as the facial nerve branches. Macrophages are mobilized to phagocytize debris along the nerve and Schwann cells contribute to this activity. However, the main role of the Schwann cells is to guide regeneration by forming dense cellular cords (i.e., Büngner bands) along the site of the degenerating axon. These bands provide conduits for axons once regeneration ensues.

Axonal regeneration generally occurs in four phases. In the initial phase, the neuron recovers, the axonal growth commences, and the axons reach the injured zone. In the second phase (scar delay), the axons must traverse the scar tissue at the site of injury. During the third phase, the axons propagate beyond the site of injury to reach the peripheral target where functional recovery (fourth phase) occurs with restoration of normal patterns of conduction. The duration of the regenerative process varies and may require 6 to 18 months, depending on the length of the nerve and the site of the lesion. Although the commonly quoted regeneration rate is 1 mm/day, this figure varies considerably and can be used only as a rough estimate. Occasionally, very early signs of recovery may be present, which are thought to be due to so-called pioneer axons, which quickly navigate the pathway to the target tissue ahead of most nerve fibers.

References:

Cheng ET, Utley DS, Ho PR, et al. Functional recovery of transected nerves treated with systemic BDNF and CNTF. *Microsurgery.* 1998;18(1):35–41.

Hebert-Blouin M, Spinner RJ. Nerve injury and repair. In: Cameron JL, Cameron AM, eds. *Current Surgical Therapy.* 10th ed. Philadelphia, PA: Mosby; 2011:648–656.

Myckatyn TM, MacKinnon SE. Microsurgical repair of peripheral nerves and nerve grafts. In: Thorne CH, Beasley RW, Aston SJ, Bartlett SP, Gurtner GC, Spear SL, eds. *Grabb and Smith's Plastic Surgery.* 6th ed. Philadelphia, PA: Lippincott Williams and Wilkins; 2006:73–83.

Sunderland S. The intraneural topography of the radial, median and ulnar nerves. *Brain.* 1945;68:243.

1E10

Key word: Etiology of Post Femoral–Tibial Arterial Bypass Swelling

Author: Eric S. Weiss, MD, MPH
Editors: G. Melville Williams, MD, FACS, and Christopher J. Abularrage, MD

A 72-year-old man with a history of diabetes and smoking presents with a 2-day history of excruciating pain in the right lower extremity. The patient states that the pain started while he was sitting in a chair, and that, unlike other pains he has had in the leg before, it was not relieved by elevation of the extremity. Physical examination shows a pale, cool, pulseless, and numb right foot and the calf is quite tender. No pedal Doppler signal is obtainable. The patient is taken to the operating room where on-table angiogram reveals occlusion of the superficial femoral artery. A right femoral below-knee popliteal bypass is performed with restoration of the pulses. Postoperatively in the surgical intensive care unit, the resident notices severe swelling of the right lower extremity and loss of the dorsalis pedis pulse. The most likely etiology of the edema is:

(A) Acute bleed from anastomotic leak

(B) Acute popliteal venous occlusion

(C) Acute reperfusion injury

(D) Chronic venous occlusive disease

(E) Lymphocele

Answer: (C) Acute reperfusion injury

Rationale:

Severe acute lower extremity occlusive disease is a limb-threatening emergency, and prompt revascularization is essential. However, the 2-day history of an insensate foot in this patient followed by restoration of his pulses renders him a perfect candidate for compartment syndrome, the dreaded culmination of a severe reperfusion injury. Reperfusion injury is caused by oxygen-free radical release after return of pulses, and is the most common cause of post revascularization swelling. Most surgeons would have performed a four-compartment fasciotomy at the time of the primary procedure to accommodate the anticipated swelling. Barring this, it is important to be diligent in assessing for compartment syndrome in the early postoperative period. The primary sign of compartment syndrome is pain, although this assessment can be difficult in the early postoperative period. When faced with the scenario described above, the intensive care resident should immediately measure the pressure in all compartments of the leg. Emergent four-compartment fasciotomy in the face of elevated compartment pressures can save the limb. Incidentally, one should not be fooled by the presence of intact distal pulses in the presence of pain and swollen limbs in a setting suggestive for compartment syndrome; loss of pulses is one of the late findings in patients with critically elevated compartment pressures.

۰۲۱-۶۶۱۹۸۵۱۴ www.myuptodate.com دریافت آخرین نسخه آپتودیت آفلاین

References:
Brant-Zawadzki P, Craig-Kent K. Femoropopliteal occlusive disease. In: Cameron JL, Cameron AM, eds. *Current Surgical Therapy.* 10th ed. Philadelphia, PA: Mosby; 2011:779–782.
Gourgiotis S, Villas C, Germanos S, et al. Acute limb compartment syndrome: A review. *J Surg Educ.* 2007;64(3):178–186.
Whitesides TE, Haney TC, Morimoto K, et al. Tissue pressure measurements as a determinant for the need of fasciotomy. *Clin Orthop Relat Res.* 1975;113:43–51.

1E11

Key word: Treatment of Atypical Ductal Hyperplasia of the Breast

Author: Robert A. Meguid, MD, MPH
Editors: Theodore N. Tsangaris, MD, and Mehran Habibi, MD, MBA

A 47-year-old woman undergoes core-needle biopsy of a lesion found on routine mammography in the lower, outer quadrant of her right breast. Pathology is read as atypical ductal hyperplasia (ADH) of the breast. What is the most appropriate next step in this patient's management?

(A) Axillary lymph node dissection
(B) Excisional biopsy with wire localization
(C) Follow-up mammography in 6 months
(D) Modified radical mastectomy
(E) Partial mastectomy with sentinel lymph node biopsy

Answer: (B) Excisional biopsy with wire localization

Rationale:
ADH is defined as: (1) A lesion that has some but not all of the histologic features of DCIS; (2) a lesion with all the features of DCIS but <2 mm in greatest dimension; (3) a lesion with all the features of DCIS but involving only two duct spaces. ADH is found in 31% of biopsies for mammographic calcifications and in 4% of benign breast biopsies.

ADH on core-needle biopsy is associated with a 20% to 25% occurrence of ductal carcinoma in situ (DCIS) and an overall relative risk of 4% to 5% for developing any invasive breast cancer compared to age-matched women of average risk. Therefore, it is important to excise the region of concern for further pathologic examination in the event that malignancy is present. Excisional biopsy following wire localization is the appropriate management of ADH.

Of note, core-needle biopsy has low false-negative rates (<2%), comparable to those for excisional biopsy. When core-needle biopsy reveals benign processes with concordance, there is no need for further surgical follow-up.

Excisional biopsy with wire localization is a diagnostic procedure. Mastectomy or lumpectomy with sentinel lymph node biopsy are therapeutic and should be utilized when the diagnosis of cancer is made. They are inappropriate procedures for ADH. A patient whose excisional biopsy confirms only ADH should be closely followed.

References:
Hatmaker AR, Meszoely IM, Kelly MC. Surgical management of carinoma in situ and proliferative lesions of the breast. In: Fischer JE, Bland KI, eds. *Mastery of Surgery.* 5th ed. Philadelphia, PA: Lippincott Williams and Wilkins; 2007:522–523.

۰۲۱-۶۶۱۹۸۵۱۴ www.myuptodate.com دریافت آخرین نسخه آپتودیت آفلاین

Kass R, Lind DS, Souba WW. Breast, skin and soft tissue. In: Souba WW, ed. *ACS Surgery: Principles and Practice.* New York, NY: WebMD; revised December 2005. Accessed April 9, 2007. Online Edition.

Lind DS, Smith BL, Souba WW. Breast complaints. In: Souba WW, ed. *ACS Surgery: Principles and Practice.* New York, NY: WebMD; revised June 2004. Accessed June 9, 2007. Online Edition.

1E12

Key word: Radiation Associated with Thyroid Cancer

Author: Robert A. Meguid, MD, MPH
Editor: Alan P.B. Dackiw, MD, PhD, BSc, BSc(Med), FACS, FRCSC

A 34-year-old male Ukrainian immigrant is seen in clinic for a right-sided thyroid nodule, which shows no uptake on technetium scan. In 1986, he was living near the Chernobyl nuclear reactor during its melt-down. Given this history and probable etiology, what is the most likely diagnosis of his thyroid nodule?

(A) Anaplastic carcinoma

(B) Follicular carcinoma

(C) Hürthle cell carcinoma

(D) Medullary carcinoma

(E) Papillary carcinoma

Answer: (E) Papillary carcinoma

Rationale:

Technetium (^{99m}Tc) scans help differentiate functioning ("hot") versus nonfunctioning ("cold") thyroid tissue. Approximately 25% of cold nodules in adults are malignant.

A major risk factor for developing thyroid carcinoma, exposure to ionizing radiation during childhood is usually associated with papillary carcinoma. Overall, prior radiation exposure is associated with 9% of thyroid cancers. Risk is greatest when exposure occurred before 15 years of age.

Follicular carcinoma is the type of thyroid cancer most commonly associated with goiter disease. Hürthle cell carcinoma is a subtype of follicular carcinoma. Medullary carcinoma also occurs in patients with multiple endocrine neoplasia type 2 (MEN 2) syndrome. This is specifically associated with the RET oncogene. Anaplastic carcinoma is one of the most deadly malignancies, with aggressive growth and a 5-year survival of 7%. It may be associated with well-differentiated thyroid cancer and may result from dedifferentiation.

References:

Blackbourne LH, ed. Thyroid gland. *Surgical Recall.* 2nd ed. Baltimore, BA: Williams and Wilkins; 1998:394.

Thomas RM, Habra MA, Perrier ND, et al. Well-differentiated carcinoma of the thyroid and neoplasms of the parathyroid glands. In: Feig BW, Ching CD, eds. *The M.D. Anderson Surgical Oncology Handbook.* 5th ed. Philadelphia, PA: Lippincott Williams and Wilkins; 2012.

۰۲۱-۶۶۱۹۸۵۱۴ www.myuptodate.com دریافت آخرین نسخه آپتودیت آفلاین

1E13

Key word: Treatment of Inflammatory Breast Cancer

Author: Robert A. Meguid, MD, MPH
Editors: Theodore N. Tsangaris, MD, and Mehran Habibi, MD, MBA

A 42-year-old woman presents with the presumed diagnosis of inflammatory carcinoma of her left breast. She is 8 weeks postpartum. What is the appropriate management?

(A) If the tumor does not respond to neoadjuvant chemotherapy, proceed to mastectomy

(B) If the tumor responds to an extended course of antibiotics, continue with local resection

(C) If the tumor responds to high-dose chemotherapy, continue with mastectomy, postoperative radiation, then possible further adjuvant therapy

(D) If the tumor responds to high-dose chemotherapy, continue with radiation therapy, followed by surgical resection, then chemotherapy

(E) If the tumor responds to neoadjuvant chemotherapy, proceed to local excision

Answer: (C) If the tumor responds to high-dose chemotherapy, continue with mastectomy, postoperative radiation then possible further adjuvant therapy

Rationale:
Any inflammation of breast that does not resolve with 2 weeks of appropriate antibiotics should be screened for underlying inflammatory breast carcinoma. Screening consists of mammography and repeat skin and core biopsies until cancer is proven or the inflammation resolves (particularly in women not of childbearing age or breastfeeding).

Upon biopsy-proven diagnosis of inflammatory breast carcinoma, staging workup should proceed with bilateral mammography, bone scan, and CT of the chest, abdomen, and pelvis. Thirty-five percent of patients with inflammatory breast carcinoma have metastases at the time of diagnosis.

Staging is followed by aggressive neoadjuvant therapy. Should the tumor respond to this high-dose chemotherapy, treatment progresses to mastectomy followed by postoperative radiation and then possible adjuvant chemotherapy. However, if the tumor does not respond to high-dose neoadjuvant chemotherapy, treatment consists of radiation therapy, followed by mastectomy if the tumor is technically resectable, and ultimately adjuvant chemotherapy.

High-dose chemotherapy alone is inadequate treatment for inflammatory breast carcinoma, with clinical response lasting only 3 to 6 months. Local excision (lumpectomy or partial mastectomy) is inappropriate for treatment of inflammatory breast carcinoma, with high early failure rate and ensuing systemic disease.

Reference:
Krontiras H, Urist MM. Inflammatory breast cancer. In: Cameron JL, Cameron AM, eds. *Current Surgical Therapy.* 10th ed. Philadelphia, PA: Mosby; 2011:540–541.

1E14

Key word: Indications for Splenectomy

Author: Kashif A. Zuberi, MBBCh, MRCSI
Editor: Dorry L. Segev, MD, PhD

A 65-year-old female complaining of weakness, fatigue, and easy bruising is found to have guarding and distention of her upper abdomen. She reports a history of taking prednisone and weekly epoetin-α. She feels her symptoms have become worse in the past year. What procedure would this patient need for definitive management of this condition?

(A) Bone marrow biopsy

(B) Gastrectomy

(C) Laparoscopic adrenalectomy

(D) Laparoscopic splenectomy

(E) Patient requires no surgical management

Answer: (D) Laparoscopic splenectomy

Rationale:
Immune thrombocytopenic purpura (ITP) is an autoimmune hematologic disease characterized by anti-platelet auto-antibody production and platelet destruction within the spleen. The initial management is medical therapy using high-dose steroids, with remission rates of 60% that decrease to 30% on drug withdrawal. The side effects of long-term steroid administration eventually result in patients seeking a more definitive form of management. Splenectomy is the surgical treatment for ITP and is indicated for failed medical management or severe bleeding. The benefits of splenectomy in ITP are the combined effects of eliminating the major source of anti-platelet antibody production as well as removing the major site of platelet destruction.

Answer **(E)** is incorrect, as the patient was referred for failure of medical management, and answer **(A)** is incorrect as it yields diagnostic value, but is not a definitive form of management. Finally, both answers **(B)** and **(C)** are incorrect as they do not address the underlying disorder, namely ITP.

References:
Cuschieri A. Disorders of the spleen and lymph nodes. In: Cuschieri A, ed. *Essential Surgical Practice.* 4th ed. London: Arnold; 2002:466–467.

Khan LR, Nixon SJ. Laparoscopic splenectomy is a better treatment for adult ITP than steroids—it should be used earlier in patient management: Conclusions of a ten year follow up study. *Surgeon.* 2007;5(1):3–7.

Poulin EC, Schlachta CM, Mamazza J. Laparoscopic splenectomy. In: Souba WW, ed. *ACS Surgery: Principles and Practice.* New York, NY: WebMD Inc; 2005:578–580.

۰۲۱-۶۶۱۹۸۵۱۴ www.myuptodate.com دریافت آخرین نسخه آپتودیت آفلاین

1E15

Key word: Diagnostic Test of Possible Abdominal Lymphoma

Author: Robert A. Meguid, MD, MPH
Editor: Anne O. Lidor, MD, MPH

A 42-year-old man presents with progressive fullness and abdominal cramping increasing in severity over the past 4 weeks. Computed tomography (CT) reveals a large intra-abdominal mass with multiple enlarged inguinal and cervical lymph nodes visible. Which of the following tests is diagnostic of this patient's possible intra-abdominal lymphoma?

(A) CT scan
(B) CT-guided needle biopsy
(C) Open biopsy
(D) Positron emission tomography (PET) scan
(E) T_2-weighted magnetic resonance imaging (MRI)

Answer: (C) Open biopsy

Rationale:
Lymphoma accounts for 15% of primary malignant neoplasms occurring in the small intestine. Diagnosis is made by histologic examination of tissue, which is usually obtained via cervical or axillary lymph node biopsy. In the case of gastric lymphoma, biopsy can be obtained endoscopically. Some abdominal lymphomas may be amenable to laparoscopic rather than open biopsy.

Histologic diagnosis is based upon examination of the cellular milieu, consisting of Reed–Sternberg cells (multinucleated giant cells), lymphocytes, histiocytes, granulocytes, fibroblasts, and plasma cells.

CT and MRI can be useful diagnostic adjuncts but will not provide definitive diagnosis. On T_1-weighted MRI, solid structures appear bright. In contrast, on T_2-weighted MRI, fluid-containing tissues appear bright. PET scans show brightness in areas of metabolic hyperactivity. CT-guided needle biopsy is only useful in obtaining tissue for diagnosis where tissue architecture is not critical to diagnosis.

More than half of patients with lymphoma of the small intestines present with masses greater than 5 cm. Therefore, while a large, intra-abdominal lymphoma would be visible on CT scan, T_1-weighted MRI, and PET scan, diagnosis could not be confirmed. In addition, open or laparoscopic biopsy of lymph nodes is preferable to CT-guided needle biopsy of the intra-abdominal mass.

References:
Bowles TL, Amos KD, Hwang RF, et al. Small bowel malignancies and carcinoid tumors. In: Feig BW, Ching CD, eds. *The M.D. Anderson Surgical Oncology Handbook.* 5th ed. Philadelphia, PA: Lippincott Williams and Wilkins; 2012.

Bowne WB, Zenilman ME. Gastrointestinal tract and abdomen. In: Souba WW, ed. *ACS Surgery: Principles and Practice.* New York, NY: WebMD, revised August 2004. Accessed April 9, 2006. Online Edition.

Choi SW, Ryu J. Lymphoma and sarcoma. In: Fleischer KJ, ed. *Advanced Surgical Recall.* Philadelphia, PA: Williams and Wilkins; 1995:616–622.

1E16

Key word: Workup of Thyroid Nodule

Author: Konstantinos I. Makris, MD
Editor: Martha A. Zeiger, MD, FACS

A 45-year-old woman was found on physical examination to have a right thyroid nodule. Ultrasound of the thyroid demonstrated a 2.5-cm hypoechoic nodule, which was identified as papillary thyroid cancer on fine-needle aspiration (FNA). What is the best next step in the management of this patient?

(A) Obtain computed tomography (CT) scan of the neck
(B) Obtain integrated positron emission tomography and computed tomography (PET–CT) scan for complete staging
(C) Obtain ultrasound of the neck to evaluate for lymphadenopathy
(D) Proceed to surgery without other studies
(E) Repeat the FNA to confirm the diagnosis

Answer: (C) Obtain ultrasound of the neck to evaluate for lymphadenopathy

Rationale:
This patient with papillary thyroid cancer will need a thyroidectomy. Before proceeding with surgery, she needs to undergo evaluation of her cervical lymph nodes to evaluate for possible metastatic disease with ultrasound as she has only undergone a dedicated thyroid ultrasound. Ultrasound of the neck is recommended for all patients undergoing thyroidectomy for malignant cytologic findings on FNA according to American Thyroid Association guidelines. Ultrasound-guided FNA of suspicious lymph nodes is recommended as positive findings would change the surgical plan, necessitating lateral neck dissection in addition to thyroidectomy. There is no role for routine preoperative use of CT, magnetic resonance imaging (MRI), or integrated PET–CT scan.

Well-differentiated thyroid cancer (papillary, follicular variant of papillary, follicular, Hürthle cell) is metastatic to cervical lymph nodes in as many as 50% of patients. Preoperative neck ultrasound detects suspicious lymph nodes in 20% to 30% of cases, leading to change of the surgical plan in as many as 20% of patients. This supports the need for preoperative staging, which is best performed with ultrasound. No benefit has been proven with the routine use of the other imaging modalities.

An FNA result of papillary thyroid cancer does not need confirmation prior to surgical resection.

References:
Burns WR, Zeiger MA. Differentiated thyroid cancer. *Semin Oncol.* 2010;37(6):557–566.

Cooper DS, Doherty GM, Haugen BR, et al. Revised American Thyroid Association management guidelines for patients with thyroid nodules and differentiated thyroid cancer. *Thyroid.* 2009;19(11):1167–1214.

۰۲۱-۶۶۱۹۸۵۱۴ www.myuptodate.com دریافت آخرین نسخه آپتودیت آفلاین

1E17

Key word: Treatment of Intraductal Papilloma of the Breast

Author: Robert A. Meguid, MD, MPH
Editors: Julie R. Lange, MD, ScM, FACS, and Mehran Habibi, MD, MBA

A 35-year-old woman presents with complaint of a bloody discharge from the left nipple. Clinical breast examination confirms inducible discharge from a single duct in the left nipple and a small palpable mass near the inferior areolar margin. Bilateral mammogram and left ultrasound show a small density that appears to correspond to the palpable mass, which measures 8 mm by ultrasound and is solid. The lesion is amenable to ultrasound-guided core biopsy. Which of the following is correct?

(A) If a core biopsy confirms a benign papilloma, no further intervention is needed

(B) If core-needle biopsy confirms intraductal papilloma, then proceed to local excision with postoperative routine breast screening examination

(C) If local excision shows DCIS, the patient can return to routine breast screening with no further intervention needed

(D) This is most likely a benign process, does not need to be biopsied, and should be followed with clinical breast examination and mammogram every 6 months

(E) Unilateral bloody discharge is usually associated with a history of breast trauma

Answer: **(B)** If core-needle biopsy confirms intraductal papilloma, then proceed to local excision with postoperative routine breast screening examination

Rationale:

Benign nipple discharge is frequently bilateral, clear or milky and occurs commonly with nipple manipulation. Negative workup, including clinical breast examination, ultrasound, and mammogram, should be followed by a second, delayed examination. Nipple discharge that is unilateral, serous or sanguinous, and spontaneous, can be either benign or malignant in origin. Such discharge requires evaluation that generally should start with mammogram and ultrasound, with further evaluation guided by the results of the radiologic studies. If a lesion is found that can be targeted for a radiologic-guided core biopsy, this is usually the preferred first method of evaluation. If no lesion is found on ultrasound, the MRI sometimes can be helpful.

Intraductal papillomas typically present with unilateral bloody or serous discharge from the breast. They may occasionally be palpable depending on their size, or subsequently detected on ultrasound, mammography, or core-needle biopsy. While intraductal papillomas are benign, any proliferative breast change is probably associated with a small increase in risk of breast cancer. Therefore, the finding of intraductal papilloma on a core biopsy warrants excisional biopsy of the area to rule out a coexistent early cancer.

References:

Gadd MA. Management of benign breast disease. In: Cameron JL, Cameron AM, eds. *Current Surgical Therapy.* 10th ed. Philadelphia, PA: Mosby; 2011:509–512.

Iglehart JD. The breast. In: Sabiston DC, Lyerly HK eds. *Textbook of Surgery.* 15th ed. Philadelphia, PA: W.B. Saunders; 1997:568.

Kass R, Lind DS, Souba WW. Breast, skin and soft tissue. In: Souba WW, ed. *ACS Surgery: Principles and Practice.* New York, NY: WebMD, revised December 2005. Accessed April 9, 2007. Online Edition.

۰۲۱-۶۶۱۹۸۵۱۴ www.myuptodate.com دریافت آخرین نسخه آپتودیت آفلاین

1E18

Key word: Interpretation of Thyroid FNA

Author: Konstantinos I. Makris, MD
Editor: Martha A. Zeiger, MD, FACS

A 52-year-old woman was found to have a single left thyroid nodule measuring 3 cm on ultrasound. She has no known risk factors for thyroid cancer and denies any compressive symptoms in the neck. Her thyroid function tests are normal and fine-needle aspiration (FNA) was performed. Cytology examination reported "follicular neoplasm" as the diagnosis. What is the next best step in the management of this patient?

(A) Obtain a core-needle biopsy of the suspicious nodule

(B) Obtain a radioactive iodine thyroid scan

(C) Perform left hemithyroidectomy

(D) Perform left hemithyroidectomy with intraoperative frozen section to decide on need for total thyroidectomy

(E) Repeat the FNA

Answer: (C) Perform left hemithyroidectomy

Rationale:

The best next step is to proceed with a left hemithyroidectomy. FNA of a thyroid nodule can result in six potential diagnoses according to guidelines known as "the Bethesda criteria": (1) *Benign*—There is minimal risk for malignancy, and the nodule can be observed; (2) *Atypia of undetermined significance*—5% to 10% risk of malignancy and a repeat FNA or thyroid resection is recommended; (3) *Follicular neoplasm*—20% to 30% risk of malignancy, and thyroid resection is recommended for accurate diagnosis; (4) *Suspicious for malignancy*—50% to 75% risk of malignancy, and curative resection is recommended; (5) *Malignant*—98% to 100% risk of malignancy, and curative resection is recommended; (6) *Inadequate*—Insufficient amount of cells for evaluation, and the FNA needs to be repeated.

The decision regarding the surgical approach is based not only on the FNA results, but also on the presence of additional thyroid nodules, the presence of compressive symptoms, personal risk factors for thyroid cancer (i.e., family history for thyroid cancer, radiation exposure of the neck), and the patient's preference. Surgical resection, usually in the form of hemithyroidectomy, is needed to determine the presence of a benign or malignant lesion for the result of "follicular neoplasm" on FNA. Intraoperative frozen section cannot accurately make this determination. If a thyroid cancer is diagnosed on permanent pathologic evaluation, resection of the contralateral thyroid lobe (i.e., completion thyroidectomy) may be indicated during a second operation.

Although the workup of a follicular neoplasm can include a thyroid scan, this is usually only indicated when hyperthyroidism is present as indicated by a low thyroid-stimulating hormone (TSH) level. In general, thyroid scan in the workup of a thyroid nodule is indicated when the TSH is low, in order to identify whether or not a nodule is hyperfunctioning and needs to be resected.

Obtaining a core-needle biopsy is not recommended in the routine workup of thyroid nodules.

References:

Baloch ZW, LiVolsi VA, Asa SL, et al. Diagnostic terminology and morphologic criteria for cytologic diagnosis of thyroid lesions: A synopsis of the National Cancer Institute Thyroid Fine-Needle Aspiration State of the Science Conference. *Diagn Cytopathol.* 2008;36(6):425–437.

Cooper DS, Doherty GM, Haugen BR, et al. Revised American Thyroid Association management guidelines for patients with thyroid nodules and differentiated thyroid cancer. *Thyroid.* 2009;19(11):1167–1214.

۰۲۱-۶۶۱۹۸۵۱۴ www.myuptodate.com دریافت آخرین نسخه آپتودیت آفلاین

1E19

Key word: Sequence of Treatment in Multiple Endocrine Neoplasia

Author: Jacqueline Garonzik-Wang, MD, PhD
Editor: Anne O. Lidor, MD, MPH

A 40-year-old woman has been recently diagnosed with multiple endocrine neoplasia type IIa (MEN 2A). Her most recent laboratory studies are significant for elevated urinary metanephrines and hypercalcemia. A cold thyroid nodule has been identified on radioisotope imaging and computed tomography of the abdomen reveals a left adrenal mass. She has elected to undergo operative intervention and asks you which surgical procedure should be performed first. Based on current recommendations, you schedule her for the following procedure:

(A) Adrenalectomy

(B) Pituitary adenectomy

(C) Single-gland parathyroidectomy

(D) Thyroid lobectomy

(E) Total thyroidectomy alone

Answer: **(A)** Adrenalectomy

Rationale:

MEN 2A is associated with pheochromocytoma, hyperparathyroidism, and medullary thyroid carcinoma (MTC). Patients with the diagnosis of MEN 2 or MTC should be tested for pheochromocytoma. If pheochromocytoma is confirmed, the surgeon should first proceed with adrenalectomy. Given the hyperadrenergic state associated with pheochromocytoma, patients need at least 2 weeks of preoperative preparation, intravenous fluid resuscitation, and documented hemodynamic stability before consideration is given to further operative management. Alpha-adrenergic blockage followed by beta blockade may be necessary.

Once adrenalectomy is performed and adrenergic tone has been normalized, the patient may safely undergo further surgical procedures. Successful adrenalectomy can be followed by neck exploration 1 to 2 weeks later.

The remaining options listed above are not recommended surgical treatments for other syndromes associated with MEN 2A. Parathyroid hyperplasia is treated with resection of three and a half glands or four-gland parathyroidectomy with autoimplantation. MTC is treated with total thyroidectomy and central lymph node dissection.

Multiple Endocrine Neoplasia Syndromes

MEN 1	MEN 2A	MEN 2B
Parathyroid hyperplasia	Pheochromocytoma	Pheochromocytoma
Pancreatic islet cell tumors	Medullary thyroid carcinoma	Medullary thyroid carcinoma
Pituitary adenomas	Parathyroid hyperplasia	Marfanoid habitus, MSK abnormalities

References:

Doherty GM. Parathyroid glands. In: Mulholland MW, Lillemoe KD, Doherty GM, Maier RV, Upchurch GR, eds. *Greenfield's Surgery: Scientific Principles & Practice.* 5th ed. Philadelphia, PA: Lippincott Williams and Wilkins. 2011.

Lairmore TC, Moley JF. The multiple endocrine neoplasia 2 syndromes. In: Townsend CM, Beauchamp RD, Evers BM, Mattox KL, eds. *Sabiston Textbook of Surgery.* 17th ed. Philadelphia, PA: Elsevier, 2004:1074–1085.

۰۲۱-۶۶۱۹۸۵۱۴ www.myuptodate.com دریافت آخرین نسخه آپتودیت آفلاین

1E20

Key word: Adrenal Incidentaloma

Author: Konstantinos I. Makris, MD
Editor: Martha A. Zeiger, MD, FACS

A 56-year-old man underwent a computed tomography (CT) scan of the abdomen for left lower quadrant abdominal pain. Mild diverticulitis was identified, and antibiotic therapy was provided. Incidentally, a 3-cm right adrenal mass was seen on the CT scan. After recovery from diverticulitis, he is seen in the surgical clinic for evaluation of the adrenal mass. Which of the following tests should be included in the workup?

(A) Check plasma aldosterone and renin levels, plasma-free metanephrine and normetanephrine levels, and a serum vanillylmandelic acid level

(B) Perform a dexamethasone suppression test and check plasma aldosterone and renin levels, plasma-free metanephrine and normetanephrine levels, and a serum vanillylmandelic acid level

(C) Perform a dexamethasone suppression test and check plasma aldosterone and renin levels and plasma-free metanephrine and normetanephrine levels

(D) Perform a dexamethasone suppression test and check plasma aldosterone and renin levels and a serum vanillylmandelic acid level

(E) Perform a dexamethasone suppression test and check plasma-free metanephrine and normetanephrine levels and a serum vanillylmandelic acid level

Answer: (C) Perform a dexamethasone suppression test and check plasma aldosterone and renin levels and plasma-free metanephrine and normetanephrine levels

Rationale:

Adrenal lesions that are incidentally identified during radiographic evaluation for other reasons are referred to as adrenal "incidentalomas," and their incidence is estimated to be 6% in patients undergoing abdominal CT scans. They can be benign adrenal adenomas (functional or nonfunctional) or adrenal malignancies (primary or metastatic), and their evaluation should be aimed at identifying whether they are hormonally functional or not and whether they are benign or malignant.

Adrenal "incidentalomas" are primarily worked up for evidence of hypercortisolism, a pheochromocytoma, or hyperaldosteronism. The recommended screening tests are therefore a low-dose (1-mg) dexamethasone suppression test, checking plasma-free metanephrine and normetanephrine levels, and calculation of the plasma aldosterone concentration:plasma renin activity ratio.

The malignant potential of the adrenal incidentalomas is evaluated with an abdominal ("adrenal protocol") CT scan. Size less than 4 cm, radiodensity less than 10 Hounsfield units on nonenhanced CT images, and rapid contrast "washout" (>50% in 10 minutes) of the adrenal lesion favor the diagnosis of benign pathology. Fine-needle aspiration is used rarely and mainly reserved for diagnosing metastases to the adrenal glands. If performed, pheochromocytoma must be excluded beforehand.

Adrenalectomy is indicated for "incidentalomas" greater than 4 cm in size due to increased risk of malignancy, radiographically indeterminate lesions, and/or growing lesions (growth of 0.8 cm in ≤12 months). Adrenalectomy is also indicated for hormonally active lesions.

References:

Young WF Jr. Clinical practice. The incidentally discovered adrenal mass. *N Engl J Med.* 2007;356(6):601–610.

Zeiger MA, Siegelman SS, Hamrahian AH. Medical and surgical evaluation and treatment of adrenal incidentalomas. *J Clin Endocrinol Metab.* 2011;96(7):2004–2015.

۰۲۱-۶۶۱۹۸۵۱۴ www.myuptodate.com دریافت آخرین نسخه آپتودیت آفلاین

1E21

Key word: Characteristics and Treatment of Multiple Endocrine Neoplasia

Author: Benjamin S. Brooke, MD, PhD
Editor: Alan P.B. Dackiw, MD, PhD, BSc, BSc(Med), FACS, FRCSC

A 2-month-old male child is born to a mother with a Marfanoid habitus and a history of pheochromocytoma. He undergoes genetic testing and is found to have a mutation in the RET oncogene. What should be the initial goal in the management of this patient?

(A) Careful observation

(B) Computed tomography (CT) scanning to look for pheochromocytoma in retroperitoneal space

(C) Positron emission tomography (PET) scan to evaluate for other tumors

(D) Total parathyroidectomy with heterotopic autotransplantation by 5 years of age

(E) Total thyroidectomy with central lymph node dissection within the first 6 months of age

Answer: (E) Total thyroidectomy with central lymph node dissection within the first 6 months of age

Rationale:
Multiple endocrine neoplasia type 2 (MEN 2) is an autosomal dominant syndrome characterized by a disposition to the development of tumors in multiple endocrine organs. MEN 2 is caused by germline mutations in the RET oncogene with variable phenotypic expression that can be divided into different subtypes (A and B). MEN 2A accounts for approximately 75% of MEN 2 and is a syndrome that includes medullary thyroid cancer (MTC) in 90%, unilateral or bilateral pheochromocytoma in 50%, and multi-gland parathyroid tumors in 20% to 30% of adult gene carriers. MEN 2B is the more aggressive variant of MEN 2, characterized by the same two major neoplasms of MEN 2A (MTC and pheochromocytoma), in addition to having a marfanoid habitus and mucosal/intestinal ganglioneuromatosis.

RET gene mutation testing has largely replaced serum calcitonin level testing in diagnosing the MEN 2 carrier state, and determining the likely age of onset and aggressiveness of MTC in these patients. Children with MEN 2B have the highest risk of developing medullary thyroid cancer and should have a total thyroidectomy within the first 6 months of age, as the finding of microscopic MTC in these patients within the first year of life is common. The operation should include a central lymph node dissection, with more extensive exploration if positive nodes are found. Pheochromocytomas usually appear in the second or third decade of life, and can be screened for using 24-hour urine catecholamine and plasma metanephrine levels, followed by CT or MRI. Hyperparathyroidism develops in about a third of patients with MEN 2A, but rarely develops in MEN 2B.

References:
Brandi ML, Gagel RF, Angeli A, et al. Consensus guidelines for diagnosis and therapy of MEN type 1 and type 2. *J Clin Endocrinol Metab.* 2001;86:5658–5671.

Doherty GM. Parathyroid glands. In: Mulholland MW, Lillemoe KD, Doherty GM, Maier RV, Upchurch GR, eds. *Greenfield's Surgery: Scientific Principles & Practice.* 5th ed. Philadelphia, PA: Lippincott Williams and Wilkins; 2011.

۰۲۱-۶۶۱۹۸۵۱۴ www.myuptodate.com دریافت آخرین نسخه آپتودیت آفلاین

1E22

Key word: Indications for Surgery in Primary Hyperparathyroidism

Author: Konstantinos I. Makris, MD
Editor: Martha A. Zeiger, MD, FACS

During routine blood testing, a 52-year-old man is found to have a serum calcium level of 11 mg/dL (normal 8.5 to 10.5 mg/dL). His primary physician suspects hyperparathyroidism and checks a parathyroid hormone (PTH) level, which is 65 pg/mL (normal 10 to 65 pg/mL). He has no history of renal stones or bone fractures. Which of the following is an indication for this patient to undergo surgery?

(A) 24-hour urine calcium of 300 mg/dL

(B) Bone density suggestive of osteopenia (T-score −1.9)

(C) Diffuse musculoskeletal pains and irritability

(D) No surgery is indicated, since PTH is normal

(E) Serum creatinine of 1.5 mg/dL

Answer: (C) Diffuse musculoskeletal pains and irritability

Rationale:

Primary hyperparathyroidism is caused by a single parathyroid adenoma, double parathyroid adenomas, parathyroid hyperplasia, or parathyroid carcinoma. The diagnosis is made with biochemical testing that typically reveals both an elevated serum calcium and serum PTH level. Frequently, primary hyperparathyroidism is also diagnosed when an elevated serum calcium level is accompanied by an "inappropriately high PTH level," within the normal range, such as in the above case. In a patient with hypercalcemia, the serum PTH level would typically be low, as a result of negative feedback inhibition. The inappropriately high normal PTH in this case is suggestive of hyperparathyroidism.

Surgery is indicated for symptomatic patients, for example, experiencing muscle aches and bony pain, irritability, and renal calculi formation. It is also indicated for patients with asymptomatic hyperparathyroidism that meet one of the National Institutes of Health criteria established in 2002: (1) Serum calcium elevated by 1 mg/dL above normal; (2) 24-hour urine calcium >400 mg/day; (3) creatinine clearance reduced by 30%; (4) T-score worse than −2.5 at any site; (5) age younger than 50 years; (6) when surveillance is difficult or impossible; (7) patient preference. Some modifications of the above criteria have been made at subsequent international workshops, notably change of the renal function criterion to creatinine clearance <60 mL/min, and elimination of the 24-hour urine calcium criterion.

References:

Augustine MM, Bravo PE, Zeiger MA. Surgical treatment of primary hyperparathyroidism. *Endocr Pract.* 2011; 17(Suppl 1):75–82.

Bilezikian JP, Khan AA, Potts JT. Guidelines for the management of asymptomatic primary hyperparathyroidism: Summary statement from the third international workshop. *J Clin Endocrinol Metab.* 2009;94(2):335–339.

Lew JI, Solorzano CC. Surgical management of primary hyperparathyroidism: State of the art. *Surg Clin North Am.* 2009; 89(5):1205–1225.

۰۲۱-۶۶۱۹۸۵۱۴ www.myuptodate.com دریافت آخرین نسخه آپتودیت آفلاین

1E23

Key word: Interpretation of Intraoperative Parathyroid Hormone Assay

Author: Robert A. Meguid, MD, MPH
Editors: Martha A. Zeiger, MD, FACS, and Konstantinos I. Makris, MD

A sestamibi scan reveals a hyperfunctioning parathyroid adenoma in the superior right position in a 53-year-old woman with hypercalcemia. Preoperative parathyroid hormone (PTH) level is measured to be 200 pg/mL. After removal of the suspected parathyroid adenoma, a decrease in PTH to which of the following levels within the specified time frame would signify that the only hyperfunctioning gland had been successfully removed?

(A) 125 pg/mL in 10 minutes
(B) 132 pg/mL in 5 minutes
(C) 43 pg/mL in 30 minutes
(D) 65 pg/mL in 20 minutes
(E) 99 pg/mL in 10 minutes

Answer: (E) 99 pg/mL in 10 minutes

Rationale:

Primary hyperparathyroidism is a result of autonomous production of PTH by a parathyroid adenoma, hyperplasia, or carcinoma. Although a single adenoma is the most common cause, in 20% of patients with primary hyperparathyroidism the cause is hyperplasia of the parathyroid glands. Furthermore, while most hyperfunctioning glands are enlarged, not all enlarged glands are hyperfunctioning. These issues create difficulties in the intraoperative decision on the adequacy of the extent of parathyroidectomy.

Normal PTH is 10 to 65 pg/mL. Intraoperatively, a drop in the PTH levels measured at 10 minutes after removal of the suspected abnormal parathyroid gland, greater than 50% compared to the highest (pre-incision or pre-excision) PTH level ("Miami criterion"), is predictive of surgical success and long-term normocalcemia.

The ^{99m}technetium sestamibi scintigraphy ("Sestamibi scan") relies on prolonged uptake of radionuclide into abnormally functioning parathyroid glands, has 50% to 60% sensitivity and 75% specificity. It is most favorably used in patients who have not undergone previous neck explorations, and who have single-gland adenomas.

References:

Doherty GM. Pararthyroid glands. In: Mulholland MW, Lillemoe KD, Doherty GM, Maier RV, Upchurch GR, eds. *Greenfield's Surgery: Scientific Principles & Practice.* 5th ed. Philadelphia, PA: Lippincott Williams and Wilkins; 2011.

Irvin GL 3rd, Solorzano CC, Carneiro DM. Quick intraoperative parathyroid hormone assay: Surgical adjunct to allow limited parathyroidectomy, improve success rate, and predict outcome. *World J Surg.* 2004;28(12):1287–1292.

1E24

Key word: Lymphadenopathy in Thyroid Cancer

Author: Konstantinos I. Makris, MD
Editor: Martha A. Zeiger, MD, FACS

A 63-year-old woman undergoes fine-needle aspiration (FNA) of a 2-cm right thyroid nodule and is diagnosed with papillary thyroid cancer. On subsequent ultrasound of her neck, an enlarged right-sided lymph node is identified close to the jugular vein and is biopsied by FNA. Cytologic examination reveals metastatic papillary thyroid cancer. What is the recommended overall treatment plan for this patient?

(A) Total thyroidectomy with central and bilateral neck lymphadenectomy followed by external beam radiation
(B) Total thyroidectomy with central and bilateral neck lymphadenectomy
(C) Total thyroidectomy with central and right lateral neck lymphadenectomy followed by radioactive iodine therapy
(D) Total thyroidectomy with right lateral neck lymphadenectomy
(E) Total thyroidectomy with right lateral neck lymphadenectomy followed by external beam radiation

Answer: (C) Total thyroidectomy with central and right lateral neck lymphadenectomy followed by radioactive iodine therapy

Rationale:

The recommended approach for a patient with thyroid cancer and regional lymph node metastases is total thyroidectomy, central and ipsilateral neck dissection followed by radioactive iodine therapy.

Palpable or suspicious lateral cervical lymph nodes on ultrasound in a patient with thyroid cancer should be biopsied by fine-needle aspiration (FNA) for confirmation of metastatic disease. Lateral cervical lymphadenectomy (usually levels II to IV, and occasionally level V) is indicated on the side of the involved lymph node. There is no need for lymphadenectomy of the contralateral side if there is no evidence of metastatic disease. The central neck compartment should also be dissected in high-risk patients such as in this scenario, even in the absence of preoperative findings. The central neck is the most common site for metastases in papillary thyroid cancer, and is usually involved when lateral lymph nodes are positive.

Radioactive iodine is used postoperatively as adjuvant therapy for patients with well-differentiated thyroid cancer and a high risk of recurrence. Size of primary tumor >1cm, aggressive histology, such as tall cell variant or presence of capsular invasion, and metastatic disease are indications for postoperative radioactive iodine therapy.

External beam radiation is not typically used in the treatment of well-differentiated thyroid cancers.

۰۲۱-۶۶۱۹۸۵۱۴ www.myuptodate.com دریافت آخرین نسخه آپتودیت آفلاین

References:
Burns WR, Zeiger MA. Differentiated thyroid cancer. *Semin Oncol.* 2010;37(6):557–566.
Cooper DS, Doherty GM, Haugen BR, et al. Revised American Thyroid Association management guidelines for patients with thyroid nodules and differentiated thyroid cancer. *Thyroid.* 2009;19(11):1167–1214.

1E25

Key word: Characteristics of Addisonian Crisis

Author: Robert A. Meguid, MD, MPH
Editor: Alan P.B. Dackiw, MD, PhD, BSc, BSc(Med), FACS, FRCSC

On postoperative day 3, after undergoing an exploratory laparotomy, distal pancreatectomy, splenectomy, and fixation of a left femur fracture after a motor vehicle collision, a 46-year-old man is found to be lethargic, confused, and vomiting. His blood pressure is 90/40 mm Hg, serum glucose is 45 mg/dL, serum sodium is 121 mEq/L, serum potassium is 5.3 mEq/L, hemoglobin 11.2 mg/dL. Which of the following is the most likely cause accounting for his condition?

(A) Acute adrenal insufficiency
(B) Internal bleeding
(C) Pituitary infarction
(D) Pulmonary embolism
(E) Volume overload with lactated Ringer solution

Answer: (A) Acute adrenal insufficiency

Rationale:
While all of the possible answers could be associated with confusion, only the diagnosis of acute adrenal insufficiency would be able to specifically account for the constellation of signs and symptoms presented. In addition, acute hypopituitarism is associated with diabetes insipidus, hypernatremia, hypokalemia, and normoglycemia. Acute adrenal insufficiency, or addisonian crisis, occurs when the hypothalamic–pituitary axis is acutely suppressed. Causes include patients on steroids that are discontinued abruptly, autoimmune or infectious adrenalitis and surgical resection. In trauma, severe hemorrhagic shock without adrenal resection has been associated with the development of adrenal insufficiency. Patients present with lethargy, confusion, nausea and vomiting, and abdominal pain, and develop hypotension, hyponatremia, hyperkalemia, and hypoglycemia. Symptoms worsen and include severe acidosis and dehydration, culminating in hypovolemic shock.

Acute management of a patient in addisonian crisis includes fluid resuscitation with normal saline, glucose and electrolyte repletion, and systemic steroids.

References:
Hedican SP. Urology. In: Fleischer KJ, ed. *Advanced Surgical Recall.* Philadelphia, PA: Williams and Wilkins; 1995: 1227–1308.
Lingappa VR. Disorders of the hypothalamus and pituitary gland. In: McPhee SJ, Lingappa VR, Ganong WF, Lange JD, eds. *Pathophysiology of Disease.* 3rd ed. New York, NY: Lange Medical Books/McGraw-Hill; 2000:459–480.
Olson JA, Scheri RP. Adrenal gland. In: Mulholland MW, Lillemoe KD, Doherty GM, Maier RV, Upchurch GR, eds. *Greenfield's Surgery: Scientific Principles & Practice.* 5th ed. Philadelphia, PA: Lippincott Williams and Wilkins; 2011.

۰۲۱-۶۶۱۹۸۵۱۴ www.myuptodate.com دریافت آخرین نسخه آپتودیت آفلاین

1E26

Key word: Diagnosis of Insulinoma

Author: Konstantinos I. Makris, MD
Editor: Martha A. Zeiger, MD, FACS

A 56-year-old man is admitted after recurrent episodes of confusion and loss of consciousness. His serum glucose is 45 mg/dL, raising the suspicion of insulinoma. Which of the following tests are *NOT* necessary for confirmation of the diagnosis?

(A) Pancreas protocol abdominal computed tomography (CT)

(B) Serum C peptide level

(C) Serum insulin level

(D) Serum proinsulin level

(E) Serum sulfonylurea level

Answer: **(A)** Pancreas protocol abdominal computed tomography (CT)

Rationale:
The diagnosis of insulinoma is established by documenting "Whipple triad": Neuroglycopenic (visual changes, altered mental status, weakness, seizures) or sympathetic adrenergic (palpitations, sweating, tremors) symptoms with hypoglycemia (blood sugar <50 mg/dL) and resolution of symptoms with food. These symptoms should be documented during a 48-hour monitored fast. The diagnosis also requires an elevated serum insulin level (>5 to 10 μUnits/mL). Other causes of fasting hypoglycemia, such as pancreatic islet disease other than insulinoma, or factitious use of excessive insulin or oral hypoglycemic agents, need to be excluded by testing for serum proinsulin and C peptide, both of which will be high in the setting of an insulinoma and low with exogenous insulin administration. Serum sulfonylureas, which will be absent in the setting of an insulinoma and high with factitious insulin use, must also be checked.

Imaging studies are not necessary for the diagnosis but are useful for localizing the insulinoma and evaluating for metastatic disease. Usually a combination of imaging studies is used for preoperative localization of the tumor, with endoscopic ultrasound considered the most sensitive test. Because most insulinomas are small and intrapancreatic, preoperative localization fails 10% to 27% of the time. The most sensitive modality for accurate localization of the insulinoma is intraoperative ultrasound combined with palpation of the pancreas.

Reference:
Mathur A, Gorden P, Libutti SK. Insulinoma. *Surg Clin North Am.* 2009;89(5):1105–1121.

1E27

Key word: Effect of Superior Laryngeal Nerve Injury

Author: Ying Wei Lum, MD
Editors: Martha A. Zeiger, MD, FACS, and Konstantinos I. Makris, MD

An opera singer who recently underwent total thyroidectomy returns for her postoperative visit reporting voice fatigue and an inability to sing high notes. Her total calcium level is 9.1 mg/dL (normal 9.0 to 10.5 mg/dL). This complication could have been prevented by which of the following?

(A) It is unavoidable, symptoms are due to transient postoperative hypocalcemia and will resolve

(B) Ligation of individual branches of the superior thyroid artery at the level of the thyroid capsule

(C) Ligation of middle thyroid artery at its origin

(D) Performing a careful dissection to avoid injury to the parathyroid glands

(E) Use of an intraoperative functional nerve stimulator to localize the recurrent laryngeal nerve

Answer: **(B)** Ligation of individual branches of the superior thyroid artery at the level of the thyroid capsule

Rationale:
The use of an intraoperative functional nerve stimulator is helpful in assisting in the identification of the recurrent laryngeal nerve. Even with the nerve stimulator, the rate of recurrent laryngeal nerve injury is still approximately 1%.

The injury suffered by the opera singer is to the external branch of the superior laryngeal nerve with an incidence of 15% to 68%. This occurs frequently because the external branch of the superior laryngeal nerve crosses the superior thyroid artery at variable positions (Type 1, Type 2a, and Type 2b). The only way to prevent injury to the external branch of the superior laryngeal nerve is careful ligation of the superior thyroid artery branches at the level of the thyroid capsule.

Typical blood supply to the thyroid gland is via bilateral superior and inferior thyroid arteries, with drainage via bilateral superior, middle, and inferior thyroid veins. There is no middle thyroid artery.

Reference:
Miller BS, Gauger PG. Thyroid gland. In: Mulholland MW, Lillemoe KD, Doherty GM, Maier RV, Upchurch GR, eds. *Greenfield's Surgery: Scientific Principles & Practice.* 5th ed. Philadelphia, PA: Lippincott Williams and Wilkins; 2011.

۰۲۱-۶۶۱۹۸۵۱۴ www.myuptodate.com دریافت آخرین نسخه آپتودیت آفلاین

1E28

Key word: Prognostic Factors for Thyroid Cancer

Author: Robert A. Meguid, MD, MPH
Editors: Martha A. Zeiger, MD, FACS, and Konstantinos I. Makris, MD

A 38-year-old woman undergoes left thyroid lobectomy for a palpable nodule with indeterminate pathology on preoperative fine-needle aspiration. The specimen is sent to pathology for examination. Which of the following factors paired with the appropriate diagnosis is associated with the poorest prognosis for this patient?

(A) 1.7-cm solitary nodule with medullary carcinoma

(B) Encapsulated, noncystic follicles with follicular carcinoma

(C) MEN 2B with medullary carcinoma

(D) Presence of lymph node disease with papillary carcinoma

(E) Psammoma bodies with anaplastic carcinoma

Answer: (C) MEN 2B with medullary carcinoma

Rationale:

Medullary carcinoma is associated with occurrence of regional metastases early in the disease, usually by the time the primary nodule is 2 cm in diameter. The 10-year survival rate for patients with regional metastases is 70%. On the contrary, medullary carcinoma associated with MEN 2B, which itself is associated with early metastases, has a 5-year survival rate of less than 5%.

Factors associated with poor prognosis for papillary carcinoma of the thyroid gland include poorly differentiated cellular histology and extrathyroidal extension. While psammoma bodies are characteristically associated with papillary (not anaplastic) carcinoma, they are not indicative of poor differentiation or of worse outcome. Overall, papillary carcinoma has the best prognosis of all the common thyroid malignancies.

The presence of lymph node metastases only factors into ACJJ staging for thyroid cancer for patients aged 45 years and older. Therefore, any degree of lymph node involvement would characterize this 38-year-old patient's disease as Stage I or II only, associated with a favorable prognosis in the setting of papillary carcinoma.

Prognosis for noninvasive follicular carcinoma, which is generally encapsulated, and composed of highly cellular, noncystic follicles, is associated with a 60% to 90% survival rate at 5 years.

Anaplastic carcinoma has the overall worst prognosis, due to a high rate of local invasion as well as regional and distant metastases at the time of diagnosis. The 5-year survival rate is 7%.

References:

McHenry CR, Jin J. Management of thyroid cancer. In: Cameron JL, Cameron AM, eds. *Current Surgical Therapy.* 10th ed. Philadelphia, PA: Mosby; 2011:602–610.

Thomas RM, Hebra MA, Perrier ND, et al. Well-differentiated carcinoma of the thyroid and neoplasms of the parathyroid glands. In: Feig BW, Ching CD, eds. *The M.D. Anderson Surgical Oncology Handbook.* 5th ed. Philadelphia, PA: Lippincott Williams and Wilkins; 2012.

۰۲۱-۶۶۱۹۸۵۱۴ www.myuptodate.com دریافت آخرین نسخه آپتودیت آفلاین

1E29

Key word: Treatment of "Missing" Parathyroid

Author: Jordan M. Winter, MD
Editor: Alan P.B. Dackiw, MD, PhD, BSc, BSc(Med), FACS, FRCSC

A 62-year-old woman with a serum calcium level of 11.4 mg/dL, elevated intact parathyroid hormone level (iPTH), and a recent history of kidney stones underwent a bilateral neck exploration. Two normal parathyroid glands were identified on the right side, and one normal superior parathyroid gland was identified posterior to the superior pole of the left thyroid lobe. The thymus and the side of the neck with the missing gland were thoroughly explored but no abnormal masses were found. What should the surgeon do next?

(A) Biopsy each of the glands since visual inspection is a poor indicator of abnormal pathology

(B) End the operation and perform noninvasive imaging to localize the abnormal parathyroid tissue

(C) Perform a left thyroid lobectomy

(D) Remove the identified parathyroid glands one at a time, until the iPTH level drops to half the baseline level.

(E) Remove the three identified glands, and autotransplant one of them into the non-dominant forearm

Answer: (C) Perform a left thyroid lobectomy

Rationale:

This patient has primary hyperparathyroidism, which is caused by a single adenoma in the majority of cases (75%). Four-gland hyperplasia occurs less frequently, although it is more common than two- and three-gland hyperplasia. Visual inspection remains an important and reliable tool for the experienced endocrine surgeon. While an enlarged parathyroid gland is not necessarily hyperfunctioning, nearly all hyperfunctioning glands are enlarged. Thus, normal-appearing tissue should not be excised. Biopsy of normal-appearing parathyroids is also not routinely performed. Frozen section can be useful to confirm the presence of parathyroid tissue, but is not useful for distinguishing normal from diseased parathyroid tissue. The iPTH level in conjunction with preoperative imaging is a useful adjunct for the surgeon when a limited surgical exploration is performed, as opposed to a conventional full neck exploration. A decrease in the iPTH level by 50% after removal of an enlarged parathyroid predicts long-term normal calcium levels and obviates the need for further exploration. Since an abnormal parathyroid gland had not been observed or removed in this particular case presentation, an iPTH assay is not applicable. Patients rarely have fewer than four parathyroid glands, and when a gland is missing from its normal location, a systematic search for an ectopic thyroid must be performed. Superior parathyroid glands, derived from the fourth pharyngeal pouch, are typically found lateral to the recurrent laryngeal nerve behind the upper pole of the thyroid at the level of the cricoid cartilage. Inferior parathyroid glands, derived from the third pharyngeal pouch, are more ventrally located toward the inferior pole of the thyroid. Fifteen percent of the time, the inferior glands are located within the thymus. If this has been ruled out, along with other locations accessible through the cervical incision (e.g., the carotid sheath, tracheoesophageal groove, anterior superior mediastinum, posterior super mediastinum), then removal of the ipsilateral thyroid lobe should be performed. Total parathyroidectomy with autotransplantation or subtotal parathyroidectomy is not indicated. Appropriate indications for these operations include primary hyperthyroidism associated with parathyroid hyperplasia, secondary hyperparathyroidism, or tertiary hyperparathyroidism.

References:

Doherty GM. Parathyroid glands. In: Mulholland MW, Lillemoe KD, Doherty GM, Maier RV, Upchurch GR, eds. *Greenfield's Surgery: Scientific Principles & Practice.* 5th ed. Philadelphia, PA: Lippincott Williams and Wilkins. 2011.

Roseman BJ, Clark OH. Thyroid and parathyroid procedures. In: Souba WW, Fink MP, Jurkovich GJ, Kaiser LR, Pearce WH, Pemberton JH, Soper NJ, eds. *ACS Surgery: Principles and Practice.* 4th ed. New York, NY: WebMD; 2004:232–238.

۰۲۱-۶۶۱۹۸۵۱۴ www.myuptodate.com دریافت آخرین نسخه آپتودیت آفلاین

1E30

Key word: Treatment of Insulinoma of the Pancreatic Head

Author: Robert A. Meguid, MD, MPH
Editor: Alan P.B. Dackiw, MD, PhD, BSc, BSc(Med), FACS, FRCSC

A 45-year-old man undergoes endoscopic ultrasonography to further localize a 3-cm insulinoma in the head of the pancreas. This solitary insulinoma is determined to be adjacent to the pancreatic duct. Which of the following procedures should be used to remove the tumor?

(A) Catheter-directed chemoembolization

(B) Laparoscopic total pancreatectomy

(C) Laparotomy with cryoablation

(D) Laparotomy with enucleation

(E) Laparotomy with pancreaticoduodenectomy

Answer: (E) Laparotomy with pancreaticoduodenectomy

Rationale:

Insulinomas greater than 2 cm or adjacent to the main pancreatic duct in the head of the pancreas are not amenable to local enucleation and should be resected as part of a pancreaticoduodenectomy.

Large (>2 cm) insulinomas in the neck and proximal body of the pancreas may be excised via central pancreatectomy, and those in the distal body and tail are excised via distal pancreatectomy. Smaller lesions may be excised via enucleation, regardless of location within the pancreas as long as they are not adjacent to the main pancreatic duct. Similarly, tumors amenable to laparoscopic approach must be either in the tail of the pancreas or not adjacent to the main pancreatic duct. Cryoablation is not a favored method of eradication of insulinomas.

References:

Kennedy EP, Brody JR, Yeo CJ. Neoplasms of the endocrine pancreas. In: Mulholland MW, Lillemoe KD, Doherty GM, Maier RV, Upchurch GR, eds. *Greenfield's Surgery: Scientific Principles & Practice.* 5th ed. Philadelphia, PA: Lippincott Williams and Wilkins; 2011.

Yeo CJ, Cameron JL. The pancreas. In: Sabiston DC, Lyerly HK, eds. *Textbook of Surgery.* 15th ed. Philadelphia, PA: W.B. Saunders; 1997:1177.

1E31

Key word: Characteristics of ITP Treatment

Author: Robert A. Meguid, MD, MPH
Editors: Charles M. Balch, MD, FACS, and Lisa K. Jacobs, MD

A 62-year-old woman undergoes laparoscopic splenectomy for idiopathic thrombocytopenic purpura (ITP). After recovery from the operation she continues to have a platelet count of 20,000. What is the next step in her management?

(A) Administration of intravenous immunoglobulin (IVIG)

(B) Begin a 4-month course of danazol

(C) Bone marrow transplantation

(D) Do nothing

(E) Reoperate for missed accessory spleen

Answer: (A) Administration of intravenous immunoglobulin (IVIG)

Rationale:

One of the most common causes of acquired thrombocytopenia, Idiopathic or Immune Thrombocytopenic Purpura (ITP) is caused by antibodies binding to and inactivating platelets. Patients are usually females in the second to third decade of life and present with petechiae or purpura, but may also present with mucosal bleeding.

Diagnosis of ITP is one of exclusion of other possible etiologies for thrombocytopenia, including drug-induced thrombocytopenia, HIV, hypersplenism, and familial thrombocytopenia. Laboratory diagnosis often includes isolation of antibodies to platelet glycoproteins IIb/IIIa, Ib/IX, and Ia/IIa.

Treatment of ITP is aimed at maintaining platelet counts greater than 20,000/μL, and begins with chronic prednisone (up to 4 months), and addition of IVIG in refractory patients. In the event of spontaneous, unremitting bleeding, platelet transfusions should be administered along with methylprednisolone.

Surgical therapy consists of splenectomy, and is indicated for patients with ITP who either fail to respond or relapse after cessation of prednisone. In addition, patients with bleeding crises necessitating further emergent surgery (i.e., craniotomy for intracranial hemorrhage) should undergo splenectomy. Results from laparoscopic and open splenectomy are comparable. Accessory spleens have been noted in 15% to 30% of patients, and must be removed in patients with ITP to improve the likelihood of remission.

Immediately prior to splenectomy, patients should be given methylprednisolone and IVIG to boost platelet counts and receive immunization with polyvalent pneumococcal vaccine 10 to 14 days prior to surgery, or postoperatively at the latest. In addition, immunosuppressed patients and those less than 10 years of age should receive the polyvalent vaccines for *Streptococcus pneumoniae, Haemophilus influenzae* type B, and *Neisseria meningitidis.* However, in general, patients do not require platelet transfusion prior to splenectomy.

Splenectomy does not successfully treat ITP in 30% to 40% of patients, especially in the elderly. Subsequent treatment is

۰۲۱-۶۶۱۹۸۵۱۴ www.myuptodate.com دریافت آخرین نسخه آپتودیت آفلاین

focused on further medical management. Initially, patients are restarted on oral prednisone. In combination, 85% of patients respond to intermittent IVIG. However, only 20% to 40% of patients respond to 4- to 6-month courses of danazol, an androgen, which has been found to be less effective in refractory patients. Since the presence of accessory spleen tissue may sustain the symptoms of ITP, workup prior to reoperation includes CT or MRI. Bone marrow transplantation is an experimental therapy. Following no medical intervention is less than ideal, as the mortality rate from bleeding is as high as 40% for patients older than 60 years of age.

References:

Bussel J, Cines D. Chapter 138: Immune thrombocytopenic purpura, neonatal alloimmune thrombocytopenia, and post-transfusion purpura. In: Hoffman R, Benz EJ, Shattil SJ, Furie B, Silberstein LE, McGlave P, Heslop HP, eds. *Hoffman: Hematology: Basic Principles and Practice.* 5th ed. New York, NY: Elsevier; 2009.

Gilbert DN, Moellering RC, Eliopoulos GM, Chambers HF, Saag MS, eds. *The Sanford Guide to Antimicrobial Therapy.* 42nd ed. Hyde Park: Antimicrobial Therapy; 2012.

Poulin EC, Schlachta CM, Mamazza J. Section 5, Chapter 25: Splenectomy. In: Souba WW, ed. *ACS Surgery: Principles and Practice.* New York, NY: WebMD; 2007.

1E32

Key word: Contraindications to TRAM Flap Reconstruction

Author: Jordan M. Winter, MD
Editors: Theodore N. Tsangaris, MD, and Mehran Habibi, MD, MBA

A 52-year-old woman with multifocal tumor in her left breast with palpable lymphadenopathy was advised to have a simple mastectomy with axillary lymph node dissection, followed by a postoperative course of chemotherapy and radiation. She has a history of hypertension and quit smoking 15 years ago. Her surgical history includes a tonsillectomy and a laparoscopic cholecystectomy. Which statement is most appropriate regarding the patient's inquiry about transverse rectus abdominus myocutaneous (TRAM) flap reconstruction?

(A) A TRAM flap should yield a more natural cosmetic result compared to breast implantation, but is best performed months after radiotherapy

(B) A TRAM flap should yield a more natural cosmetic result compared to breast implantation, and is best performed immediately following the mastectomy

(C) Breast implantation is preferable to TRAM flap reconstruction due to patient's history of hypertension and smoking

(D) Breast implantation is preferable to TRAM flap reconstruction due to the patient's history of laparoscopic surgery

(E) Breast reconstruction should not be pursued following postmastectomy radiotherapy

Answer: **(A)** A TRAM flap should yield a more natural cosmetic result compared to breast implantation, but is best performed months after radiotherapy

Rationale:

Breast reconstruction may be based on implanted materials or autogenous (natural) tissue transfer. Hybrid procedures exist as well. Implant-based techniques are simple and add little to the operative length but usually require two separate stages: Placement of tissue expanders and then removal of expanders and prosthesis implantation 4 to 4.5 months later. Good candidates for tissue expanders include patients with good skin tone and nonsmokers. Radiation is not a contraindication for tissue expanders. Symmetry may be more difficult to achieve with implants than with flaps.

Autogenous tissue transfer offers a more natural appearance, but involves a complex and relatively lengthy operation. In a TRAM flap, the contralateral rectus abdominus muscle is transferred to the desired position in the chest with its vascular pedicle (based on the superior epigastric vessels) intact. Patients who expect to undergo radiotherapy are probably best served with autogenous tissue transfer only after the completion of radiotherapy. An irradiated chest may in fact benefit from the transfer of healthy abdominal tissue to the area. Reconstruction prior to radiotherapy is considered less

۰۲۱-۶۶۱۹۸۵۱۴ www.myuptodate.com دریافت آخرین نسخه آپتودیت آفلاین

desirable than the delayed approach, as the flap could be compromised by the radiation treatment.

Contraindications to autogenous tissue transfer fall into two categories: Factors that could compromise flap viability and factors that could compromise patient viability. Variables that fit into the former category include obesity, smoking, autoimmune disease, previous abdominal surgery that interrupts blood flow to the flap, and diabetes. However, a distant smoking history and small laparoscopic incisions associated with cholecystectomy as reported for this patient, should not threaten the flap. Medical comorbidities associated with an increased patient risk include chronic obstructive pulmonary disease (COPD), heart failure, ischemic heart disease, chronic renal insufficiency, diabetes, and cerebrovascular disease. Although the patient described here is hypertensive and has a distant smoking history, she is not predicted to be at an increased risk for a cardiopulmonary event after a TRAM flap, as compared to after a breast implant.

References:

Grayburn PA, Hillis LD. Cardiac events in patients undergoing noncardiac surgery: shifting the paradigm from noninvasive risk stratification to therapy. *Ann Intern Med.* 2003;138(6):506–511.

Mehrara BJ, Disa JJ. The TRAM flap. In: King BA, Borgen PI, eds. *Atlas of Procedures in Breast Cancer Surgery.* London: Taylor and Francis; 2005:183.

Qaseem A, Snow V, Fitterman N, et al. Risk assessment for and strategies to reduce perioperative pulmonary complications for patients undergoing noncardiothoracic surgery: A guideline from the American College of Physicians. *Ann Intern Med.* 2006;144(8):575–580.

Vasconez LO, Ashruf S. Soft tissue reconstruction with flap techniques. In: Fischer JE, Bland KI, eds. *Mastery of Surgery.* 5th ed. Philadelphia, PA: Lippincott Williams and Wilkins; 2007:213–221.

1E33

Key word: Characteristics of Hypoaldosteronism

Author: Jordan M. Winter, MD
Editor: Pamela A. Lipsett, MD, MHPE, FACS, FCCM

A 51-year-old man with diabetes and a 5.8-cm abdominal aortic aneurysm undergoes a preoperative evaluation. He has the following laboratory results: Sodium 144 mEq/L, potassium 5.7 mEq/L, chloride 117 mEq/L, bicarbonate 18 mEq/L, and creatinine 1.6 mg/dL. The plasma renin activity is 1.3 ng/mL/hr (normal 1.9 to 3.7 ng/mL/hr) and the urine pH is 5. These laboratory tests are consistent with:

(A) Conn syndrome

(B) Inappropriate antidiuretic hormone secretion

(C) Type 1 renal tubular acidosis

(D) Type 2 renal tubular acidosis

(E) Type 4 renal tubular acidosis

Answer: (E) Type 4 renal tubular acidosis

Rationale:

Aldosterone opens sodium channels on the apical aspect of renal collecting tubule cells and increases Na–K–ATPase pump activity on the basolateral side of the cell. The electronegative charge that results within the lumen of the collecting tubule leads to potassium secretion into the lumen of the collecting tubule. Hypoaldosteronism or Type 4 renal tubular acidosis (RTA), may be caused by either aldosterone deficiency or aldosterone resistance and is associated with impaired potassium efflux in the collecting tubule, resulting in persistent hyperkalemia. The most common cause of Type 4 RTA in adults is hyporeninemic hypoaldosteronism secondary to low renin production from diabetic nephropathy. Other causes include primary adrenal insufficiency, the use of ACE inhibitors, the use of NSAIDs, potassium-sparing diuretics, and congenital adrenal hyperplasia. Type 4 RTA is characterized clinically by hyperkalemia and a mild nonanion gap acidosis. Treatment includes mineralocorticoid replacement in the form of oral fludrocortisone, a low potassium diet, and/or diuretics.

Type 1 RTA is characterized by distal tubular dysfunction and impaired acid excretion. Type 2 RTA is characterized by proximal tubular dysfunction and bicarbonaturia. Type 1 and Type 2 RTAs are typically associated with alkalotic urine and normal plasma renin activity. Inappropriate antidiuretic secretion causes hypotonic isovolemic hyponatremia. Conn syndrome is associated with aldosterone excess from an aldosterone producing adenoma and is associated with hypertension and hypokalemia.

Reference:

Unwin RJ, Capasso G. The renal tubular acidosis. *J R Soc Med.* 2001;94(5):221–225.

۰۲۱-۶۶۱۹۸۵۱۴ www.myuptodate.com دریافت آخرین نسخه آپتودیت آفلاین

1E34

Key word: Distribution of Insulinomas

Author: Robert A. Meguid, MD, MPH
Editors: Theodore N. Tsangaris, MD, and Mehran Habibi, MD, MBA

After radiographic localization of a solitary 3-cm insulinoma in the tail of the pancreas of a 56-year-old woman, you perform a distal pancreatectomy and splenectomy. Which of the following statements regarding the distribution of insulinomas is true?

(A) Fifteen percent of insulinomas are found in the tail of the pancreas

(B) Insulinomas are evenly distributed throughout the pancreas

(C) Malignant insulinomas are more frequently found in the head and uncinate process of the pancreas

(D) Most insulinomas are found in the tail of the pancreas

(E) Ninety percent of insulinomas are found in the head, uncinate process or body of the pancreas

Answer: (B) Insulinomas are evenly distributed throughout the pancreas

Rationale:

Insulinomas, the most common endocrine neoplasm of the pancreas, are evenly distributed throughout the pancreas. Approximately one-third of insulinomas occur in the head and uncinate process, one-third in the body and one-third in the tail of the pancreas.

Ninety percent of insulinomas are solitary, benign lesions, and 10% are malignant insulinoma, often with metastases to regional peripancreatic lymph nodes and liver. Ninety percent of insulinomas are sporadic in origin, while 10% are associated with MEN 1 syndrome. Patients with MEN 1 may have multiple insulinomas within the pancreas, as well as higher recurrence rates after treatment.

Reference:

Kennedy EP, Brody JR, Yeo CJ. Neoplasms of the endocrine pancreas. In: Mulholland MW, Lillemoe KD, Doherty GM, Maier RV, Upchurch GR, eds. *Greenfield's Surgery: Scientific Principles & Practice.* 5th ed. Philadelphia, PA: Lippincott Williams and Wilkins; 2011.

1E35

Key word: Patient at Highest Risk of Postsplenectomy Sepsis

Author: Robert A. Meguid, MD, MPH
Editor: Andrew M. Cameron, MD, PhD

The following patients have all undergone splenectomy, and none have received vaccinations for *Streptococcus pneumoniae, Haemophilus influenzae,* or *Neisseria meningitidis.* Who is at greatest risk of postsplenectomy sepsis?

(A) A 14-year-old girl who underwent splenectomy for trauma 2 years ago

(B) A 20-year-old man with HIV who underwent splenectomy for trauma

(C) A 3-year-old boy who underwent splenectomy for thalassemia major

(D) A 45-year-old man who underwent splenectomy for Hodgkin disease

(E) A 73-year-old woman who underwent splenectomy for ITP

Answer: (C) A 3-year-old boy who underwent splenectomy for thalassemia major

Rationale:

Asplenic patients are at risk of overwhelming postsplenectomy sepsis (OPSI) caused largely by encapsulated pathogens as they are normally opsonized and cleared from circulation by the spleen.

Asplenic adults are at approximately 50% greater risk of sepsis as compared to normosplenic adults. In addition, the risk and impact of OPSI is inversely related to age. The risk of OPSI in children is approximately 2% over 10 years, and higher in children less than 2 years of age. In 80% of cases, OPSI occurs within the first 2 years after splenectomy. The risk of OPSI is further increased in asplenic patients with malignancy or in those who are additionally immunosuppressed (e.g., undergoing chemotherapy). Overall, OPSI has a 50% to 60% mortality rate.

Those at greatest risk of OPSI are patients less than 3 years old and those with compromised immune systems. Patients with thalassemia major are at particular risk of developing OPSI. *S. pneumoniae* is the causative pathogen in two-thirds of infections, and *H. influenzae* and *N. meningitidis* account for the majority of the rest of infections. Patients present with a mild fever and headache, and rapidly progress to shock and death within 6 to 12 hours.

Guidelines for reduction of the risk of OPSI focuses on immunization of patients undergoing elective splenectomy with polyvalent pneumococcal vaccine 10 to 14 days prior to surgery, or postoperatively at the latest. In addition, immunosuppressed patients and those less than 10 years of age should receive the polyvalent vaccines for *H. influenzae* type B and *N. meningitidis.* Children less than 5 years of age should be put on antibiotic prophylaxis (penicillin V or amoxicillin or TMP/SMX). All asplenic patients should wear medical alert

۰۲۱-۶۶۱۹۸۵۱۴ www.myuptodate.com دریافت آخرین نسخه آپتودیت آفلاین

bracelets. Ideally, splenectomy in children should be delayed until they are older than 5 years of age.

References:

Bussel J, Cines D. Chapter 131: Immune thrombocytopenic purpura, neonatal alloimmune thrombocytopenia, and post-transfusion purpura. In: Hoffman R, Benz EJ, Shattil SJ, Furie B, Cohen HJ, Silberstein LE, McGlave P, eds. *Hematology: Basic Principles and Practice.* 4th online ed. New York, NY: Elsevier; 2005. Accessed March 21, 2006.

Fraker DL. The spleen. In: Mulholland MW, Lillemoe KD, Doherty GM, Maier RV, Upchurch GR, eds. *Greenfield's Surgery: Scientific Principles & Practice.* 5th ed. Philadelphia, PA: Lippincott Williams and Wilkins; 2011.

Gilbert DN, Moellering RC, Eliopoulos GM, et al. *The Stanford Guide to Antimicrobial Therapy 2005.* 35th ed. Hyde Park: Antimicrobial Therapy; 2005:140.

1E36

Key word: Diagnosis and Treatment of Insulinomas

Author: Jordan M. Winter, MD
Editors: Theodore N. Tsangaris, MD, and Mehran Habibi, MD, MBA

A 52-year-old man with no prior medical problems reports intermittent episodes of tachycardia, nausea, and diaphoresis that improve with snacks. He has gained 4.54 kg (10 lb) in the past 3 months, and has become increasingly irritable. The patient's internist orders a monitored fast and makes the diagnosis of an insulinoma. A computed tomography (CT) scan with IV contrast fails to localize the tumor. The next step in the patient's management is to:

(A) Perform endoscopic ultrasonography

(B) Perform exploratory laparotomy and employ intraoperative ultrasound

(C) Perform selective arterial calcium stimulation with hepatic venous insulin sampling

(D) Perform somatostatin receptor scintigraphy

(E) Recommend judicious carbohydrate intake and a trial of octreotide

Answer: (A) Perform endoscopic ultrasonography

Rationale:

After establishing the diagnosis of insulinoma from the patient's history, physical examination, and biochemical tests, imaging should be performed to try and localize the tumor. A multi-detector CT scan with IV contrast is the imaging test of choice, with a sensitivity of around 80%. Alternative imaging tests should be performed before surgery if the CT is negative for several reasons. First, failure to localize the lesion preoperatively increases the chances of a nontherapeutic exploratory laparotomy, given that a blind partial pancreatectomy is no longer recommended when the lesion cannot be identified intraoperatively. Second, a laparoscopic approach is preferable in certain instances, such as with small exophytic tumors amenable to enucleation or with tumors located in the body or tail of the pancreas. Endoscopic ultrasound can identify about 80% of islet cell tumors when the CT is negative. Gastrinomas may be imaged with somatostatin receptor scintigraphy, but this test is not useful for insulinomas. Invasive imaging techniques that may be reserved for patients after a negative exploratory laparotomy include selective transhepatic portal venous sampling or selective arterial calcium stimulation with hepatic venous insulin sampling. Dietary adjustments and octreotide are therapeutic options for patients with unresectable disease.

۰۲۱-۶۶۱۹۸۵۱۴ www.myuptodate.com دریافت آخرین نسخه آپتودیت آفلاین

Insulinoma

Parameter	Description
Symptoms	Neuroglycopenia causes confusion, personality change, coma
	Catecholamine surge causes trembling, diaphoresis, tachycardia
	Anabolic state: weight gain
Diagnostic tests	Monitored fast
	Insulin-to-glucose ratio
Anatomic localization	Evenly distributed throughout pancreas

Reprinted with permission from: Kennedy EP, Brody JR, Yeo CJ. Neoplasms of the endocrine pancreas. In: Mulholland MW, Lillemoe KD, Doherty GM, Maier RV, Upchurch GR, eds. *Greenfield's Surgery: Scientific Principles & Practice*. 5th ed. Philadelphia, PA: Lippincott Williams & Wilkins; 2011:863.

References:

Horton KM, Hruban RH, Yeo CJ, et al. Multi-detector row CT of pancreatic islet cell tumors. *Radiographics.* 2006; 26:453–464.

Kennedy EP, Brody JR, Yeo CJ. Neoplasms of the endocrine pancreas. In: Mulholland MW, Lillemoe KD, Doherty GM, Maier RV, Upchurch GR, eds. *Greenfield's Surgery: Scientific Principles & Practice.* 5th ed. Philadelphia, PA: Lippincott Williams and Wilkins; 2011.

۰۲۱-۶۶۱۹۸۵۱۴ www.myuptodate.com دریافت آخرین نسخه آپتودیت آفلاین

III
FULL-LENGTH PRACTICE EXAMINATION 2

This is the beginning of the second full-length practice examination.

To most closely simulate the actual examination, take this during an uninterrupted 5-hour block of time.

The answer key is located at the end of the examination.

۰۲۱-۶۶۱۹۸۵۱۴ www.myuptodate.com دریافت آخرین نسخه آپتودیت آفلاین

QUESTION 2-1

A 60-year-old man undergoes a right hemicolectomy for colon adenocarcinoma. The pathology revealed a tumor with negative microscopic margins, well-differentiated histology, and 10 lymph nodes in the specimen. He was found to have a stage II (T2N0M0) tumor. Which of the following characteristics place him at a higher risk, thus making him a potential candidate for adjuvant therapy?

(A) Age
(B) Highly differentiated histology
(C) Location of the tumor
(D) Number of sampled lymph nodes
(E) T2 lesion

QUESTION 2-2

A 22-year-old male presents to the emergency department with a stab wound in the right sixth intercostal space just lateral to the sternal border. His blood pressure is 90/70 mm Hg, his pulse is 130 beats per minute, and he complains of shortness of breath. His trachea is midline and his neck veins are bulging. The most likely diagnosis is:

(A) Esophageal injury
(B) Pericardial tamponade
(C) Pneumothorax
(D) Pulmonary contusion
(E) Tracheobronchial injury

QUESTION 2-3

A 62-year-old woman presents to your clinic after undergoing a left modified radical mastectomy for stage III breast carcinoma. She has done well postoperatively and is concerned only about new onset numbness and tingling over the posteromedial aspect of her left upper arm. She has normal strength, no motor deficits, and normal range of motion in her left upper extremity. What structure was likely injured during her operation?

(A) Intercostobrachial nerve
(B) Long thoracic nerve of Bell
(C) Medial cutaneous nerve of arm
(D) Medial pectoral nerve
(E) Thoracodorsal nerve

QUESTION 2-4

The anatomic separation between the common hepatic duct and the common bile duct occurs at which level?

(A) Entry of cystic duct into the common hepatic duct
(B) Entry of the duct into the pancreas
(C) The change in mucosa from columnar to squamous
(D) The intersection of the bile duct and right hepatic artery
(E) The superior edge of the duodenum where the duct starts to travel in the retroduodenal space

QUESTION 2-5

A 39-year-old female has been followed regularly by her dermatologist for a mole located on her left shoulder. Due to a family history of melanoma and her fair complexion, she is concerned that this nevus might eventually progress to malignant disease. Which of the following is true concerning the malignant transformation from melanocytic nevus to frank melanoma?

(A) Abnormal adhesion receptors make cells resistant to the typical progression from nevus to melanoma
(B) All melanocytic nevi that change shape, color, or size are considered malignant
(C) All melanomas arise from preexisting nevi
(D) Melanocytic nevi are not considered direct precursor lesions to melanoma
(E) The BRAF mutation is found in a majority of patients with melanoma and nevi

QUESTION 2-6

A 65-year-old male is undergoing an elective left inguinal hernia repair. With regard to his risk of surgical site infection, which of the following is true?

(A) A surgical site infection is defined as one occurring within 60 days of the procedure or within 6 months if an implant is left in place
(B) Administration of most preoperative antibiotics should be within 1 hour of incision
(C) Antibiotics are given postoperatively because there is documented proof that they decrease the risk of surgical site infection after wound closure
(D) If the procedure necessitates drain placement, studies have shown a decrease in infection rates if antibiotics are continued until they are removed
(E) Routine use of vancomycin for antibiotic prophylaxis is recommended

۰۲۱-۶۶۱۹۸۵۱۴ www.myuptodate.com دریافت آخرین نسخه آپتودیت آفلاین

QUESTION 2-7

On postoperative day 3 after a classic Whipple procedure, a 54-year-old man is found to be lethargic and tachycardic with a pulse of 180 beats per minute and blood pressure of 50 mm Hg/palpable. An EKG reveals an irregularly irregular rhythm. What is the most appropriate treatment of his arrhythmia?

(A) 1-mg IV atropine

(B) A bolus of 1 L of normal saline

(C) A bolus of amiodarone 150-mg IV followed by an amiodarone infusion

(D) Repeated boluses of metoprolol IV until heart rate normalizes

(E) Synchronized cardioversion

QUESTION 2-8

A 58-year-old woman with biopsy-proven papillary thyroid carcinoma and clinically involved right cervical lymph nodes undergoes total thyroidectomy and right modified radical neck dissection. On the first morning postoperatively, a focused clinical examination should include an assessment of which of the following?

(A) Grip strength

(B) Hand sensation

(C) Plantar flexion

(D) Shoulder shrug

(E) Tongue protrusion

QUESTION 2-9

A 55-year-old female presents with complaints of worsening chest pain associated with swallowing and dysphagia for solid food. Upper gastrointestinal series demonstrates narrowing of the distal esophagus with proximal dilation. Manometric studies demonstrate failure of normal relaxation of the lower esophageal sphincter. The patient undergoes an uneventful laparoscopic Heller myotomy. Postoperatively, she reports continued chest pain that occurs 30 to 60 minutes after meals and worsens upon lying down. How could this complication have been prevented?

(A) Combining myotomy with a partial fundoplication procedure

(B) Esophagectomy

(C) Injection of the lower esophageal sphincter with botulinum toxin

(D) Longer myotomy incision

(E) Postoperative initiation of calcium channel blockers

QUESTION 2-10

A 20-year-old man was an unrestrained passenger in a motor vehicle collision. Upon impact, his left leg hit the dashboard and caused a posterior hip dislocation. This was reduced in the emergency department approximately 20 hours after the accident. What is the most likely complication?

(A) Avascular necrosis of femoral head

(B) Femoral head fracture

(C) Heterotopic ossification

(D) Sciatic nerve injury

(E) Shortening of leg

QUESTION 2-11

A 27-year-old man was injured in a chemical plant explosion and presented to the hospital with burns covering over 50% of his total body surface area (TBSA). Early excision is planned. Which of the following statements is true concerning his condition?

(A) Early excision of burns prolongs the inflammatory phase of healing

(B) Early excision of burns results in a decreased risk of infection

(C) Hypertrophic scarring is a complication of early excision

(D) Early excision should occur in one procedure in extensive burns (>40% TBSA)

(E) With improved burn care, infection no longer carries significant morbidity

QUESTION 2-12

A 48-year-old male painter falls from a ladder and presents to the emergency room. Primary and secondary surveys are notable for left-sided chest pain on palpation. He is splinting with deep inspiration. Radiography demonstrates nondisplaced fifth to ninth rib fractures. Which of the following options for pain control has been shown to provide superior outcomes in patients with rib fractures?

(A) Epidural anesthesia

(B) Intercostal nerve blockade

(C) Intravenous opioid medication

(D) Oral nonsteroidal anti-inflammatory medication

(E) Oral opioid medication

۰۲۱-۶۶۱۹۸۵۱۴ www.myuptodate.com دریافت آخرین نسخه آپتودیت آفلاین

QUESTION 2-13

A 15-year-old boy presents 1 year following laparoscopic splenectomy for idiopathic thrombocytopenia purpura. He reports spontaneous massive epistaxis and is found to have a platelet count of 10,000/μL. In addition to a complete blood count, which of the following is the most helpful initial study to send based on his past history?

(A) Bone marrow aspirate

(B) Partial thromboplastin time

(C) Peripheral blood smear for eosinophils

(D) Peripheral blood smear for Howell–Jolly bodies

(E) Prothrombin time

QUESTION 2-14

A 43-year-old female patient is now postoperative day 8 after a distal gastrectomy and Roux-en-Y reconstruction for an antral gastrointestinal stromal tumor (GIST). On morning rounds, her abdomen is tender with guarding in her epigastrium, and there is bilious fluid in her intra-abdominal Jackson-Pratt drain. Her vital signs are 38.1°C, pulse 98 beats per minute, blood pressure 123/69 mm Hg, and oxygen saturation 94%. A computed tomography (CT) scan with oral contrast is performed, and a fluid collection measuring 10 × 8 × 5 cm is seen in the area of the resection bed. Which of the following is the next step in diagnosing a duodenal stump leak?

(A) Diagnostic laparoscopy

(B) Fluoroscopy (upper gastrointestinal series with Jackson-Pratt injection)

(C) Gastroscopy and inspection of anastomosis

(D) No further studies are needed as bilious fluid in the Jackson-Pratt drain is diagnostic

(E) Repeat CT scan with oral and intravenous contrast

QUESTION 2-15

A 30-year-old male is brought to the emergency room after falling off a second story balcony and landing on both feet before striking his head. He arrives intubated with normal hemodynamic parameters and a Glasgow Coma Scale score of 6T (withdraws to pain). His physical examination reveals bilateral swollen, erythematous heels but is otherwise free of other obvious deformities. In addition to computed tomography (CT) imaging of his head, cervical spine, abdomen, and pelvis, and x-rays of his chest and bilateral feet, what other plain film imaging should be obtained?

(A) Bilateral ankles, thoracic spine, lumbar spine

(B) Bilateral ankles, tibia/fibula, femurs, lumbar spine, thoracic spine

(C) Bilateral ankles, tibia/fibula, femurs, pelvis, lumbar spine

(D) Bilateral ankles, tibia/fibula, femurs, pelvis, lumbar spine, thoracic spine

(E) Bilateral ankles, tibia/fibula, lumbar spine

QUESTION 2-16

Which of the following is most likely to occur with use of local anesthetics administered via an epidural catheter for pain control following thoracic surgery?

(A) Regional vasodilation

(B) Renal toxicity

(C) Respiratory depression

(D) Temporary leg weakness

(E) Urinary retention

QUESTION 2-17

An otherwise healthy 54-year-old male presents with stable angina. Echocardiography reveals an ejection fraction of 50% with an aortic valve area of 0.9 cm^2, a mean pressure gradient of 45 mm Hg, and a jet velocity of 4.5 m/sec. Which of the following is the best definitive therapy?

(A) Aortic valve replacement (AVR)

(B) Medical management with antihypertensive therapy

(C) Orthotopic heart transplantation

(D) Percutaneous balloon valvotomy

(E) Transcatheter AVR

۰۲۱-۶۶۱۹۸۵۱۴ www.myuptodate.com دریافت آخرین نسخه آپتودیت آفلاین

QUESTION 2-18

A 25-year-old woman presents with a breast mass found on self-examination. A 3-cm tender mass is palpable in the upper outer quadrant of the right breast with no overlying skin changes. The patient has no medical history and takes only an oral contraceptive pill. What is the most appropriate initial imaging modality?

(A) Computed tomography (CT)
(B) Magnetic resonance imaging (MRI)
(C) Mammogram
(D) Positron emission tomography (PET)
(E) Ultrasound

QUESTION 2-19

A 54-year-old male undergoes laparoscopic Nissen fundoplication for persistent gastroesophageal reflux. On postoperative day 2, the patient develops pleuritic chest pain and shortness of breath. EKG and cardiac enzymes are normal. Chest x-ray demonstrates a large left-sided pleural effusion. Which of the following is the best diagnostic study to obtain next?

(A) Computed tomography (CT) scan
(B) Echocardiogram
(C) Esophagogram
(D) Lymphoscintigraphy
(E) Thoracentesis and pleural fluid sampling

QUESTION 2-20

A 34-year-old woman presents with pain in her right hand and neck that has been going on for 1 year. She experiences occasional numbness in her arm and hand. She works as a seamstress and reports that her symptoms are worsened when shooting a basketball. What is the most likely diagnosis?

(A) Brachial plexopathy
(B) Carpal tunnel syndrome
(C) Complex regional pain syndrome
(D) Medial epicondylitis
(E) Thoracic outlet syndrome

QUESTION 2-21

A 59-year-old male presents to clinic 2 years after a deceased donor kidney transplant for diabetic nephropathy. His creatinine is now 1.7 mg/dL, up from a stable baseline of 1.1 mg/dL following his transplant. His blood glucose levels have been well controlled, with HbA_{1c} of 6.2%. You perform a percutaneous core-needle biopsy, which shows no evidence of rejection. Which of the following immunosuppression medications is most likely contributing to this patient's increasing renal insufficiency?

(A) Azathioprine
(B) Mycophenolate mofetil (MMF)
(C) Prednisone
(D) Sirolimus
(E) Tacrolimus

QUESTION 2-22

During pregnancy, a woman's blood volume:

(A) Decreases by 10% to 20%
(B) Decreases by 30% to 50%
(C) Does not change
(D) Increases by 10% to 20%
(E) Increases by 30% to 50%

QUESTION 2-23

An otherwise healthy 52-year-old male is in the postoperative care unit hours after undergoing an uncomplicated left-sided laparoscopic adrenalectomy for a 0.5-cm cortisol-producing tumor when he is noted to have a heart rate of 82 beats per minute and blood pressure of 90/40 mm Hg. After administering 2 L of normal saline, the blood pressure is unchanged. The most critical next step in management will be to:

(A) Administer 100-mg IV hydrocortisone
(B) Begin a norepinephrine drip
(C) Check troponin levels
(D) Obtain a 12-lead EKG
(E) Obtain a portable chest x-ray

۰۲۱-۶۶۱۹۸۵۱۴ www.myuptodate.com دریافت آخرین نسخه آپتودیت آفلاین

QUESTION 2-24

A 52-year-old man presents to the emergency room with abdominal pain, weight loss, and dehydration. He has had large-volume diarrhea (>3 L/day) over the past few weeks. Abdominal computed tomography (CT) reveals a small mass in the tail of the pancreas, and a plasma vasoactive intestinal polypeptide (VIP) is sent. Which of the following would be most consistent with a diagnosis of Verner–Morrison syndrome?

(A) Abdominal pain

(B) Osmotic diarrhea

(C) Stool osmotic gap of 300 mOsm/kg

(D) VIP plasma level of 600 pg/mL

(E) Weight loss

QUESTION 2-25

A 25-year-old man was involved in a motor vehicle accident and suffered a tibial plateau fracture that was splinted in the emergency department. Several days after admission he develops difficulty with dorsiflexion of his foot and also reports numbness and tingling sensations in the injured leg. In which region of the leg would he most likely feel numbness and tingling?

(A) Dorsum of foot

(B) Lateral plantar surface of foot

(C) Medial plantar surface of foot

(D) Over lateral malleolus

(E) Over medial malleolus

QUESTION 2-26

A 34-year-old HIV-positive man presents with a swollen, erythematous, and painful left forearm. He reports that the redness began after injecting heroin into his left hand web spaces 2 days prior. On examination, the skin overlying his arm is blistered, he is unable to flex his hand or wrist, and you palpate crepitus along his forearm. Which of the following is true regarding these types of infections?

(A) Antibiotic therapy is the primary management modality

(B) *Clostridium perfringens* is the most frequently cultured organism in necrotizing soft tissue infections

(C) Group A beta-hemolytic Streptococcus is more common than *Clostridium perfringens* in monomicrobial infections

(D) Most necrotizing soft tissue infections are polymicrobial

(E) Surgical debridement should be performed 48 hours after presentation to provide adequate interval for response to antibiotics

QUESTION 2-27

A 70-year-old man with a 1-cm non–small-cell adenocarcinoma of his right upper lobe presents to your office for evaluation for resection of his tumor. He is thin, and although comfortable, he is breathing in a shallow and somewhat rapid fashion. Spirometry demonstrates an obstructive defect with a forced expiratory volume in 1 second (FEV_1)/forced vital capacity (FVC) of less than 70% of predicted and an FEV_1 of less than 50% of predicted. Which of the following regarding alveolar ventilation is true?

(A) Alveolar hypoventilation results in an increase in the partial pressure of carbon dioxide and hypercapnia

(B) Alveolar ventilation and minute ventilation are synonymous

(C) Alveolar ventilation can be directly measured using spirometry

(D) There is a direct relationship between alveolar ventilation and the partial pressure of carbon dioxide in the blood

(E) There is an indirect relationship between alveolar ventilation and the partial pressure of oxygen in the blood

۰۲۱-۶۶۱۹۸۵۱۴ www.myuptodate.com دریافت آخرین نسخه آپتودیت آفلاین

QUESTION 2-28

A 55-year-old postmenopausal woman is found to have osteoporosis and joint and muscle aches 1 year following Roux-en-Y gastric bypass surgery and a 68.04-kg (150-lb) weight loss from her preoperative weight of 163.29 kg (360 lb). During workup for her condition she is noted to have a calcium level of 7.8 mg/dL. Further laboratory analysis will likely show the following:

(A) PTH = 20 pg/mL, Vitamin D = 15 ng/mL, Phosphate 3.5 mg/dL

(B) PTH = 25 pg/mL, Vitamin D = 20 ng/mL, Phosphate 3.5 mg/dL

(C) PTH = 100 pg/mL, Vitamin D = 15 ng/mL, Phosphate 3.5 mg/dL

(D) PTH = 100 pg/mL, Vitamin D = 15 ng/mL, Phosphate 6 mg/dL

(E) PTH = 100 pg/mL, Vitamin D = 30 ng/mL, Phosphate 3.5 mg/dL

QUESTION 2-29

A 45-year-old woman undergoes a laparoscopic cholecystectomy for symptomatic cholelithiasis. On postoperative day 10, she presents to the emergency room with 4 days of low-grade fevers, nausea, and right upper quadrant abdominal pain. Laboratory studies reveal mildly elevated bilirubin, liver enzymes, and white blood cell count. Computed tomography demonstrates a subhepatic fluid collection. Hepatobiliary iminodiacetic acid (HIDA) scan shows some drainage enterically but also peritoneal leakage, and a percutaneous drain is placed into the collection. What is the next step in management?

(A) Endoscopic retrograde cholangiopancreatography (ERCP) with stenting

(B) Immediate open common bile duct exploration

(C) Immediate open hepaticojejeunostomy

(D) Observation

(E) Percutaneous transhepatic cholangiogram

QUESTION 2-30

A 25-year-old male notices a painless mass in his scrotum for the first time while showering. Which of the following is an accurate statement regarding the diagnosis of testicular masses?

(A) Biopsy of the testicle is generally required prior to radical inguinal orchiectomy in order to provide a histologic diagnosis

(B) Cystic or fluid-filled masses detected on scrotal ultrasound are typically seminomas

(C) Physical examinations can be performed less frequently with the availability of scrotal ultrasounds

(D) Scrotal ultrasound can distinguish extrinsic from intrinsic testicular lesions and can detect intratesticular lesions as small as 1 to 2 mm

(E) Transillumination studies are sufficient in discerning between malignant and benign testicular masses

QUESTION 2-31

Which of the following is the definition of a process measure as utilized in health care?

(A) A health state of a patient resulting from health care used to assess the extent that health care services influence the likelihood of desired outcomes.

(B) A measurement of patients' perspective of their experience in the hospital

(C) A summary of performance obtained by combining information from more than one individual measure

(D) An indicator that assesses a health care service provided to, or on behalf of, a patient often used to assess adherence to recommendations for clinical practice based on evidence or consensus

(E) The percentage of patients who had a good medical outcome

۰۲۱-۶۶۱۹۸۵۱۴ www.myuptodate.com دریافت آخرین نسخه آپتودیت آفلاین

QUESTION 2-32

A 57-year-old male presents to clinic with chronic stable angina that limits his ability to climb stairs and perform activities of daily living. Cardiac catheterization reveals a 70% occlusion in the left anterior descending artery, an 80% occlusion in the left circumflex artery, and an 85% occlusion in the right coronary artery with an ejection fraction of 50%. What is the recommended management of this patient?

(A) Coronary artery bypass grafting

(B) Optimal medical management including aspirin, clopidogrel, beta-blocker, and a statin

(C) Percutaneous balloon angioplasty

(D) Percutaneous balloon angioplasty with stenting of all three lesions

(E) Transmyocardial laser revascularization

QUESTION 2-33

A 47-year-old woman presents with a palpable breast mass discovered on self-examination. Mammography demonstrates a Breast Imaging-Reporting and Data System (BI-RADS) 4 lesion found to be a 2-cm spiculated mass with heterogeneous calcifications. Core-needle biopsy is read as atypia without malignant features. The best next step would be the following:

(A) Excisional biopsy

(B) Incisional biopsy

(C) Mastectomy

(D) Repeat needle biopsy

(E) Surveillance with yearly mammography

QUESTION 2-34

A 56-year-old male with a significant history of tobacco use complains of progressively worsening odynophagia and dysphagia and a 4.54-kg (10-lb) weight loss over the past several months. He initially had trouble swallowing solid food and has more recently developed difficulty swallowing liquids and a sensation that food gets caught in his chest. What is the most valuable diagnostic study to obtain?

(A) Barium swallow

(B) Computed tomography (CT) of the chest and abdomen

(C) Endoscopic ultrasound

(D) Esophageal manometry

(E) Esophagogastroduodenoscopy

QUESTION 2-35

A 17-year-old woman brings her 11-month-old infant boy to the emergency department for seizure activity. Despite no report of trauma, the child has a bruise on his scalp and is found to have a subarachnoid hemorrhage on computed tomography. Which of the following is true with regard to the potential for nonaccidental injury?

(A) Head injury is the most common manifestation of nonaccidental injury

(B) Nonaccidental injury is seen similarly across parent age and socioeconomic status

(C) Nonaccidental injury is the most common cause of hemorrhagic stroke in children

(D) Skeletal survey is unnecessary in this patient

(E) This patient should undergo ophthalmologic examination

QUESTION 2-36

When a physician places an order for a medication in an electronic ordering system, the system checks to see if the patient has an allergy to that medication. In addition, a pharmacist checks the dose and type of medication to ensure that it is appropriate for the patient. Afterward, a nurse administers the medication and has to scan the patient's ID badge before doing so. In one isolated case, a nurse administered the medication without checking the patient's name, and the patient experienced an adverse reaction to the medication. This scenario is an example of which of the following?

(A) Active error

(B) Close call

(C) Latent error

(D) Near-miss

(E) Systems error

۰۲۱-۶۶۱۹۸۵۱۴ www.myuptodate.com دریافت آخرین نسخه آپتودیت آفلاین

QUESTION 2-37

A 51-year-old male reports episodic light-headedness and vision changes that usually occur when he is working as a custodian. His pulse is 72 beats per minute; blood pressure is 126/87 mm Hg in the left arm and 147/103 mm Hg in the right arm. On physical examination, he is an obese man with a regular heart rate, no murmurs, clear lung sounds, a 2+ radial pulse on the right and a 1+ radial pulse on the left, and a carotid bruit present on the left but not on the right. The most appropriate next step in the diagnosis and management of his condition is:

(A) Carotid-subclavian bypass

(B) Computed tomography (CT) angiography

(C) Diagnostic angiography

(D) Duplex ultrasonography

(E) Endovascular stent placement

QUESTION 2-38

A 56-year-old woman is found to have a 2-cm mass in her left adrenal gland following an abdominal computed tomography (CT) scan performed following a motor vehicle collision. Which of the following is the best next step in management of this adrenal mass?

(A) Laparoscopic adrenalectomy

(B) Mammography

(C) Measurement of adrenocorticotropic hormone (ACTH) level, 24-hour urine-free cortisol level, urine metanephrine level, and calculate an aldosterone/renin ratio

(D) Metaiodobenzylguanidine (MIBG) scan

(E) Observation with repeat abdominal CT scan in 1 year

QUESTION 2-39

A 50-year-old man presents to the emergency room with left lower quadrant abdominal pain. He is febrile to 38.7°C with a pulse of 100 beats per minute and blood pressure of 120/70 mm Hg. On examination of his abdomen, he is found to have focal left lower quadrant tenderness without peritonitis. His white blood cell count is 15,000/μL, and a computed tomography (CT) scan demonstrates diverticular disease in the sigmoid colon with a 6-cm rim-enhancing pericolic collection. Antibiotics are started. What is the next step in management of this patient?

(A) Careful observation on antibiotic therapy

(B) Exploratory laparotomy and washout without operative resection of the colon

(C) Percutaneous drainage of the collection

(D) Sigmoid colectomy with end colostomy and Hartmann pouch

(E) Sigmoid colectomy with primary anastomosis

QUESTION 2-40

An 11-year-old boy presents to the emergency department after falling out of a tree at a height of approximately 6.1 m (20 ft). His primary survey is negative. On secondary survey, you note a Glasgow Coma Scale (GCS) score of 12, tenderness and rigidity of his abdomen, and extremity injuries. Computed tomography scans of his head, abdomen, and pelvis reveal an occipital subarachnoid hemorrhage and a grade 2 splenic laceration. Which of the following is true with regard to secondary brain injury?

(A) According to the Monro–Kellie doctrine, the cranial vault is a closed space, and thus an increase in one constituent volume must be compensated by reduction in another constituent volume

(B) All patients with moderate or severe brain injuries should have an intracranial pressure monitor placed

(C) Hyperventilation decreases PCO_2, causing intracranial vasodilation and thus increased cerebral blood flow

(D) Steroids have been proven to reduce the risks of herniation and death in patients with severe brain injuries

(E) The brain matter 180 degrees away from the site of primary brain injury is at risk for a secondary *contrecoup* injury

۰۲۱-۶۶۱۹۸۵۱۴ www.myuptodate.com دریافت آخرین نسخه آپتودیت آفلاین

QUESTION 2-41

A 57-year-old woman with no past medical or surgical history presents to the emergency room with pain in her groin. She reports that the pain has become so severe that she is nauseous and has vomited multiple times over the past day. On physical examination, her abdomen is distended, and a small, irreducible mass is palpated inferior and lateral to the pubic tubercle. Which of the following statements is correct?

(A) Incarceration and strangulation rarely occur with this condition

(B) The presence of a preformed peritoneal sac causes this congenital condition

(C) This condition typically requires a laparotomy to obtain adequate exposure

(D) This diagnosis is seen most commonly in middle-aged and older women

(E) Watchful waiting is appropriate if reduction can be achieved

QUESTION 2-42

Which of the following is the strongest risk factor for the development of an abdominal aortic aneurysm (AAA)?

(A) Age over 75

(B) Current cigarette smoking

(C) Diabetes mellitus

(D) Family history of AAA

(E) History of previous or current antihypertensive medications

QUESTION 2-43

After an uneventful total thyroidectomy, a 58-year-old female is found to have a weak voice and difficulty coughing in the recovery room. She is hemodynamically stable with 95% saturation on 2 L oxygen via nasal canal. Her examination is unremarkable, and her wound is intact without drainage or evidence of a hematoma. Direct laryngoscopy is performed at the bedside, and her right vocal cord is noted to be in a fixed position. What is the most likely cause of her symptoms?

(A) Complete transection of the right recurrent laryngeal nerve (RLN)

(B) Compression from a submuscular bleed and hematoma

(C) Stretch injury to the right RLN

(D) Transection of the external branch of the superior laryngeal nerve (EBSLN)

(E) Trauma secondary to endotracheal intubation

QUESTION 2-44

A 26-year-old man with no significant past medical history arrives to the emergency department complaining of right lower quadrant pain. His pain initially began in the periumbilical region, and he ignored the pain for the last 48 hours. His temperature is 39°C and his white blood cell count is 16,000/μL. Computed tomography (CT) scan of the abdomen and pelvis shows a 6- × 8-cm rim-enhancing fluid collection in the right pelvis. What is the best next step in the management of this patient's disease?

(A) Admission to the surgical ward, intravenous antibiotics, and laparoscopic appendectomy during this hospitalization

(B) Admission to the surgical ward, intravenous antibiotics, and repeat CT of the abdomen and pelvis in 5 days

(C) Admission to the surgical ward, intravenous antibiotics, percutaneous drainage of the fluid collection, and interval appendectomy

(D) Discharge patient on oral antibiotics

(E) Discharge patient on oral antibiotics and then perform interval appendectomy

۰۲۱-۶۶۱۹۸۵۱۴ www.myuptodate.com دریافت آخرین نسخه آپتودیت آفلاین

QUESTION 2-45

A 42-year-old male construction worker is brought to the emergency room after a 120-kg concrete plate landed on his lower anterior torso. The patient has a heart rate of 110 beats per minute and blood pressure of 95/55 mm Hg. His pelvis is unstable on examination, and you temporarily stabilize the pelvis using a binder and complete your assessment, which is otherwise negative. His vital signs respond only transiently to crystalloid resuscitation. You decide to take him to the angiography suite for potential pelvic embolization. What is the most likely source of hemorrhage in this patient?

(A) Bridging veins in the pelvis

(B) Common iliac artery

(C) Internal iliac artery

(D) Internal iliac vein

(E) Superior gluteal artery

QUESTION 2-46

You are called to the emergency department to assess a 17-year-old female with abdominal pain and suspicion of an incarcerated inguinal hernia. She has bulimia and has had several admissions to the psychiatric ward. The hernia is nonreducible, and you schedule her for surgery. Her laboratory values come back as follows:

WBC 11,000/mm^3
Hbg 11.0 g/dL
Lactic acid 3.1 mg/dL
Na 140 mEq/L
Cl 96 mEq/L
K 2.9 mEq/L
Blood pH 7.49
Urine pH 6.1

The medical student asks you why her urine is acidotic in the setting of a metabolic alkalosis. Your answer is:

(A) The patient has a renal tubular acidosis leading to low pH of the urine

(B) The patient likely has a urinary tract infection with acid-producing bacteria

(C) The patient's gastrointestinal losses stimulate the renin–angiotensin–aldosterone axis, decreasing HCO_3^- excretion into the urine

(D) The patient's gastrointestinal losses stimulate the renin–angiotensin–aldosterone axis, increasing H^+ excretion into the urine

(E) To help with weight loss, the patient is taking a diuretic that acidified the urine

QUESTION 2-47

An 82-year-old otherwise healthy and asymptomatic male with a recently diagnosed sigmoid colon cancer was noted on computed tomography (CT) to have a 6.1-cm infrarenal abdominal aortic aneurysm (AAA). The rest of his CT scan was unremarkable. The most appropriate management for this patient is:

(A) Endovascular aneurysm repair (EVAR), then left hemicolectomy at a later date

(B) Left hemicolectomy and continued surveillance for AAA growth

(C) Left hemicolectomy first, then EVAR at a later date

(D) Open AAA repair first, then left hemicolectomy at a later date

(E) Simultaneous open AAA repair and left hemicolectomy

QUESTION 2-48

In which of the following patients is laparoscopic splenectomy contraindicated and an open approach required?

(A) 18-year-old with hereditary spherocytosis and splenomegaly (spleen greater than 20 cm in length)

(B) 36-year-old morbidly obese female with a body mass index (BMI) of 38 kg/m^2

(C) 52-year-old male with cirrhosis and portal hypertension

(D) 61-year-old female with idiopathic thrombocytopenic purpura and a platelet count of 45,000/mm^3

(E) 68-year-old male with a splenic lymphangiosarcoma

۰۲۱-۶۶۱۹۸۵۱۴ www.myuptodate.com دریافت آخرین نسخه آپتودیت آفلاین

QUESTION 2-49

A 22-year-old male college student presents with anorexia and vague abdominal pain 6 months after returning from a semester abroad in Argentina. A computed tomography (CT) scan of his abdomen reveals a 10-cm, thick-walled cystic lesion and several smaller neighboring cysts. He is afebrile, has a normal white blood cell count, and normal total bilirubin. This patient is most appropriately managed with:

(A) Immediate surgical resection followed by albendazole

(B) Immediate surgical resection followed by metronidazole

(C) Medical monotherapy with metronidazole

(D) Preoperative albendazole followed by surgical therapy

(E) Preoperative metronidazole followed by surgical resection

QUESTION 2-50

A 23-year-old man presents after sustaining blunt head trauma during a physical altercation. He is noted to have drooping of his right nasolabial fold and inability to wrinkle his right forehead or close his right eye. The most likely cause of his symptoms is:

(A) Bell palsy

(B) Intracranial malignancy

(C) Parietal bone fracture

(D) Stroke

(E) Temporal bone fracture

QUESTION 2-51

A cachectic-appearing 45-year-old female with a history of long-term alcoholism is admitted for recurrent small bowel obstruction after multiple episodes of nausea and vomiting for the past 5 days. She is managed conservatively with a nasogastric tube, NPO status, intravenous fluids, and total parenteral nutrition (TPN). The best way to prevent the development of refeeding syndrome in this patient is:

(A) Avoid hyponatremia by adjusting the sodium amount in the TPN bag on a daily basis

(B) Follow daily nutritional labs such as pre-albumin and triglycerides to ensure that the nutritional needs of the patient are being met

(C) Institute caloric repletion rapidly, at 40 kcal/kg/day and slowly increase rate after the first week

(D) Monitor closely for hypoglycemia, a common paradoxical effect of excessive parenteral feeding of severely malnourished patients

(E) Strictly monitor vital signs and fluid balance and replete electrolytes as needed

QUESTION 2-52

After 1 week of antibiotics for right lower lobe pneumonia, a 55-year-old woman still has intermittent fevers and a leukocytosis. Chest radiography demonstrates a large pleural effusion. Thoracentesis demonstrates thick fluid with polymorphonuclear cells and bacteria, and a thoracostomy tube is placed. Over the next week the drainage from the thoracostomy tube decreases, yet she continues to have fevers, leukocytosis, and a persistent oxygen requirement. Computed tomography of her chest demonstrates loculated fluid collections in her right hemithorax that are not in communication with the thoracostomy tube, pleural thickening, and an incompletely expanded right lower lobe. Which of the following is the most appropriate therapy?

(A) Broadening antibiotic therapy with addition of antifungal coverage

(B) Noninvasive ventilation with positive pressure therapy

(C) Placement of an additional thoracostomy tube

(D) Thoracoscopic or open decortication

(E) Thoracoscopic or open resection of the involved right lower lobe

۰۲۱-۶۶۱۹۸۵۱۴ www.myuptodate.com دریافت آخرین نسخه آپتودیت آفلاین

QUESTION 2-53

A 53-year-old woman was found to have a suspicious lesion on routine screening mammography. She subsequently underwent stereotactic core biopsy of the lesion. Which of the following pathologic findings puts her at greatest risk of breast cancer?

(A) Apocrine metaplasia

(B) Atypical ductal hyperplasia

(C) Intraductal papilloma

(D) Mammary duct ectasia

(E) Sclerosing adenosis

QUESTION 2-54

A 51-year-old male with a history of chronic pancreatitis and pseudocysts presents to the emergency room with subjective dyspnea and ascites. His ascitic fluid has an amylase value of 2,476 Units/L. The patient is admitted and managed nonoperatively. Despite these measures, he develops increasing respiratory symptoms. You relieve his immediate symptoms with a bedside thoracentesis. Which next step in management is most appropriate?

(A) Drain placement by interventional radiology

(B) Endoscopic retrograde cholangiopancreatography (ERCP) with pancreatic stent placement

(C) Minilaparotomy and evacuation of the ascites

(D) Transjugular portosystemic shunt

(E) Whipple procedure

QUESTION 2-55

A 12-year-old boy tripped and fell on his outstretched right hand. Upon presentation to the emergency department, the boy has a swollen and extremely tender right elbow. On physical examination, the hand appears warm, but the radial pulse is absent. An x-ray reveals a displaced supracondylar humerus fracture. What is the next step in management of this patient?

(A) Closed reduction of fracture with application of a splint

(B) External fixation of fracture

(C) Observation

(D) Operative exploration for vascular injury

(E) Place in splint

QUESTION 2-56

The following laboratory finding is most consistent with the diagnosis of the syndrome of inappropriate antidiuretic hormone secretion (SIADH):

(A) Plasma ADH level of 0.2 μUnits/mL

(B) Serum osmolality of 320 mOsm/kg

(C) Serum sodium of 149 mEq/L

(D) Urine osmolality of 52 mOsm/kg

(E) Urine sodium of 60 mEq/L

QUESTION 2-57

Which of the following is correct regarding endoleaks following endovascular repair of abdominal aortic aneurysms?

(A) The sole indication for intervention for type II endoleaks is patient symptoms

(B) Type I and type II endoleaks generally require timely intervention

(C) Type I and type III endoleaks generally require timely intervention

(D) Type IV endoleak is defined as persistent sac pressurization in the absence of radiographic findings consistent with type I, II, or III endoleak

(E) Type V endoleak typically occurs during the procedure and resolves with the withdrawal of anticoagulation

QUESTION 2-58

A 58-year-old woman undergoes a lumpectomy and sentinel lymph node biopsy for a 1-cm infiltrating ductal adenocarcinoma in her right breast. Pathologic review of her sentinel nodes is negative for metastatic disease. The next step in management should include:

(A) Chemotherapy

(B) Completion axillary lymph node dissection to confirm that all nodes in the axilla are negative

(C) Completion mastectomy

(D) Radiation therapy to the right breast

(E) Repeat sentinel lymph node biopsy secondary to the high false-negative rate of the procedure

۰۲۱-۶۶۱۹۸۵۱۴ www.myuptodate.com دریافت آخرین نسخه آپتودیت آفلاین

QUESTION 2-59

A 65-year-old man presents to the emergency room with bilious vomiting and abdominal pain. He is of status post a sigmoidectomy 6 weeks ago for diverticular disease. He is afebrile, pulse is 110 beats per minute, and blood pressure is 120/70 mm Hg. Which of the following is the most likely cause for his symptoms?

(A) Anastomotic leak

(B) Perforated diverticulum

(C) Recurrent diverticular disease

(D) Small bowel obstruction

(E) Urinary tract infection

QUESTION 2-60

A trimodal distribution exists for mortality after traumatic injury. How can mortality during the first mortality peak best be prevented?

(A) Early intubation and mechanical ventilation

(B) Early operative intervention

(C) Injury prevention and control strategies

(D) Prehospital resuscitation with intravenous fluids

(E) Transport to a level one trauma center within 1 hour of injury

QUESTION 2-61

Which of the following is associated with vitamin K deficiency?

(A) Glossitis

(B) Megaloblastic anemia

(C) Prolonged prothrombin time

(D) Rickets

(E) Scurvy

QUESTION 2-62

A 74-year-old man who underwent open infrarenal abdominal aortic aneurysm (AAA) repair recently developed sigmoid diverticulitis with a 4-cm abscess that was successfully treated with percutaneous drainage and antibiotics. He now returns to the emergency department 2 months after treatment of his diverticulitis with persistent fevers, malaise, leukocytosis, and back pain. He is found to be bacteremic, and computed tomography (CT) scan demonstrates complete resolution of his diverticular abscess but with periaortic stranding and some gas bubbles surrounding the prior aortic repair. The most appropriate management of this patient is:

(A) Excision of the aortic graft and axillary–bifemoral bypass

(B) Exploratory laparotomy with abdominal washout

(C) Long-term intravenous antibiotics

(D) Repeat percutaneous drainage

(E) Sigmoid colectomy

QUESTION 2-63

A 65-year-old man recently underwent an abdominal computed tomography (CT) scan as part of a workup following a motor vehicle collision. A 5.5-cm heterogeneous adrenal mass was incidentally found, and he is referred to your clinic for evaluation and management. He otherwise has no past medical history, his blood pressure is normal, and his physical examination is unremarkable. Laboratory studies reveal a normal potassium level, normal serum and urine-free cortisol, and normal overnight dexamethasone test and plasma-free and urine metanephrines are negative. The next step in management is:

(A) Ipsilateral adrenalectomy and nephrectomy

(B) Ipsilateral laparoscopic adrenalectomy

(C) Nothing since the tumor is nonfunctional

(D) Observation and repeat CT scans every 3 to 6 months to see if the tumor is enlarging

(E) Steroid suppression and repeat imaging

۰۲۱-۶۶۱۹۸۵۱۴ www.myuptodate.com دریافت آخرین نسخه آپتودیت آفلاین

QUESTION 2-64

A 65-year-old man presents with hematemesis. He is resuscitated and started on a pantoprazole infusion. Upper endoscopy identifies a posterior duodenal ulcer with a nonbleeding visible vessel that is coagulated and clipped. Which of the following is true regarding the potential for rebleeding in this duodenal ulcer?

(A) An episode of rebleeding after endoscopic treatment mandates surgical exploration

(B) Continuation of the intravenous proton pump inhibitor after endoscopic therapy is unnecessary

(C) The posterior location of the ulcer is associated with a lower risk of rebleeding

(D) The presence of a nonbleeding visible vessel is associated with a higher risk of rebleeding than an adherent clot

(E) Younger patients have a higher risk of rebleeding

QUESTION 2-65

Which of the following represents the most effective long-term injury prevention strategy?

(A) Economic incentives

(B) Education

(C) Engineering

(D) Environment

(E) Law enforcement

QUESTION 2-66

Your medical student wants to know why yellow adhesive drapes were applied to a patient's skin prior to incision. Which of the following would be a correct reply regarding the use of iodine-impregnated drapes?

(A) Iodine-impregnated drapes are a required component of the Surgical Care Improvement Project (SCIP)

(B) Iodine-impregnated drapes are most beneficial when used for contaminated and clean–contaminated cases

(C) Iodine-impregnated drapes can be used alone in place of other skin preparations

(D) Iodine-impregnated drapes can reduce microbial counts on the skin

(E) Iodine-impregnated drapes have been shown to reduce the incidence of surgical site infections (SSIs)

QUESTION 2-67

A 25-year-old tall and thin male presents to the emergency room with sudden onset of dyspnea and right-sided pleuritic chest pain. Although in pain, he is breathing with 97% oxygen saturation on room air. Physical examination is normal but chest radiograph demonstrates a 2.5-cm apical pneumothorax which does not track down the lateral wall. He reports that a similar episode happened 1 year ago, at which time he was admitted for observation but discharged the following day after his lung re-expanded on its own. Definitive management of his underlying condition is best accomplished by which of the following?

(A) Admission to the hospital for pulse oximetry and serial chest radiographs

(B) Discharge from the emergency department with clinic follow-up in 1 week

(C) Placement of a thoracostomy tube and chemical pleurodesis with doxycycline or talc

(D) Placement of a thoracostomy tube with removal following resolution of the pneumothorax

(E) Video-assisted thoracoscopic surgery (VATS) with resection of any residual bullae and mechanical pleurodesis

QUESTION 2-68

A 45-year-old female has a 1.5-cm mass in her right breast. There are no palpable axillary nodes and her physical examination is otherwise unremarkable. She undergoes a stereotactic core biopsy which reveals infiltrating ductal carcinoma. What is the most appropriate treatment option for her?

(A) Lumpectomy alone

(B) Lumpectomy and sentinel lymph node biopsy

(C) Lumpectomy and sentinel lymph node biopsy followed by radiation

(D) Lumpectomy followed by radiation

(E) Modified radical mastectomy followed by radiation if axillary nodes are negative

۰۲۱-۶۶۱۹۸۵۱۴ www.myuptodate.com دریافت آخرین نسخه آپتودیت آفلاین

QUESTION 2-69

A 37-year-old man undergoes a laparoscopic appendectomy for presumed appendicitis and is discharged home without any complications. Pathologic examination reveals a 1-cm adenocarcinoma of the tip of the appendix that is margin negative. What is the next step in management?

(A) Chemotherapy

(B) Close surveillance with computed tomography scan in 6 months

(C) No further therapy

(D) Positron emission tomography scan to evaluate for residual disease

(E) Right hemicolectomy

QUESTION 2-70

A 24-year-old male is brought to the emergency department 1 hour following an assault with a baseball bat in which he suffered repeated head trauma. On arrival, he is hemodynamically stable. He opens his eyes to command, is speaking in incoherent statements, and moves his extremities to command. Which of the following is the most important predictor of outcome in this patient?

(A) Cranial nerve responses

(B) Glasgow Coma Scale (GCS) score on hospital admission

(C) Initial vital signs on presentation

(D) Transport time from field to emergency department

(E) Verbal responses to questions

QUESTION 2-71

Which of the following scenarios represents appropriate use of isolation gowns when entering the room of a patient infected with *Clostridium difficile*?

(A) Using the same isolation gown for two different patients in two different rooms as long as both are infected with *Clostridium difficile*

(B) Wearing an isolation gown is not necessary if one wears a laboratory coat

(C) Wearing an isolation gown only if contact with the patient is anticipated

(D) Wearing an isolation gown that covers the body from the neck to mid-thigh including the entire back and arms

(E) When removing the gown, turning the contaminated side inward, rolled into a bundle, and discarding the gown in any container outside the patient's room

QUESTION 2-72

The left vertebral artery most commonly:

(A) Arises from the left common carotid artery

(B) Is distal to the left costocervical trunk

(C) Is the first branch arising from the left subclavian artery

(D) Is the source of the deep cervical artery

(E) Joins the anterior communicating artery to form the anterior component of the Circle of Willis

QUESTION 2-73

A 45-year-old male is referred to you for management of a 2-cm lesion in his right thyroid lobe, which on biopsy is found to be medullary thyroid carcinoma (MTC). Evaluation of both sides of his neck clinically and radiographically shows no evidence of nodal disease. When discussing management options, you tell him that the treatment of choice for localized MTC is:

(A) Observation, unless he has a family history of MEN

(B) Thyroid lobectomy

(C) Thyroid lobectomy and central lymph node dissection

(D) Total thyroidectomy

(E) Total thyroidectomy and central lymph node dissection

۰۲۱-۶۶۱۹۸۵۱۴ www.myuptodate.com دریافت آخرین نسخه آپتودیت آفلاین

QUESTION 2-74

A 29-year-old surgery resident presents with anorexia, weight loss, and right upper quadrant pain. A month ago, she returned from a 1-year medical mission to Mexico. Shortly after she had arrived in Mexico, she had a brief bout of self-limited diarrhea but otherwise remained in good health for the duration of the trip. A computed tomography (CT) scan of the abdomen reveals a right-sided intrahepatic rim-enhancing fluid-filled lesion. The first-line treatment option for this patient is:

(A) Intravenous metronidazole

(B) Intravenous praziquantel

(C) Intravenous praziquantel followed by percutaneous drainage

(D) Oral paromomycin

(E) Percutaneous abscess drainage

QUESTION 2-75

A 74-year-old female is brought to the emergency room after a fall. She has normal vital signs and a Glasgow Coma Scale (GCS) score of 14. Her past medical history is notable for hypertension, osteoporosis, and colon cancer. Her physical examination reveals minimal tenderness to palpation of her upper lumbar spine. She has no motor or sensory neurologic deficits of the lower extremities, and her rectal examination demonstrates normal tone. Computed tomography is notable only for wedge compression fractures of the L1 and L2 spinal bodies. What is the most appropriate acute management of her spinal injury?

(A) Bed rest, custom orthosis, and analgesia

(B) No intervention—discharge home with appropriate analgesia

(C) Open reduction and plate fixation via anterior approach

(D) Open reduction and plate fixation via posterior approach

(E) Percutaneous vertebroplasty

QUESTION 2-76

A 59-year-old man weighing approximately 65 kg and having a long history of hepatitis C presents with a 7-cm skin laceration. For anesthesia, 20 mL of 2% lidocaine is infiltrated into the wound bed. While suturing the wound, the patient begins to have generalized convulsions. Which of the following confers an increased risk for lidocaine toxicity?

(A) Active bacterial infection

(B) Coronary artery disease

(C) Hepatic impairment

(D) Immunodeficiency

(E) Renal impairment

QUESTION 2-77

A 65-year-old male undergoes transhiatal esophagectomy for adenocarcinoma of the distal esophagus. Chest radiograph on postoperative day 5 is notable for a right-sided effusion, which is drained and found to have elevated levels of triglycerides, consistent with a chylothorax. Where is the most common location for termination of the thoracic duct?

(A) Directly into the superior vena cava

(B) Into the confluence of the left internal jugular and subclavian veins

(C) Into the confluence of the right internal jugular and subclavian veins

(D) Into the cisterna chyli

(E) Into the main portal vein

QUESTION 2-78

A 45-year-old gentleman presents with a 2-cm left thyroid nodule that is biopsy-proven papillary carcinoma. Ipsilateral neck ultrasound demonstrates two suspicious nodes, one of which on biopsy shows papillary carcinoma. Definitive management should include the following:

(A) Total thyroidectomy

(B) Total thyroidectomy with modified radical neck dissection

(C) Total thyroidectomy with selective lymph node sampling

(D) Total thyroidectomy with systemic chemotherapy

(E) Total thyroidectomy with unilateral neck radiotherapy

۰۲۱-۶۶۱۹۸۵۱۴ www.myuptodate.com دریافت آخرین نسخه آپتودیت آفلاین

QUESTION 2-79

A 57-year-old man with a history of psoriasis presents to the hospital with signs and symptoms of acute pancreatitis. Computed tomography (CT) shows diffuse enlargement of the pancreas. The pancreatic duct appears to be diminutive. He has elevated levels of IgG4 and after ruling out malignancy with endoscopic ultrasound and biopsy, a diagnosis of autoimmune pancreatitis is made. What is the next step in management of this patient?

(A) Frey procedure

(B) Glucocorticoids

(C) Intravenous antibiotics

(D) No further management

(E) Puestow procedure

QUESTION 2-80

A patient with traumatic head injury is brought to the emergency room. Which of the following scenarios is MOST appropriate for conservative, nonoperative management?

(A) A 79-year-old neurologically intact man with an open depressed skull fracture (depression of 6 mm) and no evidence of intracranial hematoma

(B) A 24-year-old neurologically intact woman with a closed depressed skull fracture (depression of 13 mm) and no evidence of intracranial hematoma

(C) A 35-year-old neurologically intact man with an open depressed fracture involving the frontal sinus with radiologic evidence of a dural tear

(D) An unresponsive 1-year-old female with an obvious concave deformity of the parietal aspect of her skull (a "ping-pong" fracture) and an underlying 2-cm intracranial hematoma

(E) A 40-year-old neurologically intact woman with an open depressed skull fracture contaminated with soil and glass

QUESTION 2-81

An 8-year-old pedestrian struck by a motor vehicle presents in extremis with a closed left femur fracture and severe right craniofacial injury. The patient is intubated and bilateral chest tubes are placed with return of 150 mL of blood from the left chest tube and 100 mL of blood from the right chest tube. As the patient is fluid-resuscitated, Focused Abdominal Sonography for Trauma (FAST) examination is performed and is negative. The patient remains hypotensive and unresponsive to initial fluid resuscitation. The most likely source of this patient's hypotension is injury to the:

(A) Femur

(B) Heart

(C) Lung

(D) Spleen

(E) Stomach

QUESTION 2-82

A 65-year-old male patient with a 50 pack-year smoking history undergoes pulmonary function testing for evaluation of chronic obstructive pulmonary disease. His results demonstrate a forced expiratory volume in 1 second (FEV_1)/forced vital capacity (FVC) ratio of less than 70% of predicted and an FEV_1 of less than 50% of predicted. Which of the following is true about functional residual capacity?

(A) It can be measured directly using normal spirometry

(B) It is the sum of expiratory reserve volume and residual volume

(C) It is typically decreased among patients with chronic obstructive pulmonary disease

(D) It is typically increased in patients with idiopathic pulmonary fibrosis

(E) It represents the total lung volume remaining after maximal exhalation

۰۲۱-۶۶۱۹۸۵۱۴ www.myuptodate.com دریافت آخرین نسخه آپتودیت آفلاین

QUESTION 2-83

A 49-year-old female is evaluated by her primary care physician for myalgias, recurrent kidney stones, and depression. After a thorough workup, she is diagnosed with primary hyperparathyroidism. Preoperative localization is attempted with a sestamibi scan, but the study failed to identify any abnormal parathyroid glands. The patient is taken to the operating room for definitive treatment. After performing bilateral neck explorations, all four glands are found and appear significantly enlarged and abnormal. Which of the following is the preferred treatment option?

(A) Biopsy of all four parathyroid glands and removal of the most hyperplastic gland

(B) Removal of all four enlarged parathyroid glands

(C) Removal of all four parathyroid glands with autotransplantation of half of a gland into the brachioradialis muscle

(D) Removal of the largest parathyroid gland

(E) Removal of the three largest and most vascular parathyroid glands

QUESTION 2-84

A 64-year-old woman who is postoperative day 23 status post Ivor Lewis esophagectomy for esophagogastric junction cancer is readmitted to the surgical intensive care unit with fever, hypotension, and a productive cough. She is resuscitated with fluid and started on broad-spectrum antibiotics. Chest x-ray demonstrates right lower lobe consolidation but no pleural fluid collection. Esophagogram reveals a small tracheo-neoesophageal fistula at the level of the esophagogastric anastomosis. The patient is made NPO and total parenteral nutrition (TPN) is initiated. Which of the following is the most appropriate next step in management of this complication?

(A) Primary surgical repair

(B) Reintubation

(C) Tracheal ring resection

(D) Tracheal stent

(E) Video-assisted thoracoscopic decortication and tube thoracostomy placement

QUESTION 2-85

A 37-year-old G1P1 woman presents to the emergency department with sudden-onset, severe abdominal pain. Her history is notable for current tobacco use and an intrauterine contraceptive device placed 3 years ago. She is afebrile with a heart rate of 130 beats per minute, blood pressure of 80/50 mm Hg, respiratory rate of 24 breaths per minute, and oxygen saturation of 93% on room air. Her examination is notable for peritonitis and adnexal tenderness. The most probable cause of her symptoms is:

(A) Appendicitis

(B) Pelvic inflammatory disease

(C) Ruptured ectopic pregnancy

(D) Ruptured uterus

(E) Tubo-ovarian abscess

QUESTION 2-86

Which of the following neck procedures puts a patient most at risk for paresthesias in the postoperative period?

(A) Central neck dissection

(B) Parathyroid autotransplantation

(C) Parathyroidectomy

(D) Thyroid lobectomy

(E) Total thyroidectomy

۰۲۱-۶۶۱۹۸۵۱۴ www.myuptodate.com دریافت آخرین نسخه آپتودیت آفلاین

QUESTION 2-87

The relationship of a patient's stroke volume and left ventricular end-diastolic pressure is depicted below. If a patient's current status is depicted by point A, a bolus of fluid will cause which of the following changes?

(A) From A to B

(B) From A to C

(C) From A to D

(D) From A to E

(E) No change

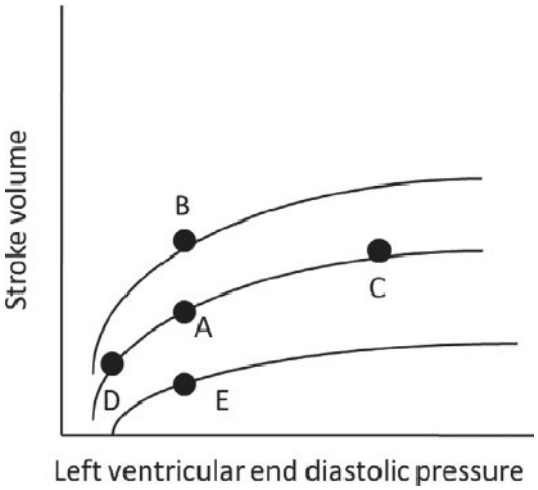

QUESTION 2-88

A 54-year-old man presents with worsening abdominal pain, nausea, vomiting, and obstipation. Plain films reveal dilated loops of small bowel and an abdominal computed tomography is concerning for a high-grade small bowel obstruction secondary to intussusception. The patient is resuscitated and taken to the operating room where he is found to have an ileal intussusception. After reduction and inspection of this segment of bowel, a mass is felt within the involved segment. A frozen section of the mass is concerning for lymphoma. Surgical management should consist of:

(A) *Helicobacter pylori* treatment in the postoperative period

(B) Inguinal lymph node sampling

(C) Reduction of the intussuscepted segment of bowel and abdominal closure, followed by systemic chemotherapy

(D) Segmental resection with wide resection of the involved mesentery

(E) Thorough abdominal exploration and random lymph node sampling

QUESTION 2-89

A 56-year-old woman with a history of gastroesophageal reflux disease presents with dyspepsia, belching, and epigastric pain. She undergoes esophagogastroduodenoscopy (EGD), which identifies a 1.8-cm smooth mucosal nodule on the lateral wall of the second portion of the duodenum. Biopsies of the lesion reveal a duodenal carcinoid tumor. What treatment should be recommended?

(A) Expectant management

(B) Pancreaticoduodenectomy

(C) Repeat EGD in 6 months

(D) Repeat EGD with endoscopic excision

(E) Transduodenal excision with primary repair of duodenum and lymphadenectomy

۰۲۱-۶۶۱۹۸۵۱۴ www.myuptodate.com دریافت آخرین نسخه آپتودیت آفلاین

QUESTION 2-90

A 39-year-old male who was not wearing a helmet presents after a motorcycle crash with a Glasgow Coma Scale score of 4, significant craniofacial injury, and asymmetric pupils. Vital signs are as follows: Pulse of 115 beats per minute, blood pressure of 70/50 mm Hg, and respiratory rate of 30 breaths per minute. The patient is intubated and noted to have bilateral breath sounds. Which of the following is the most important next step in management?

(A) Bilateral carotid Doppler/ultrasonography (duplex)

(B) Computed tomography (CT) scan of head without contrast

(C) CT of chest, abdomen, and pelvis with contrast

(D) Focused abdominal sonography for trauma (FAST)

(E) Plain radiograph of chest and pelvis

QUESTION 2-91

A postoperative patient with nausea and abdominal discomfort is discharged on both promethazine and metoclopramide. The patient has also been taking another antiemetic at home for several months, since initiating chemotherapy for her underlying malignancy, but she cannot recall the name of the drug. Two days later, the patient calls reporting a tremor and a feeling of stiffness in her extremities. Which of the following is the most appropriate next step?

(A) Continue both promethazine and metoclopramide and prescribe diphenhydramine for symptomatic relief

(B) Increase the dose of metoclopramide, switch promethazine to ondansetron, and have the patient return if symptoms persist or worsen

(C) Increase the dose of promethazine, switch metoclopramide to ondansetron, and have the patient return if symptoms persist or worsen

(D) Obtain an urgent EEG to rule out seizure activity because antiemetics may lower seizure threshold

(E) Stop all current antiemetics, prescribe a serotonin receptor inhibitor such as ondansetron, and have the patient return if symptoms persist or worsen

QUESTION 2-92

A 47-year-old female presents with increasing dyspnea on exertion. Chest x-ray is normal, and echocardiography reveals normal left ventricular function but a hypertrophied right ventricle with paradoxical systolic septal motion and significant tricuspid regurgitation. Right heart catheterization reveals a mean pulmonary artery pressure of 30 mm Hg and a pulmonary capillary wedge pressure of 10 mm Hg. Which of the following diagnoses is most likely?

(A) Chronic bronchitis

(B) Chronic obstructive pulmonary disease

(C) Idiopathic pulmonary arterial hypertension

(D) Left ventricular diastolic dysfunction

(E) Mitral stenosis

QUESTION 2-93

A 36-year-old woman with thyrotoxicosis and a large goiter extending below her sternum undergoes a radioactive iodine uptake study that shows multiple areas of intense uptake. Which of the following is the best management for her condition?

(A) Methimazole

(B) Propylthiouracil

(C) Radioactive iodine-131 ablation

(D) Thyroid lobectomy

(E) Total thyroidectomy

QUESTION 2-94

A 50-year-old man undergoes a routine screening colonoscopy during which several polyps are removed. While in the recovery room he reports significant abdominal pain and is noted to have abdominal distention on physical examination. A portable chest radiograph shows free intraperitoneal air. Where is the perforation most likely to have occurred?

(A) Ascending colon

(B) Descending colon

(C) Rectum

(D) Sigmoid colon

(E) Transverse colon

۰۲۱-۶۶۱۹۸۵۱۴ www.myuptodate.com دریافت آخرین نسخه آپتودیت آفلاین

QUESTION 2-95

A 22-year-old female presents with 1 day of anorexia, nausea, and periumbilical pain progressing over time to right lower quadrant pain. Her greatest tenderness is over McBurney point, she has a positive Rovsing sign, and there is no cervical motion tenderness on bimanual pelvic examination. She has a white blood cell count of $15.8 \times 10^3/\mu L$, a negative urine pregnancy test, and negative urine test for *Neisseria gonorrhea* and *Chlamydia trachomatis*. Upon laparoscopic exploration, a grossly inflamed appendix and a 4-cm smooth, white, mobile, unilocular cystic mass arising from the left ovary are noted. The remaining ovarian tissue appears normal. After performing an appendectomy, what is the most appropriate management of the ovarian mass?

(A) Aspiration

(B) Cystectomy

(C) No intervention

(D) Oophorectomy

(E) Oophoropexy

QUESTION 2-96

A 25-year-old man weighing 80 kg suffers partial-thickness flame burns to his entire left and right upper extremities and to his entire left lower extremity. He is brought to the emergency room 4 hours after the injury. His airway is secured for a depressed Glasgow Coma Scale (GCS) score, and two large bore intravenous lines are placed. What rate of intravenous fluid administration is this patient expected to need over the next 4 hours in order to achieve adequate resuscitation?

(A) Lactated ringers at 1,440 mL/hr

(B) Lactated ringers at 2,500 mL/hr

(C) Lactated ringers at 721 mL/hr

(D) Normal saline at 1,440 mL/hr

(E) Normal saline at 721 mL/hr

QUESTION 2-97

A 75-year-old woman with known congestive heart failure undergoes an elective low anterior resection for adenocarcinoma of the colon. On postoperative day 3 she develops hypoxia from cardiogenic pulmonary edema and is treated with intravenous furosemide. Which of the following correctly describes the physiology of the pulmonary capillary circulation and pulmonary interstitium?

(A) In cardiogenic pulmonary edema there is an increase in the net flow of fluid from the pulmonary interstitium into the pulmonary capillaries

(B) In pneumonia there is a decrease in the net flow of fluid from the pulmonary capillaries into the pulmonary interstitium

(C) In the normal lung there is a net movement of fluid from the pulmonary capillaries into the pulmonary interstitium

(D) In the normal lung there is a net movement of fluid from the pulmonary interstitium into the pulmonary capillaries

(E) In the normal lung there is no net movement of fluid between the capillaries and the pulmonary interstitium

QUESTION 2-98

A 32-year-old woman early in her second trimester of pregnancy presents to her obstetrician with tachycardia and excessive sweating. Laboratory evaluation reveals low thyroid-stimulating hormone (TSH) with high T4 and presence of Thyroid Receptor Antibody (TRAb). The most appropriate treatment for this patient is:

(A) Observation

(B) Total thyroidectomy

(C) Treatment with methimazole

(D) Treatment with propylthiouracil (PTU)

(E) Radioactive iodine ablation

۰۲۱-۶۶۱۹۸۵۱۴ www.myuptodate.com دریافت آخرین نسخه آپتودیت آفلاین

QUESTION 2-99

A 64-year-old man is admitted to the hospital with a 1-day history of abdominal pain, nausea, and vomiting. He has an elevated serum amylase and lipase (500 and 600 Units/L respectively). His liver function tests including bilirubin are within normal limits with the exception of an elevated alkaline phosphatase (188 Units/L). He has an unremarkable past medical history, does not use any medications, and has no history of alcohol use. A right upper quadrant ultrasound demonstrates cholelithiasis without evidence of cholecystitis. Apart from admission to the hospital and resuscitation, what is the most appropriate step in the overall management of this patient?

(A) Cholecystectomy as an outpatient

(B) Cholecystectomy prior to discharge from the hospital

(C) Urgent cholecystectomy on admission

(D) Urgent endoscopic retrograde cholangiopancreatography (ERCP) on admission

(E) Urgent magnetic resonance cholangiopancreatography (MRCP) on admission

QUESTION 2-100

A 19-year-old sexually active woman presents with acute pleuritic right upper quadrant pain radiating to her right shoulder. Laboratory findings are notable for a leukocytosis and mildly elevated transaminases. Her laboratory studies are otherwise normal. Her presentation is most consistent with:

(A) Asherman syndrome

(B) Fitz-Hugh–Curtis syndrome

(C) Meigs syndrome

(D) Mirizzi syndrome

(E) Sheehan syndrome

QUESTION 2-101

A 20-year-old woman presents with a 3-cm laceration on the parietal region of her scalp after tripping on a sidewalk. On physical examination, you note a linear wound with clean edges in the center of hair-bearing scalp that continues to ooze. Which of the following repair options is recommended?

(A) Clean the wound, allow to heal by secondary intention

(B) Clean the wound, clip surrounding hair, suture closed

(C) Clean the wound, leave surrounding hair in place, suture closed

(D) Clean the wound, shave surrounding hair, apply skin glue

(E) Clean the wound, shave surrounding hair, suture closed

QUESTION 2-102

A newborn infant has persistent cyanosis on day of life 5. Echocardiography reveals D-transposition of the great arteries. Which of the following associated defects will help the child compensate until definitive repair can be completed?

(A) Abnormal coronary anatomy

(B) An atrial septal defect

(C) Coarctation of the aorta

(D) Pulmonary atresia

(E) Tricuspid insufficiency

QUESTION 2-103

A 26-year-old female who was recently diagnosed with Graves disease is involved in a serious motor vehicle collision. After undergoing a computed tomography (CT) scan with IV contrast, she is found to have pelvic fractures and multiple rib fractures with underlying pulmonary contusions. While in the intensive care unit hours later, she is noted to have a temperature of 39.5°C, heart rate of 130 beats per minute, oxygen saturation of 84%, and an altered mental status. After securing the patient's airway, the next best step in management is:

(A) 100 mg hydrocortisone

(B) 1,000 mg of propylthiouracil

(C) 20 mg IV metoprolol

(D) Administration of Lugol solution

(E) Subtotal thyroidectomy

۰۲۱-۶۶۱۹۸۵۱۴ www.myuptodate.com دریافت آخرین نسخه آپتودیت آفلاین

QUESTION 2-104

A 67-year-old Japanese immigrant presents to your clinic complaining of early satiety, generalized weakness, weight loss, and mild epigastric pain. Upper endoscopy reveals a 3-cm friable lesion along the lesser curvature of the stomach. The lesion abuts the gastric cardia and is 4 cm from the gastroesophageal junction. Biopsies reveal gastric adenocarcinoma. Staging workup including computed tomography of the chest, abdomen, and pelvis and an endoscopic ultrasound reveals no metastatic disease. What is the best surgical approach for this lesion?

(A) Endoscopic mucosal resection

(B) Gastrotomy with excision of mass and primary repair of stomach

(C) Subtotal gastrectomy with Billroth II reconstruction

(D) Subtotal gastrectomy with Roux-en-Y gastrojejunostomy reconstruction

(E) Total gastrectomy with Roux-en-Y esophagojejunostomy

QUESTION 2-105

During a total thyroidectomy for papillary thyroid cancer, the left recurrent laryngeal nerve (RLN) is inadvertently ligated with a 4-0 silk suture and divided. The best management strategy is:

(A) Free the nerve and perform an emergency tracheostomy

(B) Free the nerve endings and perform a laryngoscopy to assess cord motion

(C) Medialization of the ipsilateral cord

(D) Reinnervation with direct nerve repair using a branch of the ansa cervicalis

(E) Reinnervation with direct nerve repair using the spinal accessory nerve

QUESTION 2-106

A 65-year-old man with a history of congestive heart failure and coronary artery disease underwent abdominoperineal resection 7 days ago for rectal adenocarcinoma. On morning rounds, the patient is confused, tachycardic, and hypotensive with an elevated white blood cell count. Purulent drainage from his perineal wound is present. Fluids are given. The patient is most likely to have which of the following sets of hemodynamic findings:

	Cardiac Output	Vascular Resistance	Myocardial Oxygen Consumption	Right Heart Filling Pressure
(A)	⇓	⇑	⇓	⇓
(B)	⇓	⇑	⇓	⇑
(C)	⇑	⇓	⇑	⇔
(D)	⇓	⇓	⇔	⇓
(E)	⇑	⇑	⇑	⇑

QUESTION 2-107

A 45-year-old woman with idiopathic pulmonary fibrosis is referred to you for evaluation for lung transplantation. She describes progressive dyspnea and says that even with minimal exertion she now finds herself breathing by inspiring as much as she can and expiring to her fullest extent. Which pulmonary volume is she describing with her abnormal breathing pattern?

(A) Expiratory reserve volume

(B) Inspiratory reserve volume

(C) Residual volume

(D) Total lung capacity

(E) Vital capacity (VC)

۰۲۱-۶۶۱۹۸۵۱۴ www.myuptodate.com دریافت آخرین نسخه آپتودیت آفلاین

QUESTION 2-108

A 60-year-old woman presents for routine follow-up 12 years after a right-sided mastectomy and complete axillary lymph node dissection for advanced stage breast cancer. She has been in complete remission since postoperative chemotherapy but has suffered from chronic upper extremity lymphedema. An asymptomatic 2-cm blue-purple nodule is noted on the lateral right arm along with several smaller satellite lesions. The diagnosis of primary concern in this context should be:

(A) Basal cell carcinoma
(B) Histiocytoma
(C) Lymphangiosarcoma
(D) Merkel cell carcinoma
(E) Squamous cell carcinoma

QUESTION 2-109

You are performing a laparoscopic cholecystectomy on a 25-year-old woman with acute cholecystitis. The gall bladder is edematous and inflamed, and the tissue planes are difficult to discern. After clipping and dividing what you believed was the cystic duct, you realize that you have transected the common bile duct with loss of length of the common bile duct. What operative procedure should be performed to repair this injury?

(A) Direct end to end primary repair over a T-tube
(B) Direct end to side primary repair over a T-tube
(C) Kocher maneuver with end to end primary repair
(D) Pancreaticoduodenectomy
(E) Roux-en-Y hepaticojejunostomy

QUESTION 2-110

A 21-year-old football player presents with acute scrotal pain. Review of symptoms is positive for nausea and vomiting. For which of the following would immediate emergent surgical exploration be most appropriate:

(A) Epididymitis
(B) Hydrocele
(C) Reducible inguinal hernia
(D) Testicular torsion
(E) Varicocele

QUESTION 2-111

A 52-year-old hospital maintenance worker is admitted to the Emergency Department after sustaining burn injuries from a ruptured steam pipe. On physical examination, he has circumferential deep burns involving his torso, back, and both arms and hands. The patient is intubated and placed on appropriate IV fluids and brought to the operating room for urgent escharotomy. Prior to incision for escharotomy, the appropriate treatment would be:

(A) No antibiotics
(B) Silver sulfadiazine
(C) Systemic prophylactic antibiotics alone
(D) Topical and systemic prophylactic antibiotics
(E) Topical antibiotics to all affected tissues

QUESTION 2-112

A 24-year-old female is involved in an automobile accident. She has bilateral femoral fractures, a flail chest with pulmonary contusions, and solid organ injuries. She is stabilized in the intensive care unit, but her clinical course deteriorates after several days. She exhibits labored breathing, episodes of hypotension, and an increase in her creatinine from baseline. A chest radiograph reveals bilateral pulmonary infiltrates. The results of her arterial blood gas are as follows:

pH 7.38, $PaCO_2$ 30 mm Hg, PaO_2 56 mm Hg, HCO_3^- 12 mEq/L, FiO_2 50%

Administration of inhaled nitric oxide is begun. Which of the following is true of this therapy?

(A) Due to vasodilation, pulmonary blood is redistributed to nonventilated regions
(B) In addition to pulmonary vasodilation, nitric oxide causes a concomitant decrease in systemic vascular resistance
(C) Inhaled nitric oxide therapy has minimal effects on the PaO_2:FiO_2 in the initial phase of treatment
(D) Several large, randomized controlled trials have failed to show a survival benefit in patients with acute respiratory distress syndrome (ARDS) who were treated with inhaled nitric oxide
(E) When the treatment is effective, there is an increase in the pulmonary right-to-left shunt

۰۲۱-۶۶۱۹۸۵۱۴ www.myuptodate.com دریافت آخرین نسخه آپتودیت آفلاین

QUESTION 2-113

A 55-year-old woman with a history of hypertension experiences rapid onset of insulin-dependent diabetes. On examination she is slender and athletic. She also reports a rash that has appeared in various places, starting as raised red papules that subsequently blistered and then healed from the center outward. What laboratory serum test is indicated in this patient?

(A) Glucagon
(B) Insulin
(C) Metanephrines
(D) Serotonin
(E) Somatostatin

QUESTION 2-114

A 48-year-old female is undergoing laparoscopic cholecystectomy for history of gallstone pancreatitis. An intraoperative cholangiogram demonstrates a dilated common bile duct, and no filling of the duodenum. What is the most appropriate management?

(A) Convert to an open procedure and perform common bile duct exploration
(B) Delay cholecystectomy and perform endoscopic retrograde cholangiopancreatography
(C) Finish laparoscopic cholecystectomy with no further intervention
(D) Perform T-tube placement
(E) Place percutaneous transhepatic biliary drain

QUESTION 2-115

A 72-year-old woman is diagnosed with gastric adenocarcinoma and undergoes a total gastrectomy. Her postoperative course is complicated by aspiration pneumonia, leading to intubation, ventilator dependence, and eventual tracheostomy. You are called to see her 2 weeks after her tracheostomy when her nurse sees bright red blood emanating from her tracheostomy site. Your examination reveals profuse, pulsatile bleeding from the tracheostomy. What is the first step in the management of this condition?

(A) Obtain a chest x-ray
(B) Overinflate the tracheostomy tube cuff
(C) Perform a bedside thoracotomy
(D) Perform flexible bronchoscopy
(E) Remove the tracheostomy tube

QUESTION 2-116

Which of the following parenteral analgesics is contraindicated for critically ill patients or patients with known opiate abuse due to its potential side effects?

(A) Acetaminophen
(B) Buprenorphine
(C) Fentanyl
(D) Hydromorphone
(E) Ketorolac

QUESTION 2-117

A 62-year-old right-handed woman with end-stage renal disease secondary to diabetes mellitus and hypertension has a history of multiple failed left upper extremity vascular access sites. She is 9 months out from a right upper extremity brachiocephalic arteriovenous fistula (AVF). Over the past month, she has developed right hand pain with activity that has now progressed to rest pain. In addition, she has an ischemic ulcer on the tip of her index finger. The most appropriate treatment is:

(A) Banding of the venous limb of the fistula
(B) Ligation of the fistula and placement of a tunneled hemodialysis access catheter
(C) Mechanical thrombolysis
(D) Performing a bypass of the fistula and ligating the brachial artery distal to the fistula
(E) Prescribing an arm exercise regimen to improve collateral circulation

QUESTION 2-118

A 44-year-old woman presents with a 6-month history of weight gain, worsening diabetes, and abdominal striae. Plasma adrenocorticotropic hormone (ACTH) and serum cortisol levels are high. Serum cortisol does not suppress after low-dose (1-mg) dexamethasone administration but does suppress after high-dose administration. Pituitary magnetic resonance imaging (MRI) is obtained, and no large masses are appreciated. What is the next step in diagnosis?

(A) 24-hour urine ACTH
(B) Bilateral adrenalectomy
(C) Cosyntropin stimulation test
(D) Inferior petrosal sinus sampling
(E) MRI of the chest, abdomen, and pelvis

۰۲۱-۶۶۱۹۸۵۱۴ www.myuptodate.com دریافت آخرین نسخه آپتودیت آفلاین

QUESTION 2-119

A 35-year-old man with a history of recurrent perianal abscesses presents with feculent drainage from around his anus. On examination under anesthesia, injection of hydrogen peroxide into the tract and insertion of a fistula probe reveals an intersphincteric fistula with the internal opening well below the dentate line. Which of the following would provide the most appropriate repair?

(A) Anal fistula plug

(B) Cutting seton

(C) Endoanal advancement flap

(D) Fibrin glue

(E) Fistulotomy

QUESTION 2-120

A 45-year-old man is seen by his primary care physician for painless swelling at the angle of his left mandible. Biopsy of the lesion reveals a Warthin tumor at the inferior aspect of his parotid gland. Which of the following is the appropriate definitive management and treatment for this tumor based on the pathology of the disease?

(A) Bilateral superficial or conservative parotidectomy followed by bilateral radiation therapy

(B) Simple enucleation, or shelling out, of the tumor on the affected side

(C) Superficial or conservative parotidectomy on the affected side and evaluation of the contralateral side for tumor

(D) Superficial or conservative unilateral parotidectomy on the affected side

(E) Superficial or conservative unilateral parotidectomy on the affected side followed by radiation therapy on the same side

QUESTION 2-121

A 25-year-old man is evaluated 7 days after an open right inguinal hernia repair with mesh. Intraoperatively, the patient had a large hernia sac that required extensive dissection and handling of the spermatic cord. He now reports fevers and 3 days of progressive pain and swelling in his right testicle. He denies dysuria, hematuria, or recent trauma. Physical examination demonstrates a tender, enlarged right testicle without discoloration. Ultrasonography reveals no fluid collection but reduced echogenicity of the right testicle and decreased intratesticular flow on color Doppler. What is the management of this complication?

(A) Emergent orchiectomy

(B) Reassurance, comfort measures, and NSAIDs

(C) Urgent surgical re-exploration to loosen the internal ring

(D) Urgent surgical re-exploration with neurectomy of the ilioinguinal and iliohypogastric nerves

(E) Urgent surgical re-exploration with removal of the mesh

QUESTION 2-122

A 25-year-old male is brought to the emergency department after being stabbed in the left chest. His airway is intact, but his breathing is rapid and shallow. He is tachycardic to 120 beats per minute and hypotensive to 80/40 mm Hg. Left breath sounds are absent. Emergent placement of a left thoracostomy tube is met with a rush of air, and his vital signs improve to a heart rate of 90 beats per minute and blood pressure of 120/70 mm Hg. Which of the following best explains the pathophysiology responsible for these hemodynamic changes?

(A) Constriction of the ventricles by hemopericardium

(B) Decreased delivery of oxygen to the myocardium

(C) Decreased systemic venous return from compression of the vena cava

(D) Increased sympathetic nervous system activity

(E) Massive hemorrhage during transport

۰۲۱-۶۶۱۹۸۵۱۴ www.myuptodate.com دریافت آخرین نسخه آپتودیت آفلاین

QUESTION 2-123

A 50-year-old woman scheduled for parathyroidectomy presents to the emergency department with nausea, vomiting, and altered mental status. Laboratory analysis reveals serum calcium of 16 mg/dL. In addition to IV fluids, the best medication to give immediately would be:

(A) Calcitonin
(B) Furosemide
(C) Mithramycin
(D) Prednisone
(E) Zoledronic acid

QUESTION 2-124

A 43-year-old otherwise healthy man presents with 3 months of progressive dysphagia and regurgitation of solid food several hours after eating. Barium swallow reveals a 3.5-cm pharyngeal diverticulum. Which of the choices below describes the best surgical treatment?

(A) Cricopharyngeal myotomy
(B) Transcervical diverticulectomy and cricopharyngeal myotomy
(C) Transcervical diverticulopexy
(D) Transcervical diverticulopexy and lymph node dissection
(E) Transcervical inversion of the diverticulum

QUESTION 2-125

A 25-year-old G2P2 female presents to the emergency department 1 week after an uncomplicated vaginal delivery with a 1-day history of fever and pelvic pain. Her white blood cell count is 22 × 10^3/μL. An ultrasound reveals a tubular, hypoechoic structure extending from her left adnexa. Which of the following is true concerning this condition?

(A) Complicates 10% to 15% of pregnancies
(B) Intravenous antibiotic therapy and systemic anticoagulation is the treatment of choice
(C) Most commonly affects the left ovarian vein
(D) Pulmonary embolism occurs in less than 1% of cases
(E) Ultrasonographic evaluation is always diagnostic

QUESTION 2-126

Of the following, which is the most common side effect of mycophenolate mofetil (MMF)?

(A) Diarrhea
(B) Gingival hyperplasia
(C) Hyperglycemia
(D) Nephrotoxicity
(E) Tremor

QUESTION 2-127

A 65-year-old female who underwent a low anterior resection 1 day prior develops hypoxia with oxygen saturations of 88% on room air. A chest x-ray is obtained which shows bibasilar atelectasis, and you explain to the patient that she needs to use her incentive spirometer to fully expand the inferior portions of her lungs to avoid alveolar collapse and hypoxia. She complies and with pulmonary toilet her oxygen saturations return to normal levels. What is the normal physiologic response to alveolar hypoxia?

(A) Decreased pulmonary arterial blood flow to the affected alveoli
(B) Increase in overall respiratory rate
(C) Increase in the volume of an inspired breath
(D) Increased oxygen absorption from the affected alveoli
(E) Increased pulmonary arterial blood flow to the affected alveoli

QUESTION 2-128

A thin 55-year-old female underwent a right mastectomy for ductal carcinoma 2 months ago followed by immediate tissue expander-based reconstruction. After receiving a short course of radiation therapy, the tissue expander became exposed and had to be removed. In order to provide more robust coverage, a latissimus dorsi myocutaneous flap was chosen since other flap options were not possible due to the patient's body habitus. What is the blood supply for this flap?

(A) Axillary artery
(B) Dorsal scapular artery
(C) Lateral thoracic artery
(D) Subscapular artery
(E) Thoracodorsal artery

۰۲۱-۶۶۱۹۸۵۱۴ www.myuptodate.com دریافت آخرین نسخه آپتودیت آفلاین

QUESTION 2-129

A 2-month-old boy with no significant past medical history presents with a persistent mass in his right groin. The patient has been febrile, and his mother reports decreased oral intake and no bowel movements over the preceding 48 hours. The child appears very uncomfortable and the mass is not reducible. Imaging shows nondependent gas in the bowel wall, which is trapped within a hernia. What is true of this condition?

(A) After hernia reduction, conservative management with nasogastric tube decompression is typically sufficient

(B) All cases of pneumatosis intestinalis represent a surgical emergency

(C) This is a normal bowel gas pattern found on imaging

(D) This is a surgical emergency requiring immediate attempts at hernia reduction

(E) This is a surgical emergency that may require laparotomy

QUESTION 2-130

A 63-year-old man presents to the emergency room with an exophytic 1.5-cm lesion on the glans of his uncircumcised penis. His physical examination is unremarkable except for the penile lesion; he has no palpable inguinal lymphadenectomy. Biopsy of the lesion reveals a grade 1, T1a squamous cell carcinoma without evidence of vascular, lymphatic, or perineural invasion. Which of the following is the most appropriate treatment strategy?

(A) Partial penectomy (i.e., amputation)

(B) Partial penectomy with superficial inguinal lymphadenectomy

(C) Topical therapy with imiquimod

(D) Wide local excision alone

(E) Wide local excision with sentinel lymph node biopsy

QUESTION 2-131

A 52-year-old male who had a deceased donor renal transplant 6 months ago presents to clinic with a low-grade fever, fatigue, a 4.54-kg (10-lb) weight loss, and a serum creatinine of 2.3 mg/dL, an increase from his baseline post-transplant level of 1.4 mg/dL. Transplant biopsy shows no evidence of acute rejection. Measurement of serum Epstein–Barr virus (EBV) DNA by polymerase chain reaction (PCR) demonstrates a high viral load. The patient will most likely display clinical improvement with the following:

(A) Broad-spectrum intravenous antibiotics

(B) Further increase in immunosuppression

(C) Intravenous ganciclovir

(D) Plasmapheresis

(E) Reduction of immunosuppression

QUESTION 2-132

As a normal newborn transitions from intrauterine to extrauterine life, which of the following occurs?

(A) A contraction of lung volume

(B) A decrease in pulmonary blood flow

(C) A decrease in pulmonary vascular resistance

(D) A decrease in systemic vascular resistance

(E) An increase in pulmonary vascular resistance

QUESTION 2-133

Which of the following is true concerning glucose intolerance in type II diabetes mellitus?

(A) An increase in endogenous glucose production is by itself the causative factor of hyperglycemia in type II diabetes mellitus

(B) Global control of gluconeogenesis is mediated by a cyclic AMP-regulated kinase

(C) Gluconeogenesis occurs solely in the bone marrow

(D) Gluconeogenesis occurs solely in the liver

(E) Glucose-6-phosphate can easily diffuse into and out of cells involved in glucose metabolism

۰۲۱-۶۶۱۹۸۵۱۴ www.myuptodate.com دریافت آخرین نسخه آپتودیت آفلاین

QUESTION 2-134

A 49-year-old man presents with fever, malaise, and right upper quadrant pain. Computed tomography (CT) of the abdomen reveals a rim-enhancing lesion in segment IV of the liver. You determine that the most appropriate course of action is treatment with intravenous piperacillin/tazobactam followed by percutaneous drainage of the liver lesion. The history you are mostly likely to have obtained to direct your clinical management of this patient is which of the following?

(A) History of appendicitis as a child
(B) History of recent travel to Argentina
(C) History of recent travel to Mexico
(D) History of recurrent diverticulitis
(E) Recent development of a maculopapular rash

QUESTION 2-135

A 22-year-old woman is found to have headaches, lethargy, weight gain, amenorrhea, nausea, vomiting, and double vision. She undergoes a magnetic resonance image (MRI) of the head and is found to have a pituitary tumor 2.5 cm in size. Serum prolactin is measured and is found to be mildly elevated to 100 ng/mL. The best possible treatment for this patient will be:

(A) Estrogen treatment
(B) Stereotactic radiation therapy
(C) Surgical resection of the mass through a trans-sphenoidal approach
(D) Treatment with bromocriptine
(E) Treatment with cabergoline

QUESTION 2-136

A 64-year-old woman undergoes an emergent cardiac catheterization for unstable angina. She is given 300 mg of clopidogrel before the procedure; however, the cardiologist is unable to revascularize a near-total obstructing lesion of the left anterior descending artery. The patient is therefore referred for emergent coronary artery bypass grafting. Postoperatively, she has high-volume sanguinous output from her chest tube. The most appropriate treatment for the correction of clopidogrel-associated coagulopathy is:

(A) Administration of cryoprecipitate
(B) Administration of desmopressin
(C) Administration of protamine
(D) Transfusion of fresh frozen plasma
(E) Transfusion of platelets

QUESTION 2-137

A 73-year-old man who underwent a right thyroid lobectomy for a subcentimeter nodule 1 year ago now has persistent hypocalcemia refractory to increasing levels of vitamin D and calcium supplementation. He admits to having little appetite, a poor diet, and heavy alcohol use. On review of his hospital records, his serum calcium immediately postoperatively was normal. Treatment consideration should include:

(A) An appetite stimulant
(B) Diagnostic workup for malabsorption
(C) Magnesium supplementation
(D) Neck exploration to locate residual parathyroid glands
(E) Phosphorus supplementation

QUESTION 2-138

A 49-year-old male with a history of chronic diarrhea is scheduled for a routine colonoscopy. At the time of colonoscopy, a 2-cm multilobulated polyp without ulceration is found in the cecum. Biopsies demonstrate a villous adenoma without dysplasia. The next most appropriate step would be which of the following?

(A) Laparoscopic right hemicolectomy
(B) Laparoscopic total abdominal colectomy
(C) Piecemeal polypectomy
(D) Repeat surveillance in 3 months
(E) Snare polypectomy with complete removal of the polyp

۰۲۱-۶۶۱۹۸۵۱۴ www.myuptodate.com دریافت آخرین نسخه آپتودیت آفلاین

QUESTION 2-139

A 65-year-old man who currently smokes two packs of cigarettes per day presents to clinic with a 0.6-mm ulcerated lesion on the side of his tongue. A biopsy reveals squamous cell carcinoma. After a thorough workup of the lesion, the patient's tumor stage is T1N0M0. What is the most appropriate management of this lesion?

(A) Chemotherapy

(B) Hemiglossectomy

(C) Radiation therapy

(D) Resection of lesion with 1-cm margins

(E) Total glossectomy

QUESTION 2-140

A femoral nerve block is performed in preparation for a total knee arthroplasty in a 55-year-old man. Five minutes after injecting the anesthetic, a large mass has emerged in the groin. What is the next step in the management of this patient?

(A) Apply compression

(B) Exploration of groin

(C) Needle aspiration

(D) Observation

(E) Ultrasound

QUESTION 2-141

A 49-year-old woman with diabetes and chronic renal insufficiency (creatinine 1.5 mg/dL) presents with a serum calcium of 11.4 mg/dL. Parathyroid hormone (PTH) is 70 pg/mL, phosphorus is 1.8 mg/dL, and vitamin D is 35 ng/mL. The next best step is to prescribe:

(A) Calcimimetic

(B) Oral magnesium

(C) Oral phosphate binder

(D) Sestamibi localization scan

(E) Vitamin D supplement

QUESTION 2-142

A 51-year-old woman is admitted with abdominal pain, diarrhea, and hypotension requiring vasopressors. A diagnosis of *Clostridium difficile* colitis is established, and you are consulted for surgical management when her condition fails to improve. Upon exploratory laparotomy, her colon appears to have healthy serosa with a very dilated transverse colon. The next appropriate step in management is:

(A) Colonic lavage with vancomycin and metronidazole without resection

(B) Total abdominal colectomy and end ileostomy

(C) Total abdominal colectomy with ileorectal anastomosis

(D) Transverse colectomy with colostomy leaving a long Hartmann pouch

(E) Transverse colectomy with primary anastomosis

QUESTION 2-143

A 22-year-old male driver in a high-speed collision is brought to the emergency room for evaluation. He is hemodynamically stable, has a Glasgow Coma Scale (GCS) score of 10, and on secondary survey is found to have blood oozing from his urethral meatus. A pelvic x-ray shows a type II pelvic fracture and a computed tomography (CT) cystogram shows extraperitoneal contrast extravasation and a bony fragment in the bladder. How should his bladder rupture be managed?

(A) Insertion of large bore Foley catheter and follow-up cystography in 14 days

(B) Open bladder repair using a posterior approach

(C) Open bladder repair using an anterior, intravesicular approach

(D) Open bladder repair using an anterior, intravesicular approach only if the patient is going to the operating room for laparotomy or internal fixation

(E) Transurethral cystoscopy to remove the bony fragment followed by Foley catheter decompression and a repeat cystogram in 2 weeks

۰۲۱-۶۶۱۹۸۵۱۴ www.myuptodate.com دریافت آخرین نسخه آپتودیت آفلاین

QUESTION 2-144

A 68-year-old man with diabetes mellitus presents with 3 days of progressive pain and swelling of his scrotum. On examination, he has diffuse erythema, edema, and severe tenderness of his scrotum and perineal area. His white blood count is 22,000/mm^3, and his glucose is 284 mg/dL. Ultrasonography was limited because of tenderness but showed increased echogenicity of the skin and subcutaneous tissues. Computed tomography (CT) of the pelvis revealed a markedly enlarged scrotal sac containing foci of gas extending to the perineum and subcutaneous tissues of the gluteal region. The most appropriate next step in management of this disease is:

(A) Aggressive surgical debridement

(B) Application of topical antimicrobial cream

(C) High-dose intravenous steroids

(D) Hyperbaric oxygenation

(E) Observation and serial CT scans

QUESTION 2-145

A 45-year-old man on high-dose oral steroids for ulcerative colitis presents for colectomy due to toxic megacolon. Postoperatively, he is lethargic and suffering from hypotension refractory to fluids and is begun on vasopressors. You wish to perform a diagnostic test for adrenal insufficiency. What is the correct test to evaluate this diagnosis?

(A) 1-mg dexamethasone administration at 11 pm with 8 am cortisol level

(B) 2-mg dexamethasone administration at 11 pm with 8 am cortisol level

(C) Serum adrenocorticotropic hormone (ACTH), 250-μg cosyntropin administration, and repeat serum ACTH at 30 and 60 minutes

(D) Serum cortisol, 1-mg dexamethasone administration, and repeat serum cortisol at 30 and 60 minutes

(E) Serum cortisol, 250-μg cosyntropin administration, and repeat serum cortisol at 30 and 60 minutes

QUESTION 2-146

A 45-year-old man with no significant past medical or surgical history presents to clinic with 6 months of constipation and straining and is found to have full-thickness rectal prolapse on examination. The most durable surgical treatment for this patient is:

(A) Abdominal rectopexy

(B) Abdominal rectopexy and sigmoidectomy

(C) Delorme procedure

(D) Mucosal sleeve resection

(E) Perineal rectosigmoidectomy

QUESTION 2-147

An 82-year-old is admitted from the nursing home with a small bowel obstruction that subsequently fails to resolve with conservative measures. After an exploratory laparotomy and lysis of adhesions, his postoperative course is complicated by a prolonged ileus requiring continued nasogastric decompression. Nine days after surgery, he reports pain and tenderness of his right jaw. He is febrile, and you note minor swelling of his right parotid gland without fluctuance. Which of the following is the most appropriate next step in management?

(A) Anticholinergic medications

(B) Immediate incision and drainage

(C) Initiate intravenous antibiotics

(D) Replace nasogastric tube with orogastric tube

(E) Urgent tracheostomy for airway protection

۰۲۱-۶۶۱۹۸۵۱۴ www.myuptodate.com دریافت آخرین نسخه آپتودیت آفلاین

QUESTION 2-148

A 65-year-old male is given standard prophylactic doses of subcutaneous heparin and intravenous cefotetan prior to a right hemicolectomy and is continued on prophylactic subcutaneous heparin postoperatively. On postoperative day 6, he is noted to have asymmetric left leg swelling, and his platelets haven fallen from 353,000/μL the previous day to 90,000/μL. The next best step is:

(A) Discontinue all heparin products and transfuse platelets

(B) Discontinue all heparin products, send a platelet factor 4 assay, and begin anticoagulation with a direct thrombin inhibitor

(C) Discontinue all medications and proceed with allergy testing

(D) Discontinue all standard heparin and place the patient on low-molecular-weight heparin

(E) Obtain a lower extremity duplex to confirm deep vein thrombosis and begin a heparin drip

QUESTION 2-149

A 37-year-old man has had persistent peptic ulcer disease despite appropriate medical therapy and biopsy-confirmed eradication of *Helicobacter pylori.* Serum gastrin level, measured off acid-suppressing therapy, is 378 pg/mL (normal <100 pg/mL). After a 2 unit/kg dose of intravenous secretin, his gastrin level increases by 452 pg/mL above baseline, confirming the diagnosis of gastrinoma. His past medical history is unremarkable, and his physical examination is noted only for gynecomastia. Which of the following is true with regards to the management of gastrinoma?

(A) If localization cannot be achieved with noninvasive testing, medical management with proton pump inhibitors and octreotide is indicated

(B) If preoperative imaging shows distant metastases, surgery is contraindicated and chemotherapy with streptozocin, 5-fluorouracil, and doxorubicin should be initiated

(C) If the tumor cannot be demonstrated by operative exploration, potential surgical interventions are limited only to partial vagotomy

(D) Preoperative biochemical testing should include measurement of serum calcium to rule out associated disorders

(E) Right upper quadrant ultrasound is the most sensitive localizing modality

QUESTION 2-150

A 46-year-old man with no history of cardiac disease has a myocardial infarction (MI) 5 days prior to his scheduled laparoscopic cholecystectomy for symptomatic cholelithiasis. He undergoes percutaneous angiography with revascularization and bare-metal stent placement and has a favorable outcome with no immediate cardiac complications. Prior to discharge, the medical team would like to know when his cholecystectomy will be performed. Which of the following is the most appropriate plan?

(A) Delay surgery for 1 year

(B) Perform surgery before the patient leaves the hospital

(C) Place a cholecystostomy tube for acute management and plan for a cholecystectomy in 6 weeks

(D) Proceed with the operation as scheduled

(E) Wait at least 6 weeks before performing cholecystectomy

۰۲۱-۶۶۱۹۸۵۱۴ www.myuptodate.com دریافت آخرین نسخه آپتودیت آفلاین

QUESTION 2-151

An 81-year-old female with a history of sun exposure presents to her dermatologist for evaluation of some vascular lesions covered by a thin, red scale on her left hand and arm. Which of the following is true regarding this diagnosis?



Reprinted with permission from: Olasz EB, Neuburg M. Skin disease in transplant patients. In: Hall BJ, Hall JC, eds. *Sauer's Manual of Skin Diseases*. 10th ed. Philadelphia, PA: Lippincott Williams & Wilkins; 2010:467.

(A) Lesions can be diagnosed as frank squamous cell carcinoma based on the clinical appearance of thickness, redness, and ulceration

(B) Lesions typically extend beyond the epidermis

(C) Surgical management is the treatment of choice for isolated, superficial lesions

(D) These lesions are more common in patients with a history of transplantation

(E) These lesions are uniformly benign

QUESTION 2-152

A 45-year-old gentleman with past medical history significant for hepatitis C with end-stage cirrhosis and ascites is admitted to the intensive care unit with pneumonia. On morning rounds, the patient's serum sodium is 128 mEq/L without encephalopathy or mental status changes. The most appropriate next step is to:

(A) Administer a vasopressin antagonist

(B) Correct serum sodium to normal range at a rate of 20 mEq/L in the first 24 hours.

(C) Immediately initiate hypertonic saline fluid bolus followed by aggressive diuresis once a normal serum level has been reached

(D) No intervention is warranted as the patient is asymptomatic

(E) Perform a therapeutic paracentesis to help correct the dilutional hyponatremia

QUESTION 2-153

Breast enlargement in men (gynecomastia) is caused by excess action of:

(A) Androgens

(B) Estrogens

(C) Follicle-stimulating hormone (FSH)

(D) Luteinizing hormone (LH)

(E) Oxytocin

QUESTION 2-154

A 46-year-old man presents with dysphagia, halitosis, and regurgitation. When reviewing his fluoroscopic swallow study, the area of highest likelihood for a suspected upper esophageal diverticulum is:

(A) Between the circular and longitudinal muscle layers of the upper esophagus

(B) Between the cricopharyngeus muscle and the longitudinal muscle of the upper esophagus

(C) Between the thyropharyngeus and the cricopharyngeus muscles

(D) Distal to the cricopharyngeus muscle

(E) Proximal to the inferior pharyngeal constrictor muscle

۰۲۱-۶۶۱۹۸۵۱۴ www.myuptodate.com دریافت آخرین نسخه آپتودیت آفلاین

QUESTION 2-155

A 36-year-old woman with a history of multiple ileal resections presents to the emergency room with acute onset of flank pain. She is restless and diaphoretic on arrival. Except for tachycardia, her vital signs are unremarkable. You suspect a diagnosis of urolithiasis. What is the most likely pathophysiologic mechanism leading to this diagnosis?

(A) Hypercalciuria
(B) Hyperoxaluria
(C) Hyperuricosuria
(D) Low fluid intake
(E) Type I renal tubular acidosis

QUESTION 2-156

A 37-year-old woman with an otherwise unremarkable medical history undergoes an elective laparoscopic cholecystectomy for symptomatic cholelithiasis. Her preoperative blood pressure is 135/82 mm Hg and her pulse is 75 beats per minute. In the operating room, a combination of propofol, fentanyl, and mivacurium are used for induction, and sevoflurane is used for maintenance of anesthesia. After confirming the position of the Veress needle, the abdomen is insufflated with carbon dioxide gas at a flow of 15 L/min. Suddenly, the patient's pulse drops to 42 beats per minute. Repeat blood pressure is 82/45 mm Hg, and her end-tidal carbon dioxide level remains unchanged. The most appropriate next step is:

(A) Administration of 0.5 mg of intravenous physostigmine
(B) Administration of 4 mg of intravenous atropine
(C) Administration of a 500 mL bolus of normal saline
(D) Reduction of gas flow to 5 L/min and observation
(E) Release of abdominal insufflation

QUESTION 2-157

A 68-year-old woman is started on long-term total parenteral nutrition (TPN) via a subclavian central line She is noted to have a catheter-related clot in her superior vena cava. She is immediately started on warfarin and upon re-imaging 2 days later due to increased facial swelling, it is noted that the clot is even larger. Warfarin's inhibition of which pair of factors is most likely responsible for this scenario?

(A) Factors V and VI
(B) Factors V and VIII
(C) Factors XI and XII
(D) Protein C and factor V
(E) Proteins C and S

QUESTION 2-158

A 48-year-old male with a history of hypertension poorly controlled with several agents presents to his primary care physician for regular follow-up. He complains of persistent headaches, waking up several times throughout the night to urinate, and fatigue that increases throughout the day. A computed tomography (CT) scan shows a right-sided 1.3-cm retroperitoneal mass. His serum potassium level is 2.8 mmol/L. What other findings are consistent with this disease?

(A) 24-hour urine aldosterone levels <14 μg after saline loading
(B) Enhanced ability of the kidney to produce concentrated urine
(C) Neutral to alkaline urinary pH
(D) Serum pH <7.25
(E) Symptomatic hypernatremia

۰۲۱-۶۶۱۹۸۵۱۴ www.myuptodate.com دریافت آخرین نسخه آپتودیت آفلاین

QUESTION 2-159

A 54-year-old woman with body mass index of 35 is postoperative day 5 from a right hemicolectomy for colon adenocarcinoma. She suddenly develops tachycardia, acute chest pain, and shortness of breath. She is most likely to manifest which of the following hemodynamic changes?

	Cardiac Output	Vascular Resistance	Myocardial Oxygen Consumption	Right Heart Filling Pressure
(A)	⇓	⇓	⇔	⇓
(B)	⇑	⇓	⇑	⇔
(C)	⇓	⇑	⇑	⇑
(D)	⇓	⇑	⇓	⇓
(E)	⇓	⇑	⇓	⇑

QUESTION 2-160

For a patient who is suspected of having a symptomatic Meckel diverticulum, which of the following tests is most sensitive and specific for the diagnosis?

(A) Abdominal ultrasound

(B) Magnetic resonance imaging (MRI)

(C) Standard computed tomography (CT) of the abdomen and pelvis with oral contrast

(D) Technetium scan

(E) Upper gastrointestinal series with small bowel follow-through

QUESTION 2-161

A 62-year-old woman of Asian descent is seen in clinic for a 2-week history of a dry, hacking cough. She was recently diagnosed with hypertension and has been sequentially started on a multidrug regimen including metoprolol, lisinopril, amlodipine, and clonidine. Increased levels of which of the following is thought to contribute to the dry, hacking cough caused by one of these medications?

(A) Angiotensin I

(B) Angiotensin II

(C) Angiotensinogen

(D) Bradykinin

(E) Renin

QUESTION 2-162

A 54-year-old female with a history of hypercholesterolemia and hypertension presents to the emergency room with new onset substernal chest pain. Her vital signs are within normal limits. An electrocardiogram shows ST-segment elevation in the anterolateral leads, and laboratory evaluation demonstrates an elevated troponin level. She receives an aspirin, beta-blocker, and sublingual nitroglycerin. Oxygen is given via nasal cannula, and morphine is administered for pain control. What is the best next step in the management of this patient?

(A) Cardiac catheterization

(B) Coronary artery bypass graft

(C) Echocardiogram

(D) Repeat EKG in 2 hours

(E) Systemic administration of a thrombolytic agent

QUESTION 2-163

A 54-year-old man undergoes major abdominal surgery, and his diet is advanced on the first postoperative day when bowel sounds are heard. The following morning, the patient has a large amount of emesis and a distended abdomen and reports abdominal pain. A plain abdominal radiograph shows a diffuse pattern of air throughout the entire digestive tract. Why is the patient having emesis with positive bowel sounds?

(A) It is an effect of anesthesia so he should continue to be fed as this episode is unlikely to recur

(B) The colon recovers motility before the small intestine

(C) The colon recovers motility before the stomach

(D) The small intestine recovers motility before the colon or stomach

(E) The stomach recovers motility before the small intestine

۰۲۱-۶۶۱۹۸۵۱۴ www.myuptodate.com دریافت آخرین نسخه آپتودیت آفلاین

QUESTION 2-164

A 78-year-old woman admitted to the hospital after an uneventful laparoscopic cholecystectomy is given oxycodone for pain control. She continues to complain of pain overnight and is given multiple doses of hydromorphone to help her rest. The surgical team finds her lethargic in the morning and notes a respiratory rate of 8 breaths per minute. Which of the following is true of the opioid antagonist that should be given to this patient?

(A) A continuous infusion should never be used

(B) A slow onset of action is expected

(C) Severe pain can result with its use

(D) The drug provides selective reversal of respiratory depression without reversing other opioid effects

(E) The medication is a mixed agonist–antagonist at opioid receptors

QUESTION 2-165

A 26-year-old female presents with increased liver function tests that were drawn after a computed tomography (CT) scan of the abdomen revealed a 2-cm mass in the right lobe of the liver. The mass is further evaluated with a sulfur colloid scan that reveals a cold nodule. The sulfur colloid scan is most helpful when needing to distinguish between which two entities?

(A) Focal nodular hyperplasia and hemangioma

(B) Focal nodular hyperplasia and hepatic metastases from distant sites

(C) Hepatic adenoma and focal nodular hyperplasia

(D) Hepatic adenoma and hemangioma

(E) Hepatic adenoma and hepatic abscess

QUESTION 2-166

A 45-year-old female is being evaluated for a pancreatic cystic neoplasm. History reveals heavy menses and prolonged bleeding after childbirth, and on laboratory analysis she has an isolated prolonged partial thromboplastin time (PTT). Upon further questioning she states that she has a family member with Type I von Willebrand disease. What is the most appropriate treatment for this patient before undergoing a major operation to remove her pancreatic mass?

(A) Administration of high-dose IVIG prior to surgery, followed by treatment with desmopressin (DDAVP) thereafter

(B) Intravenous or intranasal DDAVP at the time of surgery

(C) No need for treatment as long as the patient is clinically stable and if laboratory monitoring of von Willebrand factor (vWF) is normal

(D) Treatment with Factor VIII: vWF concentrate with close monitoring of vWF ristocetin cofactor activity levels

(E) Treatment with fresh frozen plasma and close monitoring of PTT and bleeding time

QUESTION 2-167

An 80-year-old woman comes to the emergency room with a 2-day history of moderate bleeding per rectum and has a bloody bowel movement upon presentation. She is hemodynamically stable, and a nasogastric tube aspirate returns bile and no blood. Which diagnostic test should be performed next?

(A) Angiography

(B) Capsule endoscopy

(C) Colonoscopy

(D) Meckel scan

(E) Tagged red blood cell scan

۰۲۱-۶۶۱۹۸۵۱۴ www.myuptodate.com دریافت آخرین نسخه آپتودیت آفلاین

QUESTION 2-168

A 45-year-old woman with no history of trauma or bleeding disorders presents with a 4-month history of a slow-growing mass in her left buttock. A nontender, immobile mass is palpated in the left buttock; no palpable lymphadenopathy is present. Laboratory values are within normal limits, and computed tomography (CT) and magnetic resonance imaging (MRI) show a large intramuscular mass measuring 14 × 13 × 12 cm in the gluteus maximus, with heterogeneous contrast enhancement. A core-needle biopsy reveals a high-grade malignant fibrous histiocytoma. The most appropriate next step for adequate staging of this malignancy is:

(A) Bone scan

(B) CT of the abdomen and pelvis

(C) CT of the chest

(D) CT of the head

(E) No further tests for staging are necessary

QUESTION 2-169

A 64-year-old man with a history of diabetes mellitus and hypertension presents to the emergency department complaining of sudden severe chest pain after a night of heavy drinking complete with multiple episodes of vomiting and retching. He denies hematemesis or hemoptysis. An electrocardiogram displays sinus tachycardia with no signs of ischemia, and a chest radiograph reveals a pneumomediastinum and a small left-sided pleural effusion. What is the definitive study that should be ordered to confirm a diagnosis in this patient?

(A) Computed tomography (CT) scan of the chest and abdomen

(B) Echocardiogram

(C) Esophagogram

(D) Flexible bronchoscopy

(E) Serum troponin level

QUESTION 2-170

You evaluate a 42-year-old patient who presents to you 6 months after a complex abdominal operation that resulted in a prolonged open abdomen that was left to granulate in over a piece of synthetic absorbable mesh, with a resultant abdominal wall hernia. He now presents for definitive repair of his large ventral hernia. You decide that he is a good candidate for a ventral hernia repair with component separation. What are the key steps to this repair?

(A) Excise the mesh, free the rectus sheath and the aponeurosis of the external oblique, separate the entire rectus muscle from its lateral attachment, repair the fascia, and place mesh bilaterally over the lateral external oblique defects

(B) Excise the mesh, raise large subcutaneous flaps, and primarily close the fascia

(C) Excise the mesh, raise large subcutaneous flaps, free the rectus sheath and the aponeurosis of the external oblique, perform a lateral relaxing incision in the external oblique, and then primarily close the fascia

(D) Excise the mesh, separate the retromuscular space, and place an underlay and overlay mesh

(E) Overlay mesh over the prior repair after raising large subcutaneous flaps

QUESTION 2-171

An 89-year-old female is brought into the Emergency Department with a second episode of "enlarged belly" and not passing stool for 2 days. Upon examination, the patient has baseline dementia, the abdomen is markedly distended and tympanic, and there is involuntary guarding with rebound tenderness. Abdominal radiograph reveals a classic "bent inner tube" sign. What is the best management?

(A) Go to the operating room for sigmoidectomy

(B) Go to the operating room for total abdominal colectomy

(C) Perform a sigmoidoscopy and leave a rectal tube in place

(D) Place a nasogastric tube and follow the patient with serial abdominal radiographs

(E) Proceed with a barium enema to confirm the diagnosis

۰۲۱-۶۶۱۹۸۵۱۴ www.myuptodate.com دریافت آخرین نسخه آپتودیت آفلاین

QUESTION 2-172

A 65-year-old man is referred to you for management of a recurrent, reducible left-sided inguinal hernia. He initially underwent an open Lichtenstein repair 3 years ago. He has a history of coronary artery disease, myocardial infarction, severe chronic obstructive pulmonary disease (COPD), and prostate cancer treated with a radical retropubic prostatectomy and radiation 2 years ago. He takes low-dose aspirin, a beta-blocker, and a statin. What should you tell him regarding the choice between open and laparoscopic repair of his recurrent inguinal hernia?

(A) His cardiopulmonary disease makes the laparoscopic approach preferable

(B) His hernia should be repaired laparoscopically because of his previous prostatectomy

(C) His hernia should be repaired open because it is recurrent

(D) His hernia should be repaired open because of his history of pelvic radiation

(E) His use of aspirin is a contraindication to laparoscopic repair

QUESTION 2-173

A 72-year-old man develops sudden, sharp pain in his abdomen and starts feeling weak with a racing heart rate. He is brought to the Emergency Department where upright and supine abdominal radiographs reveal air under the diaphragm. If this patient is found to have a perforated peptic ulcer, which clinical entity must be addressed after surgery?

(A) Bacterial overgrowth of the stomach and duodenum

(B) *Campylobacter jejuni* infection

(C) *Helicobacter pylori* infection

(D) Level of activity and exercise

(E) Malnutrition

QUESTION 2-174

According to the Milan criteria, which of the following must be true for a patient with hepatocellular carcinoma (HCC) to be a candidate for liver transplantation?

(A) If three tumors are present, they all have to be 3 cm or less in diameter

(B) If a single tumor is present, it has to be larger than 5 cm in diameter

(C) If a single tumor is present, it has to be smaller than 8 cm in diameter

(D) If multiple tumors are present, the total tumor diameter should not exceed 8 cm

(E) If multiple tumors are present, they all must be in the same lobe

QUESTION 2-175

The majority of uptake of small peptides (dipeptides and tripeptides), as opposed to single amino acids, occurs in which part of the digestive tract?

(A) Colon

(B) Duodenum

(C) Ileum

(D) Jejunum

(E) Stomach

QUESTION 2-176

An 11-year-old girl was riding a horse when she was thrown approximately 2.44 m (8 ft). She was reported to have lost consciousness and was not ambulatory at the scene. Upon arrival, vital signs are now a pulse of 58 beats per minute, blood pressure of 81/47 mm Hg, and respiratory rate of 18 breaths per minute. Physical examination is notable for a laceration over the left temple, tenderness to palpation over C6, and 2/5 strength in all four extremities. Which of the following is the most appropriate next step in management?

(A) Give atropine

(B) Initiate dobutamine drip

(C) Initiate dopamine drip

(D) Initiate phenylephrine drip

(E) Provide crystalloid bolus

۰۲۱-۶۶۱۹۸۵۱۴ www.myuptodate.com دریافت آخرین نسخه آپتودیت آفلاین

QUESTION 2-177

A 56-year-old woman with known peptic ulcer disease is rushed to the operating room for massive upper gastrointestinal bleeding found to be originating from an ulcer situated near the gastroesophageal junction on the lesser curvature of the stomach. During the operation, she will also need:

(A) Gastroduodenal artery ligation

(B) Highly selective vagotomy

(C) Selective vagotomy

(D) Truncal vagotomy

(E) Ulcer resection only

QUESTION 2-178

An 87-year-old woman presents with 2 days of lower abdominal pain, nausea, and emesis. She is tachycardic but afebrile with a normal white blood cell count. Her abdomen is soft but mildly tender. Extension and medial rotation of her right leg produces pain in the right medial thigh. After resuscitation, the most likely operative intervention required for this patient is:

(A) Inguinal approach for repair of incarcerated femoral hernia

(B) Laparoscopic appendectomy for acute appendicitis

(C) Laparotomy for repair of incarcerated femoral hernia

(D) Laparotomy for repair of incarcerated obturator hernia

(E) Laparotomy for repair of incarcerated sciatic hernia

QUESTION 2-179

A 65-year-old man presents for follow-up after an uneventful left hemicolectomy for stage IIA colon cancer. Which of the following is true regarding surveillance for recurrence of colorectal cancer?

(A) Follow-up colonoscopies are recommended to detect anastomotic recurrences and metachronous lesions

(B) Intense surveillance programs may decrease morbidity but provide no survival benefit

(C) Measurement of carcinoembryonic antigen (CEA) is not recommended

(D) Measurement of liver function tests must be included in surveillance

(E) Routine computed tomography (CT) is not recommended

QUESTION 2-180

A 75-year-old male undergoes a right upper lobectomy for squamous cell cancer of the lung. His postoperative course is complicated by prolonged intubation secondary to his underlying chronic obstructive pulmonary disease. The intensive care team would like to begin nutrition due to the patient's poor nutritional status. Which of the following is true concerning options for feeding this patient?

(A) Early enteral nutrition is associated with an increased duration of mechanical ventilation

(B) Glutamine supplementation has been proven to decrease mortality in the critically ill

(C) In recent trials, late parenteral nutrition has been associated with fewer complications in comparison with early parenteral feeding

(D) Postpyloric enteral feedings are preferred to gastric feedings in regards to overall nutrition and complications

(E) Supplementing enteral nutrition with parenteral support to ensure adequate caloric intake is *not* advocated

QUESTION 2-181

A 35-year-old male with no significant medical history presents with a 1-month history of postprandial epigastric pain and a 4.54-kg (10-lb) weight loss. He undergoes esophagogastroduodenoscopy, which demonstrates a large ulcer within the fundus of the stomach. If this is a benign gastric ulcer, which of the following findings would you expect on biopsy?

(A) Intestinalization of the gastric mucosa

(B) Polymorphic neutrophils surrounding spiral-shaped organisms

(C) Mucin-rich vacuoles within the cell apices

(D) Poorly demarcated border

(E) Signet ring cells

۰۲۱-۶۶۱۹۸۵۱۴ www.myuptodate.com دریافت آخرین نسخه آپتودیت آفلاین

QUESTION 2-182

Failure of the processus vaginalis to obliterate during embryologic development can lead to which of the following?

(A) Communicating hydrocele

(B) Hydrocele of the cord

(C) Indirect inguinal hernia

(D) Scrotal hydrocele

(E) All of the above

QUESTION 2-183

Calcium-based urinary stones are typically seen with which of the following conditions?

(A) Cystinuria

(B) Gout

(C) Myeloproliferative disorders

(D) *Proteus* colonization or infection of the genitourinary tract

(E) Sarcoidosis

QUESTION 2-184

A 68-year-old man was found to have a 6.2-cm infrarenal abdominal aortic aneurysm (AAA) on computed tomography (CT) and underwent an elective open AAA repair. His postoperative course was unremarkable until postoperative day 3 when his vital signs reveal a pulse of 128 beats per minute, blood pressure of 89/45 mm Hg, and oxygen saturation of 95% on room air. Physical examination is notable for an increasingly distended abdomen, and the nurse notes that the patient had an episode of bloody bowel movement earlier in the day. What is the most likely etiology of shock in this patient?

(A) Bleeding from the proximal graft anastomosis

(B) Bleeding from unrecognized injury to a retroaortic renal vein

(C) Rupture of a pseudoaneurysm at the graft site

(D) Sepsis from graft infection

(E) Sepsis from sigmoid colon ischemia

QUESTION 2-185

Which of the following is a step in the biosynthesis of conjugated bilirubin?

(A) Bacterial β-glucuronidases assist with active transport of bilirubin into bile canaliculi

(B) Bilirubin reductase conjugates bilirubin to glucuronic acid

(C) Ferroprotoporphyrin IX (heme) is broken down into biliverdin, iron, and carbon monoxide

(D) Microsomal heme oxygenase converts bilirubin into biliverdin

(E) Uridine diphosphate-glucuronosyltransferase (UDPGT) hydrolyzes conjugated bilirubin and forms urobilinogens, which are mostly excreted

QUESTION 2-186

An otherwise healthy, physically active 45-year-old woman is referred to you for management of a 1.5-cm pulmonary carcinoid tumor emanating from the right upper lobe bronchus. The tumor is obstructing the orifice of the right upper lobe bronchus without involvement of the right mainstem bronchus or the bronchus intermedius. No nodal enlargement was seen on computed tomography (CT) of the chest. Which of the following management options is most appropriate?

(A) Neoadjuvant chemoradiation

(B) Right carinal pneumonectomy with mediastinal lymph node sampling

(C) Right pneumonectomy with mediastinal lymph node sampling

(D) Right upper lobe sleeve resection with tumor-free margins and mediastinal lymph node sampling

(E) Right upper lobectomy with mediastinal lymph node sampling

۰۲۱-۶۶۱۹۸۵۱۴ www.myuptodate.com دریافت آخرین نسخه آپتودیت آفلاین

QUESTION 2-187

A patient with cirrhosis is undergoing evaluation for a solitary 3-cm mass suspicious for hepatocellular carcinoma based on imaging. Preoperative measurement of the portal venous pressure reveals a portal–systemic pressure gradient of 11 mm Hg with preserved liver synthetic function, no ascites, and no encephalopathy. The best choice for management should be:

(A) The patient should be followed with repeat abdominal imaging in 3 months

(B) The patient should be started on sorafenib therapy

(C) The patient should undergo liver transplantation

(D) The patient should undergo nonanatomic liver resection

(E) The patient should undergo radiofrequency ablation

QUESTION 2-188

A 76-year-old man is on systemic anticoagulation with low-molecular-weight heparin (LMWH) for a recently diagnosed deep venous thrombosis. He has presented twice to the emergency department in the past week with epistaxis that requires nasal packing for hemostasis. Today he returns to the emergency room after falling down the steps to his front door. A thorough examination reveals no injuries. What is the most appropriate management of his anticoagulation moving forward?

(A) Check weekly activated partial thromboplastin time (aPTT) and adjust LMWH dose accordingly

(B) Check weekly plasma anti-Factor Xa levels and adjust LMWH dose accordingly

(C) Convert to unfractionated heparin

(D) Convert to warfarin

(E) Stop anticoagulation and arrange for placement of an inferior vena cava (IVC) filter

QUESTION 2-189

Your patient is concerned that her coronary artery disease may be caused by elevated levels of homocysteine. Treatment with which of the following can help lower plasma homocysteine levels?

(A) Cysteine

(B) Phosphate

(C) Vitamin B1

(D) Vitamin B12

(E) Vitamin B3

QUESTION 2-190

During laparoscopic inguinal hernia repair, which nerve is most likely to be injured by tacking of the mesh?

(A) Femoral nerve

(B) Ilioinguinal nerve

(C) Iliohypogastric nerve

(D) Lateral femoral cutaneous nerve

(E) Obturator nerve

QUESTION 2-191

The site of intrinsic factor production and secretion in the stomach is:

(A) Antrum, by chief cells

(B) Antrum, by enteroendocrine cells

(C) Cardia, by mucous neck cells

(D) Fundus, by mucous neck cells

(E) Fundus, by parietal cells

QUESTION 2-192

A 45-year-old woman with ulcerative colitis undergoes a laparoscopic total proctocolectomy with ileal pouch and anal anastomosis. It is a technically challenging procedure, and the total operating time is 14 hours. The following morning, the patient complains of pain, numbness, and weakness on the lateral aspect of the left foot and leg. The most likely diagnosis is:

(A) Common peroneal nerve injury

(B) Compartment syndrome

(C) Femoral nerve injury

(D) Lateral femoral cutaneous nerve injury

(E) Sciatic nerve injury

۰۲۱-۶۶۱۹۸۵۱۴ www.myuptodate.com دریافت آخرین نسخه آپتودیت آفلاین

QUESTION 2-193

In preparation for a right lobe hepatectomy as part of a living donor liver transplantation, a potential living donor undergoes magnetic resonance imaging to evaluate the biliary tree. He is found to have the most common hepatic duct aberration, which is:

(A) A "triple confluence" made up of the right anterior, right posterior, and left hepatic ducts

(B) An accessory right posterior hepatic duct that drains into the common hepatic duct

(C) Anomalous drainage of the right posterior duct into the common hepatic duct

(D) The right posterior duct drains into the left hepatic duct

(E) The right posterior duct empties into the left aspect of the right anterior duct

QUESTION 2-194

A neurologist is called to the intensive care unit and asked to evaluate a patient for brain death. Which of the following is true regarding the clinical examination and confirmatory studies for brain death?

(A) A positive apnea test occurs when oxygen saturation drops below 85% after adequate preoxygenation

(B) Ancillary tests such as electroencephalography (EEG) can be used in place of the physical examination to diagnose brain death when performing the neurologic examination proves to be exceedingly difficult

(C) Brain death statutes are standardized across all 50 states in the US.

(D) Brainstem reflexes but not spinal reflexes must be absent to confirm brain death

(E) The patient must not be under the effect of paralytic drugs but can be well sedated during the brain death examination

QUESTION 2-195

Which of the following is a Surgical Care Improvement Project measure?

(A) Discontinuing prophylactic antibiotics 48 hours after a noncardiac surgery

(B) Receiving prophylactic antibiotics immediately after the time of incision

(C) Recording a temperature of at least 35°C (95°F) 30 minutes prior to or 15 minutes after "Anesthesia End Time"

(D) Removing the urinary catheter by postoperative day 2

(E) Shaving a patient the night before surgery

QUESTION 2-196

A 45-year-old man is referred to your clinic with a 2-month history of a pigmented skin lesion on his upper back. The lesion is dark and raised with irregular borders and 9 mm diameter. He has no palpable lymphadenopathy and no evidence of in-transit or satellite metastases. Punch biopsy of the lesion reveals melanoma with 2.3 mm thickness, two mitotic figures per mm^2, and no ulceration. Preoperative lymph node mapping with lymphoscintigraphy identifies a sentinel lymph node in the left axilla. You perform a wide excision with 2-cm margins and a sentinel lymph node biopsy. The result of the lymph node biopsy is positive for cancer. The most appropriate next step is:

(A) Axillary lymphadenectomy levels I and II

(B) Axillary lymphadenectomy levels I and II combined with radiation therapy

(C) Axillary lymphadenectomy levels I, II, and III

(D) Chemotherapy, followed by axillary lymphadenectomy

(E) Radiation therapy, followed by axillary lymphadenectomy

۰۲۱-۶۶۱۹۸۵۱۴ www.myuptodate.com دریافت آخرین نسخه آپتودیت آفلاین

QUESTION 2-197

Two days after starting warfarin as embolic prophylaxis for atrial fibrillation, a 67-year-old woman presents to the emergency room with a 3-cm black patch of sloughing skin on her left buttock. Her international normalized ratio (INR) is 1.2, and her partial thromboplastin time (PTT) is 34 seconds. What is the appropriate management?

(A) Continue warfarin and start wet-to-dry management of buttock wound

(B) Discontinue warfarin, administer intravenous vitamin K, and start topical antibiotics to buttock

(C) Increase dose of warfarin to achieve INR of 2.5 and sharply debride wound on buttock

(D) Initiate heparin infusion, discontinue warfarin, and full-thickness skin graft wound on buttock

(E) Obtain computed tomography (CT) scan of abdomen and pelvis, start subcutaneous low-molecular-weight heparin injection of 100 mg BID, and start broad-spectrum antibiotics

QUESTION 2-198

A 26-year-old man suffers multiple gun shot wounds to his abdomen. He is left with an open abdomen after an exploratory laparotomy reveals multiple small bowel injuries and a massive liver injury controlled with abdominal packing. Over the course of the next week, he returns to the operating room twice for abdominal washouts. He remains critically ill and continues to require vasopressors for hemodynamic support. Which statement is correct regarding the use of antifungal agents in this patient?

(A) Antifungal prophylaxis is proven to decrease his risk of mortality

(B) Antifungal prophylaxis will not decrease his risk of fungal infection

(C) Antifungal treatment should be used only in the setting of positive fungal blood cultures

(D) Fluconazole may be inadequate treatment for infection with some Candida species

(E) He should be provided intravenous micafungin for prophylaxis

QUESTION 2-199

A 29-year-old man presents with an enlarging testicular mass first noticed 10 days ago. He denies fever or constitutional symptoms. He has no history of urinary tract infection, epididymitis, inguinal hernia, or sexually transmitted disease and no family history of testicular or other genitourinary cancer. On examination, the right testis contains a 3-cm firm and nontender mass. An ultrasound reveals a mass concerning for testicular cancer. Which of the following tests is necessary for adequate initial staging?

(A) Abdominal magnetic resonance imaging (MRI)

(B) Bone scan

(C) Liver ultrasound

(D) Positron emission tomography–computed tomography (PET–CT)

(E) Serum markers

QUESTION 2-200

Which of the following represents a rational approach to total parenteral nutrition (TPN) in surgical patients with acute renal failure?

(A) Lipids should be removed from the TPN formulation to avoid n-6 fatty acids that stimulate inflammatory mediators

(B) Multivitamins should be eliminated from the solution to avoid build-up of toxic levels of vitamins A, D, E, and K

(C) Potassium should be minimized or eliminated to avoid hyperkalemia

(D) Proteins should be minimized in formulations for patients on continuous venovenous hemodialysis (CVVHD) to reduce the risk of uremia

(E) Sodium should be given in high concentration to maximize serum osmolarity and avoid edema associated with renal failure

۰۲۱-۶۶۱۹۸۵۱۴ www.myuptodate.com دریافت آخرین نسخه آپتودیت آفلاین

QUESTION 2-201

A 42-year-old 60-kg woman has developed short gut syndrome after having undergone numerous small bowel resections. She requires total parenteral nutrition (TPN) due to malabsorption. In preparing the initial TPN order, the most appropriate number of total calories to provide would be:

(A) 1,200 kcal

(B) 1,500 kcal

(C) 2,400 kcal

(D) 3,000 kcal

(E) Cannot be calculated without determining total protein requirements

QUESTION 2-202

Which of the following amino acids has been clinically proven to improve immunologic function?

(A) Alanine

(B) Glutamine

(C) Leucine

(D) Proline

(E) Valine

QUESTION 2-203

A 52-year-old female patient presents with nausea, vomiting, abdominal distension, and abdominal pain. She has not passed flatus during this time and describes her pain as intermittent, dull, and diffusely generalized across her abdomen. The most likely origin and path for her abdominal pain is:

(A) Referred pain to abdominal striated musculature

(B) Somatic pain via autonomic nerves

(C) Somatic pain via spinal nerves

(D) Visceral pain via autonomic nerves

(E) Visceral pain via spinal nerves

QUESTION 2-204

A 55-year-old man is currently undergoing chemotherapy for metastatic renal cell carcinoma. He is admitted to the hospital from the outpatient chemotherapy ward after sustained hypotension and tachycardia. Which of the following chemotherapeutic agents used for renal cell carcinoma is most likely to blame?

(A) Bevacizumab

(B) Cisplatin

(C) IL-2

(D) Sorafenib

(E) Sunitinib

QUESTION 2-205

A prospective clinical trial examining the benefit of a new drug is halted because several patients have experienced an adverse event while enrolled in the study. An adverse event is best defined as which of the following?

(A) A complication associated with a particular therapy that occurs in at least three patients

(B) An outcome that contradicts a study's underlying hypothesis

(C) Any unwanted experience associated with a medication, device, procedure, or other aspect of medical care

(D) Any unwanted outcome that does not result in a death

(E) Death or hospitalization during the trial period

QUESTION 2-206

Which of the following would be best analyzed using an unpaired t-test?

(A) A comparison of height in a group of pediatric patients with short gut syndrome to the average height for their age group

(B) A comparison of postoperative bilirubin levels in two different groups of hepatectomy patients, one of which has data that are not normally distributed

(C) A comparison of pre- and postoperative weight in a single group of bariatric patients

(D) A comparison of serum albumin levels taken serially in two groups of patients with ARDS over multiple time points

(E) A comparison of white blood cell counts in two different groups of patients on postoperative day 3 following splenectomy

۰۲۱-۶۶۱۹۸۵۱۴ www.myuptodate.com دریافت آخرین نسخه آپتودیت آفلاین

QUESTION 2-207

A 40-year-old male patient is undergoing a two-stage operation to be performed over 2 days. After the first operation, the patient remains intubated and is taken to the surgical intensive care unit for postoperative management. The anesthesiologist states that the patient did not have reversal of his neuromuscular blockade. The longest period of neuromuscular blockade would be expected with which of the following agents?

(A) Mivacurium
(B) Pancuronium
(C) Rocuronium
(D) Succinylcholine
(E) Vecuronium

QUESTION 2-208

A surgery resident is interested in studying pancreatic sarcomas. She wants to estimate the relative odds of the association between a putative risk factor and this rare disease. What is the most appropriate and efficient study for this research question?

(A) Cross-sectional survey
(B) Prospective cohort study
(C) Randomized clinical trial
(D) Retrospective case-control study
(E) Retrospective observational study

QUESTION 2-209

A 68-year-old male patient is being treated for relapsing nonHodgkin lymphoma. He is started on a monoclonal antibody by his medical oncologist. Which agent was likely used?

(A) Chimeric antibody that targets EGFR
(B) Chimeric IgG1 anti-CD20 antibody
(C) Humanized antibody against CD52
(D) Humanized antibody against VEGF
(E) Humanized IgG1 that targets the her2/neu antigen

QUESTION 2-210

A 74-year-old male patient underwent a pancreaticoduodenectomy for pancreatic adenocarcinoma. His postoperative course was complicated by a large leak at his pancreaticojejunostomy. The patient developed septic shock and subsequently died of multiorgan failure. If immunohistochemical analysis were performed 1 hour after death, which of the following cells would likely be decreased?

(A) B cells
(B) CD8 T cells
(C) Macrophages
(D) Monocytes
(E) Natural Killer (NK) cells

QUESTION 2-211

A retrospective study of 50 patients was performed to evaluate total hospital charges after laparoscopic versus open pancreaticoduodenectomy. The distribution of charges was generally symmetric, but two patients in the open group had a significantly prolonged hospital stay and therefore had total hospital charges that were extremely high. Which of the following statistical measures will likely be affected most for the open group?

(A) 25th percentile
(B) Interquartile range
(C) Mean
(D) Median
(E) Mode

QUESTION 2-212

Which of the following represents the most potent opioid dose?

(A) 2 mg of hydromorphone
(B) 30 mg of morphine
(C) 5 μg of sufentanil
(D) 5 mg of methadone
(E) 50 μg of fentanyl

۰۲۱-۶۶۱۹۸۵۱۴ www.myuptodate.com دریافت آخرین نسخه آپتودیت آفلاین

QUESTION 2-213

A 28-year-old male is taken to the operating room for an elective inguinal hernia repair. During preoperative evaluation, he is noted to have Type I von Willebrand disease. Which of the following is true regarding this scenario?

(A) Desmopressin (DDAVP) is ineffective for this condition

(B) Platelet aggregation response to ristocetin will be abnormal

(C) The disease is inherited in an autosomal recessive fashion

(D) The disease results in qualitatively abnormal von Willebrand factor

(E) The patient should be given cryoprecipitate and platelets prior to incision

QUESTION 2-214

As you are closing the incision on a patient with von Willebrand disease, your astute medical student notices that the patient's wound surfaces are especially oozy. He asks how von Willebrand disease leads to excessive bleeding. You tell him that the functional von Willebrand protein is important for which of the following?

(A) Activation of phosphatidylinositol diphosphate pathway

(B) Adherence of platelets to subendothelial collagen

(C) Aggregation of platelets via fibrinogen

(D) Localized vasoconstriction

(E) Platelet activation and release of granule contents

QUESTION 2-215

A 28-year-old woman who is 22 weeks pregnant presents to the emergency room after a motor vehicle accident and reports mild abdominal pain. A Kleihauer–Betke test suggests the present of fetomaternal hemorrhage (FMH). Which of the following treatments should be considered?

(A) Betamethasone

(B) Immediate delivery

(C) Magnesium

(D) Oxytocin

(E) Rh immune globulin (RhoGAM)

QUESTION 2-216

A 55-year-old man with an extensive history of tobacco smoking and alcohol abuse is postoperative day 14 from a pancreatic necrosectomy for infected pancreatic necrosis. He has been maintained on total parenteral nutrition and is having trouble weaning off the ventilator. Indirect calorimetry demonstrates a respiratory quotient of 1.2. What can be done to assist his ventilator weaning?

(A) Decrease caloric intake and carbohydrates

(B) Decrease protein intake and increase carbohydrates

(C) Increase caloric intake and carbohydrates

(D) Increase fat intake and increase carbohydrates

(E) Increase protein intake and decrease carbohydrates

QUESTION 2-217

A 45-year-old man with a left wrist fracture that was repaired 6 months ago reports developing pain in his left hand a few weeks after the surgery. On examination, his left wrist and hand are exquisitely tender to palpation. The skin is thickened and has a brown discoloration. X-ray of the left hand shows focal osteoporosis. The treatment that has been shown to be LEAST effective in the management of this disease is:

(A) Intranasal calcitonin

(B) Intravenous bisphosphonates

(C) Intravenous regional analgesia

(D) Oral vitamin C

(E) Sympathetic nerve blocks

۰۲۱-۶۶۱۹۸۵۱۴ www.myuptodate.com دریافت آخرین نسخه آپتودیت آفلاین

QUESTION 2-218

A 27-year-old man presents to the emergency room reporting severe pain in his right index finger. On examination of the finger, the patient has edema, erythema, fluctuance, and tenderness in the soft tissue surrounding the fingernail. The erythema spreads proximally into his middle phalanx. Which of the following is the most appropriate management of this acute paronychia?

(A) Bilateral, longitudinal incisions of the hyponychium to decompress the infection

(B) Drill through the nail with a sterile heated instrument to decompress the infection

(C) Extended course of oral antibiotics alone

(D) Remove a strip of nail to decompress the infection

(E) Warm soaks and elevation alone

QUESTION 2-219

A 50-year-old male is of status post deceased donor renal transplant for diabetic nephropathy. He is found to have a markedly reduced tacrolimus level despite having no change in his regular dose. The cause of his decreased level is most likely due to which recent change in his medication history?

(A) Treatment of a fungal infection with fluconazole

(B) Treatment of *Clostridium difficile* infection with metronidazole

(C) Treatment of gastroparesis with metoclopramide

(D) Treatment of hypertension with diltiazem

(E) Treatment of new-onset seizure disorder with phenytoin

QUESTION 2-220

A 35-year-old woman presents after a high-speed motor vehicle accident in which there was significant intrusion into her side of the car, the windshield was broken, and she required a prolonged extrication time due to her legs being crushed beneath the dashboard. Upon arrival, the patient makes incomprehensible sounds, does not open her eyes, and withdraws to painful stimuli. A dilated right pupil is noted. Which of the following is the most appropriate muscle relaxant to use when intubating this patient?

(A) Glycopyrrolate

(B) Neostigmine

(C) Pancuronium

(D) Succinylcholine

(E) Vecuronium

QUESTION 2-221

A new screening test is implemented for prostate cancer. It has a sensitivity of 92% and a specificity of 90%. If a patient has prostate cancer, what is the probability that the patient will test negative?

(A) 8%

(B) 10%

(C) 90%

(D) 92%

(E) 97%

QUESTION 2-222

When combined with ampicillin, sulbactam exerts a synergistic antimicrobial effect. How does sulbactam help extend the spectrum of activity of ampicillin?

(A) Inhibits beta-lactamase

(B) Inhibits cell wall synthesis

(C) Inhibits dihydrofolate reductase

(D) Inhibits DNA gyrase

(E) Inhibits protein synthesis

۰۲۱-۶۶۱۹۸۵۱۴ www.myuptodate.com دریافت آخرین نسخه آپتودیت آفلاین

QUESTION 2-223

A 42-year-old male with a 20% total body surface area full-thickness burn across his back and chest is treated with Sulfamylon. Use of this drug places him at risk for which of the following acid–base disturbances?

(A) Metabolic acidosis

(B) Metabolic acidosis and respiratory alkalosis

(C) Metabolic alkalosis

(D) Respiratory acidosis

(E) Respiratory alkalosis

QUESTION 2-224

A 67-year-old woman was given 5 mg of midazolam in divided doses for sedation while undergoing an esophagoscopy. Which of the following is true regarding this medication?

(A) Hypertension is a common side effect

(B) It has strong analgesic properties

(C) It provides long-acting sedation

(D) Its effects are mediated through GABA receptors

(E) Its effects are quickly reversed with naloxone

QUESTION 2-225

A 3-week-old boy with no past medical history presents to your clinic with nonbilious, projectile vomiting for the last 4 days. Upon physical examination, a mass is palpated in the upper abdomen. You inform the family that their child has pyloric stenosis and that a pyloromyotomy is the surgical treatment of choice. What electrolyte and acid–base derangement is most likely present?

(A) Hyperchloremic, hypokalemic metabolic acidosis

(B) Hyperchloremic, hypokalemic metabolic alkalosis

(C) Hypochloremic, hyperkalemic metabolic acidosis

(D) Hypochloremic, hypokalemic metabolic acidosis

(E) Hypochloremic, hypokalemic metabolic alkalosis

۰۲۱-۶۶۱۹۸۵۱۴ www.myuptodate.com دریافت آخرین نسخه آپتودیت آفلاین

دریافت آخرین نسخه آپتودیت آفلاین www.myuptodate.com ۰۲۱-۶۶۱۹۸۵۱۴

ANSWER KEY FOR PRACTICE EXAMINATION 2

The answer key lists the correct answer choice by letter, with the explanation number.

B = Body as a Whole

G = Gastrointestinal

C = Cardiovascular and Respiratory

M = Miscellaneous (Genitourinary, Head and Neck, Skin, Muscle, and Nervous System)

E = Endocrine, Hematic, Lymphatic, and Breast

۰۲۱-۶۶۱۹۸۵۱۴ www.myuptodate.com دریافت آخرین نسخه آپتودیت آفلاین

Question Number	Correct Answer	Explanation Number	Question Number	Correct Answer	Explanation Number	Question Number	Correct Answer	Explanation Number
2-1	D	2B01	2-26	D	2B06	2-51	E	2B11
2-2	B	2C01	2-27	A	2C06	2-52	D	2C11
2-3	A	2E01	2-28	C	2E06	2-53	B	2E11
2-4	A	2G01	2-29	A	2G06	2-54	B	2G11
2-5	E	2M01	2-30	D	2M06	2-55	A	2M11
2-6	B	2B02	2-31	D	2B07	2-56	E	2B12
2-7	E	2C02	2-32	A	2C07	2-57	C	2C12
2-8	D	2E02	2-33	A	2E07	2-58	D	2E12
2-9	A	2G02	2-34	E	2G07	2-59	D	2G12
2-10	A	2M02	2-35	E	2M07	2-60	C	2M12
2-11	B	2B03	2-36	A	2B08	2-61	C	2B13
2-12	A	2C03	2-37	D	2C08	2-62	A	2C13
2-13	D	2E03	2-38	C	2E08	2-63	B	2E13
2-14	D	2G03	2-39	C	2G08	2-64	D	2G13
2-15	C	2M03	2-40	A	2M08	2-65	C	2M13
2-16	A	2B04	2-41	D	2B09	2-66	D	2B14
2-17	A	2C04	2-42	B	2C09	2-67	E	2C14
2-18	E	2E04	2-43	C	2E09	2-68	C	2E14
2-19	C	2G04	2-44	C	2G09	2-69	E	2G14
2-20	E	2M04	2-45	E	2M09	2-70	B	2M14
2-21	E	2B05	2-46	D	2B10	2-71	D	2B15
2-22	E	2C05	2-47	A	2C10	2-72	C	2C15
2-23	A	2E05	2-48	C	2E10	2-73	E	2E15
2-24	D	2G05	2-49	D	2G10	2-74	A	2G15
2-25	A	2M05	2-50	E	2M10	2-75	A	2M15

۰۲۱-۶۶۱۹۸۵۱۴ www.myuptodate.com دریافت آخرین نسخه آپتودیت آفلاین

Question Number	Correct Answer	Explanation Number
2-76	C	2B16
2-77	B	2C16
2-78	B	2E16
2-79	B	2G16
2-80	A	2M16
2-81	D	2B17
2-82	B	2C17
2-83	C	2E17
2-84	D	2G17
2-85	C	2M17
2-86	E	2B18
2-87	B	2C18
2-88	D	2E18
2-89	E	2G18
2-90	D	2M18
2-91	E	2B19
2-92	C	2C19
2-93	E	2E19
2-94	D	2G19
2-95	C	2M19
2-96	A	2B20
2-97	C	2C20
2-98	C	2E20
2-99	B	2G20
2-100	B	2M20
2-101	C	2B21
2-102	B	2C21
2-103	B	2E21
2-104	E	2G21
2-105	D	2M21
2-106	C	2B22
2-107	E	2C22
2-108	C	2E22
2-109	E	2G22
2-110	D	2M22
2-111	C	2B23
2-112	D	2C23
2-113	A	2E23
2-114	A	2G23
2-115	B	2M23
2-116	B	2B24
2-117	D	2C24
2-118	D	2E24
2-119	E	2G24
2-120	C	2M24
2-121	B	2B25
2-122	C	2C25
2-123	B	2E25
2-124	B	2G25
2-125	B	2M25
2-126	A	2B26
2-127	A	2C26
2-128	E	2E26
2-129	E	2G26
2-130	D	2M26
2-131	E	2B27
2-132	C	2C27
2-133	B	2E27
2-134	D	2G27
2-135	C	2M27
2-136	E	2B28
2-137	C	2E28
2-138	E	2G28
2-139	D	2M28
2-140	A	2B29
2-141	D	2E29
2-142	B	2G29
2-143	C	2M29
2-144	A	2B30
2-145	E	2E30
2-146	B	2G30
2-147	C	2M30
2-148	B	2B31
2-149	D	2E31
2-150	E	2G31

۰۲۱-۶۶۱۹۸۵۱۴ www.myuptodate.com دریافت آخرین نسخه آپتودیت آفلاین

Question Number	Correct Answer	Explanation Number
2-151	D	2M31
2-152	D	2B32
2-153	B	2E32
2-154	C	2G32
2-155	B	2M32
2-156	E	2B33
2-157	E	2G33
2-158	C	2M33
2-159	E	2B34
2-160	D	2G34
2-161	D	2M34
2-162	A	2B35
2-163	D	2G35
2-164	C	2B36
2-165	C	2G36
2-166	D	2B37
2-167	C	2G37
2-168	C	2B38
2-169	C	2G38
2-170	C	2B39
2-171	A	2G39
2-172	D	2B40
2-173	C	2G40
2-174	A	2B41
2-175	D	2G41
2-176	E	2B42
2-177	E	2G42
2-178	D	2B43
2-179	A	2G43
2-180	C	2B44
2-181	B	2G44
2-182	E	2B45
2-183	E	2G45
2-184	E	2B46
2-185	C	2G46
2-186	D	2B47
2-187	E	2G47
2-188	E	2B48
2-189	D	2G48
2-190	D	2B49
2-191	E	2G49
2-192	A	2B50
2-193	D	2G50
2-194	D	2B51
2-195	D	2B52
2-196	C	2B53
2-197	D	2B54
2-198	D	2B55
2-199	E	2B56
2-200	C	2B57
2-201	B	2B58
2-202	B	2B59
2-203	D	2B60
2-204	C	2B61
2-205	C	2B62
2-206	E	2B63
2-207	B	2B64
2-208	D	2B65
2-209	B	2B66
2-210	A	2B67
2-211	C	2B68
2-212	B	2B69
2-213	B	2B70
2-214	B	2B71
2-215	E	2B72
2-216	A	2B73
2-217	C	2B74
2-218	D	2B75
2-219	E	2B76
2-220	E	2B77
2-221	A	2B78
2-222	A	2B79
2-223	A	2B80
2-224	D	2B81
2-225	E	2B82

۰۲۱-۶۶۱۹۸۵۱۴ www.myuptodate.com دریافت آخرین نسخه آپتودیت آفلاین

IV
QUESTIONS WITH ANSWERS AND EXPLANATIONS FOR PRACTICE EXAMINATION 2

۰۲۱-۶۶۱۹۸۵۱۴ www.myuptodate.com دریافت آخرین نسخه آپتودیت آفلاین

دریافت آخرین نسخه آپتودیت آفلاین www.myuptodate.com ۰۲۱-۶۶۱۹۸۵۱۴

1
BODY AS A WHOLE

CONTENTS:

Number:	Key Word:	Page:
2B01	Adjuvant Treatment of Colon Cancer	316
2B02	Antibiotic Prophylaxis of Surgical Site Infection	318
2B03	Characteristics of Early Excision of 40% Total Body Surface Area Burns	319
2B04	Characteristics of Epidural Analgesia	319
2B05	Immunosuppressant Side Effects	320
2B06	Characteristics of Necrotizing Soft Tissue Infections	321
2B07	Characterization of Process Measures	322
2B08	Definition of Active and Latent Error	323
2B09	Diagnosis of Incarcerated Femoral Hernia	323
2B10	Diagnosis of Paradoxic Aciduria	324
2B11	Diagnosis of Refeeding Syndrome	325
2B12	Diagnosis of Syndrome of Inappropriate Antidiuretic Hormone	326
2B13	Diagnosis of Vitamin K Deficiency	327
2B14	Effect of Use of Iodine Drapes	328
2B15	Effect of Use of Isolation Gowns	328
2B16	Etiology of Grand Mal Seizure after Lidocaine Administration	329
2B17	Etiology of Hypotension after Blunt Trauma	329
2B18	Etiology of Paresthesias after Thyroid Surgery	330
2B19	Extrapyramidal Effects of Antiemetics	331
2B20	Fluid Requirement with 30% TBSA Flame Burn	332
2B21	Hair Removal in Contaminated Laceration Repair	332
2B22	Hemodynamic Findings in Septic Shock	333
2B23	Indication for Antibiotics with 40% TBSA Burns	333
2B24	Effective Pain Control	334
2B25	Initial Treatment of Ischemic Orchitis after Hernia Repair	334
2B26	Most Common Side Effect of Mycophenolate	335
2B27	Risks of Long-term Immunosuppression	336
2B28	Treatment of Bleeding Associated with Clopidogrel	336
2B29	Treatment of Complications of Femoral Nerve Block	337
2B30	Treatment of Fournier Gangrene	338
2B31	Treatment of Heparin-induced Thrombocytopenia	339

۰۲۱-۶۶۱۹۸۵۱۴ www.myuptodate.com دریافت آخرین نسخه آپتودیت آفلاین

Number:	Key Word:	Page:
2B32	Treatment of Hyponatremia in Cirrhosis	340
2B33	Treatment of Intraoperative Bradycardia	341
2B34	Hemodynamics of Massive Pulmonary Embolism	342
2B35	Treatment of Myocardial Infarction	342
2B36	Treatment of Oxycodone Toxicity	343
2B37	Treatment of von Willebrand Disease	343
2B38	Staging of Soft Tissue Sarcoma	344
2B39	Technique of Component Separation for Ventral Hernia Repair	347
2B40	Contraindications to Laparoscopic Inguinal Hernia Repair	349
2B41	Criteria for Liver Transplantation in Patients with Hepatocellular Carcinoma	350
2B42	Treatment of Neurogenic Shock in a Quadriplegic	351
2B43	Treatment of Obturator Hernias	352
2B44	Early Initiation of Enteral versus Parenteral Nutrition	353
2B45	Embryology of Indirect Hernias	354
2B46	Etiology of Shock after Aneurysm Repair	354
2B47	Treatment of Tumor of the Bronchus	355
2B48	Monitoring Treatment of Low-molecular-weight Heparin	356
2B49	Nerve Injury During Laparoscopic Inguinal Hernia Repair	357
2B50	Nerve Injuries Associated with Lithotomy Positioning	358
2B51	Neurologic Findings Associated with Brain Death	358
2B52	Process Measures of SCIP	359
2B53	Sentinel Lymph Node Biopsy for Melanoma	360
2B54	Treatment of Warfarin-induced Skin Necrosis	362
2B55	Sources of Postoperative Intra-abdominal Infection	363
2B56	Staging of Testicular Germ Cell Tumors	364
2B57	TPN Component Adjusted in Renal Insufficiency	365
2B58	Adult Caloric Supply for TPN	366
2B59	Amino Acid which Enhances Immune Function	367
2B60	Comparison of Somatic and Visceral Pain	367
2B61	Cytokine Treatment of Renal Cell Carcinoma	368
2B62	Definition of Adverse Event	368
2B63	Design of T-tests	369
2B64	Function Recovery Postneuromuscular Block	369
2B65	Major Limitations of Retrospective Clinical Studies	370
2B66	Major Modification of Tumor Cell Response	370
2B67	Molecules which Mediate Leukocytosis in Inflammation	371
2B68	Most Representative Descriptive Statistic	371

۰۲۱-۶۶۱۹۸۵۱۴ www.myuptodate.com دریافت آخرین نسخه آپتودیت آفلاین

Number:	Key Word:	Page:
2B69	Narcotic with Greatest Potency	372
2B70	Platelet Adherence after Tissue Injury	372
2B71	Prompt Formation of Platelet Plug	373
2B72	Patient at Risk of Alloimmune Response Postabdominal Trauma	374
2B73	Respiratory Quotient of Fatty Acid Synthesis	375
2B74	Treatment of Reflex Sympathetic Dystrophy	375
2B75	Treatment of Acute Paronychia	376
2B76	Components Needed for Tacrolimus Absorption	377
2B77	Characteristics of General Anesthesia	378
2B78	Sensitivity and Specificity of Screening Tests	379
2B79	Synergism of Ampicillin and Sulbactam	379
2B80	Acid–Base Disturbances with Sulfamylon Treatment	380
2B81	Common Effects of Benzodiazepines	380
2B82	Electrolyte Abnormalities Associated with Pyloric Stenosis	381

۰۲۱-۶۶۱۹۸۵۱۴ www.myuptodate.com دریافت آخرین نسخه آپتودیت آفلاین

2B01

Key word: Adjuvant Treatment of Colon Cancer

Author: Ibrahim Sultan, MD
Editor: Elizabeth C. Wick, MD

A 60-year-old man undergoes a right hemicolectomy for colon adenocarcinoma. The pathology revealed a tumor with negative microscopic margins, well-differentiated histology, and 10 lymph nodes in the specimen. He was found to have a stage II (T2N0M0) tumor. Which of the following characteristics place him at a higher risk, thus making him a potential candidate for adjuvant therapy?

(A) Age

(B) Highly differentiated histology

(C) Location of the tumor

(D) Number of sampled lymph nodes

(E) T2 lesion

Answer: (D) Number of sampled lymph nodes

Rationale:
Adjuvant therapy is typically reserved for patients with stage III colon adenocarcinoma. The advantage of adjuvant therapy for patients with node negative disease has not been clearly proven, but there may be a survival advantage of 2% to 5% in 5 years for certain groups of patients. Specific characteristics of stage II or node negative patients that may indicate a benefit with adjuvant therapy include T4 lesions, inadequate nodal sampling (<12), lymphovascular invasion, poorly differentiated histology, and bowel perforation.

Staging of Colorectal Cancer[a]

Stage	Description
Tumor-Node-Metastasis (TNM) System	
Primary Tumor	
TX	Primary tumor cannot be assessed
T0	No evidence of tumor in resected specimen (prior polypectomy or fulguration)
Tis	Carcinoma in situ
T1	Invades into submucosa
T2	Invades into muscularis propria
T3/T4	Depends on whether serosa is present
Serosa Present	
T3	Invades through muscularis propria into subserosa; invades serosa (but not through); invades pericolic fat within the leaves of the mesentery
T4	Invades through serosa into free peritoneal cavity or through serosa into a contiguous organ
NP Serosa (distal two thirds of rectum, posterior left or right colon)	
T3	Invades through muscularis propria
T4	Invades other organs (vagina, prostate, ureter, kidney)
Regional Lymph	**Node Involvement**
NX	Nodes cannot be assessed (e.g., local excision only)
N0	No regional node metastases
N1	1–3 positive nodes
N2	4 or more positive nodes
N3	Central nodes positive
Distant Metastasis	
MX	Presence of distant metastases cannot be assessed
M0	No distant metastases
M1	Distant metastases present

Stage	Description		
0	Tis	N0	M0
I	T1,2	N0	M0
IIA	T3	N0	M0
IIB	T4	N0	M0
IIIA	T1,2	N1	M0
IIIB	T3,4	N1	M0
IIIC	Any T	N2	M0
IV	Any T	Any N	M1

۰۲۱-۶۶۱۹۸۵۱۴ www.myuptodate.com دریافت آخرین نسخه آپتودیت آفلاین

Staging of Colorectal Cancer[a] (*Continued*)

Stage	Description
Dukes Staging System Correlated with TNM System	
Dukes A	T1, N0, M0 (stage I)
	T2, N0, M0 (stage I)
Dukes B	T3, N0, M0 (stage II)
	T4, N0, M0 (stage II)
Dukes C	T (any), N1, M0; T (any), N2, M0 (stage III)
Dukes D	T (any), N (any), M1 (stage IV)
Modified Astler-Coller (MAC) System Correlated with TNM System	
MAC A	T1, N0, M0 (stage I)
MAC B1	T2, N0, M0 (stage I)
MAC B2	T3, N0, M0 (stage II)
MAC B3	T4, N0, M0 (stage II)
MAC C1	T2, N1, M0; T2, N2, M0 (stage III)
MAC C2	T3, N1, M0; T3, N2, M0 (stage III)
	T4, N1, M0; T4, N2, M0 (stage III)
MAC C3	T4, N1, M0; T4, N2, M0 (stage III)

[a]In all pathologic staging systems, particularly those applied to rectal cancer, the abbreviations m and g may be used; m denotes microscopic transmural penetration; g or m + g denotes transmural penetration visible on gross inspection and confirmed microscopically.

Reprinted with permission from: Morris A. Colorectal cancer. In: Mulholland MW, Lillemoe KD, Doherty GM, Maier RV, Simeone DM, Upchurch GR, Jr, eds. *Greenfield's Surgery: Scientific Principles & Practice*. 5th ed. Philadelphia, PA: Lippincott Williams & Wilkins; 2011:1106.

References:

Compton C, Hawk E, Grochow L, et al. Colon cancer. In: Abeloff MD, Armitage JO, Niederhuber JE, Kastan MB, McKenna WG, eds. *Abeloff's Clinical Oncology.* 4th ed. Philadelphia, PA: Churchill Livingstone Elsevier; 2008: 1477–1524.

Morris A. Colorectal cancer. In: Mulholland MW, Lillemoe KD, Doherty GM, Maier RV, Simeone DM, Upchurch GR, eds. *Greenfield's Surgery: Scientific Principles and Practice.* 5th ed. Philadelphia, PA: Lippincott Williams and Wilkins; 2011.

Saltz LB. Adjuvant therapy for colon cancer. *Surg Onc Clin N Am.* 2010;19:819–827.

۰۲۱-۶۶۱۹۸۵۱۴ www.myuptodate.com دریافت آخرین نسخه آپتودیت آفلاین

2B02

Key word: Antibiotic Prophylaxis of Surgical Site Infection

Author: Joshua C. Grimm, MD
Editor: Elizabeth C. Wick, MD

A 65-year-old male is undergoing an elective left inguinal hernia repair. With regard to his risk of surgical site infection, which of the following is true?

(A) A surgical site infection is defined as one occurring within 60 days of the procedure or within 6 months if an implant is left in place

(B) Administration of most preoperative antibiotics should be within 1 hour of incision

(C) Antibiotics are given postoperatively because there is documented proof that they decrease the risk of surgical site infection after wound closure

(D) If the procedure necessitates drain placement, studies have shown a decrease in infection rates if antibiotics are continued until they are removed

(E) Routine use of vancomycin for antibiotic prophylaxis is recommended

Answer: (B) Administration of most preoperative antibiotics should be within 1 hour of incision.

Rationale:

In order to curb the increasing prevalence of surgical site infections, the Surgical Care Improvement Project (SCIP) was designed and implemented. It outlines six infection prevention measures, including the timing of preoperative antibiotic administration, duration of therapy, and appropriate selection depending on the case type to ensure adequate coverage. Most antibiotics should be given within 1 hour of incision (vancomycin and some fluoroquinolones being the exception due to prolonged infusion times). A surgical site infection is defined as an infection occurring within 30 days of the procedure date or within 1 year if an implant is left in place. The antibiotic chosen should cover the most likely infective agent encountered during the given operation but need not cover every potential pathogen. Preoperative antibiotics should be used in every clean–contaminated procedure and selectively in clean procedures. Routine use of vancomycin is not recommended, but it can be implemented in patients with beta-lactam allergy or in institutions with a preponderance of methicillin-resistant *Staphylococcus aureus.* There is no benefit in prolongation of antibiotic therapy for greater than 24 hours after the procedure. Some cardiothoracic surgeons advocate antibiotic use for 48 hours due to the impact of cardiopulmonary bypass on immune modulation and pharmacokinetics, however. While some surgeons continue antibiotics until surgical drains are removed, there is no evidence to support such actions on the basis of decreasing wound infections, and this practice should not be continued.

References:

Bosco JA 3rd, Slover JD, Haas JP. Perioperative strategies for decreasing infection: a comprehensive evidence-based approach. *J Bone Joint Surg Am.* 2010;92(1):232–239.

Edwards FH, Engelman RM, Houck P, et al. The Society of Thoracic Surgeons practice guideline series: antibiotic prophylaxis in cardiac surgery, part I: duration. *Ann Thorac Surg.* 2006;81(1):397–404.

Horan TC, Gaynes RP, Martone WJ, et al. CDC definitions of nosocomial surgical site infections, 1992: a modification of CDC definitions of surgical wound infections. *Infect Control Hosp Epidemiol.* 1992;13(10):606–608.

Mangram AJ, Horan TC, Pearson ML, et al. Guideline for prevention of surgical site infection, 1999. Hospital Infection Control Practices Advisory Committee. *Infect Control Hosp Epidemiol.* 1999;20(4):250–278.

۰۲۱-۶۶۱۹۸۵۱۴ www.myuptodate.com دریافت آخرین نسخه آپتودیت آفلاین

2B03

Key word: Characteristics of Early Excision of 40% Total Body Surface Area Burns

Author: Joshua C. Grimm, MD
Editor: Pamela A. Lipsett, MD, MHPE, FACS, FCCM

A 27-year-old man was injured in a chemical plant explosion and presented to the hospital with burns covering over 50% of his total body surface area (TBSA). Early excision is planned. Which of the following statements is true concerning his condition?

(A) Early excision of burns prolongs the inflammatory phase of healing

(B) Early excision of burns results in a decreased risk of infection

(C) Hypertrophic scarring is a complication of early excision

(D) Early excision should occur in one procedure in extensive burns (>40% TBSA)

(E) With improved burn care, infection no longer carries significant morbidity

Answer: (B) Early excision of burns results in a decreased risk of infection

Rationale:

Early surgical excision and grafting of burns has been an ongoing area of focus and debate. Until recently, however, the morbidity and mortality associated with early excision created a surgical dilemma. Advances in the care of critically ill burn patients in the intensive care unit setting have now afforded surgeons the ability to undertake early, aggressive treatment in burn injuries.

Burn wound excision should occur within the first few days of the injury and results in improved survival. The goals of this strategy are to reduce the period of inflammation (which results in greater function and improved cosmetic result by decreasing the incidence of hypertrophic scaring) and to diminish the risk of infection (which carries a significant morbidity). Despite these benefits, several studies have demonstrated reduced complications when less than 20% of burned surfaces are removed in a single procedure. Therefore, large body surface area burns should be excised with serial procedures.

References:

Barret JP, Herndon DN. Modulation of inflammatory and catabolic responses in severely burned children by early burn wound excision in the first 24 hours. *Arch Surg.* 2003;138:127–132.

Deitch EA, Wheelahan TM, Rose MP, et al. Hypertrophic burn scars: analysis of variables. *J Trauma.* 1983;23:895–898.

Engrav LH, Heimbach DM, Reus JL, Harnar TJ, et al. Early excision and grafting vs. nonoperative treatment of burns of indeterminate depth: a randomized prospective study. *J Trauma.* 1983;23:1001–1004.

2B04

Key word: Characteristics of Epidural Analgesia

Author: Brenessa M. Lindeman, MD
Editor: Asad Latif, MBBS, MPH

Which of the following is most likely to occur with use of local anesthetics administered via an epidural catheter for pain control following thoracic surgery?

(A) Regional vasodilation

(B) Renal toxicity

(C) Respiratory depression

(D) Temporary leg weakness

(E) Urinary retention

Answer: (A) Regional vasodilation

Rationale:

Epidural catheters are a method of regional anesthesia and utilize local anesthetic agents either alone or in combination with other drugs such as opioids. Autonomic nerves are the most sensitive to the effects of local anesthetics, followed by sensory nerves and then, motor nerves. This sensitivity pattern can lead to loss of sympathetic vasomotor tone and subsequently hypotension, particularly in dehydrated or hemodynamically unstable patients. Epidural catheters are intended to provide analgesia only to the body region where an operation is performed. With a thoracic epidural, the coverage area of the block does not routinely extend to the lumbar spine. This coverage means that urinary retention and leg weakness should not occur, unlike when an epidural catheter is placed in the lumbar region. Renal toxicity and muscle tremors are not associated with epidural anesthesia. Respiratory depression is possible when opioids are also administered via the epidural catheter, although this side effect is infrequent given the relatively small doses of opioid that are typically used.

Reference:

Catterall WA, Mackie K. Local anesthetics. In: Brunton LL, Chabner BA, Knollmann BC, eds. *Goodman & Gilman's Pharmacologic Basis of Therapeutics.* 12th ed. New York, NY: McGraw-Hill; 2011. http://www.accessanesthesiology.com/content/16665256. Accessed May 20, 2013.

۰۲۱-۶۶۱۹۸۵۱۴ www.myuptodate.com دریافت آخرین نسخه آپتودیت آفلاین

2B05

Key word: Immunosuppressant Side Effects

Author: Isaac Howley, MD
Editor: Andrew M. Cameron, MD, PhD

A 59-year-old male presents to clinic 2 years after a deceased donor kidney transplant for diabetic nephropathy. His creatinine is now 1.7 mg/dL, up from a stable baseline of 1.1 mg/dL following his transplant. His blood glucose levels have been well controlled, with HbA_{1c} of 6.2%. You perform a percutaneous core-needle biopsy, which shows no evidence of rejection. Which of the following immunosuppression medications is most likely contributing to this patient's increasing renal insufficiency?

(A) Azathioprine

(B) Mycophenolate mofetil (MMF)

(C) Prednisone

(D) Sirolimus

(E) Tacrolimus

Answer: **(E)** Tacrolimus

Rationale:

All immunosuppressive agents currently in use have clinically significant side effects. Medications differ both in their mechanisms of action, side effect profiles, and drug interactions. Most patients following abdominal organ transplantation require a three-drug maintenance regimen, most typically consisting of a corticosteroid (prednisone), an antiproliferative agent (azathioprine or MMF), and a T-cell directed immunosuppressant (tacrolimus, cyclosporine, or sirolimus). Determining the most appropriate immunosuppressive regimen for a given patient is contingent on a balance of these factors.

Glucocorticoids such as prednisone work through inhibiting macrophage and T-cell cytokine production, inhibiting macrophage activation, and suppressing prostaglandin synthesis. Side effects may be significant and include hypertension, hyperglycemia, truncal obesity, mood lability, cataract formation, pancreatitis, and osteoporosis.

MMF is perhaps the least toxic of the standard immunosuppressant medications. It interferes with purine metabolism and therefore with lymphocyte proliferation. It may cause leukopenia, but the most common side effect is diarrhea, which may be mitigated by administering the drug in divided doses or in enteric-coated formulations. Azathioprine is a purine analogue that has essentially been supplanted by MMF due to its improved efficacy. Azathioprine may cause leukopenia and hepatic insufficiency.

Tacrolimus and sirolimus inhibit the production of IL-2 via binding to FK binding protein, which then blocks the phosphatase activity of calcineurin, an upstream regulator of IL-2 transcription. These medications therefore have potent antilymphocyte activity without affecting other cell lines. Tacrolimus is associated with alopecia, post-transplant diabetes, hypertension, nephrotoxicity, and neurotoxicity. Compared to tacrolimus, sirolimus causes less significant nephrotoxicity, although it may cause hypertriglyceridemia, proteinuria, thrombocytopenia, anemia, and profound impairment of wound healing.

Reference:

Granger DK, Ildstad ST. Transplantation immunology and immunosuppression. In: Townsend CM, Beauchamp RD, Evers BM, Mattox KL, eds. *Sabiston Textbook of Surgery.* 18th ed. Philadelphia, PA: Saunders Elsevier; 2008:655–691.

۰۲۱-۶۶۱۹۸۵۱۴ www.myuptodate.com دریافت آخرین نسخه آپتودیت آفلاین

2B06

Key word: Characteristics of Necrotizing Soft Tissue Infections

Author: Robert A. Meguid, MD, MPH
Editor: Pamela A. Lipsett, MD, MHPE, FACS, FCCM

A 34-year-old HIV-positive man presents with a swollen, erythematous, and painful left forearm. He reports that the redness began after injecting heroin into his left hand web spaces 2 days prior. On examination, the skin overlying his arm is blistered, he is unable to flex his hand or wrist, and you palpate crepitus along his forearm. Which of the following is true regarding these types of infections?

(A) Antibiotic therapy is the primary management modality

(B) *Clostridium perfringens* is the most frequently cultured organism in necrotizing soft tissue infections

(C) Group A β-hemolytic *Streptococcus* is more common than *Clostridium perfringens* in monomicrobial infections

(D) Most necrotizing soft tissue infections are polymicrobial

(E) Surgical debridement should be performed 48 hours after presentation to provide adequate interval for response to antibiotics

Answer: **(D)** Most necrotizing soft tissue infections are polymicrobial

Rationale:

Immunocompromised patients are more susceptible to necrotizing soft tissue infections than the general population. Approximately 75% of necrotizing soft tissue infections are due to polymicrobial infections, with the most frequently cultured species of organisms being Streptococcus and Bacteroides. However, in cases in which a single pathogen is cultured (monomicrobial infections), anaerobic bacteria (such as Clostridium species) are more commonly identified than aerobic bacteria.

Patients often present with a recent history of an identifiable inoculation with microorganisms, such as intravenous drug administration, trauma, cutaneous infections, or insect bites. Characteristic findings on physical examination include erythema, tenderness, tense edema, bullae, crepitus, and skin necrosis. Liquefactive necrosis of the fascia and adjacent soft tissue produces a characteristic dish-water–like drainage. Patients may rapidly progress to septic shock.

Treatment relies on early diagnosis based on a high index of suspicion for necrotizing soft tissue infection. In addition to administration of broad-spectrum antibiotics, surgical debridement should be performed immediately. Debridement entails wide resection of infected tissue to reach uninfected margins. Serial debridement is often necessary to ensure thorough resection of infected tissue. Delay in surgical debridement beyond 24 hours is associated with a doubling of mortality. Supportive therapy such as intensive monitoring and hemodynamic resuscitation are important, given the high rate of sepsis associated with necrotizing soft tissue infections.

References:

Dellinger EP. Surgical Infections. In: Mulholland MW, Lillemoe KD, Doherty GM, Maier RV, Upchurch GR, eds. *Greenfield's Surgery: Scientific Principles and Practice.* 5th ed. 132–146. Philadelphia, PA: Lippincott Williams and Wilkins; 2011.

Manahan MA, Milner SM, Freeswick P, et al. Necrotizing skin and soft tissue infection. In: Cameron JL, ed. *Current Surgical Therapy.* 9th ed. Philadelphia, PA: Mosby; 2008:1128–1131.

۰۲۱-۶۶۱۹۸۵۱۴ www.myuptodate.com دریافت آخرین نسخه آپتودیت آفلاین

2B07

Key word: Characterization of Process Measures

Author: Brenessa M. Lindeman, MD
Editor: Martin A. Makary, MD, MPH

Which of the following is the definition of a process measure as utilized in health care?

(A) A health state of a patient resulting from health care used to assess the extent that health care services influence the likelihood of desired outcomes

(B) A measurement of patients' perspective of their experience in the hospital

(C) A summary of performance obtained by combining information from more than one individual measure

(D) An indicator that assesses a health care service provided to, or on behalf of, a patient often used to assess adherence to recommendations for clinical practice based on evidence or consensus

(E) The percentage of patients who had a good medical outcome

Answer: (D) An indicator that assesses a health care service provided to, or on behalf of, a patient often used to assess adherence to recommendations for clinical practice based on evidence or consensus.

Rationale:

Measures used to assess and compare the quality of care provided to patients are classified as structure, process, and outcomes measures. Structure measures examine physical equipment, facilities, and available personnel. Process measures assess whether patients receive specific health care services, which are known to be good care based on their condition. For example, if one was examining the quality of care received by patients with diabetes, one might assess the proportion of diabetic patients who had undergone an annual fundoscopic examination by an ophthalmologist. Such measures are used because research has demonstrated a link between those processes and important outcomes.

Outcome measures, on the other hand, attempt to assess the effects of medical care on the health status of patients (e.g., an improvement in symptoms, morbidity, or mortality). Outcome measures therefore attempt to measure the sum of multiple health care services/processes provided to an individual. Together process and outcome measures provide a more comprehensive view of the quality of health care compared to either one alone.

A national initiative to improve outcomes for patients having surgery is the Surgical Care Improvement Project, or SCIP. SCIP is a collaborative partnership between surgeons, anesthesiologists, nurses, pharmacists and others to reduce preventable surgical morbidity and mortality. Begun in 2003, the measures primarily focus on care processes and center around prevention of surgical site infection (e.g., appropriate antibiotics, given within 1 hour of incision, and discontinued within 24 hours of the procedure), venous thromboembolism (e.g., appropriate prophylaxis ordered and continued postoperatively), cardiac events (e.g., appropriate administration of perioperative beta-blockers), or prevention of respiratory complications (e.g., elevation of the head of the bed to at least 30 degrees for patients receiving mechanical ventilation, appropriate stress ulcer disease prophylaxis, etc.).

Answer **(A)** is the definition of outcome measures. Answer **(B)** is the definition of patient experience measures. Answer **(C)** is the definition of composite measures. Answer **(E)** is an outcome measure.

References:

Bratzler DW, Hunt DR. The surgical infection prevention and surgical care improvement projects: national initiatives to improve outcomes for patients having surgery. *Clin Infect Dis.* 2006;43(3):322–330.

Brook RH, McGlynn EA, Cleary PD. Quality of health care. Part 2: measuring quality of care. *N Engl J Med.* 1996; 335(13):966–970.

Donabedian A. The quality of care. How can it be assessed? *JAMA.* 1988;260(12):1743–1748.

۰۲۱-۶۶۱۹۸۵۱۴ www.myuptodate.com دریافت آخرین نسخه آپتودیت آفلاین

2B08

Key word: Definition of Active and Latent Error

Author: Raja Mohan, MD
Editor: Martin A. Makary, MD, MPH

When a physician places an order for a medication in an electronic ordering system, the system checks to see if the patient has an allergy to that medication. In addition, a pharmacist checks the dose and type of medication to ensure that it is appropriate for the patient. Afterwards, a nurse administers the medication and has to scan the patient's ID badge before doing so. In one isolated case, a nurse administered the medication without checking the patient's name, and the patient experienced an adverse reaction to the medication. This scenario is an example of which of the following?

(A) Active error
(B) Close call
(C) Latent error
(D) Near-miss
(E) Systems error

Answer: (A) Active error

Rationale:
Errors in prescribing, dispensing and administering medications are common in health care and result in significant human and financial cost. A report issued by the U.S. Institute of Medicine concluded that medication-related adverse events are the single leading cause of injury, harming at least 1.5 million people every year and causing extra medical costs of up to $3.5 billion per year. It is estimated that up to 7,000 people die annually from medication errors.

Human errors can be classified as "latent errors" and "active errors." Latent errors refer to failures of routines or systems that either contribute to the occurrence of errors or allow them to cause harm. In other words, latent errors are "accidents waiting to happen." Latent errors are synonymous with systems errors. Causes of latent errors can be ambiguous drug references, drug storage issues, lack of independent double checks, or incomplete patient information, such as a missing allergy. On the other hand, active errors are the unsafe acts committed by people who are in direct contact with the patient. They can be caused by a variety of reasons, such as mistakes, lapses in judgment, or procedural violations. Near-misses and close calls are errors that occur but do not cause an adverse event.

References:
Bates DW. Preventing medication errors: a summary. *Am J Health Syst Pharm.* 2007;64(14 Suppl 9):S3–S9, quiz S24–S26.
Glavin RJ. Drug errors: consequences, mechanisms, and avoidance. *Br J Anaesth.* 2010;105(1):76–82.
Reason J. Human error: models and management. *BMJ.* 2000;320(7237):768–770.

2B09

Key word: Diagnosis of Incarcerated Femoral Hernia

Author: Kyle J. Van Arendonk, MD, PhD
Editor: Barish H. Edil, MD

A 57-year-old woman with no past medical or surgical history presents to the emergency room with pain in her groin. She reports that the pain has become so severe that she is nauseous and has vomited multiple times over the past day. On physical examination, her abdomen is distended, and a small, irreducible mass is palpated inferior and lateral to the pubic tubercle. Which of the following statements is correct?

(A) Incarceration and strangulation rarely occur with this condition
(B) The presence of a preformed peritoneal sac causes this congenital condition
(C) This condition typically requires a laparotomy to obtain adequate exposure
(D) This diagnosis is seen most commonly in middle-aged and older women
(E) Watchful waiting is appropriate if reduction can be achieved

Answer: (D) This diagnosis is seen most commonly in middle-aged and older women

Rationale:
Hernia is the third most common cause of intestinal obstruction after adhesions and cancer. Examination of a patient with intestinal obstruction should therefore include a careful examination of the entire abdominal wall and groin to look for the presence of any hernias. Femoral hernias are relatively rare compared to inguinal hernias, accounting for approximately 10% of all groin hernias. They most commonly occur in women and in patients of age 40 to 70 years old.

The femoral canal is just medial to the femoral vessels and normally just contains lymphatics and adipose tissue and ends blindly. With femoral hernias, however, preperitoneal fat, bladder, or peritoneal sac (with or without intraperitoneal contents) passes through the femoral ring and through the femoral canal, becoming clinically evident when passing distally through the femoral orifice, which is bound posteriorly by the pectineal fascia, laterally by the femoral sheath, anteriorly by the fascia lata, and medially by the iliopubic tract. The etiology of femoral hernias is thought to be acquired, rather than congenital, and caused by persistently elevated intra-abdominal pressure.

Differentiating between a femoral and inguinal hernia through physical examination can be somewhat difficult, and often definitive diagnosis is not obtained until surgery. On examination, the pubic tubercle is typically palpable superior and medial to a femoral hernia but inferior and lateral to an inguinal hernia. In addition, if the hernia is reduced, a finger can be placed over the medial end of the inguinal ligament: With Valsalva, a femoral hernia should then appear inferior

۰۲۱-۶۶۱۹۸۵۱۴ www.myuptodate.com دریافت آخرین نسخه آپتودیت آفلاین

to the finger, while an inguinal hernia should appear superior to the finger.

Femoral hernias have a propensity to incarcerate and therefore more frequently require emergency surgery and bowel resection compared to inguinal hernias. All femoral hernias require surgical repair and can be corrected via a femoral, inguinal, or preperitoneal approach with suture, mesh, or both. Each approach has its advantages and disadvantages, and any technique can be applied in the absence of incarceration or strangulation. With incarcerated or strangulated femoral hernias, the femoral and laparoscopic totally extraperitoneal (TEP) repairs should be avoided. In cases of strangulation, prosthetic mesh should not be used, but biologic mesh can still be considered.

Reference:

Swartz DE, Felix EL. Femoral hernia. In: Yeo CJ, ed. *Shackelford's Surgery of the Alimentary Tract.* 7th ed. Philadelphia, PA: Saunders Elsevier; 2013:547–555.

2B10

Key word: Diagnosis of Paradoxic Aciduria

Author: Jens U. Berli, MD
Editor: Pamela A. Lipsett, MD, MHPE, FACS, FCCM

You are called to the emergency department to assess a 17-year-old female with abdominal pain and suspicion of an incarcerated inguinal hernia. She has bulimia and has had several admissions to the psychiatric ward. The hernia is nonreducible, and you schedule her for surgery. Her laboratory values come back as follows:

WBC 11,000/mm^3

Hbg 11.0 g/dL

Lactic acid 3.1 mg/dL

Na 140 mEq/L

Cl 96 mEq/L

K 2.9 mEq/L

Blood pH 7.49

Urine pH 6.1

The medical student asks you why her urine is acidotic in the setting of a metabolic alkalosis. Your answer is:

(A) The patient has a renal tubular acidosis leading to low pH of the urine

(B) The patient likely has a urinary tract infection with acid-producing bacteria

(C) The patient's gastrointestinal losses stimulate the renin–angiotensin–aldosterone axis, decreasing HCO_3^- excretion into the urine

(D) The patient's gastrointestinal losses stimulate the renin—angiotensin–aldosterone axis, increasing H^+ excretion into the urine

(E) To help with weight loss, the patient is taking a diuretic that acidified the urine

Answer: (D) The patient's gastrointestinal losses stimulate the renin—angiotensin–aldosterone axis, increasing H^+ excretion

Rationale:

The patient described above is suffering from loss of gastric fluid rich in chloride and to a lesser degree hydrogen ion (H^+) and potassium. This leads to an overall net loss of H^+ causing a metabolic alkalosis. The body's ability to correct a metabolic alkalosis is limited as respiratory and renal compensation are inefficient. Instead, the hypovolemia and electrolyte losses lead to activation of the renin—angiotensin–aldosterone system, in which aldosterone acts to reabsorb sodium in exchange for potassium. This also leads to water reabsorption. Potassium is then exchanged for H^+ leading to the paradoxical aciduria in the setting of contraction alkalosis. The release of antidiuretic hormone is also stimulated, which assists in absorption of free water.

۰۲۱-۶۶۱۹۸۵۱۴ www.myuptodate.com دریافت آخرین نسخه آپتودیت آفلاین

Renal tubular acidosis leads to a normal anion gap metabolic acidosis and alkalotic urine. Bacteria (urinary tract infection) can lead to alkalotic urine due to splitting of urea into ammonia.

References:

Galla JH. Metabolic alkalosis. *J Am Soc Nephrol.* 2000;11(2): 369–375.

Marino PL. Metabolic alkalosis. *The ICU book.* 3rd ed. Philadelphia, PA: Lippincott Williams & Wilkins; 2006:565–576.

2B11

Key word: Diagnosis of Refeeding Syndrome

Author: Said C. Azoury, MD
Editor: Elliott R. Haut, MD, FACS

A cachectic-appearing 45-year-old female with a history of long-term alcoholism is admitted for recurrent small bowel obstruction after multiple episodes of nausea and vomiting for the past 5 days. She is managed conservatively with a nasogastric tube, NPO status, intravenous fluids, and total parenteral nutrition (TPN). The best way to prevent the development of refeeding syndrome in this patient is:

(A) Avoid hyponatremia by adjusting the sodium amount in the TPN bag on a daily basis

(B) Follow daily nutritional laboratory values such as prealbumin and triglycerides to ensure that the nutritional needs of the patient are being met

(C) Institute caloric repletion rapidly, at 40 kcal/kg/day and slowly increase rate after the first week

(D) Monitor closely for hypoglycemia, a common paradoxical effect of excessive parenteral feeding of severely malnourished patients

(E) Strictly monitor vital signs and fluid balance and replete electrolytes as needed

Answer: **(E)** Strictly monitor vital signs and fluid balance and replete electrolytes as needed

Rationale:

Refeeding syndrome (RFS) may be described as the metabolic disturbances, clinical manifestations, and complications that occur with excessive and rapid feeding of patients with severe underlying malnutrition. RFS was first recognized and described in World War II when victims of starvation were noted to experience cardiac or neurologic dysfunction after being reintroduced to food. RFS can result in serious harm and death. The hallmark biochemical feature of refeeding syndrome is hypophosphatemia. However, hypokalemia, hypomagnesemia, and changes in sodium, fluid balance, glucose, protein, and fat metabolism may also be seen. Electrolyte disturbances occur within 12 to 72 hours of refeeding and can continue for the next 2 to 7 days. Cardiac complications can develop within the first week, most commonly within the first 24 to 48 hours, while neurologic signs and symptoms develop somewhat later.

The pathophysiology of RFS relies on the fact that during starvation, secretion of insulin is decreased in response to the reduced intake of carbohydrates. Fat and protein stores are instead used to produce energy. This leads to intracellular loss of electrolytes, in particular, phosphate. Malnourished patients can have depleted intracellular phosphate stores despite normal serum phosphate concentrations. With reintroduction of nutrition to a malnourished individual, a sudden shift from fat to carbohydrate metabolism occurs, leading to increased insulin secretion. Insulin stimulates cellular uptake of phosphate, potassium, and magnesium, thus

۰۲۱-۶۶۱۹۸۵۱۴ www.myuptodate.com دریافت آخرین نسخه آپتودیت آفلاین

leading to hypophosphatemia, hypokalemia, and hypomagnesemia. The electrolyte disturbances and fluid overload that result with refeeding can produce the clinical features of RFS, which include rhabdomyolysis, respiratory failure, cardiac failure, arrhythmias, hypotension, seizures, coma, and sudden death. Early clinical features of RFS are nonspecific and may go unrecognized; therefore high clinical suspicion is critical in order to recognize and treat the syndrome. Postoperative patients and patients with anorexia nervosa, chronic alcoholism, and cancer are known to be at high risk for RFS and should be followed carefully.

RFS can occur with both enteral and parenteral feeding. Prevention is the key to successful management. RFS can be avoided by identifying patients at risk early, restarting feeding at a reduced calorific rate (i.e, "permissive underfeeding" with 25% to 50% of estimated requirements), avoiding rapid increases in the amount of daily calories ingested for 3 to 7 days, and closely monitoring the patients during the refeeding process. Correction of electrolyte abnormalities, especially magnesium and potassium, and fluid imbalances is performed alongside feeding. If the syndrome is detected, the rate of feeding should be slowed, and essential electrolytes should be repleted. The cardiovascular system should be evaluated closely, and the fluids provided should be limited. Most fatalities are due to cardiac complications since atrophy of the heart during starvation renders the patient more vulnerable to fluid overload and heart failure.

References:

Mehanna HM, Moledina J, Travis J. Refeeding syndrome: what it is, and how to prevent and treat it. *BMJ.* 2008; 336:1495–1498.

Shires GT. Fluid and electrolyte management of the surgical patient. In: Brunicardi FC, Andersen DK, Billiar TR, Dunn DL, Hunter JG, Matthews JB, Pollock RE, eds. *Schwartz's Principles of Surgery.* 9th ed. New York, NY: McGraw-Hill; 2010. http://www.accessmedicine.com/content.aspx?aID=5011700. Accessed April 14, 2013.

2B12

Key word: Diagnosis of Syndrome of Inappropriate Antidiuretic Hormone

Author: Emmanouil Pappou, MD
Editor: Pamela A. Lipsett, MD, MHPE, FACS, FCCM

The following laboratory finding is most consistent with the diagnosis of the syndrome of inappropriate antidiuretic hormone secretion (SIADH):

(A) Plasma ADH level of 0.2 μUnits/mL
(B) Serum osmolality of 320 mOsmol/kg
(C) Serum sodium of 149 mEq/L
(D) Urine osmolality of 52 mOsmol/kg
(E) Urine sodium of 60 mEq/L

Answer: (E) Urine sodium of 60 mEq/L

Rationale:

Syndrome of inappropriate antidiuretic hormone secretion (SIADH) is characterized by an inappropriately high secretion of antidiuretic hormone (ADH), which leads to water retention and ensuing hyponatremia. Hyponatremia, defined as a serum sodium concentration of less than 135 mEq/L, occurs in approximately 10% to 15% of patients at some time during their hospital stay. Although history (heart failure, cirrhosis, renal failure, hypothyroidism, adrenal insufficiency, recent fluid infusion, diarrhea, and diuretics) and physical examination (edema and ascites) often provide important clues to the cause of hyponatremia, laboratory testing is almost always required to establish the diagnosis.

The three most important laboratory tests in the evaluation of hyponatremia are serum osmolality, urine osmolality, and urine sodium concentration. Serum osmolality (Sosm), which normally ranges from 280 to 300 mOsmol/kg, is reduced in most hyponatremic patients. Hyper-osmolar (Sosm >300 mOsmol/kg) hyponatremia occurs in patients with marked hyperglycemia, where glucose acts as an osmotically active solute. Iso-osmolar hyponatremia is seen with conditions such as hyperlipidemia or hyperglobulinemia (e.g., multiple myeloma). However, these cases are laboratory artifacts and are often referred to as pseudohyponatremia since the sodium concentration in the plasma water remains normal.

In patients with hypo-osmolar hyponatremia, urine osmolality is typically high (>100 mOsmol/kg) due to impaired water excretion. Values below 100 mOsmol/kg may be seen with primary polydipsia, where maximally dilute urine is excreted because of excessive water-drinking.

Measurement of urine sodium is helpful in the diagnosis of hyponatremia, particularly when the volume status of the patient is hard to assess clinically. Urine sodium is usually low (<20 mEq/L) in most patients with a low circulating volume (hypovolemia, congestive heart failure, liver cirrhosis), whereas patients with SIADH will typically have high levels (>20 mEq/L). In a retrospective study, the ability to distinguish hypovolemia and SIADH using the urine sodium

۰۲۱-۶۶۱۹۸۵۱۴ www.myuptodate.com دریافت آخرین نسخه آپتودیت آفلاین

concentration alone was found to be reasonably high (82%) when a cutoff of 50 mEq/L was used.

SIADH is a diagnosis of exclusion and can usually be made with routine history, physical examination, and laboratory confirmation with hyponatremia, hypo-osmolality, a urine osmolality above 100 mOsmol/kg, and a urine sodium concentration above 20 mEq/L. Plasma ADH levels tend to be high or inappropriately normal in most types of hyponatremia and are currently of limited diagnostic value.

Management of SIADH includes treatment of the underlying cause (cancer, infection, drugs, central nervous system disease, etc.), fluid restriction, diuretics, intravenous infusion of saline, and/or medications (e.g., demeclocycline).

References:

Decaux G, Musch W. Clinical laboratory evaluation of the syndrome of inappropriate secretion of antidiuretic hormone. *Clin J Am Soc Nephrol.* 2008;3(4):1175–1184.

Hato T, Ng R. Diagnostic value of urine sodium concentration in hyponatremia due to syndrome of inappropriate antidiuretic hormone secretion versus hypovolemia. *Hawaii Med J.* 2010;69(11):264–267.

Vaidya C, Ho W, Freda BJ. Management of hyponatremia: providing treatment and avoiding harm. *Cleve Clin J Med.* 2010;77(10):715–726.

2B13

Key word: Diagnosis of Vitamin K Deficiency

Author: Robert A. Meguid, MD, MPH
Editor: Pamela A. Lipsett, MD, MHPE, FACS, FCCM

Which of the following is associated with vitamin K deficiency?

(A) Glossitis
(B) Megaloblastic anemia
(C) Prolonged prothrombin time
(D) Rickets
(E) Scurvy

Answer: (C) Prolonged prothrombin time

Rationale:

Vitamin K is a lipid-soluble vitamin produced by bacteria within the small intestine, where it is absorbed. In the liver, vitamin K is necessary for the carboxylation and subsequent activation of the vitamin K-dependent coagulation pathway Factors II, VII, IX, X, Protein C, and Protein S. Warfarin inhibits the activity of these factors by competitively binding vitamin K receptor sites in the liver. Vitamin K deficiency can result from dietary insufficiency, or more commonly, following administration of broad-spectrum antibiotics resulting in inhibition of bacteria producing vitamin K and subsequent bacterial overgrowth of the small intestine.

Vitamin K deficiency results in a lack of the active forms of Factors II, VII, IX, X, Protein C, and Protein S, which can lead to increased bleeding. Specifically, active Factor VII with a half life of 4 hours becomes depleted first, resulting in prolonged prothrombin time (PT) as the first clinical manifestation of vitamin K deficiency.

Glossitis, dermatitis, mucositis, and neuropathy are due to vitamin B_2 (riboflavin) deficiency. Megaloblastic anemia is due to vitamin B_{12} deficiency and folate deficiency. Vitamin B_{12} deficiency is also associated with peripheral neuropathy. Vitamin D deficiency results in rickets, or softening of the bones in children with immature skeletal development, and osteomalacia in adults. Scurvy is caused by vitamin C (ascorbic acid) deficiency, resulting in failure to cross-link collagen. Ascorbic acid is required for the hydroxylation of lysine and proline into hydroxylysine and hydroxyproline, which in turn cross-link collagen into a stable construct.

References:

Ansell J, Hirsh J, Hylek E, et al. Pharmacology and management of the vitamin K antagonists: American College of Chest Physicians Evidence-Based Clinical Practice Guidelines (8th Edition). *Chest.* 2008;133(6 Suppl):160S–198S.

Heneke PK, Wakefield TW. Hemostasis. In: Mulholland MW, Lillemoe KD, Doherty GM, Maier RV, Upchurch GR, eds. *Greenfield's Surgery: Scientific Principles and Practice.* 5th ed. Philadelphia, PA: Lippincott Williams and Wilkins; 2011.

Reilly JJ, Jr. Principles of surgical nutrition. In: Simmons RL, Steed DL, eds. *Basic Science Review for Surgeons.* St. Louis, MO: W.B. Saunders; 1992.

Steed DL. Hemostasis and coagulation. In: Simmons RL, Steed DL, eds. *Basic Science Review for Surgeons.* St. Louis, MO: W.B. Saunders; 1992.

۰۲۱-۶۶۱۹۸۵۱۴ www.myuptodate.com دریافت آخرین نسخه آپتودیت آفلاین

2B14

Key word: Effect of Use of Iodine Drapes

Author: Kyle J. Van Arendonk, MD, PhD
Editor: Martin A. Makary, MD, MPH

Your medical student wants to know why yellow adhesive drapes were applied to a patient's skin prior to incision. Which of the following would be a correct reply regarding the use of iodine-impregnated drapes?

(A) Iodine-impregnated drapes are a required component of the Surgical Care Improvement Project (SCIP)

(B) Iodine-impregnated drapes are most beneficial when used for contaminated and clean–contaminated cases

(C) Iodine-impregnated drapes can be used alone in place of other skin preparations

(D) Iodine-impregnated drapes can reduce microbial counts on the skin

(E) Iodine-impregnated drapes have been shown to reduce the incidence of surgical site infections (SSIs)

Answer: (D) Iodine-impregnated drapes can reduce microbial counts on the skin

Rationale:

SSIs are a common preventable adverse event associated with considerable morbidity, extended hospital stay, and financial cost. Evidence-based practices for prevention of SSIs include the initial administration of perioperative antibiotics within 1 hour before surgery, the preoperative use of electric hair clippers or no hair removal (as opposed to razor shaving of hair), and the maintenance of normothermia during surgery.

For many SSIs, the pathogen originates from the patient's skin. Povidone-iodine is a potent, rapid, and persistent bactericidal with broad-spectrum activity. Iodine-impregnated drapes have therefore been used in attempt to further prevent SSIs by decreasing microbial counts on the skin and by acting as a microbial barrier. However, a meta-analysis of two studies comparing iodine-impregnated adhesive drapes with no adhesive drapes found that iodine-impregnated drapes did not in fact significantly reduce the risk of SSI.

References:

Bratzler DW, Hunt DR. The surgical infection prevention and surgical care improvement projects: national initiatives to improve outcomes for patients having surgery. *Clin Infect Dis.* 2006;43(3):322–330.

Webster J, Alghamdi AA. Use of plastic adhesive drapes during surgery for preventing surgical site infection. *Cochrane Database Syst Rev.* 2007;(4):CD006353.

2B15

Key word: Effect of Use of Isolation Gowns

Author: Andrew P. Dhanasopon, MD
Editor: Martin A. Makary, MD, MPH

Which of the following scenarios represents appropriate use of isolation gowns when entering the room of a patient infected with *Clostridium difficile*?

(A) Using the same isolation gown for two different patients in two different rooms as long as both are infected with *Clostridium difficile*

(B) Wearing an isolation gown is not necessary if one wears a laboratory coat

(C) Wearing an isolation gown only if contact with the patient is anticipated

(D) Wearing an isolation gown that covers the body from the neck to mid-thigh including the entire back and arms

(E) When removing the gown, turning the contaminated side inward, rolled into a bundle, and discarding the gown in any container outside the patient's room

Answer: (D) Wearing an isolation gown that covers the body from the neck to mid-thigh including the entire back and arms

Rationale:

Isolation gowns protect the health care worker's neck, arms, torso, and upper thigh to prevent contamination of clothing with blood, body fluids, and other potentially infectious materials. When contact precautions are used, as in the case of this patient with *Clostridium difficile,* donning of a gown regardless of anticipated interaction with the patient prevents unintentional contact with contaminated environmental surfaces. When removing the gown, one must discard it before leaving the patient's room to prevent contaminating the environment outside of the patient's room. Clinical and laboratory coats or jackets worn over personal clothing are not considered Personal Protective Equipment. The same isolation gown must not be used for two different patients.

Reference:

Siegel JD, Rhinehart E, Jackson M, et al. 2007 guideline for isolation precautions: Preventing transmission of infectious agents in health care settings. *Am J Infect Control.* 2007;35(10 Suppl 2):S65–S164.

۰۲۱-۶۶۱۹۸۵۱۴ www.myuptodate.com دریافت آخرین نسخه آپتودیت آفلاین

2B16

Key word: Etiology of Grand Mal Seizure after Lidocaine Administration

Author: Brenessa M. Lindeman, MD
Editor: Bradford D. Winters, MD, PhD

A 59-year-old man weighing approximately 65 kg and having a long history of hepatitis C presents with a 7-cm skin laceration. For anesthesia, 20 mL of 2% lidocaine is infiltrated into the wound bed. While suturing the wound, the patient begins to have generalized convulsions. Which of the following confers an increased risk for lidocaine toxicity?

(A) Active bacterial infection
(B) Coronary artery disease
(C) Hepatic impairment
(D) Immunodeficiency
(E) Renal impairment

Answer: (C) Hepatic impairment

Rationale:
Lidocaine is an amide local anesthetic. Doses of 4 to 5 mg/kg of plain lidocaine and up to 7 mg/kg of lidocaine with epinephrine are safe in healthy patients without producing toxicity. Lidocaine is usually given as a 1% solution (10 mg/mL). Higher concentrations beyond 1% do not improve onset or duration of analgesia and may in fact increase the risk of toxicity.

The central nervous system (CNS) and cardiovascular system are the major sites of lidocaine toxicity. The CNS is more sensitive to local anesthetic toxicity than the cardiovascular system, and therefore CNS intoxication usually manifests before signs of cardiovascular compromise. CNS symptoms of lidocaine toxicity include perioral numbness, tinnitus, and grand mal seizures. Cardiovascular effects include bradycardia, hypotension, arrhythmias, and cardiac arrest.

Approximately 90% of lidocaine is metabolized by the microsomal enzyme system in the liver, and less than 10% is excreted unchanged in the urine. Thus patients with compromised hepatic function are at increased risk for lidocaine toxicity. Dosage reductions by two- to three fold are highly recommended, especially in patients with moderate to severe cirrhosis. The patient in this case received 20 mL of 2% lidocaine (20 mg/mL) for a total dose of 400 mg, which is approximately 6 mg/kg and clearly excessive given his hepatic impairment.

Reference:
DeToledo JC. Lidocaine and seizures. *Therapeutic Drug Monitoring.* 2000;22(3):320–322.

2B17

Key word: Etiology of Hypotension after Blunt Trauma

Author: Lisa M. Kodadek, MD
Editors: Elliott R. Haut, MD, FACS, and F. Dylan Stewart, MD, FACS

An 8-year-old pedestrian struck by a motor vehicle presents in extremis with a closed left femur fracture and severe right craniofacial injury. The patient is intubated and bilateral chest tubes are placed with return of 150 mL of blood from the left chest tube and 100 mL of blood from the right chest tube. As the patient is fluid-resuscitated, Focused Abdominal Sonography for Trauma (FAST) examination is performed and is negative. The patient remains hypotensive and unresponsive to initial fluid resuscitation. The most likely source of this patient's hypotension is injury to the:

(A) Femur
(B) Heart
(C) Lung
(D) Spleen
(E) Stomach

Answer: (D) Spleen

Rationale:
This pediatric patient presents with a pattern of injuries known as Waddell's triad. This triad is seen in pedestrians stuck by motor vehicles and consists of (1) tibiofibular or femur fracture, (2) truncal injury, and (3) craniofacial injury. Most often, the initial impact causes the bony injury and ipsilateral intrathoracic and intra-abdominal injury, while subsequent injury to the contralateral face and cranium is sustained after the child is thrown following initial impact.

The liver and spleen are the most commonly injured intra-abdominal organs after blunt abdominal trauma. In this scenario, splenic injury is the most likely etiology of hypotension given the presenting injury pattern. It is important to remember that the FAST examination is relatively insensitive in children because of the frequency of solid-organ injury seen without associated hemoperitoneum.

The patient has bilateral chest tubes without a dramatic initial return of blood. Lung injury would be more likely if chest tube output was higher. In adults, initial chest tube output greater than 1,500 mL or greater than 200 mL/hr for 4 hours is an indication for thoracotomy. In children, these numbers must be adjusted. Initial chest tube output greater than approximately 15 to 20 mL/kg or ongoing output of greater than approximately 5 mL/kg is considered an indication for thoracotomy in the pediatric trauma setting. Stomach injuries occur in less than 1% of blunt abdominal trauma patients. Cardiac injury would be less plausible in this scenario and is often recognized during FAST examination of the pericardium.

۰۲۱-۶۶۱۹۸۵۱۴ www.myuptodate.com دریافت آخرین نسخه آپتودیت آفلاین

References:
Holmes JF, Gladman A, Chang CH. Performance of abdominal ultrasonography in pediatric blunt trauma patients: a meta-analysis. *J Pediatr Surg.* 2007;42(9):1588–1594.
Hoyt DB, Coimbra R, Acosta J. Management of acute trauma. In: Townsend CM, Beauchamp RD, Evers MB, Mattox KL, eds. *Sabiston Textbook of Surgery.* 18th ed. Philadelphia, PA: Elsevier Saunders; 2008:477–520.
Piper GL, Peitzman AB. Blunt abdominal trauma. In: Cameron JL, Cameron AM, eds. *Current Surgical Therapy.* 10th ed. Philadelphia, PA: Elsevier Saunders; 2011:918–923.

2B18

Key word: Etiology of Paresthesias after Thyroid Surgery

Author: Brenessa M. Lindeman, MD
Editor: Anthony P. Tufaro, DDS, MD, FACS

Which of the following neck procedures puts a patient most at risk for paresthesias in the postoperative period?

(A) Central neck dissection
(B) Parathyroid autotransplantation
(C) Parathyroidectomy
(D) Thyroid lobectomy
(E) Total thyroidectomy

Answer: **(E)** Total thyroidectomy

Rationale:
Hypoparathyroidism leading to digital or perioral paresthesia is a known side effect of surgical procedures in the neck. The risk of hypoparathyroidism is increased with bilateral neck procedures, specifically total thyroidectomy, and in the presence of malignancy. It is routine practice to check a calcium level following total thyroidectomy to screen for the presence of hypoparathyroidism and determine the need for postoperative calcium supplementation. Most cases of hypoparathyroidism are transient, but up to 2% may be permanent.

Reference:
Borman KA, Rabaglia JL. Thyroid diseases. In: Souba WW, Fink MP, Jurkovich GJ, Kaiser LR, Pearce WH, Pemberton JH, Soper NJ, eds. *ACS Surgery: Principles and Practice.* Decker Intellectual Properties; 2011.

۰۲۱-۶۶۱۹۸۵۱۴ www.myuptodate.com دریافت آخرین نسخه آپتودیت آفلاین

2B19

Key word: Extrapyramidal Effects of Antiemetics

Author: Said C. Azoury, MD
Editor: Bradford D. Winters, MD, PhD

A postoperative patient with nausea and abdominal discomfort is discharged on both promethazine and metoclopramide. The patient has also been taking another antiemetic at home for several months, since initiating chemotherapy for her underlying malignancy, but she cannot recall the name of the drug. Two days later, the patient calls reporting a tremor and a feeling of stiffness in her extremities. Which of the following is the most appropriate next step?

(A) Continue both promethazine and metoclopramide and prescribe diphenhydramine for symptomatic relief

(B) Increase the dose of metoclopramide, switch promethazine to ondansetron, and have the patient return if symptoms persist or worsen

(C) Increase the dose of promethazine, switch metoclopramide to ondansetron, and have the patient return if symptoms persist or worsen

(D) Obtain an urgent EEG to rule out seizure activity because antiemetics may lower seizure threshold

(E) Stop all current antiemetics, prescribe a serotonin receptor inhibitor such as ondansetron, and have the patient return if symptoms persist or worsen

Answer: **(E)** Stop all current antiemetics, prescribe a serotonin receptor inhibitor such as ondansetron, and have the patient return if symptoms persist or worsen

Rationale:

Postoperative nausea and vomiting is the most common complication in postanesthesia care units, ranging between 10% and 30%, and a major concern for both patients and health care providers. There are several different kinds of antiemetics prescribed for the postoperative patient and for chemotherapy-induced emesis prophylaxis, with varying mechanisms of action.

Promethazine is a phenothiazine derivative that blocks postsynaptic mesolimbic dopamine receptors in the brain. It also antagonizes H1- and muscarinic receptors in the central nervous system, both of which are responsible for its sedating properties. The muscarinic-blocking effect may in fact be the one responsible for its antiemetic activity. Promethazine may cause extrapyramidal symptoms, including acute dystonic reactions, akathisia, pseudoparkinsonism, and tardive dyskinesia.

Metoclopramide blocks dopamine and serotonin receptors in the chemoreceptor trigger zone of the central nervous system. It is used to increase gastric motility and gut motility by enhancing the tissue response to acetylcholine in the upper gastrointestinal tract, and this prokinetic effect itself may contribute to its antiemetic properties. Metoclopramide, like promethazine, has been associated with extrapyramidal symptoms. Coadministration of metoclopramide with neuroleptics/antipsychotics or with phenothiazines such as promethazine may increase the frequency and severity of extrapyramidal reactions.

Acute dystonic reactions most typically manifest within the initial 24 to 48 hours of use, whereas pseudoparkinsonism (bradykinesia, tremor, rigidity) or tardive dyskinesia may occur after several months of therapy. Tardive dyskinesia is a hyperkinetic movement disorder manifested as chorea, athetosis, dystonia, akathisia, stereotyped behaviors, and tremor and may be irreversible. Treatment of extrapyramidal symptoms includes antimuscarinic agents such as benztropine or diphenhydramine and dopamine agonists such as pramipexole.

Ondansetron is a selective 5-HT3 receptor antagonist, blocking serotonin both peripherally on vagal nerve terminals and centrally in the chemoreceptor trigger zone. Ondansetron has not been associated with extrapyramidal symptoms.

References:

Ganzini L, Casey DE, Hoffman WF, et al. The prevalence of metoclopramide induced tardive Dyskinesia and acute extrapyramidal movement disorders. *Arch Intern Med.* 1993;153:1469.

Tarsy D, Baldessarinin RJ. Tardive dyskinesia. *Annu Rev Med.* 1984;35:605.

۰۲۱-۶۶۱۹۸۵۱۴ www.myuptodate.com دریافت آخرین نسخه آپتودیت آفلاین

2B20

Key word: Fluid Requirement with 30% TBSA Flame Burn

Author: Ibrahim Sultan, MD
Editor: F. Dylan Stewart, MD, FACS

A 25-year-old man weighing 80 kg suffers partial-thickness flame burns to his entire left and right upper extremities and to his entire left lower extremity. He is brought to the emergency room 4 hours after the injury. His airway is secured for a depressed Glasgow Coma Scale (GCS) score, and two large bore intravenous lines are placed. What rate of intravenous fluid administration is this patient expected to need over the next 4 hours in order to achieve adequate resuscitation?

(A) Lactated Ringer at 1,440 mL/hr
(B) Lactated Ringer at 2,500 mL/hr
(C) Lactated Ringer at 721 mL/hr
(D) Normal saline at 1,440 mL/hr
(E) Normal saline at 721 mL/hr

Answer: (A) Lactated Ringer 1,440 mL/hr

Rationale:
The man in the vignette has sustained nearly 36% burns to his body according to the "rule of nines" used to estimate total body surface area (TBSA) involved in burns. According to this rule, each upper extremity represents 9% TBSA and each lower extremity represents 18% TBSA. The Parkland formula is employed to calculate resuscitation in patients who sustain greater than 15% TBSA burns. According to the Parkland formula, fluid resuscitation over the first 24 hours = 4 mL × body weight (in kilograms) × % TBSA. Thus, for the patient in this vignette, 4 mL × 80 kg × 36% = 11,520 mL. Half of this volume (5,760 mL) is given in the first 8 hours beginning immediately after the thermal injury, and the other half is given over the next 16 hours. In this instance, it took 4 hours for the patient to reach the emergency room, making it such that the first half of fluids needs to be administered over the next 4 hours, making the hourly resuscitation volume for these 4 hours 5,760 mL/4 hr = 1,440 mL/hr. In addition, lactated Ringer is the fluid of choice for patients with thermal burns because of the massive amount of volume they require. Large amounts of normal saline can cause a nongap metabolic acidosis.

References:
Gallagher JJ, Wolf SE, Herndon DN. Burns. In: Townsend CM, Beauchamp RD, Evers BM, Mattox KL, eds. *Sabiston Textbook of Surgery.* 18th ed. Philadelphia, PA: Elsevier; 2008: 559–585.

Phillips BJ. Burns: fluids, nutrition and metabolics. In: Cameron JL, Cameron AM, eds. *Current Surgical Therapy.* 10th ed. Philadelphia, PA: Elsevier; 2011: 1036–1042.

2B21

Key word: Hair Removal in Contaminated Laceration Repair

Author: Brenessa M. Lindeman, MD
Editor: Martin A. Makary, MD, MPH

A 20-year-old woman presents with a 3-cm laceration on the parietal region of her scalp after tripping on a sidewalk. On physical examination, you note a linear wound with clean edges in the center of hair-bearing scalp that continues to ooze. Which of the following repair options is recommended?

(A) Clean the wound, allow to heal by secondary intention
(B) Clean the wound, clip surrounding hair, suture closed
(C) Clean the wound, leave surrounding hair in place, suture closed
(D) Clean the wound, shave surrounding hair, apply skin glue
(E) Clean the wound, shave surrounding hair, suture closed

Answer: (C) Clean the wound, leave surrounding hair in place, suture closed

Rationale:
For many years, the advice regarding how to manage hair surrounding a laceration has been in flux. Initial advice was to shave the hair, but evidence revealed that this led to an increased incidence of wound infection. Clipping hair then became the standard of care, but several studies have shown that this step is not necessary provided that the wound can be appropriately cleaned. An emergency medicine study from 1988 revealed no infections in 68 lacerations when hair was neither clipped nor shaved, after a mean follow-up time of 5 days. In addition, a randomized trial from the otolaryngology literature showed no difference in wound infection rate of skull base surgery when hair was removed versus not.

References:
Gil Z, Cohen JT, Spektor S, et al. The role of hair shaving in skull base surgery. *Otolaryngol Head Neck Surg.* 2003; 128(1):43–47.

Howell JM, Morgan JA. Scalp laceration repair without prior hair removal. *Am J Emerg Med.* 1988;6(1):7–10.

۰۲۱-۶۶۱۹۸۵۱۴ www.myuptodate.com دریافت آخرین نسخه آپتودیت آفلاین

2B22

Key word: Hemodynamic Findings in Septic Shock

Author: Lisa M. Kodadek, MD
Editor: Mark D. Duncan, MD, FACS

A 65-year-old man with a history of congestive heart failure and coronary artery disease underwent abdominoperineal resection 7 days ago for rectal adenocarcinoma. On morning rounds, the patient is confused, tachycardic, and hypotensive with an elevated white blood cell count. Purulent drainage from his perineal wound is present. Fluids are given. The patient is most likely to have which of the following sets of hemodynamic findings?

	Cardiac Output	Vascular Resistance	Myocardial Oxygen Consumption	Right Heart Filling Pressure
(A)	⇓	⇑	⇓	⇓
(B)	⇓	⇑	⇓	⇑
(C)	⇑	⇓	⇑	⇔
(D)	⇓	⇓	⇔	⇓
(E)	⇑	⇑	⇑	⇑

Answer: (C)

Cardiac Output	Vascular Resistance	Myocardial Oxygen Consumption	Right Heart Filling Pressure
⇑	⇓	⇑	⇔

Rationale:

Early septic shock is associated with increased cardiac output, decreased vascular resistance, increased myocardial oxygen consumption, and variable or unchanged right heart filling pressure. Answer **(A)** is typical of hypovolemic shock. Answer **(B)** is typical of cardiogenic shock. Answer **(D)** is typical of spinal/neurogenic shock. Answer **(E)** is a pattern of hemodynamic findings not seen in shock states.

Reference:

Cuschieri J. Shock. In: Mulholland MW, Lillemoe KD, Doherty GM, Maier RM, Simeone DM, Upchurch GR, eds. *Greenfield's Surgery: Scientific Principles and Practice.* 5th ed. Philadelphia, PA: Lippincott Williams amd Wilkins; 2011.

2B23

Key word: Indication for Antibiotics with 40% TBSA Burns

Author: Andrew P. Dhanasopon, MD
Editor: F. Dylan Stewart, MD, FACS

A 52-year-old hospital maintenance worker is admitted to the Emergency Department after sustaining burn injuries from a ruptured steam pipe. On physical examination, he has circumferential deep burns involving his torso, back, and both arms and hands. The patient is intubated and placed on appropriate IV fluids and brought to the operating room for urgent escharotomy. Prior to incision for escharotomy, the appropriate treatment would be:

(A) No antibiotics
(B) Silver sulfadiazine
(C) Systemic prophylactic antibiotics alone
(D) Topical and systemic prophylactic antibiotics
(E) Topical antibiotics to all affected tissues

Answer: (C) Systemic prophylactic antibiotics alone

Rationale:

Burn wounds begin to be colonized over the first 2 days by skin flora and later by gastrointestinal flora. Aggressive wound care, early excision and grafting, and topical antibiotics are associated with a significant decline in the incidence of burn wound infections. Topical antibiotics and other topical antimicrobials such as silver sulfadiazine are therefore indicated in this patient postoperatively but are not necessary prior to incision.

Systemic antibiotics are indicated for burn wounds with a documented infection (defined as $>10^5$ organisms per gram of tissue via wound biopsy) or in systemically ill patients presumed to have sepsis or other sources of infection (urinary tract infection, pneumonia, etc.). Prophylactic administration of systemic antibiotics are generally recommended only for the perioperative period for severe burns with total body surface area (TBSA) >40% that require escharotomy, excision, and/or skin grafting. Systemic prophylactic antibiotics have no benefit prior to routine debridements or skin grafting for small burns.

References:

Avni T, Levcovich A, Ad-El DD, et al. Prophylactic antibiotics for burns patients: systematic review and meta-analysis. *BMJ.* 2010;340:c241.

Church D, Elsayed S, Reid O, et al. Burn wound infections. *Clin Microbiol Rev.* 2006;19(2):403–434.

D'Avignon LC, Chung KK, Saffle JR, et al. (The Prevention of Combat-Related Infections Guidelines Panel). Prevention of infections associated with combat-related burn injuries. *J Trauma.* 2011;71(2 Supplement 2):S282–S289.

Mozingo DW, McManus AT, Kim SH, et al. Incidence of bacteremia after burn wound manipulation in the early postburn period. *J Trauma.* 1997;42(6):1006–1011.

۰۲۱-۶۶۱۹۸۵۱۴ www.myuptodate.com دریافت آخرین نسخه آپتودیت آفلاین

2B24

Key word: Effective Pain Control

Author: Jens U. Berli, MD
Editor: Bradford D. Winters, MD, PhD

Which of the following parenteral analgesics is contraindicated for critically ill patients or patients with known opiate abuse due to its potential side effects?

(A) Acetaminophen
(B) Buprenorphine
(C) Fentanyl
(D) Hydromorphone
(E) Ketorolac

Answer: (B) Buprenorphine

Rationale:
Some opioids are not recommended for routine use in critically ill patients. Buprenorphine is a partial mu opiate receptor agonist and a weak kappa opiate receptor antagonist that has less euphoric and respiratory depression effects than typical opiate agonists. Because it is a partial antagonist, buprenorphine in moderate to high doses (e.g., infusion in critical care setting) can precipitate an extremely intense form of opioid withdrawal called "precipitated withdrawal" in opioid-dependent patients or after prolonged opiate administration. Other agents with the same properties as buprenorphine are butorphanol, dezocine, nalbuphine, and pentazocine.

Fentanyl and hydromorphone are amongst the most frequently used opioids in the inpatient setting. Fentanyl is a synthetic derivative of morphine with a rapid onset of action due to its better penetration through the blood–brain barrier. Hydromorphone has a faster onset compared to morphine, and unlike morphine, it does not have active metabolites that extend its effect. Both fentanyl and hydromorphone are commonly used as continuous intravenous infusions in critically ill patients.

Ketorolac may be used in critically ill patients as a short-term adjunct, although all nonsteroidal anti-inflammatory drugs should be used with caution, especially in elderly patients, in those with preexisting renal insufficiency, or in states of hypoperfusion as they are associated with renal events (nephritis, kidney failure), bleeding, an increased risk of cardiovascular thrombotic events including myocardial infarction and stroke, and gastrointestinal events such as bleeding or ulceration. When used, treatment should not exceed 5 days.

Acetaminophen in parenteral form has been widely used in Europe in the past and has recently been approved by the FDA for use in the United States. It is a good analgesic for patients with normal liver function.

Reference:
Schumacher MA, Basbaum AI, Way WL. Opioid analgesics & antagonists. In: Katzung BG, Masters SB, Trevor AJ, eds. *Basic & Clinical Pharmacology.* 11th ed. New York, NY: McGraw-Hill; 2011.

2B25

Key word: Initial Treatment of Ischemic Orchitis after Hernia Repair

Author: Andrew P. Dhanasopon, MD
Editor: Mohamad E. Allaf, MD

A 25-year-old man is evaluated 7 days after an open right inguinal hernia repair with mesh. Intraoperatively the patient had a large hernia sac that required extensive dissection and handling of the spermatic cord. He now reports fevers and 3 days of progressive pain and swelling in his right testicle. He denies dysuria, hematuria, or recent trauma. Physical examination demonstrates a tender, enlarged right testicle without discoloration. Ultrasonography reveals no fluid collection but reduced echogenicity of the right testicle and decreased intratesticular flow on color Doppler. What is the management of this complication?

(A) Emergent orchiectomy
(B) Reassurance, comfort measures, and NSAIDs
(C) Urgent surgical re-exploration to loosen the internal ring
(D) Urgent surgical re-exploration with neurectomy of the ilioinguinal and iliohypogastric nerves
(E) Urgent surgical re-exploration with removal of the mesh

Answer: (B) Reassurance, comfort measures, and NSAIDs

Rationale:
This patient presents with ischemic orchitis after inguinal hernia repair. This complication occurs in <1% of all herniorrhaphies and is more frequent after recurrent inguinal hernia repair. Patients usually present within the first week after hernia repair. Typical symptoms include low-grade fever and testicular pain, tenderness, and enlargement. Ultrasound usually reveals hypoechogenicity and reduced flow to the testicle using color Doppler. Risk factors include a large hernia sac, a hernia sac that extends into the scrotum, extensive dissection of the hernia sac off the spermatic cord, and extensive handling of the spermatic cord. These risk factors may also lead to hematoma formation; the scrotum would then typically have a blue-black discoloration, and ultrasound would reveal a fluid collection.

Ischemic orchitis is thought to be due to injury and thrombosis of the veins in the pampiniform plexus, not injury to the testicular artery. This injury is self-limited, and long-term effects are rare. Management is expectant: reassurance, comfort measures, and NSAIDs. Surgical re-exploration is not helpful and will increase the patient's risk of additional complications. Neurectomy is the treatment for chronic neuropathic groin pain that has failed conservative management following herniorrhaphy. Emergent orchiectomy is rarely indicated and reserved for testicular necrosis.

References:
Holloway BJ, Belcher HE, Letourneau JG, et al. Scrotal sonography: a valuable tool in the evaluation of complications following inguinal hernia repair. *J Clin Ultrasound.* 1998;26(7):341–344.

۰۲۱-۶۶۱۹۸۵۱۴ www.myuptodate.com دریافت آخرین نسخه آپتودیت آفلاین

Sherman V, Macho JR, Brunicardi FC. Inguinal hernias. In: Brunicardi FC, Andersen DK, Billiar TR, Dunn DL, Hunter JG, Matthews JB, Pollock RE, eds. *Schwartz's Principles of Surgery.* 9th ed. New York, NY: McGraw-Hill; 2010. http://www.accesssurgery.com/content.aspx?aID=5031117. Accessed May 10, 2013.

2B26

Key word: Most Common Side Effect of Mycophenolate

Author: Babak J. Orandi, MD, MSc
Editor: Dorry L. Segev, MD, PhD

Of the following, which is the most common side effect of mycophenolate mofetil (MMF)?

(A) Diarrhea

(B) Gingival hyperplasia

(C) Hyperglycemia

(D) Nephrotoxicity

(E) Tremor

Answer: (A) Diarrhea

Rationale:

MMF, which acts by blocking de novo purine synthesis, preventing formation of DNA and RNA and therefore B- and T-cell proliferation, is a frequently used immunosuppressive drug in transplant patients. MMF is a fundamental component of many post-transplant immunosuppressive regimens, as it has been shown to reduce the incidence of acute rejection.

The most common side effects are gastrointestinal in nature, particularly diarrhea. About 40% to 50% of patients on MMF experience one or more gastrointestinal complications within the first 6 months post-transplant, which may lead to MMF dose reduction or withdrawal in about half of these cases. Other side effects of MMF include bone marrow suppression, infectious complications, and neurologic effects such as headache and fatigue. In the transplant patient, it is critically important to differentiate medication-induced diarrhea from other causes of diarrhea, particularly infectious diarrhea. If MMF proves to be the causative agent, more frequent administration with a lower dose is often effective in minimizing this side effect; in some cases, the overall dose also needs to be decreased. The clinician must exercise caution in adjusting and in particular decreasing immunosuppression, as there is a delicate balance between resolving symptoms and maintaining sufficient immunosuppression to protect the graft.

Nephrotoxicity and tremors are most strongly associated with calcineurin inhibitors such as cyclosporine and tacrolimus. Steroids cause a hyperglycemic state. Gingival hyperplasia is a side effect of cyclosporine.

References:

Mourad M, Malaise J, Eddour DC, et al. Correlation of mycophenolic acid pharmacokinetic parameters with side effects in kidney transplant patients treated with mycophenolate mofetil. *Clin Chem.* 2001;47:88–94.

Platt JL, Cascalho M. Transplantation immunology. In: Mulholland MW, Lillemoe KD, Doherty GM, Maier RV, Upchurch GR, eds. *Greenfield's Surgery: Scientific Principles and Practice.* 5th ed. Philadelphia, PA: Lippincott Williams and Wilkins; 2011.

۰۲۱-۶۶۱۹۸۵۱۴ www.myuptodate.com دریافت آخرین نسخه آپتودیت آفلاین

2B27

Key word: Risks of Long-term Immunosuppression

Author: Babak J. Orandi, MD, MSc
Editor: Dorry L. Segev, MD, PhD

A 52-year-old male who had a deceased donor renal transplant 6 months ago presents to clinic with a low-grade fever, fatigue, a 4.54 kg (10 lb) weight loss, and a serum creatinine of 2.3 mg/dL, an increase from his baseline post-transplant level of 1.4 mg/dL. Transplant biopsy shows no evidence of acute rejection. Measurement of serum Epstein–Barr virus (EBV) DNA by polymerase chain reaction (PCR) demonstrates a high viral load. The patient will most likely display clinical improvement with the following:

(A) Broad-spectrum intravenous antibiotics
(B) Further increase in immunosuppression
(C) Intravenous ganciclovir
(D) Plasmapheresis
(E) Reduction of immunosuppression

Answer: (E) Reduction of immunosuppression

Rationale:
This scenario likely represents post-transplant lymphoproliferative disease (PTLD), which complicates up to 15% of solid organ transplants. PTLD represents a spectrum of disease that ranges from an indolent, EBV-positive polyclonal lymphoproliferation that is usually seen early post-transplant and often resolves with reduction of immunosuppression, to a malignant and aggressive lymphoma that is rapidly fatal without combination chemotherapy. PTLD has myriad presentations but often presents with fever, lymphadenopathy, pharyngitis, fatigue, weight loss, sweat, and/or allograft dysfunction. It may occur at any time after transplantation; however, the risk appears to be greatest within the first year post-transplantation, with a median time to presentation of 6 months. Empiric treatment of allograft dysfunction as acute rejection may actually lead to worsened allograft function and worsening of PTLD, so careful workup is required. A variety of treatment paradigms for PTLD have been proposed, most of which are poorly studied. It is generally accepted that first-line treatment is the reduction of immunosuppression. Surgical excision and/or radiation therapy can also be used for localized disease. Prompt recognition and treatment is imperative because mortality rates have been reported to be as high as 70%.

References:
Gottschalk S, Rooney CM, Heslop HE. Post-transplant lymphoproliferative disorders. *Annu Rev Med.* 2005;56:29–44.
Tsai DE, Loren AW. Post-transplant lymphoproliferative disorder. *Clin Chest Med.* 2005;26:631–645.

2B28

Key word: Treatment of Bleeding Associated with Clopidogrel

Author: Babak J. Orandi, MD, MSc
Editor: Ying Wei Lum, MD

A 64-year-old woman undergoes an emergent cardiac catheterization for unstable angina. She is given 300 mg of clopidogrel before the procedure; however, the cardiologist is unable to revascularize a near-total obstructing lesion of the left anterior descending artery. The patient is therefore referred for emergent coronary artery bypass grafting. Postoperatively she has high-volume sanguinous output from her chest tube. The most appropriate treatment for the correction of clopidogrel-associated coagulopathy is:

(A) Administration of cryoprecipitate
(B) Administration of desmopressin
(C) Administration of protamine
(D) Transfusion of fresh frozen plasma
(E) Transfusion of platelets

Answer: (E) Transfusion of platelets

Rationale:
Clopidogrel exerts its antiplatelet activity by inhibiting ADP from binding to receptors on the platelets, thereby inhibiting platelet aggregation. This inhibition is irreversible, which is why patients are urged to cease taking clopidogrel 5 to 7 days prior to any elective operation. However, in a variety of urgent and emergent clinical settings, (including the care of vasculopathic patients), that luxury is not available. The only way to overcome this coagulopathy is through the transfusion of platelets as there is no antidote. Patients who are taking clopidogrel have been shown to have significantly more bleeding, require more blood transfusions, and have longer hospitalizations following coronary artery bypass grafting.

Fresh frozen plasma contains all coagulation factors and is used most often in the surgical setting to treat dilutional coagulopathy or to correct warfarin-induced coagulopathy. Cryoprecipitate contains Factors VIII and XIII, fibrinogen, and von Willebrand factor and is used to treat patients who are deficient in fibrinogen and Factor XIII. Protamine is used to reverse the effects of heparin. Desmopressin causes the release of von Willebrand factor and Factor VIII and is used in the treatment of von Willebrand deficiency and Factor VIII deficiency.

References:
Chen L, Bracey AW, Radovancevic R, et al. Clopidogrel and bleeding in patients undergoing elective coronary artery bypass grafting. *J Thorac Cardiovasc Surg.* 2004;128:425–431.
Leong JY, Baker RA, Shah PJ, et al. Clopidogrel and bleeding after coronary artery bypass graft surgery. *Ann Thorac Surg.* 2005;80:928–933.

۰۲۱-۶۶۱۹۸۵۱۴ www.myuptodate.com دریافت آخرین نسخه آپتودیت آفلاین

Streiff MB. Coagulopathy in the critically ill patient. In: Cameron JL, ed. *Current Surgical Therapy.* 9th ed. Philadelphia, PA: Mosby Elsevier; 2008: 1245–1257.

The Clopidogrel in Unstable Angina to Prevent Recurrent Events Trial Investigators. Effects of clopidogrel in addition to aspirin in patients with acute coronary syndromes without ST-segment elevation. *New Engl J Med.* 2001;345:494–502.

2B29

Key word: Treatment of Complications of Femoral Nerve Block

Author: Raja Mohan, MD
Editor: Bradford D. Winters, MD, PhD

A femoral nerve block is performed in preparation for a total knee arthroplasty in a 55-year-old man. Five minutes after injecting the anesthetic, a large mass has emerged in the groin. What is the next step in the management of this patient?

Ⓐ Apply compression

Ⓑ Exploration of groin

Ⓒ Needle aspiration

Ⓓ Observation

Ⓔ Ultrasound

Answer: (A) Apply compression

Rationale:

Peripheral nerve blocks are safe and effective techniques used to provide regional anesthesia for a variety of surgical procedures. Complications are rare but can be devastating and include nerve injury, hematoma formation, infection, block failure, inadvertent intravascular injection, and allergic reaction to the local anesthetic.

Needle-induced complications, such as hematoma formation, are possible due to the close relationship between the femoral nerve and femoral vessels. The formation of a hematoma can compress the femoral nerve and significantly injure it. In addition, the hematoma can extend to the retroperitoneal space, a complication difficult to identify based on outward appearance or clinical examination alone. Femoral artery cannulation can also cause a pseudoaneurysm, which can be diagnosed with ultrasound. In the initial stage following a likely vascular injury, it is prudent to apply compression to control any additional bleeding, after which additional diagnostic studies may be performed as necessary. Surgical intervention is necessary only if conservative measures fail or vascular compromise ensues.

Reference:

Auyong DB, Tokeshi J, Joshi S, et al. Recognition of an incidental abscess and a hematoma during ultrasound-guided femoral nerve block. *Reg Anesth Pain Med.* 2011;36(4): 406–409.

۰۲۱-۶۶۱۹۸۵۱۴ www.myuptodate.com دریافت آخرین نسخه آپتودیت آفلاین

2B30

Key word: Treatment of Fournier Gangrene

Author: Emmanouil Pappou, MD
Editor: Mohamad E. Allaf, MD

A 68-year-old man with diabetes mellitus presents with 3 days of progressive pain and swelling of his scrotum. On examination, he has diffuse erythema, edema, and severe tenderness of his scrotum and perineal area. His white blood count is 22,000/mm^3, and his glucose is 284 mg/dL. Ultrasonography was limited because of tenderness but showed increased echogenicity of the skin and subcutaneous tissues. Computed tomography (CT) of the pelvis revealed a markedly enlarged scrotal sac containing foci of gas extending to the perineum and subcutaneous tissues of the gluteal region. The most appropriate next step in management of this disease is:

(A) Aggressive surgical debridement

(B) Application of topical antimicrobial cream

(C) High-dose intravenous steroids

(D) Hyperbaric oxygenation

(E) Observation and serial CT scans

Answer: **(A)** Aggressive surgical debridement

Rationale:

This patient has a classic presentation of Fournier gangrene, which is defined as an aggressive necrotizing fasciitis that includes the genital, perineal, and/or perianal regions. Fournier gangrene is most commonly found in middle-aged men and is much less common in women and children. The average age at presentation is 55 to 65 years and the male-to-female ratio is 10:1. Fournier gangrene is commonly associated with diabetes (30% to 60%) and alcoholism (25% to 65%). Other important risk factors include immunosuppression, chemotherapy, leukemia, and HIV infection. A colorectal (perirectal abscess, diverticulitis, appendicitis, colon cancer, etc.), dermatologic (local infection, trauma, etc.), or urinary (stone, urethral stricture, etc.) source of infection is found after careful investigation in 75% to 90% of cases.

Fournier gangrene tends to be a polymicrobial infection caused by virulent organisms such as *Escherichia coli* and various species of Bacteroides, Staphylococcus, Enterococcus, Clostridium, and Streptococcus. Patients typically present with genital pain, swelling, and erythema frequently accompanied by fever and leukocytosis. Crepitus and gangrene of the genital area may also develop. Although the diagnosis of Fournier gangrene is made primarily clinically, ultrasonography, CT, or magnetic resonance imaging may help to confirm the diagnosis, define the extent of disease, or identify the underlying cause. Surgical debridement should not be delayed, however, in order to obtain these studies.

Treatment includes prompt and aggressive surgical debridement, fluid resuscitation, and empiric broad-spectrum intravenous antibiotics (e.g., piperacillin–tazobactam or clindamycin and metronidazole). The aim of surgery is to resect all infected and necrotic tissues. Multiple surgical debridements may be necessary in order to completely remove the source of infection. Hyperbaric oxygen has also been used as adjuvant therapy with promising but not widely accepted results. Hyperbaric oxygen therapy may decrease length of stay, increase wound healing, and decrease the spread of infection, but its use is currently limited to centers with available facilities for hyperbaric oxygenation. Even with optimal therapy, mortality is approximately 20% to 40% in patients with Fournier gangrene.

References:

Eke N. Fournier's gangrene: a review of 1726 cases. *Br J Surg.* 2000;87(6):718–728.

Levenson RB, Singh AK, Novelline RA. Fournier gangrene: role of imaging. *Radiographics.* 2008;28(2):519–528.

Safioleas M, Stamatakos M, Mouzopoulos G, et al. Fournier's gangrene: exists and it is still lethal. *Int Urol Nephrol.* 2006; 38(3–4):653–657.

۰۲۱-۶۶۱۹۸۵۱۴ www.myuptodate.com دریافت آخرین نسخه آپتودیت آفلاین

2B31

Key word: Treatment of Heparin-induced Thrombocytopenia

Author: Timothy J. George, MD
Editor: Elliott R. Haut, MD, FACS

A 65-year-old male is given standard prophylactic doses of subcutaneous heparin and intravenous cefotetan prior to a right hemicolectomy and is continued on prophylactic subcutaneous heparin postoperatively. On postoperative day 6, he is noted to have asymmetric left leg swelling, and his platelets haven fallen from 353,000/μL the previous day to 90,000/μL. The best next step is:

(A) Discontinue all heparin products and transfuse platelets

(B) Discontinue all heparin products, send a platelet factor 4 assay, and begin anticoagulation with a direct thrombin inhibitor

(C) Discontinue all medications and proceed with allergy testing

(D) Discontinue all standard heparin and place the patient on low-molecular-weight heparin

(E) Obtain a lower extremity duplex to confirm deep vein thrombosis and begin a heparin drip

Answer: **(B)** Discontinue all heparin products, send a platelet factor 4 assay, and begin anticoagulation with a direct thrombin inhibitor

Rationale:

Heparin-induced thrombocytopenia (HIT) has two forms. HIT-II is immune mediated and caused by formation of antibodies to heparin–platelet factor 4 complex. HIT-I is a milder, nonimmune form in which platelet counts decrease following heparin administration but will rebound despite continued heparin therapy. HIT-II occurs in 0.2% to 5% of patients exposed to heparin. It is characterized by a decrease in the platelet count by >50% usually 5 to 10 days after the initiation of heparin therapy. The thrombocytopenia can be accompanied by thrombosis. Lower extremity deep vein thrombosis and resulting pulmonary emboli are common sequelae.

Diagnosis of HIT requires a high index of suspicion. Currently the best test is an ELISA assay for platelet factor 4. When HIT is suspected, all heparin products should be discontinued. Although low-molecular-weight heparins are associated with a lower incidence of HIT, once HIT is suspected they should also be discontinued because of possible cross-reactivity. Given the possibility of forming an associated thrombosis, patients with HIT should be anticoagulated with a direct thrombin inhibitor.

Bivalirudin and argatroban are direct thrombin inhibitors administered intravenously for patients with HIT. Bivalirudin is excreted via the kidneys, so dosage must be reduced in patients with renal insufficiency. Argatroban undergoes hepatobiliary excretion, and therefore dose adjustments are not needed for patients with renal sufficiency (but are needed for those with liver impairment). Platelet transfusions are generally contraindicated in HIT because of the risk for thrombosis.

References:

Kelton JG. The clinical management of heparin-induced thrombocytopenia. *Semin Hematol.* 1999;36(1 Suppl 1): 17–21.

Warkentin TE. Heparin-induced thrombocytopenia: pathogenesis and management. *B J Haematol.* 2003;121:535–555.

۰۲۱-۶۶۱۹۸۵۱۴ www.myuptodate.com دریافت آخرین نسخه آپتودیت آفلاین

2B32

Key word: Treatment of Hyponatremia in Cirrhosis

Author: Said C. Azoury, MD
Editor: Andrew M. Cameron, MD, PhD

A 45-year-old gentleman with past medical history significant for hepatitis C with end-stage cirrhosis and ascites is admitted to the intensive care unit with pneumonia. On morning rounds, the patient's serum sodium is 128 mEq/L without encephalopathy or mental status changes. The most appropriate next step is to:

(A) Administer a vasopressin antagonist

(B) Correct serum sodium to normal range at a rate of 20 mEq/L in the first 24 hours

(C) Immediately initiate hypertonic saline fluid bolus followed by aggressive diuresis once a normal serum level has been reached

(D) No intervention is warranted as the patient is asymptomatic

(E) Perform a therapeutic paracentesis to help correct the dilutional hyponatremia

Answer: (D) No intervention is warranted as the patient is asymptomatic

Rationale:

Hypervolemic hyponatremia is a common problem in patients with advanced cirrhosis due to sequestration of circulating volume in the splanchnic circulation secondary to vasodilation. This fluid sequestration leads to renal hypoperfusion, which stimulates both the renin–angiotensin–aldosterone axis and the secretion of antidiuretic hormone (ADH) (vasopressin), which in turn causes water retention and a fall in serum sodium. The severity of hyponatremia is directly proportional to the severity of cirrhosis.

Hyponatremia in these patients develops slowly and usually produces no obvious clinical manifestations until the serum sodium concentration falls below 120 mEq/L. The correction of hyponatremia above this level has no effect on hemodynamic changes and does not improve morbidity or mortality. The main indications for treatment are the development of neurologic symptoms and a serum sodium less than 120 mEq/L. The major options to achieve a sustained increase in serum sodium are fluid restriction and ADH receptor antagonists. Free water restriction is onerous for most patients and has only modest effects on serum sodium; ADH antagonists are expensive and must be administered as an inpatient. Paracentesis can decrease ascites but may not change any of the underlying physiologic mechanisms driving the hyponatremia.

Overly rapid correction of serum sodium should be avoided, and the rate of correction should be less than 10 mEq/hr in the first 24 hours and less than 18 mEq/hr during the first 48 hours. Overly rapid correction can lead to osmotic demyelination syndrome (central pontine myelinolysis). There is no reason to assume a patient has suffered a demyelination neurologic injury if attempts have not been made to replete the sodium.

References:

Angeli P, Wong F, Watzon H, et al. Hyponatremia in cirrhosis: results of a patient population survey. *Hepatology.* 2006;44: 1535–1542.

Gines P, Guevara M. Hyponatremia in cirrhosis: pathogenesis, clinical significance and management. *Hepatology.* 2008;48: 1002–1010.

۰۲۱-۶۶۱۹۸۵۱۴ www.myuptodate.com دریافت آخرین نسخه آپتودیت آفلاین

2B33

Key word: Treatment of Intraoperative Bradycardia

Author: Emmanouil Pappou, MD
Editor: Asad Latif, MBBS, MPH

A 37-year-old woman with an otherwise unremarkable medical history undergoes an elective laparoscopic cholecystectomy for symptomatic cholelithiasis. Her preoperative blood pressure is 135/82 mm Hg and her pulse is 75 beats per minute. In the operating room, a combination of propofol, fentanyl, and mivacurium are used for induction, and sevoflurane is used for maintenance of anesthesia. After confirming the position of the Veress needle, the abdomen is insufflated with carbon dioxide gas at a flow of 15 L/min. Suddenly, the patient's pulse drops to 42 beats per minute. Repeat blood pressure is 82/45 mm Hg, and her end-tidal carbon dioxide level remains unchanged. The most appropriate next step is:

(A) Administration of 0.5 mg of intravenous physostigmine

(B) Administration of 4 mg of intravenous atropine

(C) Administration of a 500 mL bolus of normal saline

(D) Reduction of gas flow to 5 L/min and observation

(E) Release of abdominal insufflation

Answer: **(E)** Release of abdominal insufflation

Rationale:

Bradycardia is one of the most common cardiac arrhythmias observed in the intraoperative period. The incidence of bradycardia during laparoscopic cholecystectomy has been estimated to be approximately 0.5% to 5%. It can occur even in low-risk patients undergoing a laparoscopic cholecystectomy, and no association between the occurrence of bradycardia and American Society of Anesthesiologists (ASA) status has been observed.

Most bradycardic episodes occurring during insufflation are reversible and respond to immediate deflation of the pneumoperitoneum, discontinuation of the anesthetic agent, administration of 100% oxygen with manual ventilation, placement of the patient in the supine position, and administration of a cholinergic agent such as atropine or glycopyrrolate. The usual dosage of intravenous atropine for symptomatic bradycardia is 0.5 to 1 mg, which may be repeated every 3 to 5 minutes up to a maximum dose of 3 mg.

After rapid assessment of ABC's and deflation of the pneumoperitoneum, intravenous fluid boluses and vasopressors (e.g., ephedrine, epinephrine) are acceptable treatment options when hypotension is persistent or severe. Physostigmine is a parasympathomimetic agent and its administration can lead to bradycardia. It is important to note that gas embolization, a dreaded complication of laparoscopic surgery may also present with bradycardia and hypotension, but a significant decrease in the end-tidal carbon dioxide level is typically seen when this complication occurs.

References:

Reed DN Jr, Duff JL. Persistent occurrence of bradycardia during laparoscopic cholecystectomies in low-risk patients. *Dig Surg.* 2000;17(5):513–517.

Reed DN Jr, Nourse P. Untoward cardiac changes during CO2 insufflation in laparoscopic cholecystectomies in low-risk patients. *J Laparoendosc Adv Surg Tech A.* 1998; 8(2):109–114.

Watterson LM, Morris RW, Westhorpe RN, et al. Crisis management during anaesthesia: bradycardia. *Qual Saf Health Care.* 2005;14(3):e9.

۰۲۱-۶۶۱۹۸۵۱۴ www.myuptodate.com دریافت آخرین نسخه آپتودیت آفلاین

2B34

Key word: Hemodynamics of Massive Pulmonary Embolism

Author: Lisa M. Kodadek, MD
Editor: Glenn J.R. Whitman, MD

A 54-year-old woman with body mass index of 35 is postoperative day 5 from a right hemicolectomy for colon adenocarcinoma. She suddenly develops tachycardia, acute chest pain, and shortness of breath. She is most likely to manifest which of the following hemodynamic changes?

	Cardiac Output	Vascular Resistance	Myocardial Oxygen Consumption	Right Heart Filling Pressure
(A)	⇓	⇓	⇔	⇓
(B)	⇑	⇓	⇑	⇔
(C)	⇓	⇑	⇑	⇑
(D)	⇓	⇑	⇓	⇓
(E)	⇓	⇑	⇓	⇑

Answer: (E)

Cardiac Output	Vascular Resistance	Myocardial Oxygen Consumption	Right Heart Filling Pressure
⇓	⇑	⇓	⇑

Rationale:

Acute pulmonary embolism is a common cause of obstructive shock among surgical patients. Obstructive shock is associated with decreased cardiac output, increased vascular resistance, decreased myocardial oxygen consumption, and increased right heart filling pressure. Answer **(A)** is typical of spinal shock. Answer **(B)** is typical of early sepsis. Answer **(C)** is not a common pattern of hemodynamic findings. Answer **(D)** is typical of hypovolemic shock.

Risk factors for pulmonary embolism include high body mass index; malignancy; cigarette smoking; hypertension; surgery; and hypercoagulopathy such as Factor V Leiden mutation, hyperhomocysteinemia, and lupus anticoagulant. Clinical presentation may include anxiety, dyspnea, tachypnea, hypotension, hemoptysis, chest pain, or sudden death.

References:

Cuschieri J. Shock. In: Mulholland MW, Lillemoe KD, Doherty GM, Maier RV, Upchurch GR, eds. *Greenfield's Surgery: Scientific Principles and Practice.* 5th ed. Philadelphia, PA: Lippincott Williams and Wilkins; 2011.

Smythe WR, Reznik SI, Putnam JB. Lung (including pulmonary embolism and thoracic outlet syndrome). In: Townsend CM, Beauchamp RD, Evers MB, Mattox KL, eds. *Sabiston Textbook of Surgery.* 18th ed. Philadelphia, PA: Elsevier Saunders; 2008:1743–1745.

2B35

Key word: Treatment of Myocardial Infarction

Author: Vicente Valero III, MD
Editor: Glenn J.R. Whitman, MD

A 54-year-old female with a history of hypercholesterolemia and hypertension presents to the emergency room with new onset substernal chest pain. Her vital signs are within normal limits. An electrocardiogram shows ST-segment elevation in the anterolateral leads, and laboratory evaluation demonstrates an elevated troponin level. She receives an aspirin, beta-blocker, and sublingual nitroglycerin. Oxygen is given via nasal cannula, and morphine is administered for pain control. What is the best next step in the management of this patient?

(A) Cardiac catheterization
(B) Coronary artery bypass graft
(C) Echocardiogram
(D) Repeat EKG in 2 hours
(E) Systemic administration of a thrombolytic agent

Answer: **(A)** Cardiac catheterization

Rationale:

ST-segment elevation myocardial infarction (STEMI) is considered a medical emergency and must be treated expeditiously. It is caused by a ruptured plaque in the coronary arteries, which leads to an occluding thrombus. STEMI criteria requires angina lasting more than 30 minutes plus ST-segment elevation of >1 mm in two consecutive ECG leads along with an elevation of serum troponin. It can be accompanied by diaphoresis, dyspnea, palpitations, nausea, or syncope. These patients must be treated with standard medical therapy and taken immediately to the coronary catheterization laboratory. The goal is to have a "door to balloon" time of less than 90 minutes. Standard medical therapy involves maximizing oxygen delivery with supplemental oxygen. A chewable aspirin should be given immediately, and systemic anticoagulation with a heparin drip should be instituted as soon as possible. In the absence of hypotension, nitroglycerin should be given to decrease preload. Beta blockade should be commenced as it has been shown to decrease infarct size by blocking the catecholamine surge. Morphine also decreases the catecholamine surge, preload, and pain.

Reference:

Kates A, Zajarias A, Goldberg A. Ischemic heart disease. In: Cooper DH, Krainik AJ, Lubner SJ, Micek ST, Reno HEL, eds. *Washington Manual of Medical Therapeutics.* 32nd ed. Philadelphia, PA: Lippincott Williams & Wilkins; 2007: 119–166.

۰۲۱-۶۶۱۹۸۵۱۴ www.myuptodate.com دریافت آخرین نسخه آپتودیت آفلاین

2B36

Key word: Treatment of Oxycodone Toxicity

Author: Kyle J. Van Arendonk, MD, PhD
Editor: Asad Latif, MBBS, MPH

A 78-year-old woman admitted to the hospital after an uneventful laparoscopic cholecystectomy is given oxycodone for pain control. She continues to complain of pain overnight and is given multiple doses of hydromorphone to help her rest. The surgical team finds her lethargic in the morning and notes a respiratory rate of 8 breaths per minute. Which of the following is true of the opioid antagonist that should be given to this patient?

(A) A continuous infusion should never be used

(B) A slow onset of action is expected

(C) Severe pain can result with its use

(D) The drug provides selective reversal of respiratory depression without reversing other opioid effects

(E) The medication is a mixed agonist–antagonist at opioid receptors

Answer: (C) Severe pain can result with its use

Rationale:

Oxycodone, like other opioids in clinical use, acts primarily as an agonist at mu opioid receptors in order to provide analgesia. All opioids can cause dose-dependent respiratory depression. Other common opioid side effects are nausea, constipation, and drowsiness. Opioid overdose can result in profound respiratory depression. The treatment consists of administration of an opioid antagonist, most commonly naloxone. Naltrexone, a long-acting oral agent, is also available. These drugs are competitive inhibitors of opioid agonists and have relatively universal antagonist effects at all opioid receptors, meaning that all opioid effects will be reversed rather than selective ones like respiratory depression. Severe pain can therefore result in postoperative patients if these antagonists are not administered carefully, and opioid withdrawal can also result in patients with chronic opioid use or opioid dependence.

Naloxone has a fast onset of action and a short half-life and therefore can easily be titrated with incremental doses to achieve the desired effects (i.e., improved ventilation without complete reversal of analgesia). In cases of long-acting opioid overdose, naloxone infusions can be helpful to prevent recurrence of respiratory depression.

Reference:

Coda BA. Opioids. In: Barash PG, Cullen BF, Stoelting RK, Cahalan MK, Stock MC, eds. *Clinical Anesthesia.* 6th ed. Philadelphia, PA: Lippincott Williams & Wilkins; 2009: 465–497.

2B37

Key word: Treatment of von Willebrand Disease

Author: Said C. Azoury, MD
Editor: Nicole M. Chandler, MD

A 45-year-old female is being evaluated for a pancreatic cystic neoplasm. History reveals heavy menses and prolonged bleeding after childbirth, and on laboratory analysis she has an isolated prolonged partial thromboplastin time (PTT). Upon further questioning she states that she has a family member with Type I von Willebrand disease. What is the most appropriate treatment for this patient prior to undergoing a major operation to remove her pancreatic mass?

(A) Administration of high-dose IVIG prior to surgery, followed by treatment with desmopressin (DDAVP) thereafter

(B) Intravenous or intranasal DDAVP at the time of surgery

(C) No need for treatment as long as the patient is clinically stable and if laboratory monitoring of von Willebrand factor (vWF) is normal

(D) Treatment with Factor VIII:vWF concentrate with close monitoring of vWF ristocetin cofactor activity levels

(E) Treatment with fresh frozen plasma and close monitoring of PTT and bleeding time

Answer: (D) Treatment with Factor VIII:vWF concentrate with close monitoring of vWF ristocetin cofactor activity levels

Rationale:

von Willebrand disease is the most common congenital bleeding disorder and results from deficient or defective vWF. vWF is needed for hemostasis in combination with Factor VIII and links the GPlb receptor on platelets to collagen. Prothrombin time (PT) is generally normal, while PTT can be prolonged.

Type I disease is the most common (70% of cases), and Type III causes the most severe bleeding. Types I and II are autosomal dominant, whereas Type III is autosomal recessive. Types I and III usually result in reduced quantity of circulating vWF (often entirely absent in Type III). Type I disease can be treated with recombinant Factor VIII:vWF, cryoprecipitate, DDAVP, or conjugated estrogens. Type III disease requires Factor VIII:vWF or cryoprecipitate. Type II is actually a defect in the vWF molecule itself, so the patient has enough vWF, but it does not function correctly. Type II is treated with recombinant Factor VIII:vWF or cryoprecipitate.

Intravenous or intranasal DDAVP is generally recommended in patients with type I disease as initial treatment of minor bleeding or at the time of minor surgery in those who have shown a prior response. Bleeding should be followed clinically and with laboratory monitoring. Factor VIII:vWF concentrate can be used if the patient continues to have bleeding. This treatment can be supplemented with antifibrinolytic and/or topical therapies.

۰۲۱-۶۶۱۹۸۵۱۴ www.myuptodate.com دریافت آخرین نسخه آپتودیت آفلاین

For major surgeries, such as a Whipple procedure, vWF:Factor VIII concentrate is favored over DDAVP, and the optimal levels of vWF ristocetin cofactor activity and Factor VIII levels should be 100 International Units/dL during the operation and then maintained above 50 International Units/dL for 7 to 14 days or more as needed. Patients should undergo a loading dose of 40 to 60 Units/kg and then daily doses of 20 to 40 Units/kg in order to achieve these levels. Patients should be hospitalized at a location where expertise in management is available. High-dose IVIG is mainly used if DDAVP treatment fails or in patients with acquired antibody-mediated von Willebrand disease.

References:

Nichols WL, Hultin MB, James AH, et al. von Willebrand disease (VWD): evidence-based diagnosis and management guidelines, the National Heart, Lung, and Blood Institute (NHLBI) Expert Panel report (USA). *Haemophilia.* 2008;14(2):171–232.

The National Heart, Lung, and Blood Institute. *The Evaluation and Management of Von Willebrand Disease.* Bethesda, M.D.: National Institutes of Health. NIH Publication No. 08-5832; 2007. Available at http://www.nhlbi.nih.gov/guidelines/vwd/vwd.pdf

2B38

Key word: Staging of Soft Tissue Sarcoma

Author: Emmanouil Pappou, MD
Editor: Mehran Habibi, MD, MBA

A 45-year-old woman with no history of trauma or bleeding disorders presents with a 4-month history of a slow-growing mass in her left buttock. A nontender, immobile mass is palpated in the left buttock; no palpable lymphadenopathy is present. Laboratory values are within normal limits, and computed tomography (CT) and magnetic resonance imaging (MRI) show a large intramuscular mass measuring 14 × 13 × 12 cm in the gluteus maximus, with heterogeneous contrast enhancement. A core-needle biopsy reveals a high-grade malignant fibrous histiocytoma. The most appropriate next step for adequate staging of this malignancy is:

(A) Bone scan

(B) CT of the abdomen and pelvis

(C) CT of the chest

(D) CT of the head

(E) No further tests for staging are necessary

Answer: (C) CT of the chest

Rationale:

Soft tissue sarcomas (STS) are a group of anatomically and histologically diverse tumors of extraskeletal mesenchymal origin, grouped together because of shared biologic characteristics and treatment responses. They account for about 1% of adult malignancies, and approximately 9,000 to 12,000 cases of STS are reported annually in the United States, leading to 3,000 to 4,000 annual deaths. About 50% of patients diagnosed with sarcoma eventually die of the disease.

No identifiable etiology is found in most cases, but a variety of factors have been identified to predispose or be associated with sarcomas. Genetic predisposition confers a substantial risk. Li–Fraumeni syndrome, caused by a germline mutation in *p53,* and hereditary retinoblastoma, caused by a germline mutation in the *Rb* gene, are associated with a significant risk for STS. Type 1 neurofibromatosis and familial adenomatous polyposis/Gardner syndrome are also associated with the development of STS. Past treatment with radiation therapy—most commonly for breast, head and neck cancer, and lymphoma—may also lead to STS after an average of 11 to 13 years. Lymphedema, due to lymphadenectomy (Stewart–Treves syndrome), filariasis, or a hereditary abnormality of the lymphatic ducts (e.g., congenital lymphedema), has also been linked to the development of lymphangiosarcoma. Finally, human immunodeficiency virus and human herpes virus 8 have been implicated in the pathogenesis of Kaposi sarcoma.

STS can occur at any site throughout the body, but almost 50% of them are found in the lower limb, particularly in the buttock or thigh. They most commonly present as a gradually enlarging mass, which is painless in about two-thirds of patients. A history of recent trauma at the site is often given, but there is no evidence that trauma actually causes the

۰۲۱-۶۶۱۹۸۵۱۴ www.myuptodate.com دریافت آخرین نسخه آپتودیت آفلاین

malignant change; rather, trauma is thought to merely draw attention to a pre-existing condition. The common differential diagnoses of a benign soft tissue mass, namely hematoma or muscle injury, frequently result in diagnostic delays.

Any mass that is larger than 5 cm, located deep to the muscle fascia, rapidly enlarging, or persisting for more than 4 weeks should lead one to suspect sarcoma. Various radiologic techniques are used to investigate a soft tissue mass, including plain films, CT, MRI, and positron emission tomography (PET). Over recent years, MRI has become the preferred imaging technique for sarcomas in the United States because it provides good definition of fascial planes and the contrast between the tumor and surrounding structures is sharper. However, there is conflicting evidence as to whether MRI provides additional clinically useful information compared to CT. In most cases, both studies are performed. CT is still the most commonly used imaging technique for retroperitoneal sarcomas. PET and PET–CT are not routinely performed for workup of a sarcoma but may be useful in detecting local recurrence or metastatic disease and in determining response to chemotherapy.

Histologic examination is the gold standard for diagnosis of STS and an essential part of treatment planning. Small masses (<3 cm) can be safely removed with an excisional biopsy. For larger masses (>3 cm), a core-needle or incisional biopsy is indicated. Biopsy should ideally be performed after an MRI has been obtained to prevent misinterpretation of biopsy-related changes. Core-needle biopsy has minimal complications and provides a 97% accuracy in diagnosing malignancy and an 86% to 90% accuracy in determining histologic type and grade of STS. If open biopsy is needed, it is important that the incision be placed longitudinally along the extremity so that it can be resected along with the tumor at the time of definitive surgical resection. FNA is *not* recommended in the initial diagnostic evaluation as it has a lower diagnostic accuracy than core-needle biopsy. More than 50 different histologic types of STS have been described. Malignant fibrous histiocytoma, liposarcoma, and leiomyosarcoma constitute the majority of adult STS.

Accurate assessment of the extent of disease is important to plan appropriate therapy. Sarcomas mainly metastasize to the lung via hematogenous spread. Chest imaging is therefore essential for all patients with STS. Chest x-ray is adequate for small (<5 cm) low-grade tumors, whereas patients with high-grade, deep-seated, or large tumors (>5 cm) need a chest CT. Round cell/myxoid liposarcomas commonly metastasize to the abdomen/retroperitoneum without any involvement of the lung, and a CT of the abdomen and pelvis is therefore recommended for this type of STS. In addition, angiosarcomas have a high propensity for brain metastases, and a CT of the head is recommended as part of their preoperative workup. Retroperitoneal sarcomas spread to both liver and lungs, thus making a CT of the chest, abdomen, and pelvis necessary for their staging. Lymph node metastases occur in <5% of adults with STS. A higher rate of about 10% to 40% is seen in patients with angiosarcoma, rhabdomyosarcoma, clear cell, epithelioid, or synovial cell sarcoma. Radical lymphadenectomy is therefore an integral part of the therapeutic plan for these specific subtypes of STS.

Staging of STS is usually based on the AJCC system (Table "Staging of Colorectal Cancer"), which uses five descriptors, namely tumor size **(T)**, depth (superficial or deep), lymph node involvement **(N)**, distant metastasis **(M)**, and histologic grade **(G)**. The most important prognostic factors are histologic grade and tumor size, but other factors including site, age, and histologic subtype influence prognosis as well. A postoperative nomogram from Memorial Sloan–Kettering Cancer Center reliably predicts 12-year sarcoma-specific death.

STS require a multimodality therapeutic approach. Complete surgical resection with microscopically negative margins (R0) is the cornerstone of therapy. Preoperative or postoperative radiation therapy may decrease risk for recurrence. The benefit of neoadjuvant or adjuvant chemotherapy following optimal local therapy remains uncertain.

New Staging System for GIST and Soft-tissue Sarcoma

7th Edition AJCC Soft-tissue Sarcoma Staging System

Primary Tumor (T)	
TX	Primary tumor cannot be assessed
T0	No evidence of primary tumor
T1	Tumor ≤5 cm in greatest dimension
	T1a Tumor above superficial fascia
	T1b Tumor invading or deep to superficial fascia
T2	Tumor >5 cm in greatest dimension
	T2a Tumor above superficial fascia
	T2b Tumor invading or deep to superficial fascia
Regional Lymph Nodes (N)	
NX	Regional lymph nodes cannot be assessed
N0	No regional lymph node metastasis
N1	Regional lymph node metastasis
Distant Metastasis (M)	
MX	Distant metastasis cannot be assessed
M0	No distant metastasis
M1	Distant metastasis

(*continued*)

۰۲۱-۶۶۱۹۸۵۱۴ www.myuptodate.com دریافت آخرین نسخه آپتودیت آفلاین

New Staging System for GIST and Soft-tissue Sarcoma (*Continued*)

7th Edition AJCC Soft-tissue Sarcoma Staging System	
Histopathological Grade (G)	
GX	Grade cannot be assessed
G1	Grade 1
G2	Grade 2
G3	Grade 3
Stage Grouping	
Stage I	
A	T1a N0 M0 G1, Gx
	T1b N0 M0 G1, Gx
B	T2a N0 M0 G1, Gx
	T2b N0 M0 G1, Gx
Stage II	
A	T1a N0 M0 G2, G3
	T1b N0 M0 G2, G3
B	T2a N0 M0 G2
	T2b N0 M0 G2
Stage III	T2a, T2b N0 M0 G3
	Any T N1 M0 Any G
Stage IV	Any T Any N M1 Any G
7th Edition AJCC GIST Staging System	
Primary Tumor (T)	
Tx	Primary tumor cannot be assessed
T0	No evidence of primary tumor
T1	Tumor ≤2 cm
T2	Tumor >2 cm but ≤5 cm
T3	Tumor >5 cm but ≤10 cm
T4	Tumor >10 cm
Regional Lymph Nodes (N)	
Nx	Regional lymph nodes cannot be assessed
N0	No regional lymph node metastasis
N1	Regional lymph node metastasis
Distant Metastasis (M)	
M0	No distant metastasis
M1	Distant metastasis
Stage Grouping—*Gastric GIST*	
Stage I	
A	T1 or T2 N0 M0 Low mitotic rate
B	T3 N0 M0 Low mitotic rate
Stage II	T1, T2 N0 M0 High mitotic rate
	T4 N0 M0 Low mitotic rate
Stage III	
A	T3 N0 M0 High mitotic rate
B	T4 N0 M0 High mitotic rate
Stage IV	Any T N1 M0 Any Rate
	Any T Any N M1 Any Rate
Stage Grouping—*Small Intestinal GIST*	
Stage I	T1 or T2 N0 M0 Low mitotic rate
Stage II	T3 N0 M0 Low mitotic rate
Stage III	
A	T1 N0 M0 High mitotic rate
	T4 N0 M0 Low mitotic rate
B	T2, T3, T4 N0 M0 High mitotic rate
Stage IV	Any T N1 M0 Any rate
	Any T Any N M1 Any rate

Adapted from: Edge SB, Byrd DR, Compton CC, eds. *AJCC Cancer Staging Manual.* 7th ed. New York, NY: Springer, 2010.

۰۲۱-۶۶۱۹۸۵۱۴ www.myuptodate.com دریافت آخرین نسخه آپتودیت آفلاین

References:
Brennan MF. Soft tissue sarcoma: advances in understanding and management. *Surgeon.* 2005;3(3):216–223.
Caudle AS, Delman KA, Cormier JN. Soft-tissue and bone sarcoma. In: Feig BW, Ching CD, eds. *The M.D. Anderson Surgical Oncology Handbook.* 5th ed. Philadelphia, PA: Lippincott Williams and Wilkins; 2012.
Grobmyer SR, Brennan MF. Treatment of retroperitoneal sarcomas. *Adv Surg.* 2004;38:13–29.
Hueman MT, Thornton K, Herman JM, et al. Management of extremity soft tissue sarcomas. *Surg Clin North Am.* 2008; 88(3):539–557, vi.

2B39

Key word: Technique of Component Separation for Ventral Hernia Repair

Author: Jens U. Berli, MD
Editor: Anthony P. Tufaro, DDS, MD, FACS

You evaluate a 42-year-old patient who presents to you 6 months after a complex abdominal operation that resulted in a prolonged open abdomen that was left to granulate in over a piece of synthetic absorbable mesh, with a resultant abdominal wall hernia. He now presents for definitive repair of his large ventral hernia. You decide that he is a good candidate for a ventral hernia repair with component separation. What are the key steps to this repair?

(A) Excise the mesh, free the rectus sheath and the aponeurosis of the external oblique, separate the entire rectus muscle from its lateral attachment, repair the fascia, and place mesh bilaterally over the lateral external oblique defects

(B) Excise the mesh, raise large subcutaneous flaps, and primarily close the fascia

(C) Excise the mesh, raise large subcutaneous flaps, free the rectus sheath and the aponeurosis of the external oblique, perform a lateral relaxing incision in the external oblique, and then primarily close the fascia

(D) Excise the mesh, separate the retromuscular space, and place an underlay and overlay mesh

(E) Overlay mesh over the prior repair after raising large subcutaneous flaps

Answer: (C) Excise the mesh, raise large subcutaneous flaps, free the rectus sheath and the aponeurosis of the external oblique, perform a lateral relaxing incision in the external oblique, and then primarily close the fascia

Rationale:
Component separation is a technique for repair of complex abdominal wall defects that has been developed mainly over the last decade. Separation of the external oblique from the rectus sheath and from the internal oblique can add an additional 10 cm of length to each side of the fascia (see figure). Usually the repair is enforced by an overlay mesh to buttress the repair. Further length can be achieved by incising the posterior sheath above the arcuate line. With extensive component separation, attention must be given to preserving major perforating vessels as flap necrosis is a feared complication. Still under investigation and not yet widely applied are minimally invasive component separation with laparoscopic sutures and intraperitoneal sublay mesh.

Overall ventral hernias can be repaired with or without mesh. Placement of mesh can be intraperitoneal, underlay, overlay, or in a sandwich fashion. Mesh-free repair can be

۰۲۱-۶۶۱۹۸۵۱۴ www.myuptodate.com دریافت آخرین نسخه آپتودیت آفلاین

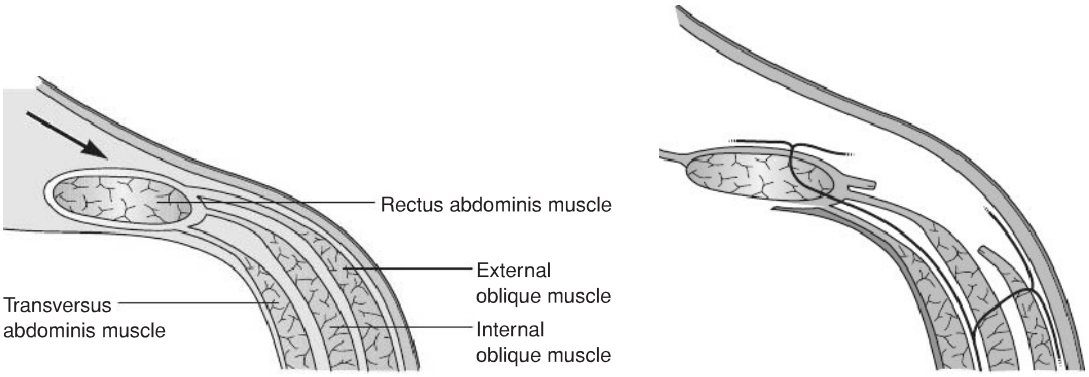

Component separation technique. Reprinted with permission from: Fitzgibbons RJ, Cemaj S, Quinn TH. Abdominal wall hernias. In: Mulholland MW, Lillemoe KD, Doherty GM, Maier RV, Simeone DM, Upchurch GR, Jr, eds. *Greenfield's Surgery: Scientific Principles & Practice*. 5th ed. Philadelphia, PA: Lippincott Williams & Wilkins, 2011:1187.

achieved by simple subcutaneous flaps or component separation technique. With all ventral hernias, the recurrence rates are high. The principles to success are:

- Physiologic placement of mesh if possible (intraperitoneal pressure holds mesh in place if placed under peritoneum)
- Mesh should overlap and be fixated at least 4 cm beyond the defect
- Repair should be done with the least tension possible

Underlay mesh either retromuscular or intraperitoneal is still the preferred method with the lowest recurrence rates.

References:

Fitzgibbons RJ, Cemaj S, Quinn TH. Abdominal wall hernias. In: Mulholland MW, Lillemoe KD, Doherty GM, Maier RV, Simeone DM, Upchurch GR, eds. *Greenfield's Surgery: Scientific Principles and Practice,* 5th ed. Lippincott Williams & Wilkins; 2011.

Malangoni MA, Rosen MJ. Hernias. In: Townsend CM, Beauchamp RD, Evers MB, Mattox KL, eds. *Sabiston Textbook of Surgery: The Biological Basis of Modern Surgical Practice.* 18th ed. Philadelphia, PA: Saunders Elsevier; 2008.

۰۲۱-۶۶۱۹۸۵۱۴ www.myuptodate.com دریافت آخرین نسخه آپتودیت آفلاین

2B40

Key word: Contraindications to Laparoscopic Inguinal Hernia Repair

Author: Kyle J. Van Arendonk, MD, PhD
Editor: Pamela A. Lipsett, MD, MHPE, FACS, FCCM

A 65-year-old man is referred to you for management of a recurrent, reducible left-sided inguinal hernia. He initially underwent an open Lichtenstein repair 3 years ago. He has a history of coronary artery disease, myocardial infarction, severe chronic obstructive pulmonary disease (COPD), and prostate cancer treated with a radical retropubic prostatectomy and radiation 2 years ago. He takes low-dose aspirin, a beta-blocker, and a statin. What should you tell him regarding the choice between open and laparoscopic repair of his recurrent inguinal hernia?

(A) His cardiopulmonary disease makes the laparoscopic approach preferable

(B) His hernia should be repaired laparoscopically because of his previous prostatectomy

(C) His hernia should be repaired open because it is recurrent

(D) His hernia should be repaired open because of his history of pelvic radiation

(E) His use of aspirin is a contraindication to laparoscopic repair

Answer: (D) His hernia should be repaired open because of his history of pelvic radiation

Rationale:

Unilateral primary inguinal hernias can be corrected with either a laparoscopic or open repair with mesh, and the choice generally depends upon surgeon experience and patient preference. Most studies have found that laparoscopic repairs, most commonly performed via either a transabdominal preperitoneal (TAPP) or totally extraperitoneal (TEP) approach, have less postoperative pain, provide a faster return to normal activities, and have similar recurrence rates compared to open repairs.

Laparoscopic repairs offer significant benefits and have been especially useful in the treatment of recurrent hernias (especially those that were initially repaired with an open approach) and bilateral hernias. For recurrent hernias, the laparoscopic approach provides a definitive diagnosis when the diagnosis of recurrence is uncertain, avoids dissection in scarred tissues (and thereby minimizes the chance of injury to the cord structures), and allows for complete visualization of the myopectineal orifice and thereby better identification of femoral hernias, which have been shown to account for 9% of recurrent hernias. For bilateral hernias, the laparoscopic approach allows simultaneous repair of both sides without additional incisions. Finally, laparoscopic repairs may also offer significant advantages to obese patients (avoids the risk of wound complications after groin dissection) and to women (because synchronous femoral hernias are frequently present in women at the time of inguinal hernia repair and can be simultaneously repaired when noted).

Laparoscopic inguinal hernia repairs are inappropriate for some patients, however. Patients who are unlikely to tolerate general anesthesia or pneumoperitoneum because of severe cardiopulmonary disease should instead undergo an open repair under local anesthesia. Patients with previous lower abdominal surgery, pelvic radiation, or preperitoneal surgery (such as radical retropubic prostatectomy or preperitoneal placement of a kidney transplant) are also best served by an open rather than laparoscopic repair. While the current use of antiplatelet agents or systemic anticoagulation is also considered a contraindication to laparoscopic inguinal hernia repair, the use of low-dose aspirin is not. Finally, patients with strangulated hernias should be repaired open because field contamination may make necessary a primary repair without mesh.

References:

Carter J, Duh QY. Laparoscopic repair of inguinal hernias. *World J Surg.* 2011;35(7):1519–1525.

Ferzil GS, Edwards ED. Laparoscopic inguinal herniorrhaphy. In: Cameron JL, Cameron AM, eds. *Current Surgical Therapy.* 10th ed. Philadelphia, PA: Mosby; 2011:1197–1210.

۰۲۱-۶۶۱۹۸۵۱۴ www.myuptodate.com دریافت آخرین نسخه آپتودیت آفلاین

2B41

Key word: Criteria for Liver Transplantation in Patients with Hepatocellular Carcinoma

Author: Emmanouil Pappou, MD
Editor: Michael A. Choti, MD, MBA

According to the Milan criteria, which of the following must be true for a patient with hepatocellular carcinoma (HCC) to be a candidate for liver transplantation?

(A) If three tumors are present, they all have to be 3 cm or less in diameter

(B) If a single tumor is present, it has to be larger than 5 cm in diameter

(C) If a single tumor is present, it has to be smaller than 8 cm in diameter

(D) If multiple tumors are present, the total tumor diameter should not exceed 8 cm

(E) If multiple tumors are present, they all must be in the same lobe

Answer: **(A)** If three tumors are present, they all have to be smaller than 3 cm

Rationale:

HCC is the fifth most common solid malignancy worldwide and the third leading cause of cancer death, accounting for over half a million deaths across the globe annually. Although it is a less common disease in the United States, its incidence has been rising and is projected to further increase over the coming decades as a consequence of high hepatitis C virus (HCV) infection rates. The majority of HCC arises in the face of underlying liver cirrhosis and the main factors are chronic hepatitis B and C infection, alcohol abuse, and nonalcoholic fatty liver disease.

Management of patients with HCC is complex, and treatment options range from local ablative therapies to systemic chemotherapy. Ablative techniques include radiofrequency ablation (RFA) and microwave ablation. RFA is considered an effective alternative to resection in patients with small (≤3 cm) tumors, used percutaneously in the majority of cases, and greatly limited by tumor size and location. Microwave ablation is a promising new modality that could potentially prove more effective than RFA in treating larger tumors; however, experience with this new technique is still limited.

Advances in surgical technique and perioperative care have established surgery as the primary curative therapy, with either liver resection or liver transplantation. Unlike ablative treatment modalities, surgery allows complete pathologic evaluation of the specimen. Liver resection has been the primary surgical treatment for HCC, especially in noncirrhotic patients but also in selected patients with well-compensated cirrhosis and preserved liver function. Resection is widely applicable, as it is not constrained by tumor size or location. Its success depends on the ability of the surgeon to achieve complete resection and maintain a posthepatectomy liver remnant with adequate perfusion, biliary drainage, and volume that will ensure sufficient liver function. Resection with wide margins (1 to 2 cm) is recommended. Resection of single large tumors (>10 cm) has been associated with favorable outcomes, suggesting that size alone is not a contraindication for resection. The overall 5-year survival after liver resection for HCC is 25% to 50%, with recurrence seen in up to 80% of patients.

Liver transplantation is the most attractive therapeutic option for patients with HCC and cirrhosis because it removes both detectable and undetectable tumors together with the remaining liver that is at risk for *de novo* HCC. Moreover, it treats simultaneously the underlying cirrhosis and prevents the development of future complications associated with portal hypertension and liver failure. Early experience with liver transplantation as treatment for HCC in the 1980s had quite poor outcomes. This unfavorable early experience led to the identification of factors defining a group of patients with HCC who would maximally benefit from liver transplantation.

In a landmark study from Milan in 1996, Mazzafero et al. reported a 4-year survival of 75% after liver transplantation in patients with cirrhosis and HCC if liver transplantation was restricted to patients who had (a) a single tumor up to 5 cm or (b) up to three tumors each 3 cm or less in diameter, with no evidence of macrovascular invasion or extrahepatic disease. The "Milan criteria" were subsequently adopted by the United Network from Organ Sharing (UNOS) in 2002 and are currently considered the gold standard for selection of patients with HCC for liver transplantation. Since then, several studies from around the world have validated these restrictive criteria. Unlike liver resection, transplantation is not restricted by the underlying liver function, although advanced cirrhosis is associated with worse survival after transplantation.

Transplantation for HCC remains severely limited by organ availability. Median time to transplantation in the United States can range from 9 to 12 months from time of initial listing, with 25% to 40% dropping from the waiting list due to either disease progression leading to ineligibility or death. More recent studies have challenged the Milan criteria, reporting comparable outcomes after transplantation for more advanced stage tumors. Still, for patients beyond Milan criteria, liver transplantation is currently considered only on a highly selective basis.

References:

Jarnagin W, Chapman WC, Curley S, et al. Surgical treatment of hepatocellular carcinoma: expert consensus statement. *HPB (Oxford).* 2010;12(5):302–310.

Mazzaferro V, Regalia E, Doci R, et al. Liver transplantation for the treatment of small hepatocellular carcinomas in patients with cirrhosis. *N Engl J Med.* 1996;334(11):693–699.

۰۲۱-۶۶۱۹۸۵۱۴ www.myuptodate.com دریافت آخرین نسخه آپتودیت آفلاین

2B42

Key word: Treatment of Neurogenic Shock in a Quadriplegic

Author: Brenessa M. Lindeman, MD
Editor: Kent A. Stevens, MD, MPH

An 11-year-old girl was riding a horse when she was thrown approximately 2.44 m (8 ft). She was reported to have lost consciousness and was not ambulatory at the scene. Upon arrival, vital signs are now a pulse of 58 beats per minute, blood pressure of 81/47 mm Hg, and respiratory rate of 18 breaths per minute. Physical examination is notable for a laceration over the left temple, tenderness to palpation over C6, and 2/5 strength in all four extremities. Which of the following is the most appropriate next step in management?

(A) Give atropine

(B) Initiate dobutamine drip

(C) Initiate dopamine drip

(D) Initiate phenylephrine drip

(E) Provide crystalloid bolus

Answer: (E) Provide crystalloid bolus

Rationale:

Acute injury to the cervical or high thoracic spine can result in disruption of sympathetic vasomotor fibers. Loss of these impulses may result in hypotension, bradycardia, decreased cardiac output, decreased peripheral vascular resistance, increased vascular capacitance, and decreased venous return (i.e., neurogenic shock). This is classically described on physical examination as bradycardia and hypotension in a patient with warm extremities and motor and/or sensory deficits indicative of spinal cord injury.

In a patient with multiple traumatic injuries, other causes of hypotension including hemorrhagic shock, tension pneumothorax, and cardiogenic shock must be excluded. Indeed, it has been reported in the literature that in a subset of patients with spinal cord injuries associated with penetrating trauma, only the minority of patients (7%) presented with the classic findings of neurogenic shock. One key feature that often distinguishes neurogenic shock from hemorrhagic shock is the absence of the typical reflex tachycardia that occurs with hypovolemia. The loss of all sympathetic tone, including the adrenal medulla, may also limit systemic catecholamine release, contributing to diminished vasomotor tone.

Administration of vasopressors will serve to improve vascular tone, but adequate intravascular volume must first be obtained in order to exclude hypovolemia as the cause of the patient's hypotension. In terms of specific vasopressors, phenylephrine is an ideal choice if the patient is tachycardic, while dopamine is preferred if the patient is bradycardic.

References:

Zipnick RI, Scalea TM, Trooskin SZ, et al. Hemodynamic responses to penetrating spinal cord injuries. *J Trauma.* 1993;35(4):578–582.

Zuckerbraun BS, Peitzman AB, Billiar TR. Shock. In: Brunicardi FC, Andersen DK, Billiar TR, Dunn DL, Hunter JG, Matthews JB, Pollock RE, eds. *Schwartz's Principles of Surgery.* 9th ed. New York, NY: McGraw-Hill; 2010. http://www.accessmedicine.com/content.aspx?aID=5011953. Accessed May 9, 2013.

۰۲۱-۶۶۱۹۸۵۱۴ www.myuptodate.com دریافت آخرین نسخه آپتودیت آفلاین

2B43

Key word: Treatment of Obturator Hernias

Author: Bonnie E. Lonze, MD, PhD
Editor: Mark D. Duncan, MD, FACS

An 87-year-old woman presents with 2 days of lower abdominal pain, nausea, and emesis. She is tachycardic but afebrile with a normal white blood cell count. Her abdomen is soft but mildly tender. Extension and medial rotation of her right leg produces pain in the right medial thigh. After resuscitation, the most likely operative intervention required for this patient is:

(A) Inguinal approach for repair of incarcerated femoral hernia

(B) Laparoscopic appendectomy for acute appendicitis

(C) Laparotomy for repair of incarcerated femoral hernia

(D) Laparotomy for repair of incarcerated obturator hernia

(E) Laparotomy for repair of incarcerated sciatic hernia

Answer: (D) Laparotomy for repair of incarcerated obturator hernia

Rationale:

Obturator hernias comprise a rare subset of abdominal wall hernias and are most frequently seen in thin, elderly women. They carry the highest mortality of all abdominal hernias, given their frequent association with acute bowel obstruction and their frequent occurrence in elderly patients with multiple co-morbidities. Small bowel is the most common intra-abdominal organ present in an obturator hernia, and intestinal obstruction is seen in over 80% of patients presenting with an obturator hernia.

Because obturator hernias frequently present with nonspecific symptoms and no externally palpable hernia, they are often challenging to diagnose. A positive Howship–Romberg sign, characterized by pain extending down the medial thigh upon abduction, extension, or internal rotation of the knee, is the most specific clinical sign of an obturator hernia and is caused by compression of the obturator nerve by the hernia sac. This sign is present in only about half of patients with obturator hernias, so a high index of suspicion is required to establish the diagnosis. Occasionally, incarcerated obturator hernias may be felt as a mass on rectal examination. Computed tomography (CT) scan frequently will demonstrate the defect as well, but for patients with obstructive symptoms, prompt operative management is paramount. Many obturator hernias are in fact not diagnosed pre-operatively but rather during an emergent operation for bowel obstruction and/or ischemic bowel.

Surgical repair is necessary for all obturator hernias; conservative management has no role. Exploratory laparotomy though a lower midline incision provides the best exposure for repair of obturator hernias. The incarcerated bowel is first reduced, incising the obturator membrane to facilitate exposure as necessary, and then assessed for viability. The hernia opening is then either closed with a running layer of polypropylene or nylon suture or closed with mesh if no bowel contamination has occurred. In cases diagnosed pre-operatively in which there is no suspicion for ischemic bowel, obturator hernias can also be repaired through a midline extraperitoneal approach or through an anterior thigh exposure.

Reference:

Javid PJ, Brooks DC. Hernias. In: Ashley SW, Zinner MJ, eds. *Maingot's Abdominal Operations.* 11th ed. New York, NY: McGraw-Hill; 2007.

۰۲۱-۶۶۱۹۸۵۱۴ www.myuptodate.com دریافت آخرین نسخه آپتودیت آفلاین

2B44

Key word: Early Initiation of Enteral versus Parenteral Nutrition

Author: Joshua C. Grimm, MD
Editor: Elliott R. Haut, MD, FACS

A 75-year-old male undergoes a right upper lobectomy for squamous cell cancer of the lung. His postoperative course is complicated by prolonged intubation secondary to his underlying chronic obstructive pulmonary disease. The intensive care team would like to begin nutrition due to the patient's poor nutritional status. Which of the follow is true concerning options for feeding this patient?

(A) Early enteral nutrition is associated with an increased duration of mechanical ventilation

(B) Glutamine supplementation has been proven to decrease mortality in the critically ill

(C) In recent trials, late parenteral nutrition has been associated with fewer complications in comparison with early parenteral feeding

(D) Postpyloric enteral feedings are preferred to gastric feedings in regards to overall nutrition and complications

(E) Supplementing enteral nutrition with parenteral support to ensure adequate caloric intake is *not* advocated

Answer: (C) In recent trials, late parenteral nutrition has been associated with fewer complications in comparison with early parenteral feeding

Rationale:

It is clear that nutrition, including both enteral and/or parenteral, has benefits in critically ill patients. Recent debates have centered on the advantages and applications of each method. A recent study showed superiority in delaying parenteral nutrition due to a decrease in the rates of infection and cholestasis. Several studies have shown that, while there is a benefit of enteral nutrition over parenteral nutrition, there is also no harm in supplementing enteral nutrition with parenteral forms in order to ensure adequate caloric intake (however, no reduction in mortality was seen with this caloric supplementation).

Enteral nutrition has been almost universally accepted as a preferential means of feeding patients. Originally, it had been thought that postpyloric feeding would be superior to gastric feeding (specifically in terms of the risk of aspiration). Recent studies, however, have shown no benefit to duodenal or jejunal feeding in the majority of patients. While previous reports suggested that glutamine, the amino acid utilized by small bowel enterocytes, should be added to parenteral formulations to enhance T-cell activity and ensure integrity of the small bowel mucosa, a recent randomized trial in critically ill patients with multiorgan failure found that the use of glutamine did not improve clinical outcomes and instead was associated with an increased risk of mortality.

References:

Casaer MP, Mesotten D, Hermans G. Early versus late parenteral nutrition in critically ill adults. *N Engl J Med.* 2011;365(6):506–517.

Heyland D, Muscedere J, Wischmeyer PE, et al. Canadian Critical Care Trials Group. A randomized trial of glutamine and antioxidants in critically ill patients. *N Engl J Med.* 2013;368(16):1489–1497.

Wernerman J. Glutamine supplementation. *Ann Intensive Care.* 2011;1(1):25.

White H, Sosnowski K, Tran K. A randomised controlled comparison of early post-pyloric versus early gastric feeding to meet nutritional targets in ventilated intensive care patients. *Crit Care.* 2009;13(6):R187.

۰۲۱-۶۶۱۹۸۵۱۴ www.myuptodate.com دریافت آخرین نسخه آپتودیت آفلاین

2B45

Key word: Embryology of Indirect Hernias

Author: Bonnie E. Lonze, MD, PhD
Editor: F. Dylan Stewart, MD, FACS

Failure of the processus vaginalis to obliterate during embryologic development can lead to which of the following?

(A) Communicating hydrocele
(B) Hydrocele of the cord
(C) Indirect inguinal hernia
(D) Scrotal hydrocele
(E) All of the above

Answer: (E) All of the above

Rationale:
During the third month of gestation, the processus vaginalis forms as an outpouching of the ventral peritoneum. In males, the testes pass by way of the processus vaginalis through the internal inguinal ring between months 7 though 9 of gestation. Normally, the processus vaginalis ultimately obliterates, closing the communication between the peritoneal cavity and the scrotum. Indirect inguinal hernias and the various types of hydroceles are all the result of a failure of the processus vaginalis to completely obliterate. A widely patent processus vaginalis, through which bowel may pass into the scrotum, is an indirect inguinal hernia. A more narrowly patent processus vaginalis, whereby there is communication between peritoneal fluid and the scrotum, is a communicating hydrocele. Obliteration of the processus vaginalis proximally but not distally results in a scrotal hydrocele. Obliteration of the processus vaginalis proximally and distally but incompletely within the midportion of the spermatic cord results in a cord hydrocele.

Reference:
Malangoni MA, Rosen MJ. Hernias. In: Townsend CM, Beauchamp RD, Evers BM, Mattox KL, eds. *Sabiston Textbook of Surgery.* 19th ed. Philadelphia, PA: Saunders Elsevier; 2012:1114–1140.

2B46

Key word: Etiology of Shock after Aneurysm Repair

Author: Brenessa M. Lindeman, MD
Editor: Ying Wei Lum, MD

A 68-year-old man was found to have a 6.2-cm infrarenal abdominal aortic aneurysm (AAA) on computed tomography (CT) and underwent an elective open AAA repair. His postoperative course was unremarkable until postoperative day 3 when his vital signs reveal a pulse of 128 beats per minute, blood pressure of 89/45 mm Hg, and oxygen saturation of 95% on room air. Physical examination is notable for an increasingly distended abdomen, and the nurse notes that the patient had an episode of bloody bowel movement earlier in the day. What is the most likely etiology of shock in this patient?

(A) Bleeding from the proximal graft anastomosis
(B) Bleeding from unrecognized injury to a retroaortic renal vein
(C) Rupture of a pseudoaneurysm at the graft site
(D) Sepsis from graft infection
(E) Sepsis from sigmoid colon ischemia

Answer: (E) Sepsis from sigmoid colon ischemia

Rationale:
The inferior mesenteric artery supplies branches that extend from the splenic flexure to the mid-rectum and is often sacrificed during AAA repair. Loss of this arterial supply can lead to ischemia of the left colon, which typically presents with acidosis, abdominal distention, and bloody stools. The diagnosis is most easily made with flexible sigmoidoscopy but may also be seen on CT of the abdomen and pelvis. Despite loss of the superior rectal artery, which is the continuation of the inferior mesenteric artery, the rectum is often spared from the region of ischemia, given its additional blood supply from the middle rectal artery and inferior rectal artery (both originating from the internal iliac artery).

Aggressive fluid resuscitation and antibiotics may suffice when only mucosal ischemia is present. However, in the presence of full-thickness necrosis or if the patient demonstrates signs of sepsis or frank peritonitis, surgical intervention with colectomy and end colostomy is required.

Reference:
Schermerhorn M, Nedeau AE. Type IV thoracoabdominal, infrarenal, and pararenal aortic aneurysms. In: Fischer JE, ed. *Mastery of Surgery.* 6th ed. Philadelphia, PA: Lippincott Williams & Wilkins; 2012:2212–2218.

۰۲۱-۶۶۱۹۸۵۱۴ www.myuptodate.com دریافت آخرین نسخه آپتودیت آفلاین

2B47

Key word: Treatment of Tumor of the Bronchus

Author: Kyle J. Van Arendonk, MD, PhD
Editor: Robert A. Meguid, MD, MPH

An otherwise healthy, physically active 45-year-old woman is referred to you for management of a 1.5-cm pulmonary carcinoid tumor emanating from the right upper lobe bronchus. The tumor is obstructing the orifice of the right upper lobe bronchus without involvement of the right mainstem bronchus or the bronchus intermedius. No nodal enlargement was seen on computed tomography (CT) of the chest. Which of the following management options is most appropriate?

(A) Neoadjuvant chemoradiation

(B) Right carinal pneumonectomy with mediastinal lymph node sampling

(C) Right pneumonectomy with mediastinal lymph node sampling

(D) Right upper lobe sleeve resection with tumor-free margins and mediastinal lymph node sampling

(E) Right upper lobectomy with mediastinal lymph node sampling

Answer: (D) Right upper lobe sleeve resection with tumor-free margins and mediastinal lymph node sampling

Rationale:

Carcinoid tumors are a relatively uncommon type of lung cancer. However, after the gastrointestinal tract the lung is the second most common site of origin for carcinoid tumors. They are neuroendocrine tumors and arise from the Kulchitsky cells of the bronchus. Carcinoid tumors are classified as typical or atypical based upon the frequency of mitoses and the presence or absence of necrosis on pathologic examination. While both typical and atypical carcinoid tumors may metastasize, atypical carcinoids are more aggressive, tend to occur more peripherally and in older patients, and have poorer survival rates compared to typical carcinoids.

Typical carcinoid tumors are usually centrally located tumors that arise from the major bronchi. Patients usually present with cough, recurrent pneumonia, and hemoptysis. The presence of carcinoid syndrome is usually associated with hepatic metastases, and therefore with atypical carcinoids. Diagnosis is typically made with CT imaging of the chest, taking note of any peribronchial or mediastinal lymph node enlargement, followed by bronchoscopy with biopsy (for central tumors) or transthoracic needle aspiration (for peripheral tumors).

Surgery is the mainstay of treatment for isolated pulmonary carcinoid tumors and is frequently curative, as metastases are rare. Bronchoscopy is essential for determining the location of central carcinoid tumors and relation to uninvolved bronchus, thereby providing information necessary for planning for surgical resection. Mediastinoscopy with biopsy is performed on patients with lymph node enlargement on CT. Mediastinal nodal involvement should prompt multidisciplinary review and consideration of neoadjuvant chemotherapy versus resection followed by adjuvant chemotherapy.

Centrally located carcinoid tumors without evidence of nodal involvement are treated if possible with a parenchymal-sparing sleeve resection, which offers survival outcomes similar to lobectomy or pneumonectomy. Margins need to be free of tumor on frozen section pathologic evaluation, and mediastinal lymph node dissection should be performed to aid in staging, treatment, and guidance of further management. Peripheral carcinoids are generally treated with a lobectomy. Neoadjuvant chemotherapy can also be considered for atypical carcinoids with N2 or N3 nodal involvement.

The technique of carinal pneumonectomy resects the entire lung and ipsilateral mainstem bronchus, reanastomosing the contralateral mainstem bronchus to the trachea. This is useful for tumors involving the proximal mainstem bronchus where resection to negative margins does not leave enough bronchial tissue to permit stapled or sewn closure of the bronchial cuff.

References:

Blackmon SH, Valporciyan AA. Thoracic malignancies. In: Feig BW, Ching CD, eds. *The M.D. Anderson Surgical Oncology Handbook.* 5th ed. Philadelphia, PA: Lippincott Williams and Wilkins; 2012:220–236.

Escalon JC, Detterbeck FC. Carcinoid Tumors. In: Shields TW, LoCicero J III, Reed CE, Feins RH, eds. *General Thoracic Surgery.* 7th ed. Philadelphia, PA: Lippincott Williams and Wilkins; 2009:1539–1554.

۰۲۱-۶۶۱۹۸۵۱۴ www.myuptodate.com دریافت آخرین نسخه آپتودیت آفلاین

2B48

Key word: Monitoring Treatment of Low-molecular-weight Heparin

Author: Kyle J. Van Arendonk, MD, PhD
Editor: Elliott R. Haut, MD, FACS

A 76-year-old man is on systemic anticoagulation with low-molecular-weight heparin (LMWH) for a recently diagnosed deep venous thrombosis. He has presented twice to the emergency department in the past week with epistaxis that requires nasal packing for hemostasis. Today he returns to the emergency room after falling down the steps to his front door. A thorough examination reveals no injuries. What is the most appropriate management of his anticoagulation moving forward?

(A) Check weekly activated partial thromboplastin time (aPTT) and adjust LMWH dose accordingly

(B) Check weekly plasma anti-Factor Xa levels and adjust LMWH dose accordingly

(C) Convert to unfractionated heparin

(D) Convert to warfarin

(E) Stop anticoagulation and arrange for placement of an inferior vena cava (IVC) filter

Answer: (E) Stop anticoagulation and arrange for placement of an inferior vena cava (IVC) filter

Rationale:

Treatment of venous thromboembolism (VTE) with systemic anticoagulation reduces the risk of pulmonary embolism (PE), extension of the thrombosis, and recurrence of the thrombosis. Anticoagulation can be achieved with an intravenous unfractionated heparin bridge while initiating warfarin or alternatively with LMWH, which has a lower risk of hemorrhage compared to unfractionated heparin. LMWH can be administered subcutaneously in the outpatient setting and does not require routine serum monitoring. In rare circumstances, such as in patients with renal failure, LMWH can be monitored by measurement of plasma anti-Factor Xa activity, but correlation with the risks of bleeding and thrombosis recurrence is not great. Because LMWH has some anti-Factor IIa activity, the partial thromboplastin time (PTT) can also be prolonged but is not considered an adequate monitoring test for adjusting LMWH dosing.

The most common complication of systemic anticoagulation is bleeding. Patients with VTE who experience bleeding complications, as well as patients with failure of anticoagulation, a contraindication to anticoagulation, or excessive anticoagulation risks (e.g., elderly patients with a high risk of falls), should be considered for insertion of an IVC filter, which provides excellent (>95%) protection against PE. The patient above has experienced bleeding complications and is also at high risk of falls, both reasons to discontinue anticoagulation and instead place an IVC filter for prevention of PE.

References:

Henke PK. Venous thromboembolism: diagnosis, prevention, and treatment. In: Cameron JL, Cameron AM, eds. *Current Surgical Therapy.* 10th ed. Philadelphia, PA: Mosby; 2011:867–873.

Kaufman JA, Kinney TB, Streiff MB, et al. Guidelines for the use of retrievable and convertible vena cava filters: report from the Society of Interventional Radiology multidisciplinary consensus conference. *J Vasc Interv Radiol.* 2006;17(3):449–459.

۰۲۱-۶۶۱۹۸۵۱۴ www.myuptodate.com دریافت آخرین نسخه آپتودیت آفلاین

2B49

Key word: Nerve Injury During Laparoscopic Inguinal Hernia Repair

Author: Bonnie E. Lonze, MD, PhD
Editor: Nicole M. Chandler, MD

During laparoscopic inguinal hernia repair, which nerve is most likely to be injured by tacking of the mesh?

(A) Femoral nerve
(B) Ilioinguinal nerve
(C) Iliohypogastric nerve
(D) Lateral femoral cutaneous nerve
(E) Obturator nerve

Answer: (D) Lateral femoral cutaneous nerve

Rationale:
During laparoscopic repair of inguinal hernias, the lateral femoral cutaneous nerve and the femoral branch of the genitofemoral nerve (GFN) are at greatest risk to be injured. These nerves lie within the so-called "triangle of pain." Typically nerve injury occurs as a result of entrapment from tacking devices and can be avoided by taking care not to place tacks more than a few centimeters lateral to the internal inguinal ring. Injury to the lateral femoral cutaneous nerve causes pain and paresthesias in the thigh. Injury to the femoral branch of the genitofemoral nerve causes pain and paresthesias in the skin over the femoral triangle. Unlike in open inguinal hernia repairs, the ilioinguinal and iliohypogastric nerves are not encountered with a laparoscopic approach. The femoral nerve is also typically not encountered during this dissection.

References:
Garcia-Ruiz A, Weber-Sanchez A. Laparoscopic transabdominal preperitoneal inguinal hernia repair. In: Fischer JE, ed. *Mastery of Surgery.* 6th ed. Philadelphia, PA: Lippincott Williams & Wilkins; 2012:2085–2090.

Tetik C, Arregui ME, Dulucq JL, et al. Complications and recurrences associated with laparoscopic repair of groin hernias. *Surg Endosc.* 1994;8(11):1316–1322.

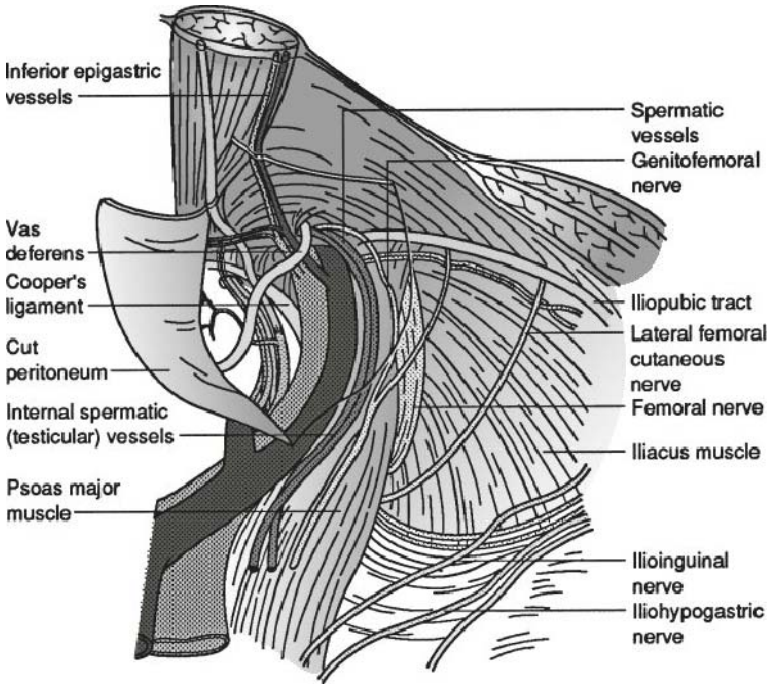

Reprinted with permission from: Jones DB, Maithel SK, Schneider BE, (eds.). *Atlas of Minimally Invasive Surgery*. Woodbury, CT: Cine-Med, 2006.

۰۲۱-۶۶۱۹۸۵۱۴ www.myuptodate.com دریافت آخرین نسخه آپتودیت آفلاین

2B50

Key word: Nerve Injuries Associated with Lithotomy Positioning

Author: Bonnie E. Lonze, MD, PhD
Editor: Susan L. Gearhart, MD

A 45-year-old woman with ulcerative colitis undergoes a laparoscopic total proctocolectomy with ileal pouch and anal anastomosis. It is a technically challenging procedure, and the total operating time is 14 hours. The following morning, the patient complains of pain, numbness, and weakness on the lateral aspect of the left foot and leg. The most likely diagnosis is:

(A) Common peroneal nerve injury

(B) Compartment syndrome

(C) Femoral nerve injury

(D) Lateral femoral cutaneous nerve injury

(E) Sciatic nerve injury

Answer: **(A)** Common peroneal nerve injury

Rationale:
Lithotomy positioning can result in peripheral nerve injuries that result in significant morbidity for patients, and therefore careful attention to positioning and padding is important. Patients who are thin and those who undergo prolonged operating times in the lithotomy position are at greatest risk for a lower extremity nerve injury. The common peroneal nerve is the nerve most commonly injured as a consequence of lithotomy positioning, though femoral, obturator, and sciatic neuropathies have been reported as well. Common peroneal neuropathy generally presents with weakness, pain, and paresthesias in the affected lower leg and foot.

Reference:
Warner MA, Martin JT, Schroeder DR, et al. Lower-extremity motor neuropathy associated with surgery performed on patients in a lithotomy position. *Anesthesiology.* 1994;81: 6–12.

2B51

Key word: Neurologic Findings Associated with Brain Death

Authors: Said C. Azoury, MD, and Kyle J. Van Arendonk, MD, PhD
Editors: Elliott R. Haut, MD, FACS, and Pamela A. Lipsett, MD, MHPE, FACS, FCCM

A neurologist is called to the intensive care unit and asked to evaluate a patient for brain death. Which of the following is true regarding the clinical examination and confirmatory studies for brain death?

(A) A positive apnea test occurs when oxygen saturation drops below 85% after adequate preoxygenation

(B) Ancillary tests such as electroencephalography (EEG) can be used in place of the physical examination to diagnose brain death when performing the neurologic examination proves to be exceedingly difficult

(C) Brain death statutes are standardized across all 50 states in the United States

(D) Brainstem reflexes but not spinal reflexes must be absent to confirm brain death

(E) The patient must not be under the effect of paralytic drugs but can be well-sedated during the brain death examination

Answer: **(D)** Brainstem reflexes but not spinal reflexes must be absent to confirm brain death

Rationale:
Brain death is defined as the complete and irreversible loss of cerebral and brainstem function. The specifics of brain death statutes vary by state and institution, but a number of common principles exist. Prior to performing the neurologic examination, one must confirm that the comatose state does not exist because of sedative medications (including alcohol), neuromuscular-blocking agents, or major electrolyte or acid–base disturbances, and clinicians should instead have another explanation for the patient's presentation. The patient must also be normothermic, normotensive, and adequately oxygenated.

The clinical examination, which is sufficient alone in most states to pronounce brain death, must then confirm that the patient is comatose and lacking all evidence of responsiveness on repeated examinations (confirming irreversibility). All brainstem reflexes (papillary, oculocephalic, oculovestibular, corneal, pharyngeal, and tracheal) must be absent. Spinal reflexes may be present, but noxious stimuli should produce no other motor response (eye movement, etc.) or autonomic circulatory stimulation. The absence of a respiratory drive is confirmed through an apnea test: After achieving normotension, normothermia, euvolemia, eucapnia, and adequate oxygenation, the patient is disconnected from the ventilator. While preserving oxygenation and normotension, the patient is observed to confirm the absence of any respiratory efforts. A positive test is generally confirmed with a rise in the arterial

۰۲۱-۶۶۱۹۸۵۱۴ www.myuptodate.com دریافت آخرین نسخه آپتودیت آفلاین

PCO_2 to at least 60 mm Hg or at least 20 points higher than baseline.

Ancillary tests including EEG, cerebral angiography, nuclear scan, transcranial Doppler (TCD), computed tomography angiography (CTA), and magnetic resonance angiography (MRA) can be used when the neurologic examination is equivocal or when the apnea test cannot be performed. Ancillary tests are not required to make the diagnosis of brain death and are not sufficient to replace the neurologic examination.

Some locations use a minimum observation period before brain death can be diagnosed and/or require two examinations spaced out by a minimum time interval (e.g., two examinations 12 hours apart). However, a recent American Academy of Neurology guideline update found insufficient evidence to determine if there is a minimum observation period that should be utilized before confirming the irreversible loss of neurologic function.

Reference:

Wijdicks EF, Varelas PN, Gronseth GS, et al; American Academy of Neurology. Evidence-based guideline update: determining brain death in adults: report of the Quality Standards Subcommittee of the American Academy of Neurology. *Neurology.* 2010;23:1911–1918.

2B52

Key word: Process Measures of SCIP

Author: Andrew P. Dhanasopon, MD
Editor: Martin A. Makary, MD, MPH

Which of the following is a Surgical Care Improvement Project (SCIP) measure?

(A) Discontinuing prophylactic antibiotics 48 hours after a noncardiac surgery

(B) Receiving prophylactic antibiotics immediately after the time of incision

(C) Recording a temperature of at least 35°C (95°F) 30 minutes prior to or 15 minutes after "Anesthesia End Time"

(D) Removing the urinary catheter by postoperative day 2

(E) Shaving a patient the night before surgery

Answer: (D) Removing the urinary catheter by postoperative day 2

Rationale:

The SCIP is a partnership of organizations whose goal is to improve the safety of surgical care through the reduction of postoperative complications by adherence to evidence-based practice recommendations—the SCIP measures. The following table is the core list of all the SCIP measures.

Measure ID #	Measure Name
SCIP Inf-1	Prophylactic Antibiotic Received Within One Hour Prior to Surgical Incision
SCIP Inf-2	Appropriate Prophylactic Antibiotic Selection for Surgical Patients
SCIP Inf-3	Prophylactic Antibiotics Discontinued Within 24 Hours After Surgery End Time
SCIP Inf-4	Cardiac Surgery Patients With Controlled 6 A.M. Postoperative Blood Glucose
SCIP Inf-6	Appropriate Hair Removal Before Surgery (using an electric shaver)
SCIP Inf-9	Urinary Catheter Removed on Postoperative Day 1 or Postoperative Day 2
SCIP Inf-10	Perioperative Temperature Management
SCIP Card-2	Receipt of Beta-Blocker During the Perioperative Period if on Beta-Blocker Therapy Prior to Arrival
SCIP VTE-1	Recommended Venous Thromboembolism Prophylaxis Ordered
SCIP VTE-2	Appropriate Venous Thromboembolism Prophylaxis Within 24 Hours Prior to Surgery to 24 Hours After Surgery

Adapted from http://www.jointcommission.org/surgical_care_improvement_project/

Patients should receive prophylactic antibiotics within 1 hour before the incision time. For noncardiac surgery, patients should have prophylactic antibiotics discontinued within 24 hours after surgery end time. If necessary, patient hair should be removed with an electric clipper and not by razor shaving. A temperature of at least 36°C (96.8°F) is necessary 30 minutes before or up to 15 minutes after anesthesia end time.

۰۲۱-۶۶۱۹۸۵۱۴ www.myuptodate.com دریافت آخرین نسخه آپتودیت آفلاین

References:
Chen CL, Shapiro ML, Angood PB, et al. Patient safety. In: Brunicardi FC, Andersen DK, Billiar TR, Dunn DL, Hunter JG, Matthews JB, Pollock RE, eds. *Schwartz's Principles of Surgery.* 9th ed. New York, NY: McGraw-Hill; 2010.
Surgical Care Improvement Project. The Joint Commission. Available at http://www.jointcommission.org/surgical_care_improvement_project/. Accessed October 30, 2011.

2B53

Key word: Sentinel Lymph Node Biopsy for Melanoma

Author: Emmanouil Pappou, MD
Editor: Lisa K. Jacobs, MD

A 45-year-old man is referred to your clinic with a 2-month history of a pigmented skin lesion on his upper back. The lesion is dark and raised with irregular borders and 9 mm diameter. He has no palpable lymphadenopathy and no evidence of in-transit or satellite metastases. Punch biopsy of the lesion reveals melanoma with 2.3 mm thickness, two mitotic figures per mm^2, and no ulceration. Pre-operative lymph node mapping with lymphoscintigraphy identifies a sentinel lymph node in the left axilla. You perform a wide excision with 2-cm margins and a sentinel lymph node biopsy. The result of the lymph node biopsy is positive for cancer. The most appropriate next step is:

(A) Axillary lymphadenectomy levels I and II
(B) Axillary lymphadenectomy levels I and II combined with radiation therapy
(C) Axillary lymphadenectomy levels I, II, and III
(D) Chemotherapy, followed by axillary lymphadenectomy
(E) Radiation therapy, followed by axillary lymphadenectomy

Answer: (C) Axillary lymphadenectomy levels I, II, and III

Rationale:
Melanoma is the fifth most common cancer for males and sixth most common for females in the United States. Approximately 124,000 patients were expected to receive a diagnosis of melanoma in the United States in 2011 with nearly 8,800 resulting deaths. Although melanoma represents less than 5% of all skin cancer diagnoses, at least 75% of skin cancer deaths are attributed to melanoma. The vast majority of mutations found in melanoma are caused by ultraviolet (UV) radiation, and about 65% of melanoma cases can be attributed to UV radiation from the sun. A history of blistering sunburns in childhood or adolescence is a strong risk factor for developing melanoma.

Various clinicopathologic factors have been identified that affect prognosis, including tumor thickness (depth of tumor invasion in millimeters), presence or absence of ulceration, mitotic rate (number of mitoses per mm^2), and presence or absence of regional lymph node spread, which is the single most important independent predictor of survival. Patients with palpable regional lymphadenopathy have at least a 50% risk of future distant metastases.

Evaluation of a patient with a possible melanoma begins with physical examination to search for additional melanomas or clinically suspicious regional lymphadenopathy. Biopsy of the suspected pigmented lesion and histologic assessment of the specimen (tumor thickness, ulceration, and mitotic rate) guide the treatment algorithm of melanoma. Sentinel lymph node biopsy is recommended for all tumors ≥1 mm thick and should also be considered if high risk features are present in

۰۲۱-۶۶۱۹۸۵۱۴ www.myuptodate.com دریافت آخرین نسخه آپتودیت آفلاین

the specimen (ulceration, high mitotic rate [more than one mitosis per mm^2], or presence of lymphovascular invasion) or if the deep margin of the biopsy specimen is positive for cancer. Lymphoscintigraphy using technetium-99m–labeled sulfur colloid is performed preoperatively to identify the appropriate nodal basins and to facilitate intraoperative identification of the sentinel nodes using a handheld gamma probe. Lymphoscintigraphy is particularly helpful in areas (e.g., the trunk, distal extremities, head and neck) that may have drainage to multiple nodal basins.

After intraoperative identification of the sentinel lymph node with a handheld gamma detector (and blue dye), excision of the sentinel node and wide excision of the primary tumor down to the level of the fascia are performed. For melanomas <1 mm thick, wide resection with a 1-cm margin of normal tissue is recommended. For lesions ≥2 mm thick, wide resection with at least a 2-cm margin is recommended. For lesions between 1 and 2 mm in thickness, wide resection with a margin up to 2 cm is recommended if there is adequate tissue for primary closure, while a margin ≥1 cm may be used if a larger margin is not anatomically feasible. Intraoperative frozen sections are not recommended, because they are less accurate than final pathologic assessment of formalin-fixed tissue. For patients with negative sentinel lymph nodes, no further surgery is recommended. For patients with a positive sentinel node, completion lymphadenectomy is the standard of care. Complete axillary lymphadenectomy of levels I, II, and III is currently recommended after a positive axillary sentinel node for patients with melanoma. For a positive femoral node, a superficial node dissection is performed including Cloquet node. The number of positive nodes, the presence of tumor in Cloquet node, and preoperative imaging are used to determine the need for a deep or iliac node dissection. In the head and neck, a formal neck dissection is required. For positive nodes at the popliteal or epitrochlear spaces or other aberrant locations, a formal dissection is not routinely performed. Several retrospective studies have suggested that completion of lymphadenectomy after a positive sentinel lymph node excision might improve survival by 25% to 40%. Prospective randomized trials have not confirmed this survival benefit, although it is possible that there are subsets of patients who benefit from this approach.

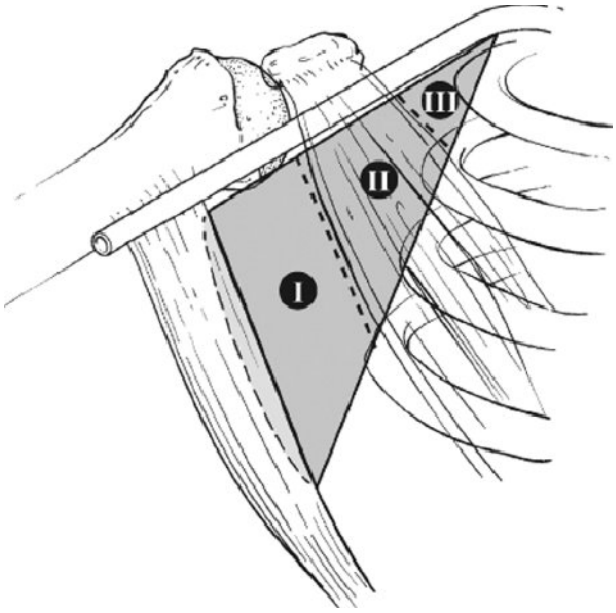

The anatomic extent of axillary lymph node dissection, with levels I, II, and III designated as lying lateral to, behind, or medial to pectoralis minor muscle, respectively. Reprinted with permission from: Cody HS. Sentinel node biopsy and axillary dissection. In: Spear SL, Willey SC, Robb GL, Hammond DC, Nahabedian MY, eds. *Surgery of the Breast: Principles and Art.* 3rd ed. Philadelphia, PA: Lippincott Williams & Wilkins, 2011:111.

References:

Balch CM. Randomized surgical trials involving elective node dissection for melanoma. *Adv Surg.* 1999;32:255–270.

Cody III HS. Sentinel node biopsy and axillary dissection. In: Spear SL, Willey SC, Robb GL, Hammond DC, Nahabedian MY, eds. *Surgery of the Breast: Principles and Art.* 3rd ed. Lippincott Williams & Wilkins; 2011.

Gershenwald JE, Ross MI. Sentinel-lymph-node biopsy for cutaneous melanoma. *N Engl J Med.* 2011;364:1738–1745.

Ross MI, Gershenwald JE. Evidence-based treatment of early-stage melanoma. *J Surg Oncol.* 2011;104:341–353.

۰۲۱-۶۶۱۹۸۵۱۴ www.myuptodate.com دریافت آخرین نسخه آپتودیت آفلاین

2B54

Key word: Treatment of Warfarin-induced Skin Necrosis

Author: Robert A. Meguid, MD, MPH
Editor: Pamela A. Lipsett, MD, MHPE, FACS, FCCM

Two days after starting warfarin as embolic prophylaxis for atrial fibrillation, a 67-year-old woman presents to the emergency room with a 3-cm black patch of sloughing skin on her left buttock. Her international normalized ratio (INR) is 1.2, and her partial thromboplastin time (PTT) is 34 seconds. What is the appropriate management?

(A) Continue warfarin and start wet-to-dry management of buttock wound

(B) Discontinue warfarin, administer intravenous vitamin K, and start topical antibiotics to buttock

(C) Increase dose of warfarin to achieve INR of 2.5 and sharply debride wound on buttock

(D) Initiate heparin infusion, discontinue warfarin, and full-thickness skin graft wound on buttock

(E) Obtain computed tomography (CT) scan of abdomen and pelvis, start subcutaneous low-molecular-weight heparin injection of 100 mg BID, and start broad-spectrum antibiotics

Answer: (D) Initiate heparin infusion, discontinue warfarin, and full-thickness skin graft wound on buttock

Rationale:

Warfarin causes anticoagulation by inhibition of vitamin K-dependent factors (Factors II, VII, IX, X, Protein C, and Protein S). During initiation of systemic anticoagulation with warfarin, Protein C and Factor VII are inhibited before Factors II, IX, and X. This results in a transient state of hypercoagulability prior to systemic anticoagulation being achieved. Skin necrosis with the administration of warfarin occurs due to thrombosis of microvasculature resulting from this transient, warfarin-induced hypercoagulability. Patients with Proteins C or S deficiencies, either congenital or acquired, are prone to this complication.

The resulting full-thickness skin necrosis occurs over poorly vascularized areas such as those overlying fatty tissue in the abdomen, breasts, and buttocks. In addition, venous thromboembolism (VTE) may occur during this transient hypercoagulable state. These complications may be avoided by systemic anticoagulation with direct thrombin inhibitors (e.g., argatroban, bivalirudin, or dabigatran) or heparin prior to administration of warfarin. Management of warfarin-induced skin necrosis entails debridement of necrotic tissue and skin grafting.

Proteins C and S deficiencies account for approximately 2% to 5% of VTE. Protein C has a half-life of 4 to 6 hours, and its co-factor, Protein S, has a half-life of 12 to 14 hours. Both are produced by the liver, and are vitamin K-dependent.

Reference:

Heneke PK, Wakefield TW. Hemostasis. In: Mulholland MW, Lillemoe KD, Doherty GM, Maier RV, Upchurch GR, eds. *Greenfield's Surgery: Scientific Principles and Practice.* 5th ed. Philadelphia, PA: Lippincott Williams and Wilkins; 2011.

۰۲۱-۶۶۱۹۸۵۱۴ www.myuptodate.com دریافت آخرین نسخه آپتودیت آفلاین

2B55

Key word: Sources of Postoperative Intra-abdominal Infection

Author: Kyle J. Van Arendonk, MD, PhD
Editor: Barish H. Edil, MD

A 26-year-old man suffers multiple gun shot wounds to his abdomen. He is left with an open abdomen after an exploratory laparotomy reveals multiple small bowel injuries and a massive liver injury controlled with abdominal packing. Over the course of the next week, he returns to the operating room twice for abdominal washouts. He remains critically ill and continues to require vasopressors for hemodynamic support. Which statement is correct regarding the use of antifungal agents in this patient?

(A) Antifungal prophylaxis is proven to decrease his risk of mortality

(B) Antifungal prophylaxis will not decrease his risk of fungal infection

(C) Antifungal treatment should be used only in the setting of positive fungal blood cultures

(D) Fluconazole may be inadequate treatment for infection with some Candida species

(E) He should be provided intravenous micafungin for prophylaxis

Answer: (D) Fluconazole may be inadequate treatment for infection with some Candida species

Rationale:

Hospital-acquired fungal infections have increased in recent years, and critically ill surgical patients are at especially high risk. Risk factors for invasive fungal infection include extended length of stay in the intensive care unit, the presence of multiple comorbidities, immunosuppression (including neutropenia and the use of corticosteroids), diabetes, broad-spectrum antibiotic administration, the presence of medical devices including central venous catheters, and the use of total parenteral nutrition or renal replacement therapy. Several scoring systems have been proposed to quantify the risk of fungal infections based on these risk factors.

Because of the considerable morbidity and mortality associated with invasive fungal infections among the critically ill, the practice of antifungal prophylaxis was introduced in some centers. Prophylaxis is typically provided in the form of 400 mg of enteral fluconazole administered daily in patients with normal renal function. A meta-analysis of four double-blinded, randomized studies evaluating this practice found that fluconazole prophylaxis significantly reduced the rate of fungal infections but did not significantly impact patient survival. Current guidelines do therefore recommend fluconazole for prophylaxis in high-risk patients in the intensive care unit.

The diagnosis of fungemia as the cause of a patient's sepsis requires a strong index of suspicion, as blood cultures are frequently false-negatives and the clinical presentation is similar to that of bacteremia. Treatment of an identified invasive fungal infection typically begins with fluconazole, caspofungin, or micafungin. In the critically ill and those with recent fluconazole exposure, caspofungin or micafungin are preferred, with de-escalation to fluconazole as appropriate depending on speciation and susceptibility results. Notably *Candida glabrata* and *Candida krusei* are typically resistant to fluconazole. Empiric treatment for an invasive fungal infection should also be considered in the critically ill, especially in those with fungal isolates from non-bloodstream sites in the presence of fever, hypothermia, prolonged and otherwise unexplained hypotension, and/or inadequate response to antibacterials given for a suspected bacterial infection.

References:

Barie PS. Surgical infections and antibiotic use. In: Towsend CM, Beauchamp RD, Evers BM, Mattox KL, eds. *Sabiston Textbook of Surgery.* 19th ed. Philadelphia, PA: Saunders Elsevier; 2012:265–271.

Shorr AF, Chung K, Jackson WL, et al. Fluconazole prophylaxis in critically ill surgical patients: A meta-analysis. *Crit Care Med.* 2005;33:1928–1935.

۰۲۱-۶۶۱۹۸۵۱۴ www.myuptodate.com دریافت آخرین نسخه آپتودیت آفلاین

2B56

Key word: Staging of Testicular Germ Cell Tumors

Author: Emmanouil Pappou, MD
Editor: Mohamad E. Allaf, MD

A 29-year-old man presents with an enlarging testicular mass first noticed 10 days ago. He denies fever or constitutional symptoms. He has no history of urinary tract infection, epididymitis, inguinal hernia, or sexually transmitted disease and no family history of testicular or other genitourinary cancer. On examination, the right testis contains a 3-cm firm and nontender mass. An ultrasound reveals a mass concerning for testicular cancer. Which of the following tests is necessary for adequate initial staging?

(A) Abdominal magnetic resonance imaging (MRI)

(B) Bone scan

(C) Liver ultrasound

(D) Positron emission tomography–computed tomography (PET–CT)

(E) Serum markers

Answer: **(E)** Serum markers

Rationale:

Testicular tumors are the most common malignancies affecting adult men between the ages of 15 and 35. About 95% of testicular cancers are germ cell tumors and are broadly divided into two categories: Seminomas and nonseminomatous germ cell tumors (NSGCTs). Most of the remaining 5% are sex cord stromal tumors (e.g., Sertoli–Leydig cell tumor). Testicular cancer is usually a clinical diagnosis. A firm, nontender testicular mass in a patient younger than 40 years should be presumed to be malignant until proven otherwise. The use of scrotal ultrasound helps to confirm the diagnosis and to differentiate tumor from hydrocele or epididymitis. The majority of men with a testicular tumor present with a painless mass. Scrotal or lower abdominal pain may be the presenting symptom in up to 10% to 20% of cases. Radical orchiectomy is used to provide both the histologic diagnosis and local tumor control. It is performed through an inguinal incision, and if a tumor is found the spermatic cord is divided at the internal inguinal ring. Less invasive surgical procedures, such as biopsy of the testicle, are generally contraindicated.

Imaging studies should include computed tomography (CT) imaging of the abdomen and pelvis to look for evidence of regional lymph node metastases and CT of the chest to look for evidence of mediastinal lymphadenopathy or pulmonary metastases. Positron emission tomography (PET) scans are of limited use in the initial evaluation because of the frequent occurrence of false-negative results. The sensitivity of CT in determining the presence or retroperitoneal lymph nodes is 70% to 80%. MRI produces similar results to CT scanning in the detection of retroperitoneal lymph nodes. Currently there are no indications for its routine use in the staging of testicular cancer, although it can be helpful if the CT is inconclusive or when a CT is contraindicated, as in the presence of contrast allergy.

The initial evaluation of a patient with testicular cancer includes measurement of three serum tumor markers: Alpha fetoprotein (AFP), which is produced by yolk sac cells, β-human chorionic gonadotropin (β-hCG), which is produced by trophoblasts, and in the case of advanced tumors also lactate dehydrogenase (LDH). Serum tumor markers are prognostic factors and contribute to the diagnosis and staging. Serum tumor markers should be measured before and after orchiectomy to determine the half-life kinetics. The persistence of elevated serum tumor markers after orchiectomy indicates the presence of metastatic disease. Normalization of marker levels after orchiectomy, however, does not rule out the presence of tumor metastases.

Serum levels of AFP and/or β-hCG are elevated in 80% to 85% of men with NSGCTs, whereas less than 30% of seminomas have elevated β-hCG. AFP is not elevated in pure seminomas. LDH (a marker of tissue destruction) is a less specific marker, and its concentration is proportional to the tumor volume. Its level can be elevated in up to 80% of patients with advanced testicular cancer.

For localized seminomas, an extremely high cure rate can be achieved with radical orchiectomy alone. In the presence of retroperitoneal disease, men with seminomas can be treated with radiation therapy or cisplatin-based chemotherapy after orchiectomy based on the extent of the disease. NSGCTs with retroperitoneal lymph node involvement can be treated with either retroperitoneal lymph node dissection or adjuvant chemotherapy after orchiectomy. For those with more extensive disease, chemotherapy is generally used. Adjuvant chemotherapy can also be used for NSGCTs that have positive lymph nodes identified with a retroperitoneal lymph node dissection. Advanced testicular germ cell tumors are generally treated with cisplatin-based combination chemotherapy. During chemotherapy, tumor markers should decline; persistence has an adverse prognostic value.

References:

Albers P, Algaba F, Cohn-Cedermark G, et al. Diagnosis, staging, and risk factors: SIU/ICUD Consensus Meeting on Germ Cell Tumors (GCT), Shanghai 2009. *Urology.* 2011; 78(4 Suppl):S427–S434.

Klein EA. Tumor markers in testis cancer. *Urol Clin North Am.* 1993;20(1):67–73.

۰۲۱-۶۶۱۹۸۵۱۴ www.myuptodate.com دریافت آخرین نسخه آپتودیت آفلاین

2B57

Key word: TPN Component Adjusted in Renal Insufficiency

Author: Isaac Howley, MD
Editor: Elliott R. Haut, MD, FACS

Which of the following represents a rational approach to total parenteral nutrition (TPN) in surgical patients with acute renal failure?

(A) Lipids should be removed from the TPN formulation to avoid n-6 fatty acids that stimulate inflammatory mediators

(B) Multivitamins should be eliminated from the solution to avoid build-up of toxic levels of vitamins A, D, E, and K

(C) Potassium should be minimized or eliminated to avoid hyperkalemia

(D) Proteins should be minimized in formulations for patients on continuous venovenous hemodialysis (CVVHD) to reduce the risk of uremia

(E) Sodium should be given in high concentration to maximize serum osmolarity and avoid edema associated with renal failure

Answer: (C) Potassium should be minimized or eliminated to avoid hyperkalemia

Rationale:

The use of TPN reduces the body's ability to self-regulate its metabolic intake, presenting special dangers in patients with reduced renal function. Care of the critically ill patient with renal failure depends on ensuring that metabolic needs are met while electrolytes and metabolic byproducts are kept below toxic levels. Indications for dialysis include hypervolemia, profound acidosis, hyperkalemia, profound uremia (BUN > 100 mg/dL), and risk for calciphylaxis (calcium–phosphate product >55 mg^2/dL^2). If not carefully determined, TPN formulations can quickly lead to any of these abnormalities.

Of the metabolic derangements due to renal failure, hyperkalemia is one of the most common and dangerous, potentially causing sudden cardiac death. The vast majority of potassium is stored in the intracellular space, and it is difficult to cause clinically significant hypokalemia in patients with renal failure. Potassium in the TPN formulation for those with renal failure should therefore be minimized or eliminated to avoid hyperkalemia.

Serum sodium concentration is rarely a cause of significant concern in renal failure. It is important to remember that while pulmonary edema may cause respiratory failure, peripheral edema has little to no impact on patient outcomes. Pulmonary edema generally occurs only after several liters of volume overload in patients with adequate cardiac function. While functional kidneys regulate intravascular volume via several Na^+-dependent pumps in the nephron and collecting duct system, failing kidneys have a limited ability to do this. However, typical TPN volumes of 1.5 to 2 L/day for most adults rarely cause volume increases beyond what can be removed by intermittent hemodialysis in patients with cardiovascular reserve.

There is some concern that n-6 fatty acids (omega-6 fatty acids), found in the commercially available TPN lipid supplement Intralipid, may increase systemic inflammation in their role as arachidonic acid precursors. While there is no strong evidence that this affects clinical outcomes, there is theoretical interest in minimizing lipid administration to patients whose primary disorder is inflammatory in nature, especially patients with pancreatitis. While there may be some degree of inflammation in acute kidney injury, there is little reason to think that the deleterious effects of n-6 fatty acid administration outweigh the benefit of maintaining caloric intake while minimizing high dextrose loads that may cause hyperglycemia.

Protein administration is necessary to sustain amino acid stores that provide substrates for acute phase reactants, tissue growth, and wound healing. However, protein is also metabolized in part to urea. Thus, protein administration causes some degree of uremia. There is experimental evidence that limiting protein administration to essential amino acids in patients with renal failure helps avoid dialysis, expedite diuresis, and improve survival. However, once a patient has already been shown to require renal replacement therapy, urea nitrogen can be easily removed, and there is no reason to minimize protein and thereby risk malnutrition.

There is a low incidence of vitamin toxicity in surgical patients with renal failure, and rarely is there reason to withhold multivitamins from the TPN formulation.

Reference:

Tawa NE, Fischer, JE. Metabolism in surgical patients. In: Townsend CM, Beauchamp RD, Evers BM, Mattox KL, eds. *Sabiston Textbook of Surgery.* 18th ed. Philadelphia, PA: Saunders Elsevier; 2008:143–190.

۰۲۱-۶۶۱۹۸۵۱۴ www.myuptodate.com دریافت آخرین نسخه آپتودیت آفلاین

2B58

Key word: Adult Caloric Supply for TPN

Author: Bonnie E. Lonze, MD, PhD
Editor: Albert Chi, MD

A 42-year-old 60 kg woman has developed short gut syndrome after having undergone numerous small bowel resections. She requires total parenteral nutrition (TPN) due to malabsorption. In preparing the initial TPN order, the most appropriate number of total calories to provide would be:

(A) 1,200 kcal

(B) 1,500 kcal

(C) 2,400 kcal

(D) 3,000 kcal

(E) Cannot be calculated without determining total protein requirements

Answer: (B) 1,500 kcal

Rationale:

Over 200 predictive equations (including Harris–Benedict, Schofield, and Ireton-Jones) have been published in the literature. Energy requirements may be calculated either through simplistic formulas (25 to 30 kcal/kg/day), published predictive equations, or the use of indirect calorimetry. Calories provided via infusion of propofol should be considered when calculating the nutrition regimen.

The basal metabolic rate in normal patients is estimated to be 25 kcal/kg/day. For this 60 kg patient, that would equate to 1,500 kcal/day. Estimates of caloric needs are adjusted depending upon the clinical scenario. For critically ill patients in the intensive care unit, for example, daily caloric requirements can be much higher. For patients on chronic parenteral nutrition, caloric needs are adjusted over the long-term by monitoring patient weight. Precise calculations of caloric expenditure can be calculated by measuring oxygen consumption (indirect calorimetry).

In the critically ill obese patient, permissive underfeeding or hypocaloric feeding is recommended. For all classes of obesity where body mass index (BMI) is greater than 30, the goal of the nutritional regimen should not exceed 60% to 70% of target energy requirements or 11 to 14 kcal/kg actual body weight per day (or 22 to 25 kcal/kg ideal body weight per day). Protein should be provided in a range ≥2 g/kg ideal body weight per day for Class I and II patients (BMI 30 to 40), and ≥2.5 g/kg ideal body weight per day for Class III (BMI ≥40).

Reference:

McClave SA, Martindale RG, Vanek VW, et al.; A.S.P.E.N. Board of Directors; American College of Critical Care Medicine; Society of Critical Care Medicine. Guidelines for the provision and assessment of nutrition support therapy in the adult critically ill patient: Society of Critical Care Medicine (SCCM) and American Society for Parenteral and Enteral Nutrition (A.S.P.E.N.). *JPEN J Parenter Enteral Nutr.* 2009;33(3):277–316.

Smith JS, Jr, Frankenfield DC. Nutrition and metabolism. In: Mulholland MW, Lillemoe KD, Doherty GM, Maier RV, Upchurch GR, eds. *Greenfield's Surgery: Scientific Principles and Practice.* 5th ed. Philadelphia, PA: Lippincott Williams and Wilkins; 2011.

۰۲۱-۶۶۱۹۸۵۱۴ www.myuptodate.com دریافت آخرین نسخه آپتودیت آفلاین

2B59

Key word: Amino Acid which Enhances Immune Function

Author: Jose H. Salazar, MD
Editor: Pamela A. Lipsett, MD, MHPE, FACS, FCCM

Which of the following amino acids has been clinically proven to improve immunologic function?

(A) Alanine
(B) Glutamine
(C) Leucine
(D) Proline
(E) Valine

Answer: (B) Glutamine

Rationale:
Glutamine is a nonessential amino acid, but it becomes a conditional essential amino acid in catabolic states such as trauma and sepsis. It is synthesized by the enzyme glutamine synthetase from glutamate and ammonia. Its immune effects are important for production of IL-2, for adaptive immunity in regulation of T-cells and B-cell differentiation, and for the innate immune system in enhancement of phagocytosis and superoxide production in neutrophils and macrophages. Its other functions include roles in protein synthesis and cellular respiration; it also acts as the main energy substrate for enterocytes and inflammatory cells. Studies have shown a decrease in infectious complications in burn and surgical patients with the use of glutamine, but these improvements have not led to a demonstrable decrease in mortality.

References:
Garrel D, Patenaude J, Nedelec B, et al. Decreased mortality and infectious morbidity in adult burn patients given enteral glutamine supplements: a prospective, controlled, randomized clinical trial. *Crit Care Med.* 2003;3(10): 2444–2449.
Jayarajan S, Daly JM. The relationships of nutrients, routes of delivery, and immunocompetence. *Surg Clin North Am.* 2011;91(4):737–753, vii.
Schulman AS, Willcutts KF, Claridge JA, et al. Does the addition of glutamine to enteral feeds affect patient mortality? *Crit Care Med.* 2005;33(11):2501–2506.

2B60

Key word: Comparison of Somatic and Visceral Pain

Author: Jose H. Salazar, MD
Editor: Asad Latif, MBBS, MPH

A 52-year-old female patient presents with nausea, vomiting, abdominal distension, and abdominal pain. She has not passed flatus during this time and describes her pain as intermittent, dull, and diffusely generalized across her abdomen. The most likely origin and path for her abdominal pain is:

(A) Referred pain to abdominal striated musculature
(B) Somatic pain via autonomic nerves
(C) Somatic pain via spinal nerves
(D) Visceral pain via autonomic nerves
(E) Visceral pain via spinal nerves

Answer: (D) Visceral pain via autonomic nerves

Rationale:
The peritoneum consists of two layers: visceral and parietal. The visceral peritoneum is supplied by autonomic nerves. Pain associated with the visceral peritoneum, such as that which arises in small bowel obstruction, usually manifests as intermittent, dull, poorly localized, and cramping pain. The visceral peritoneum is sensitive to stretch, distention, vigorous contraction against resistance, chemical irritation, ischemia, and inflammation but is insensitive to touch, pinching, cutting, burning, and electrical stimulation.

The parietal peritoneum, on the other hand, has somatic innervation derived from spinal nerves. Pain associated with the parietal peritoneum is generally sharp, severe, and persistent. This pain is often associated with rigidity and tenderness of overlying muscle groups. The transition from visceral to somatic pain can signify the progression of intra-abdominal disease. For example, distention of the appendix in patients with appendicitis typically leads to the initial onset of vague periumbilical pain. With progression of the disease and irritation of the parietal peritoneum overlying the appendix, the pain then becomes sharp and localized to the right lower quadrant region.

Reference:
Matthews JB, Hodin RA. Acute abdomen and appendix. In: Mulholland MW, Lillemoe KD, Doherty GM, Maier RV, Simeone DM, Upchurch GR, eds. *Greenfield's Surgery: Scientific Principles and Practice.* 5th ed. Philadelphia, PA: Lippincott Williams & Wilkins; 2011:1200.

۰۲۱-۶۶۱۹۸۵۱۴ www.myuptodate.com دریافت آخرین نسخه آپتودیت آفلاین

2B61

Key word: Cytokine Treatment of Renal Cell Carcinoma

Author: Jose H. Salazar, MD
Editor: Mohamad E. Allaf, MD

A 55-year-old man is currently undergoing chemotherapy for metastatic renal cell carcinoma. He is admitted to the hospital from the outpatient chemotherapy ward after sustained hypotension and tachycardia. Which of the following chemotherapeutic agents used for renal cell carcinoma is most likely to blame?

(A) Bevacizumab
(B) Cisplatin
(C) IL-2
(D) Sorafenib
(E) Sunitinib

Answer: (C) IL-2

Rationale:
Chemotherapy against renal cell carcinoma (RCC) has changed dramatically in the last decade. Metastatic RCC is generally resistant to standard chemotherapy. Alternative methods, such as cytokine therapy with IL-2 and IFN-α have been relatively successful in improving prognosis for these patients. Unfortunately, cytokine therapy is associated with significant toxicity and is poorly tolerated. The most common and severe side effects of IL-2 are hypotension (usually responsive to intravenous fluids) and tachycardia (probably secondary to hypotension). The mechanisms of action for cytokine therapy are poorly understood. Antitumor activity is thought to occur via immunologic destruction of tumor cells by natural killer (NK) cells and activated T-cells.

Several other new agents have also shown potential for treatment of RCC. These include the oral agents sunitinib and sorafenib, which inhibit protein kinases that lie in signaling pathways controlling tumor growth and angiogenesis, and the intravenous drug bevacizumab, which is a monoclonal antibody that inhibits vascular endothelial growth factor A (VEGF-A). These agents are generally well tolerated and are not associated with the development of hypotension. Cisplatin has no current role in the treatment of RCC.

Reference:
Oudard S, George D, Medioni J, et al. Treatment options in renal cell carcinoma: past, present and future. *Ann Oncol.* 2007;18(Suppl 10):x25–x31.

2B62

Key word: Definition of Adverse Event

Author: Joshua H. Wolf, MD
Editor: Martin A. Makary, MD, MPH

A prospective clinical trial examining the benefit of a new drug is halted because several patients have experienced an adverse event while enrolled in the study. An adverse event is best defined as which of the following?

(A) A complication associated with a particular therapy that occurs in at least three patients
(B) An outcome that contradicts a study's underlying hypothesis
(C) Any unwanted experience associated with a medication, device, procedure, or other aspect of medical care
(D) Any unwanted outcome that does not result in a death
(E) Death or hospitalization during the trial period

Answer: (C) Any unwanted experience associated with the use of a medication, device, procedure, or other aspect of medical care

Rationale:
An adverse event is any undesirable event. Examples of adverse events include falls, infections, medication dosing errors, and iatrogenic injuries. An adverse event may or may not be preventable. An adverse event does not necessarily need to occur during the period of treatment or intervention and does not need to involve multiple patients. True causal relationships are difficult to establish when event numbers are small, as is often the case.

References:
Chen CL, Shapiro ML, Angood PB, et al. Patient safety. In: Brunicardi FC, Andersen DK, Billiar TR, Dunn DL, Hunter JG, Matthews JB, Pollock RE, eds. *Schwartz's Principles of Surgery.* 9th ed. New York, NY: McGraw-Hill; 2010.
Safety. U.S. Food and Drug Administration. Available from http://www.fda.gov/safety/medwatch/howtoreport/ucm053087.htm. Accessed October 20, 2011.

۰۲۱-۶۶۱۹۸۵۱۴ www.myuptodate.com دریافت آخرین نسخه آپتودیت آفلاین

2B63

Key word: Design of T-tests

Author: Joshua H. Wolf, MD
Editor: Dorry L. Segev, MD, PhD

Which of the following would be best analyzed using an unpaired t-test?

(A) A comparison of height in a group of pediatric patients with short gut syndrome to the average height for their age group

(B) A comparison of postoperative bilirubin levels in two different groups of hepatectomy patients, one of which has data that are not normally distributed

(C) A comparison of pre- and postoperative weight in a single group of bariatric patients

(D) A comparison of serum albumin levels taken serially in two groups of patients with ARDS over multiple time points

(E) A comparison of white blood cell counts in two different groups of patients on postoperative day 3 following splenectomy

Answer: (E) A comparison of white blood cell counts in two different groups of patients on postoperative day 3 following splenectomy

Rationale:
The unpaired Student t-test is a comparison of means between two independent groups of normally distributed data. The incorrect answer choices above each require a different analysis. Choice **(A)** requires a one-sample t-test, in which the mean for a group is compared to a single value, usually the mean for a more general population. Choice **(B)** violates the assumption of normality (relevant for all types of t-tests) and therefore requires either a transformation to normalize the data or use of a nonparametric method. The most common nonparametric method is the Wilcoxon rank-sum (or Mann–Whitney) test. Choice **(C)** requires a paired t-test, which can compare means (assuming weight is normally distributed) between two time points for the same group of patients. Choice **(D)** is incorrect because it will require a longitudinal study that can integrate more than two time points into a single analysis. Had only two time points been chosen, a paired t-test could be used.

Reference:
Dawson B, Trapp RG. Research questions about two separate or independent groups. In: Dawson B, Trapp RG, eds. *Basic and Clinical Biostatistics.* 4th ed. New York, NY: McGraw-Hill; 2004:134–162.

2B64

Key word: Function Recovery Postneuromuscular Block

Author: Jose H. Salazar, MD
Editor: Asad Latif, MBBS, MPH

A 40-year-old male patient is undergoing a two-stage operation to be performed over 2 days. After the first operation, the patient remains intubated and is taken to the surgical intensive care unit for postoperative management. The anesthesiologist states that the patient did not have reversal of his neuromuscular blockade. The longest period of neuromuscular blockade would be expected with which of the following agents?

(A) Mivacurium

(B) Pancuronium

(C) Rocuronium

(D) Succinylcholine

(E) Vecuronium

Answer: (B) Pancuronium

Rationale:
Neuromuscular-blocking drugs interact with nicotinic acetylcholine receptors at the neuromuscular junction. They can have one of two potential mechanisms of action. Depolarizing agents (succinylcholine) act as agonists at the acetylcholine receptors, first causing muscle contraction followed by paralysis. Nondepolarizing agents (all the rest of the neuromuscular-blocking drugs) are competitive antagonists at the acetylcholine receptors, leaving fewer receptors available for acetylcholine to act upon.

Succinylcholine has a rapid onset (30 to 90 seconds) and short duration of action (25% neuromuscular recovery at 6 to 8 minutes). Mivacurium is a short duration agent (25% recovery neuromuscular at 15 to 20 minutes). Rocuronium and vecuronium are intermediate duration agents (25% neuromuscular recovery at 30 to 45 minutes), and pancuronium is one of the longest duration agents (25% recovery at 60 to 120 minutes).

Reference:
Donati F, Bevan DR. Neuromuscular blocking agents. In: Barash PG, Cullen BF, Stoelting RK, Cahalan MK, Stock MC, eds. *Clinical Anesthesia.* 6th ed. Philadelphia, PA: Lippincott Williams & Wilkins; 2009:498–527.

۰۲۱-۶۶۱۹۸۵۱۴ www.myuptodate.com دریافت آخرین نسخه آپتودیت آفلاین

2B65

Key word: Major Limitations of Retrospective Clinical Studies

Author: Jose H. Salazar, MD
Editor: Dorry L. Segev, MD, PhD

A surgery resident is interested in studying pancreatic sarcomas. She wants to estimate the relative odds of the association between a putative risk factor and this rare disease. What is the most appropriate and efficient study for this research question?

(A) Cross-sectional survey
(B) Prospective cohort study
(C) Randomized clinical trial
(D) Retrospective case-control study
(E) Retrospective observational study

Answer: (D) Retrospective case-control study

Rationale:
Case-control studies have the advantage of being a relatively efficient method of studying risk factors for disease. They are good for studying rare entities, and multiple exposures can be studied at the same time. Still, they carry their own limitations, as they only provide an estimate of relative and not absolute risk, they do not provide information on the temporal relation between exposure and outcome, and they are prone to some forms of selection bias, observation bias, and confounding.

Randomized clinical trials are interventional studies that do not answer questions about risk factors (unless the "risk factor" is the intervention). Pancreatic sarcoma is a very rare disease. In retrospective observational or prospective cohort studies, an entire population needs to be sampled, so this population would need to be extremely large to contain enough cases of such a rare disease. Cross-sectional surveys provide data on an entire population at a specific point in time and are often used to assess the prevalence of a given condition.

Reference:
Hajat C. Introduction to epidemiology. In: Teare MD. ed. *Genetic Epidemiology (Methods in Molecular Biology).* New York, NY: Springer, 2011:27–39.

2B66

Key word: Major Modification of Tumor Cell Response

Author: Jose H. Salazar, MD
Editor: Elizabeth C. Wick, MD

A 68-year-old male patient is being treated for relapsing non-Hodgkin lymphoma. He is started on a monoclonal antibody by his medical oncologist. Which agent was likely used?

(A) Chimeric antibody that targets EGFR
(B) Chimeric IgG1 anti-CD20 antibody
(C) Humanized antibody against CD52
(D) Humanized antibody against VEGF
(E) Humanized IgG1 that targets the her2/neu antigen

Answer: (B) Chimeric IgG1 anti-CD20 antibody

Rationale:
Monoclonal antibodies (mAbs) are now used routinely for the treatment of cancer. mAbs bind to tumor cells and can be used to focus an inflammatory response against the tumor through chemotaxis, activation of complement, formation of the membrane attack complex, and antibody-dependent cell-mediated cytotoxicity.

Rituximab is a chimeric IgG1 anti-CD 20 antibody used for relapsed/refractory low-grade B-cell non-Hodgkin lymphoma. Cetuximab is a chimeric mAb that targets EGFR and is used for metastatic colon cancer. Trastuzumab is a humanized IgG1 mAb that targets the her2/neu antigen in patients with breast cancer. Alemtuzumab is a humanized mAb that targets CD52 and is used for chronic lymphocytic leukemia (CLL). Bevacizumab is a humanized mAb against VEGF that is used for metastatic colon cancer.

Reference:
Jurcic JG, Mulford DA, Scheinberg DA. Monoclonal antibody therapy of cancer. In: Kaufman HL, Wolchok JD, eds. *General Principles of Tumor Immunotherapy.* Dordrecht, the Netherlands: Springer; 2007:319–342.

۰۲۱-۶۶۱۹۸۵۱۴ www.myuptodate.com دریافت آخرین نسخه آپتودیت آفلاین

2B67

Key word: Molecules which Mediate Leukocytosis in Inflammation

Author: Jose H. Salazar, MD
Editor: Elizabeth C. Wick, MD

A 74-year-old male patient underwent a pancreaticoduodenectomy for pancreatic adenocarcinoma. His postoperative course was complicated by a large leak at his pancreaticojejunostomy. The patient developed septic shock and subsequently died of multiorgan failure. If immunohistochemical analysis were performed 1 hour after death, which of the following cells would likely be decreased?

(A) B-cells
(B) CD8 T-cells
(C) Macrophages
(D) Monocytes
(E) Natural killer (NK) cells

Answer: **(A)** B-cells

Rationale:
Autopsy and immunohistochemical studies in patients who died of sepsis have revealed a marked decrease in the number of B-cells, CD4 T-cells, and follicular dendritic cells. These effects on adaptive immunity are opposite what is expected since a clonal expansion should be the physiologic response to a life-threatening infection. The mechanism of these changes is not completely understood but is believed to be a sepsis-induced acceleration of the normal physiologic process of rapid turnover of lymphocytes. Levels of CD8 T-cells, NK cells, and macrophages/monocytes are not significantly affected.

Reference:
Hotchkiss RS, Karl IE. The pathophysiology and treatment of sepsis. *N Engl J Med.* 2003;348:138–150.

2B68

Key word: Most Representative Descriptive Statistic

Author: Jose H. Salazar, MD
Editor: Dorry L. Segev, MD, PhD

A retrospective study of 50 patients was performed to evaluate total hospital charges after laparoscopic versus open pancreaticoduodenectomy. The distribution of charges was generally symmetric, but two patients in the open group had a significantly prolonged hospital stay and therefore had total hospital charges that were extremely high. Which of the following statistical measures will likely be affected most for the open group?

(A) 25th percentile
(B) Interquartile range
(C) Mean
(D) Median
(E) Mode

Answer: **(C)** Mean

Rationale:
The mean describes the sum of all data points divided by the number of observations. This measure is easy to interpret but also has the disadvantage of being quite sensitive to extreme outliers. The median, which is the value that lies exactly in the middle of a continuous set of data points, is less sensitive to extreme outliers and is therefore a better measure to report in incidences of skewed distributions. The mode is the most frequently observed value. The interquartile range is the range in values between the 25th and the 75th percentile.

Reference:
Rosner B. Descriptive statistics. *Fundamentals of Biostatistics.* 7th ed. Boston, MA: Brooks/Cole Publishing; 2010:5–37.

۰۲۱-۶۶۱۹۸۵۱۴ www.myuptodate.com دریافت آخرین نسخه آپتودیت آفلاین

2B69

Key word: Narcotic with Greatest Potency

Author: Jose H. Salazar, MD
Editor: Asad Latif, MBBS, MPH

Which of the following represents the most potent opioid dose?

(A) 2 mg of hydromorphone

(B) 30 mg of morphine

(C) 5 μg of sufentanil

(D) 5 mg of methadone

(E) 50 μg of fentanyl

Answer: (B) 30 mg of morphine

Rationale:
Narcotics vary in their potency due to differences in their pharmacokinetics and pharmacodynamics. The potency of narcotics is commonly assessed as relative to 1 mg of morphine:

- fentanyl: 50–100×
- sufentanil: 500–1000×
- hydromorphone: 5–10×
- methadone: 3–4×
- oxycodone: 1.5–2×
- meperidine, codeine, and tramadol: 0.1×

Reference:

Kheterpal S, Rutter TW, Tremper KK. Anesthesiology and pain management. In: Mulholland MW, Lillemoe KD, Doherty GM, Maier RV, Simeone DM, Upchurch GR, eds. *Greenfield's Surgery: Scientific Principles and Practice.* 5th ed. Philadelphia, PA: Lippincott Williams & Wilkins; 2011: 240–241.

2B70

Key word: Platelet Adherence after Tissue Injury

Author: Jose H. Salazar, MD
Editor: Nicole M. Chandler, MD

A 28-year-old male is taken to the operating room for an elective inguinal hernia repair. During preoperative evaluation, he is noted to have Type I von Willebrand disease. Which of the following is true regarding this scenario?

(A) Desmopressin (DDAVP) is ineffective for this condition

(B) Platelet aggregation response to ristocetin will be abnormal

(C) The disease is inherited in an autosomal recessive fashion

(D) The disease results in qualitatively abnormal von Willebrand factor

(E) The patient should be given cryoprecipitate and platelets prior to incision

Answer: (B) Platelet aggregation response to ristocetin will be abnormal

Rationale:
The most common coagulation factor deficiencies are hemophilia A (Factor VIII deficiency) and B (Factor IX deficiency) and Type I von Willebrand disease (vWD). Type I vWD is an autosomal dominant condition resulting in a reduced quantity of otherwise normal vWF. On the other hand, Type II vWD, although also autosomal dominant, results in defective, nonfunctional vWF. Type III vWD is autosomal recessive and results in the absence of vWF and the most severe bleeding risk. vWD typically presents with bruising, epistaxis, gingival bleeding, menorrhagia, or prolonged bleeding after surgery.

vWF is produced in both megakaryocytes and endothelial cells. In combination with Factor VIII, it initiates platelet plug formation by adhering platelets to collagen. Laboratory testing in vWD typically reveals a normal prothrombin time (PT), a prolonged partial thromboplastin time (PTT), a prolonged bleeding time, decreased levels of vWF, and an abnormal platelet aggregation response to ristocetin.

For mild vWF deficiency (Type I disease), therapy with DDAVP, which stimulates release of vWF, is usually sufficient for patients undergoing minor surgical procedures. If a patient suffers from severe vWF deficiency (Type III disease) or is undergoing a major operation, vWF:Factor VIII concentrate is the best treatment. DDAVP is rarely effective for Type II disease, and vWF:Factor VIII concentrate is usually required. Although cryoprecipitate is a reliable source of vWF, due to its infectious risks (not virally inactivated) and the availability of vWF:Factor VIII concentrate, its role is generally limited to trauma or acute, life-threatening bleeding. Platelet transfusion is an inadequate treatment for vWD as it does not address the primary underlying pathology—vWF deficiency.

۰۲۱-۶۶۱۹۸۵۱۴ www.myuptodate.com دریافت آخرین نسخه آپتودیت آفلاین

Reference:
Henke PK, Wakefield TW. Hemostasis. In: Mulholland MW, Lillemoe KD, Doherty GM, Maier RV, Simeone DM, Upchurch GR, eds. *Greenfield's Surgery Scientific Principles & Practice.* 5th ed. Philadelphia, PA: Lippincott Williams & Wilkins; 2011.

2B71

Key word: Prompt Formation of Platelet Plug

Author: Betsy King, MD
Editor: Ying Wei Lum, MD

As you are closing the incision on a patient with von Willebrand disease, your astute medical student notices that the patient's wound surfaces are especially oozy. He asks how von Willebrand disease leads to excessive bleeding. You tell him that the functional von Willebrand protein is important for which of the following?

(A) Activation of phosphatidylinositol diphosphate pathway
(B) Adherence of platelets to subendothelial collagen
(C) Aggregation of platelets via fibrinogen
(D) Localized vasoconstriction
(E) Platelet activation and release of granule contents

Answer: (B) Adherence of platelets to subendothelial collagen

Rationale:
von Willebrand disease is the most common congenital bleeding disorder and is associated with either a quantitative or qualitative deficiency in von Willebrand factor. Along with several other proteins, von Willebrand factor is vital to prompt formation of the platelet plug, in particular through adherence of platelets to subendothelial collagen. Effective hemostasis relies on the initial formation of this stable platelet plug within 1 to 3 minutes after vascular injury. Platelet function is achieved through three steps: Adherence, activation, and granular release.

Vascular insults result in exposure of subendothelial extracellular matrix proteins, including collagen. Platelets quickly adhere to collagen via the GPIb surface receptor, an interaction that is facilitated by von Willebrand factor.

Platelet binding to subendothelial collagen initiates a signaling cascade that utilizes the phosphatidylinositol signaling pathway. Resultant intracellular calcium activates platelet glycoprotein GPIIb/IIIa receptor to bind fibrinogen, leading to platelet aggregation and maturation of the platelet plug.

Platelet activation also stimulates release of granule contents. Platelet granules contain adhesive proteins, signaling molecules, growth factors, and procoagulants, which promote platelet function in hemostasis. Thromboxane A2, one of the molecules released from platelet granules, promotes localized vasoconstriction. In addition, it triggers further release of calcium stores to enhance platelet aggregation and clot formation.

References:
Konkle B. Disorders of platelets and vessel wall. In: Longo DL, Fauci AS, Kasper DL, Hauser SL, Jameson JL, Loscalzo J, eds. *Harrison's Principles of Internal Medicine.* 18th ed. New York, NY: McGraw-Hill; 2012. http://www.accessmedicine.com/content.aspx?aID=9100733. Accessed May 9, 2013.
Rutherford EJ, Brecher ME, Fakhry SM, et al. Hematologic principles in surgery. In: Towsend CM, Beuchamp RD, Evers BM, Mattox KL, eds. *Sabiston Textbook of Surgery.* 18th ed. Philadelphia, PA: Saunders Elsevier; 2008.

۰۲۱-۶۶۱۹۸۵۱۴ www.myuptodate.com دریافت آخرین نسخه آپتودیت آفلاین

2B72

Key word: Patient at Risk of Alloimmune Response Postabdominal Trauma

Authors: Brenessa M. Lindeman, MD, and Kyle J. Van Arendonk, MD, PhD
Editor: Albert Chi, MD

A 28-year-old woman who is 22 weeks pregnant presents to the emergency room after a motor vehicle accident and reports mild abdominal pain. A Kleihauer-Betke test suggests the present of fetomaternal hemorrhage (FMH). Which of the following treatments should be considered?

(A) Betamethasone

(B) Immediate delivery

(C) Magnesium

(D) Oxytocin

(E) Rh immune globulin (RhoGAM)

Answer: (E) Rh immune globulin (RhoGAM)

Rationale:

Trauma occurs in approximately 5% of pregnancies and is the leading nonobstetric cause of maternal death during pregnancy. Initial evaluation of the injured pregnant patient proceeds in a similar fashion to that done in a nonpregnant patient, remembering that proper resuscitation of the mother will simultaneously provide proper resuscitation to the fetus. Specific points to remember in treating pregnant trauma patients include the potential for inferior vena cava compression from the gravid uterus (making the left lateral decubitus position ideal to maintain venous return) and the increased blood volume present during pregnancy (meaning signs of blood loss such as tachycardia may be delayed).

FMH, defined as the transplacental hemorrhage of fetal blood into the normally separate maternal circulation, can also occur in approximately 8% to 30% of cases of blunt abdominal trauma in pregnant patients. The complications of FMH are primarily Rh sensitization in the mother and anemia, paroxysmal atrial tachycardia, and death from exsanguination in the fetus. The uterus is relatively protected in the pelvis until approximately 12 weeks of gestation, and thus the potential for injury to the uterus and development of FMH increases after 12 weeks of gestation.

The Kleihauer-Betke test is used to detect FMH. This acid elution technique turns fetal red blood cells purple-pink on microscopy, while adult cells remain colorless. The ratio of fetal cells to maternal cells is then utilized to assess the volume of fetal blood present in the maternal circulation. Because the Kleihauer-Betke test is relatively insensitive, all Rh-negative pregnant patients presenting with abdominal trauma should receive a single prophylactic dose of RhoGAM within 72 hours of the traumatic event, regardless of the result of the Kleihauer-Betke test.

References:

Desjardins G. Management of the Injured Pregnant Patient. TRAUMA.ORG: Trauma in Pregnancy. Available at: http://www.trauma.org/archive/resus/pregnancytrauma.html

Mikami DJ, Beery PR, Ellison EC. Surgery in the pregnancy patient. In: Towsend CM, Beauchamp RD, Evers BM, Mattox KL, eds. *Sabiston Textbook of Surgery.* 19th ed. Philadelphia, PA: Saunders Elsevier; 2012:2041–2042.

۰۲۱-۶۶۱۹۸۵۱۴ www.myuptodate.com دریافت آخرین نسخه آپتودیت آفلاین

2B73

Key word: Respiratory Quotient of Fatty Acid Synthesis

Author: Andrew P. Dhanasopon, MD
Editor: Pamela A. Lipsett, MD, MHPE, FACS, FCCM

A 55-year-old man with an extensive history of tobacco smoking and alcohol abuse is postoperative day 14 from a pancreatic necrosectomy for infected pancreatic necrosis. He has been maintained on total parenteral nutrition and is having trouble weaning off the ventilator. Indirect calorimetry demonstrates a respiratory quotient of 1.2. What can be done to assist his ventilator weaning?

(A) Decrease caloric intake and carbohydrates
(B) Decrease protein intake and increase carbohydrates
(C) Increase caloric intake and carbohydrates
(D) Increase fat intake and increase carbohydrates
(E) Increase protein intake and decrease carbohydrates

Answer: (A) Decrease caloric intake and carbohydrates

Rationale:

The respiratory quotient (RQ) is the ratio of CO_2 produced per O_2 consumed. This patient's RQ is consistent with overfeeding syndrome (RQ > 1), in which excessive caloric intake leads to lipogenesis and production of excess CO_2. This excess CO_2 leads to increased work of breathing and thus difficulty in weaning from the ventilator. Therefore, decreasing caloric intake and carbohydrate (major contributor to CO_2 production), and thus, decreasing CO_2, can assist the patient in weaning from the ventilator **(A)**. An RQ = 1 is indicative of carbohydrate metabolism, an RQ = 0.8 is indicative of protein metabolism, and an RQ ≤ 0.7 is consistent with ketosis and fat metabolism.

Reference:

Barbour JR, Barbour EF, Herrmann VM. Surgical metabolism & nutrition. In: Doherty GM, ed. *Current Diagnosis & Treatment: Surgery.* 13th ed. Columbus: The McGraw-Hill Companies; 2010.

2B74

Key word: Treatment of Reflex Sympathetic Dystrophy

Author: Emmanouil Pappou, MD
Editor: Bradford D. Winters, MD, PhD

A 45-year-old man with a left wrist fracture that was repaired 6 months ago reports developing pain in his left hand a few weeks after the surgery. On examination his left wrist and hand are exquisitely tender to palpation. The skin is thickened and has a brown discoloration. X-ray of the left hand shows focal osteoporosis. The treatment that has been shown to be LEAST effective in the management of this disease is:

(A) Intranasal calcitonin
(B) Intravenous bisphosphonates
(C) Intravenous regional analgesia
(D) Oral vitamin C
(E) Sympathetic nerve blocks

Answer: (C) Intravenous regional analgesia

Rationale:

Complex regional pain syndrome (CRPS), formerly known as reflex sympathetic dystrophy, Sudeck dystrophy, or causalgia, is a highly painful disorder of a particular body region, usually one of the extremities. The syndrome is characterized by a triad of pain (typically continuous burning or shooting and localized deep in the tissues), trophic tissue changes (hair and nail changes, skin atrophy or swelling, patchy bone demineralization), and vasomotor instability (vasodilation or vasoconstriction, skin color and temperature abnormalities, hyperhidrosis or hypohidrosis). CRPS can also impair motor function of the affected body part. Almost one-third of patients may develop tremor or dyskinesia of the affected extremity. In severe cases, the limb can become virtually useless, due to misuse or secondary to edema, fibrosis, and contractures. In about 60% to 70% of cases there is an inciting event for CRPS, such as trauma, surgery, or a vascular event (e.g., stroke). The pathophysiology of this pain syndrome is still controversial. Most investigators suggest a combination of peripheral and central mechanisms—peripheral nerves that are injured are thought to release inflammatory neuropeptides that produce pain and signs of inflammation, while at the same time there is increased activity in the sensory fibers in the dorsal root ganglia of the central nervous system.

CRPS is subdivided into CRPS type I and CRPS type II. CRPS type I is diagnosed when there is no obvious nerve injury and constitutes about 90% of cases, whereas CRPS type II refers to cases with known nerve injury. The diagnosis of CRPS is primarily made clinically. Three stages of the disease have been described: Stage I is characterized by throbbing pain, sensitivity to cold or touch, and edema and can occur as early as 3 weeks after the injury; stage II lasts 3 to 6 months and is marked by progression of the tissue edema, thickening, and discoloration of the skin; stage III is marked by severe fibrosis,

۰۲۱-۶۶۱۹۸۵۱۴ www.myuptodate.com دریافت آخرین نسخه آپتودیت آفلاین

contractures of the digits, and trophic skin changes and may include severe osteoporosis seen on radiograph.

Management of CRPS should be multidisciplinary and instituted immediately following diagnosis. Physical therapy and adequate pain control are key in preventing the development and progression of CRPS. Early sympathetic blocks (e.g., stellate ganglion block for upper limbs or lumbar sympathetic chain block for lower limbs) may prevent the development of CRPS. Vitamin C (500 mg/day) for 50 days has also been shown to significantly decrease the incidence of CRPS after a wrist fracture when compared to placebo. A positive effect of oral glucocorticoids in CRPS has been demonstrated in controlled studies as well. Several randomized trials have shown that intranasal calcitonin and intravenous bisphosphonates (e.g., alendronate) can improve function and symptoms when instituted early in the disease. Surgical sympathectomy has been used with some success in this patient population. Results seem to be best when surgery is performed within 12 months of the original injury. Finally, transcutaneous electrical nerve stimulation is a simple and safe technique that has also been used in CRPS with moderate success. The efficacy of intravenous regional blocks (Bier blocks) using agents such as lidocaine, clonidine, guanethidine, or reserpine is uncertain since a meta-analysis of randomized trials found that they are no better than placebo.

References:

Maihofner C, Seifert F, Markovic K. Complex regional pain syndromes: new pathophysiological concepts and therapies. *Eur J Neurol.* 2010;17(5):649–660.

Perez RS, Kwakkel G, Zuurmond WW, et al. Treatment of reflex sympathetic dystrophy (CRPS type 1): a research synthesis of 21 randomized clinical trials. *J Pain Symptom Manage.* 2001;21(6):511–526.

Stanton-Hicks M, Janig W, Hassenbusch S, et al. Reflex sympathetic dystrophy: changing concepts and taxonomy. *Pain.* 1995;63(1):127–133.

2B75

Key word: Treatment of Acute Paronychia

Author: Kyle J. Van Arendonk, MD, PhD
Editor: Robert A. Meguid, MD, MPH

A 27-year-old man presents to the emergency room reporting severe pain in his right index finger. On examination of the finger, the patient has edema, erythema, fluctuance, and tenderness in the soft tissue surrounding the fingernail. The erythema spreads proximally into his middle phalanx. Which of the following is the most appropriate management of this acute paronychia?

(A) Bilateral, longitudinal incisions of the hyponychium to decompress the infection

(B) Drill through the nail with a sterile heated instrument to decompress the infection

(C) Extended course of oral antibiotics alone

(D) Remove a strip of nail to decompress the infection

(E) Warm soaks and elevation alone

Answer: **(D)** Remove a strip of nail to decompress the infection

Rationale:

Acute paronychia is an infection of the soft tissues surrounding the fingernail—the paronychium and eponychium (see figure)—and is the most common infection of the hand. The most common pathogen implicated in acute paronychia is *Staphylococcus aureus.* The infection begins with edema, erythema, and tenderness surrounding the fingernail and can progress to include an abscess.

Treatment of acute paronychia consists of splint immobilization, warm soaks, and a course of oral antibiotics when no purulence is present. However, in more advanced, purulent infections, drainage must be performed—after elevating from the nail bed the nail plate adjacent to the infection, a longitudinal strip of nail is removed in order the decompress the infection. Further decompression through opening the lateral and/or proximal aspect of the nail fold may also be required. This drainage can be performed using digital anesthesia and a digital tourniquet. Following drainage, antibiotics are continued for 10 to 14 days, splinting and elevation are maintained for approximately 24 hours, and then daily soaks and dressing changes are begun.

Drilling through the nail with a sterile heated instrument is appropriate treatment for a painful subungual hematoma. Bilateral, longitudinal incisions of the hyponychium are appropriate for treatment of a felon, which is an infection of the volar aspect of the fingertip that is contained between the vertical septae.

۰۲۱-۶۶۱۹۸۵۱۴ www.myuptodate.com دریافت آخرین نسخه آپتودیت آفلاین

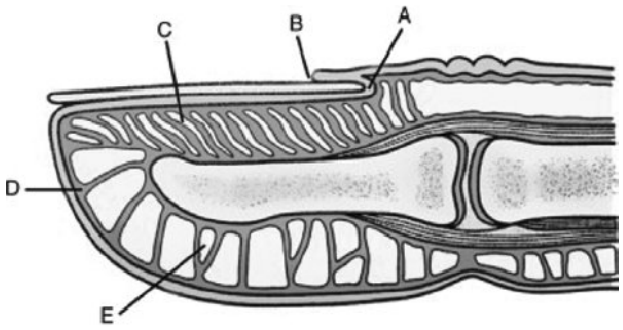

Fingertip anatomy. **A:** Nail fold. **B:** Eponychium. **C:** Nail bed. **D:** Hyponychium. **E:** Vertical septa. The paronychial folds flank the lateral borders of the fingernail. Reprinted with permission from: Brushart TM. Hand Infections. In: Cameron JL, Cameron AM, eds. *Current Surgical Therapy*, 10th ed. Philadelphia, PA: Mosby, 2011:641–642.

Reference:

Brushart TM. Hand infections. In: Cameron JL, Cameron AM, eds. *Current Surgical Therapy.* 10th ed. Philadelphia, PA: Mosby; 2011:641–642.

2B76

Key word: Components Needed for Tacrolimus Absorption

Author: Kelly Olino, MD
Editor: Andrew M. Cameron, MD, PhD

A 50-year-old male is status post deceased donor renal transplant for diabetic nephropathy. He is found to have a markedly reduced tacrolimus level despite having no change in his regular dose. The cause of his decreased level is most likely due to which recent change in his medication history?

(A) Treatment of a fungal infection with fluconazole

(B) Treatment of *Clostridium difficile* infection with metronidazole

(C) Treatment of gastroparesis with metoclopramide

(D) Treatment of hypertension with diltiazem

(E) Treatment of new-onset seizure disorder with phenytoin

Answer: **(E)** Treatment of new-onset seizure disorder with phenytoin

Rationale:

Tacrolimus is a macrolide immunosuppressant that acts as a calcineurin inhibitor, thereby affecting both humoral and T-cell–mediated immunity. Tacrolimus is a substrate for both P-glycoprotein and the cytochrome P450 enzyme CYP3A. P-glycoprotein is involved in both active transport in the small intestine and hepatic efflux transport, while CYP3A is important for liver metabolism. These enzymes share similar co-expression patterns, and both can be affected by other drugs including immunosuppressants, antifungals, and antiseizure medications.

Tacrolimus absorption and metabolism is affected by many factors, including steroids, hormones, herbal supplements such as St. Johns Wort, gastric emptying, intestinal absorption, and high fat content meals. Tacrolimus is primarily metabolized in the liver by the P450 CYP3A system; therefore CYP3A inhibitors generally increase tacrolimus concentrations, and CYP3A inducers typically decrease tacrolimus concentrations. In this scenario, use of phenytoin will lead to a decrease in the tacrolimus level as phenytoin induces the P450 CYP3A system. All the other choices inhibit the P450 CYP3A system and therefore would be expected to increase tacrolimus levels.

Reference:

Christians U, Strom T, Zhang Y, et al. Active drug transport of immunosuppressants: new insights for pharmacokinetics and pharmacodynamics. *Ther Drug Monit.* 2006; 28(1):39–44.

۰۲۱-۶۶۱۹۸۵۱۴ www.myuptodate.com دریافت آخرین نسخه آپتودیت آفلاین

2B77

Key word: Characteristics of General Anesthesia

Author: Andrew P. Dhanasopon, MD
Editor: Asad Latif, MBBS, MPH

A 35-year-old woman presents after a high-speed motor vehicle accident in which there was significant intrusion into her side of the car, the windshield was broken, and she required a prolonged extrication time due to her legs being crushed beneath the dashboard. Upon arrival, the patient makes incomprehensible sounds, does not open her eyes, and withdraws to painful stimuli. A dilated right pupil is noted. Which of the following is the most appropriate muscle relaxant to use when intubating this patient?

(A) Glycopyrrolate
(B) Neostigmine
(C) Pancuronium
(D) Succinylcholine
(E) Vecuronium

Answer: (E) Vecuronium

Rationale:

This patient was involved in a motor vehicle accident with a likely intracranial bleed and crush injury to her legs. She requires intubation due to concern for airway protection, consistent with a Glasgow Coma Scale (GCS) score ≤8 (her GCS is 7) as per ATLS guidelines. Due to concern for significant crush muscular injury and resultant hyperkalemia, depolarizing neuromuscular blockers like succinylcholine should not be administered for intubation.

Nondepolarizing neuromuscular blockers in general cause histamine release and potential cerebral vasodilation leading to transient cardiovascular effects including increased intracranial pressure, which should be minimized in this patient with an intracranial bleed and the risk of herniation. Vecuronium usually produces no cardiovascular effects in clinical doses and even in large doses has been shown to have no significant effect on cerebral physiology in studies involving patients with brain tumors. Thus, vecuronium is an appropriate agent to use in this case.

Pancuronium can cause an abrupt increase in heart rate and blood pressure, which may elevate intracranial pressure in patients with impaired intracranial compliance and defective autoregulation. Neostigmine is a neuromuscular blockade reversal agent and would not be appropriate. Glycopyrrolate is a muscarinic anticholinergic agent and is usually administered with neostigmine to counteract its resulting excessive cholinergic activity.

References:

Kheterpal S, Rutter TW, Tremper KK. Anesthesiology and pain management. In: Mulholland MW, Lillemoe KD, Doherty GM, Maier RV, Upchurch GR, eds. *Greenfield's Surgery: Scientific Principles and Practice.* 5th ed. Philadelphia, PA: Lippincott Williams and Wilkins; 2011.

Patel PM, Drummond JC. Cerebral physiology and the effects of anesthetic drugs. In: Miller RD, ed. *Miller's Anesthesia.* 7th ed. Philadelphia, PA: Elsevier; 2010:305–339.

Common Neuromuscular Blocking Drugs and Reversal Agents

Muscle Relaxant	Intubating Dose (mg/kg)	Infusion Dose (mg/kg/min)	Strengths	Weaknesses
Depolarizing				
Succinylcholine	1.0	100[a]	Fastest onset (30 to 60 s) Short duration[b] (5 min)	Associated with malignant hyperthermia, dysrhythmias, bradycardia, and hyperkalemia, especially in patients with burns or neurologic injury
Nondepolarizing				
Long acting (>1 h)				
Pancuronium	0.1	0.3	No histamine release	Tachycardia Slow onset Long duration
Intermediate acting (≈1 h)				
Cisatracurium	0.2	0.1	Spontaneous degradation, not affected by renal or liver disease	Moderate cost
Vecuronium	0.1	1	No cardiovascular effects	
Rocuronium	0.8	10	Fast onset, no cardiovascular effects	

[a]This should not be used for longer than 1 h.

[b]Duration is dramatically increased in patients with abnormal plasma pseudocholinesterase.

Reprinted with permission from: Kheterpal S, Rutter TW, Tremper KK. Anesthesiology and pain management. In: Mulholland MW, Lillemoe KD, Doherty GM, Maier RV, Simeone DM, Upchurch GR, Jr, eds. *Greenfield's Surgery: Scientific Principles & Practice*, 5th ed. Philadelphia, PA: Lippincott Williams & Wilkins, 2011:239.

۰۲۱-۶۶۱۹۸۵۱۴ www.myuptodate.com دریافت آخرین نسخه آپتودیت آفلاین

2B78

Key word: Sensitivity and Specificity of Screening Tests

Author: Betsy King, MD
Editor: Dorry L. Segev, MD, PhD

A new screening test is implemented for prostate cancer. It has a sensitivity of 92% and a specificity of 90%. If a patient has prostate cancer, what is the probability that the patient will test negative?

(A) 8%
(B) 10%
(C) 90%
(D) 92%
(E) 97%

Answer: (A) 8%

Rationale:
Sensitivity and specificity measure the ability of a test to correctly determine the presence of disease. Sensitivity is defined as the probability of a positive test among individuals with the disease. In this example the sensitivity is 92%, meaning 92 out of 100 individuals with prostate cancer will test positive. This also means 8 out of 100 individuals with prostate cancer will test negative (false negative).

Specificity is defined as the probability of a negative test among individuals without the disease. In this example, the specificity is 90%, meaning 90 out of 100 individuals without prostate cancer will test negative. This also means 10 out of 100 individuals without disease will test positive (false positive).

High sensitivity is important in order to rule a disease out and is therefore desirable for screening tests. If a test has high sensitivity, the number of false negatives will be low, meaning if an individual tests negative, the disease is very unlikely to be present. High specificity is important to rule a disease in and is therefore desirable for confirmatory diagnostic tests. If a test has high specificity, the number of false positives will be low, meaning if an individual tests positive, the disease is very likely to be present.

Reference:
Palson EC, Sonnad SS. Statistics and epidemiology. In: Porett PM, Frederick JR, Roses RE, Kaiser LR, eds. *The Surgical Review: An Integrated Basic and Clinical Science Study Guide.* 3rd ed. Philadelphia, PA: Lippincott Williams & Wilkins; 2010.

2B79

Key word: Synergism of Ampicillin and Sulbactam

Author: Andrew P. Dhanasopon, MD
Editor: Pamela A. Lipsett, MD, MHPE, FACS, FCCM

When combined with ampicillin, sulbactam exerts a synergistic antimicrobial effect. How does sulbactam help extend the spectrum of activity of ampicillin?

(A) Inhibits beta-lactamase
(B) Inhibits cell wall synthesis
(C) Inhibits dihydrofolate reductase
(D) Inhibits DNA gyrase
(E) Inhibits protein synthesis

Answer: (A) Inhibits beta-lactamase

Rationale:
Ampicillin is a beta-lactam antibiotic that inhibits cell wall synthesis and is effective against *Streptococcus pyogenes, Streptococcus pneumoniae,* and *Haemophilus influenzae.* However, many strains have developed beta-lactamases, which hydrolyze the amide bond of the beta-lactam ring, inactivating this class of antibiotics. The addition of the beta-lactamase inhibitor sulbactam extends the spectrum of ampicillin to include the above organisms as well as some Enterobacteriaceae members such as *Escherichia coli.* Tetracycline and aminoglycosides are inhibitors of protein synthesis. Fluoroquinolones inhibit DNA gyrase. Trimethoprim inhibits dihydrofolate reductase.

Reference:
Petri WA. Penicillins, cephalosporins, and other β-lactam antibiotics. In: Brunton LL, Chabner BA, Knollmann BC, eds. *Goodman & Gilman's The Pharmacological Basis of Therapeutics.* 12th ed. New York, NY: McGraw-Hill; 2011.

۰۲۱-۶۶۱۹۸۵۱۴ www.myuptodate.com دریافت آخرین نسخه آپتودیت آفلاین

2B80

Key word: Acid–Base Disturbances with Sulfamylon Treatment

Author: Joshua H. Wolf, MD
Editor: Pamela A. Lipsett, MD, MHPE, FACS, FCCM

A 42-year-old male with a 20% total body surface area full-thickness burn across his back and chest is treated with sulfamylon. Use of this drug places him at risk for which of the following acid–base disturbances?

(A) Metabolic acidosis
(B) Metabolic acidosis and respiratory alkalosis
(C) Metabolic alkalosis
(D) Respiratory acidosis
(E) Respiratory alkalosis

Answer: (A) Metabolic acidosis

Rationale:
Sulfamylon (mafenide acetate) is a sulfonamide antibiotic that is commonly used as a topical agent to prevent bacterial colonization in burn injuries. Like other sulfonamides, its mechanism of action is competitive inhibition of bacterial dihydropteroate synthase, which normally incorporates para-aminobenzoic acid (PABA) into dihydropteroic acid in order to produce folic acid. In addition to its antimicrobial properties, mafenide acetate is also a carbonic anhydrase inhibitor, which can lead to metabolic acidosis. In the above case, the patient may also have decreased lung expansion as a result of eschar formation across the chest, thereby compounding a drug-related acidosis with a respiratory component. Other side effects of mafenide acetate include fluid losses (from evaporation at the burn site) and intense pain at the site of application.

References:
Brunton L, Parker K, Blumenthal, Buxton I. Chemotherapy of microbial diseases. In: Brunton L, Parker K, Blumenthal, Buxton, eds. *Goodman and Gilman's Manual of Pharmacology and Therapeutics.* New York, NY: McGraw and Hill; 2008:716–719.

Marini JJ, Wheeler AP. Burns and inhalation injury. In: Marini JJ, Wheeler AP, eds. *Critical Care Medicine.* 3rd ed. Philadelphia, PA: Lippincott Williams and Wilkins; 2006:630–631.

2B81

Key word: Common Effects of Benzodiazepines

Author: Raja Mohan, MD
Editor: Asad Latif, MBBS, MPH

A 67-year-old woman was given 5 mg of midazolam in divided doses for sedation while undergoing an esophagoscopy. Which of the following is true regarding this medication?

(A) Hypertension is a common side effect
(B) It has strong analgesic properties
(C) It provides long-acting sedation
(D) Its effects are mediated through GABA receptors
(E) Its effects are quickly reversed with naloxone

Answer: (D) Its effects are mediated through GABA receptors

Rationale:
Midazolam is a benzodiazepine frequently used to help with sedation and reduce anxiety before operative procedures. It has a rapid onset and offset and fewer active metabolites compared to other benzodiazepines. Midazolam is primarily indicated for sedation, anxiolysis, amnesia, and for the treatment of seizures, specifically status epilepticus.

Benzodiazepines have sedative, hypnotic, anxiolytic, amnestic, and anticonvulsant properties. This class of medications acts through GABA receptors, which causes depression of the central nervous system (CNS). Benzodiazepines generally produce only mild decreases in blood pressure and heart rate and only mild respiratory depression, unless in the presence of other CNS depressants or in the setting of decreased hepatic function. The most common side effects of benzodiazepines are weakness, disorientation, headache, blurred vision, vertigo, and nausea. Flumazenil is a benzodiazepine antagonist used to reverse the effects of benzodiazepines.

Reference:
Bahn EL, Holt KR. Procedural sedation and analgesia: a review and new concepts. *Emerg Med Clin North Am.* 2005;23(2):503.

۰۲۱-۶۶۱۹۸۵۱۴ www.myuptodate.com دریافت آخرین نسخه آپتودیت آفلاین

2B82

Key word: Electrolyte Abnormalities Associated with Pyloric Stenosis

Author: Vicente Valero III, MD
Editor: F. Dylan Stewart, MD, FACS

A 3-week-old boy with no past medical history presents to your clinic with nonbilious, projectile vomiting for the last 4 days. Upon physical examination a mass is palpated in the upper abdomen. You inform the family that their child has pyloric stenosis and that a pyloromyotomy is the surgical treatment of choice. What electrolyte and acid–base derangement is most likely present?

(A) Hyperchloremic, hypokalemic metabolic acidosis

(B) Hyperchloremic, hypokalemic metabolic alkalosis

(C) Hypochloremic, hyperkalemic metabolic acidosis

(D) Hypochloremic, hypokalemic metabolic acidosis

(E) Hypochloremic, hypokalemic metabolic alkalosis

Answer: (E) Hypochloremic, hypokalemic metabolic alkalosis

Rationale:

Pyloric stenosis is the most common cause of metabolic alkalosis in infants and is the most common reason for an abdominal operation in the first 6 months of life. The hypertrophied pyloric muscle results in a mechanical gastric outlet obstruction that usually presents in the first 12 weeks of life. The classic presentation depicts a male infant with nonbilious, projectile vomiting and a palpable olive-like mass in the midline of the upper abdomen. The incidence of pyloric stenosis is about 1 in 250 and is three times more common in boys. An abdominal sonogram is the imaging modality of choice to confirm the diagnosis. The continuous loss of gastric secretions results in the depletion of hydrogen chloride and potassium chloride with concomitant bicarbonate retention and thus a hypochloremic, hypokalemic metabolic alkalosis. This alkalosis is further exacerbated by the total body potassium loss, which shifts potassium into the extracellular space, and hydrogen ions are transported into the intracellular space to retain electroneutrality. At the same time the kidneys reabsorb potassium in the distal tubules in exchange for hydrogen ions, resulting in worsening of the alkalosis.

Reference:

McEvoy CF. Developmental disorders of gastrointestinal function. In: McMillian JA, Feigin RD, DeAngelis CD, Jones MD, eds. *Oski's Pediatrics.* 4th ed. Philadelphia, PA: Lippincott Williams & Wilkins; 2006:371–372.

۰۲۱-۶۶۱۹۸۵۱۴ www.myuptodate.com دریافت آخرین نسخه آپتودیت آفلاین

دریافت آخرین نسخه آپتودیت آفلاین www.myuptodate.com ۰۲۱-۶۶۱۹۸۵۱۴

2
GASTROINTESTINAL

CONTENTS:

Number:	Key Word:	Page:
2G01	Anatomy of the Cystic Duct	385
2G02	Complication of Achalasia Operation	385
2G03	Diagnosis of Duodenal Stump Leak	386
2G04	Diagnostic Test of Pleural Effusion after Laparoscopic Nissen Fundoplication	387
2G05	Diagnosis of VIPoma	388
2G06	Etiology of Increased Enzymes with Common Bile Duct Injury	389
2G07	Evaluation of Foregut Symptoms	389
2G08	Initial Treatment of Diverticular Disease	390
2G09	Initial Treatment of Appendiceal Abscess	390
2G10	Initial Treatment of Echinococcal Liver Cyst	391
2G11	Initial Treatment for Respiratory Complications with Pancreatic Ascites	391
2G12	Procedure with the Greatest Risk of Postoperative Small Bowel Obstruction	392
2G13	Risk of Rebleeding of Duodenal Ulcer	393
2G14	Treatment of Adenocarcinoma of the Appendix	394
2G15	Treatment of Amebic Liver Abscess	394
2G16	Treatment of Autoimmune Pancreatitis	395
2G17	Treatment of Tracheo-neoesophageal Fistula after Esophagectomy	396
2G18	Treatment of Duodenal Carcinoid	397
2G19	Complications of Colonoscopic Polyp Removal	397
2G20	Treatment of Gallstone Pancreatitis	398
2G21	Treatment of Gastric Adenocarcinoma of the Lesser Curvature	398
2G22	Treatment of Common Bile Duct Injury during Laparoscopic Cholecystectomy	399
2G23	Treatment of Obstruction of the Ampulla during Laparoscopic Cholecystectomy	399
2G24	Treatment of Persistent Fistula-in-ano	400
2G25	Treatment of Pharyngeal Diverticulum	401
2G26	Treatment of Pneumatosis Intestinalis and Inguinal Hernia	402
2G27	Treatment of Pyogenic Liver Abscess	403
2G28	Treatment of Villous Adenoma	403
2G29	Surgical Treatment of *Clostridium difficile* Colitis	404
2G30	Surgical Treatment of Rectal Prolapse	404

۰۲۱-۶۶۱۹۸۵۱۴ www.myuptodate.com دریافت آخرین نسخه آپتودیت آفلاین

Number:	Key Word:	Page:
2G31	Timing of Cholecystectomy after Myocardial Infarction	406
2G32	Anatomy of the Normal Upper Esophageal Sphincter	407
2G33	Vitamin K-dependent Clotting Factors	408
2G34	Most Specific Diagnostic Imaging of Meckel Diverticulum	408
2G35	Sequence of Return of Bowel Motility	409
2G36	Characteristics of Hepatic Adenoma	409
2G37	Diagnostic Tests for the Etiology of Lower GI Bleeding	410
2G38	Diagnostic Test for Suspected Boerhaave Syndrome	411
2G39	Treatment of Recurrent Sigmoid Volvulus	412
2G40	Most Common Etiology of Peptic Ulcer Disease	413
2G41	Site of Gastrointestinal Protein Absorption	413
2G42	GI Hemorrhage and Inhibition of Gastric Acid Secretion	414
2G43	Surveillance for Recurrent Colorectal Cancer	414
2G44	Cell Type for Benign Gastric Ulcer	415
2G45	Etiology of Urinary Stones	416
2G46	Origin of Bilirubin	416
2G47	Preoperative Measurement of Portal Venous Pressure	417
2G48	Treatment of Increased Homocysteine Levels	418
2G49	Site of Intrinsic Factor Secretion	418
2G50	Most Common Hepatic Duct Aberration	419

۰۲۱-۶۶۱۹۸۵۱۴ www.myuptodate.com دریافت آخرین نسخه آپتودیت آفلاین

2G01

Key word: Anatomy of the Cystic Duct

Author: Trevor A. Ellison, MD, MBA
Editor: Christopher L. Wolfgang, MD, PhD

The anatomic separation between the common hepatic duct and the common bile duct occurs at which level?

(A) Entry of cystic duct into the common hepatic duct

(B) Entry of the duct into the pancreas

(C) The change in mucosa from columnar to squamous

(D) The intersection of the bile duct and right hepatic artery

(E) The superior edge of the duodenum where the duct starts to travel in the retroduodenal space

Answer: (A) Entry of cystic duct into the common hepatic duct

Rationale:
The common hepatic duct and cystic duct join to form the common bile duct, although approximately 15% to 20% of patients will have a variation in their biliary duct anatomy. One of the more important variations to be aware of during a cholecystectomy is a short cystic duct, which leads to the common bile duct being mistaken for the cystic duct. Another variant to be cautious of during a cholecystectomy is the presence of an anterior or posterior right hepatic duct that independently inserts into the common hepatic duct. In this situation, the anterior or posterior right hepatic duct may be mistaken for the cystic duct and inadvertently clipped. The wide variation in extrahepatic biliary anatomy creates the need to establish the "critical view" during a cholecystectomy. To obtain this view, the window between the cystic duct, the inferior liver edge, and the common hepatic duct is opened so that the cystic duct and cystic artery can be identified as the only structures entering directly into the gallbladder.

References:
Jackson PG, Evans SRT. Biliary system. In: Towsend CM, Beauchamp RD, Evers BM, Mattox KL, eds. *Sabiston Textbook of Surgery.* 19th ed. Philadelphia, PA: Saunders Elsevier; 2012:1476–1495.

Van Arendonk KJ, Duncan MD. Acute cholecystitis. In: Cameron JL, Cameron AM, eds. *Current Surgical Therapy.* 10th ed. Philadelphia, PA: Mosby; 2011:340.

2G02

Key word: Complication of Achalasia Operation

Author: Betsy King, MD
Editor: Robert A. Meguid, MD, MPH

A 55-year-old female presents with complaints of worsening chest pain associated with swallowing and dysphagia for solid food. Upper gastrointestinal series demonstrates narrowing of the distal esophagus with proximal dilation. Manometric studies demonstrate failure of normal relaxation of the lower esophageal sphincter. The patient undergoes an uneventful laparoscopic Heller myotomy. Postoperatively she reports continued chest pain that occurs 30 to 60 minutes after meals and worsens upon lying down. How could this complication have been prevented?

(A) Combining myotomy with a partial fundoplication procedure

(B) Esophagectomy

(C) Injection of the lower esophageal sphincter with botulinum toxin

(D) Longer myotomy incision

(E) Postoperative initiation of calcium channel blockers

Answer: (A) Combining myotomy with a partial fundoplication procedure

Rationale:
Achalasia results from a progressive neuronal degeneration of Auerbach plexus within the muscular wall of the esophagus. The disease is characterized by failure of relaxation of the lower esophageal sphincter. Patients present with symptoms of dysphagia to liquids and solids and can also have regurgitation.

Initial therapy is medical, utilizing calcium channel blockers and nitrates to induce relaxation of the lower esophageal sphincter. Initial invasive management methods include pneumatic or mechanical dilation, which is associated with a risk of perforation and often requires repeat procedures for improved efficacy. Botulinum toxin injection is also used and acts by inhibiting release of excitatory acetylcholine. If medical therapy fails, surgical management is indicated.

Surgical treatment of achalasia is most commonly with a Heller esophagomyotomy, during which an anterior longitudinal incision is made within the longitudinal and circular muscle layers of the esophagus and continued onto the proximal stomach. Following this step, the lower esophageal sphincter is no longer competent, and the patient loses the ability to prevent reflux of gastric acid into the esophagus. Addition of an antireflux procedure in the form of a partial fundoplication is commonly performed and can create a mechanical barrier and decreases symptoms of gastroesophageal reflux.

Esophagectomy is considered a therapy of last resort for achalasia in patients with a severely tortuous sigmoid esophagus or those who have had failure of prior myotomy to relieve dysphagia.

۰۲۱-۶۶۱۹۸۵۱۴ www.myuptodate.com دریافت آخرین نسخه آپتودیت آفلاین

References:
Maish MS. Esophagus. In: Towsend CM, Beauchamp RD, Evers BM, Mattox KL, eds. *Sabiston Textbook of Surgery.* 19th ed. Philadelphia, PA: Saunders Elsevier; 2012:1025–1028.
Richards WO, Williams DB. Current treatment of achalasia. In: Cameron JL, Cameron AM, eds. *Current Surgical Therapy.* 10th ed. Philadelphia, PA: Saunders Elsevier; 2011:41–45.

2G03

Key word: Diagnosis of Duodenal Stump Leak

Author: Jens U. Berli, MD
Editor: Christopher L. Wolfgang, MD, PhD

A 43-year-old female patient is now postoperative day 8 after a distal gastrectomy and Roux-en-Y reconstruction for an antral gastrointestinal stromal tumor (GIST). On morning rounds, her abdomen is tender with guarding in her epigastrium, and there is bilious fluid in her intra-abdominal Jackson-Pratt drain. Her vital signs are 38.1°C, pulse 98 beats per minute, blood pressure 123/69 mm Hg, and oxygen saturation 94%. A computed tomography (CT) scan with oral contrast is performed, and a fluid collection measuring 10 × 8 × 5 cm is seen in the area of the resection bed. Which of the following is the next step in diagnosing a duodenal stump leak?

(A) Diagnostic laparoscopy

(B) Fluoroscopy (upper gastrointestinal series with Jackson-Pratt injection)

(C) Gastroscopy and inspection of anastomosis

(D) No further studies are needed as bilious fluid in the Jackson-Pratt drain is diagnostic

(E) Repeat CT scan with oral and intravenous contrast

Answer: (D) No further studies are needed as bilious fluid in the Jackson-Pratt drain is diagnostic

Rationale:
Duodenal stump insufficiency is a feared complication after any surgery that leaves the duodenum disconnected from the stomach (e.g., Billroth II, Whipple with side-to-end anastomosis of pancreas and duodenum, Roux-en-Y reconstruction after gastrectomy, duodenal switch). In this case, a CT scan with oral contrast has already established that an anastomotic leak has occurred, and bile in the Jackson-Pratt drain indicates that the source of this leak is the duodenum. Fluoroscopy could be used as a confirmatory test but is not required for diagnosis. Repeat CT scan is not likely to help clarify the source of the leak. Gastroscopy and inspection of the anastomosis carries the risk of worsening a potential anastomotic leak or creating one *de novo*. Gastroscopy is usually the preferred diagnostic and treatment tool for suspected hemorrhage of the gastrojejunal anastomosis (e.g., anastomotic ulcer).

Duodenal stump insufficiency is generally managed conservatively with drainage. In cases of high output leaks, percutaneous biliary drainage might be indicated. Diagnostic laparoscopy on postoperative day 8 is likely to be complicated by adhesions and may create additional harm. Unless appropriate drainage cannot be achieved by percutaneous drain placement, surgery should not be the first choice in management. If this were to occur on postoperative day 1, however, one might consider taking the patient back for exploration. In cases of open repair, a duodenostomy tube with or without T-tube drainage of the common bile duct can be performed with repair of the leak.

۰۲۱-۶۶۱۹۸۵۱۴ www.myuptodate.com دریافت آخرین نسخه آپتودیت آفلاین

References:
Mercer DW, Robinson EK. Stomach. In: Townsend CM, Beauchamp RD, Evers MB, Mattox KL, eds. *Sabiston Textbook of Surgery: the biological basis of modern surgical practice.* 18th ed. Philadelphia, PA: Saunders Elsevier; 2008:1245–1275.
Minter RM. Gastric neoplasms. In: Mulholland MW, Lillemoe KD, Doherty GM, Maier RV, Simeone, DM, Upchurch GR. *Greenfield's Surgery Scientific Principles & Practice.* 5th ed. Philadelphia, PA: Lippincott Williams & Wilkins; 2011:722–736.
Richards WO, Schirmer BD. Morbid obesity. In: Townsend CM, Beauchamp RD, Evers MB, Mattox KL, eds. *Sabiston Textbook of Surgery: The Biological Basis of Modern Surgical Practice.* 18th ed. Philadelphia, PA: Saunders Elsevier; 2008:399–429.

2G04

Key word: Diagnostic Test of Pleural Effusion after Laparoscopic Nissen Fundoplication

Author: Betsy King, MD
Editor: Robert A. Meguid, MD, MPH

A 54-year-old male undergoes laparoscopic Nissen fundoplication for persistent gastroesophageal reflux. On postoperative day 2 the patient develops pleuritic chest pain and shortness of breath. EKG and cardiac enzymes are normal. Chest x-ray demonstrates a large left-sided pleural effusion. Which of the following is the best diagnostic study to obtain next?

(A) Computed tomography (CT) scan
(B) Echocardiogram
(C) Esophagogram
(D) Lymphoscintigraphy
(E) Thoracentesis and pleural fluid sampling

Answer: (C) Esophagogram

Rationale:
A rare yet serious postoperative complication of laparoscopic Nissen fundoplication is esophageal or gastric perforation secondary to injuries caused by surgical instrumentation of the viscera. A perforation presents most commonly within the first 48 hours after surgery, and risk is increased if there is any postoperative retching or emesis.

Perforation often presents with peritoneal signs if leakage of gastrointestinal contents is contained within the abdomen. Dyspnea and pleural effusion are common symptoms and are signs of a leak into the chest. Barium or water-soluble contrast swallow study will definitively diagnose the leak and may also identify the site of perforation. Definitive management is by exploratory laparotomy and direct surgical repair of the defect.

CT scan is a reasonable diagnostic study to evaluate the nature of the chest x-ray findings but is not sensitive in identifying visceral perforations because it is not a dynamic study. It may identify stigmata associated with perforation such as pneumoperitoneum (often present for several days after a laparoscopic procedure) or a large effusion. Sampling the pleural effusion would give more information regarding the composition of the effusion; however, it would neither provide a definitive diagnosis nor identify the site of perforation. Lymphoscintigraphy would be useful in the diagnosis of chylous effusion secondary to thoracic duct injury in the setting of a large chyle leak. While the thoracic duct does run alongside the esophagus, injury to it is rare during laparoscopic Nissen fundoplication.

References:
Heitmiller RF, You CJ. Gastroesophageal reflux disease. In: Cameron JL, Cameron AL, eds. *Current Surgical Therapy.* 10th ed. Philadelphia, PA: Saunders Elsevier; 2011.
Maish M. Esophagus. In: Towsend CM, Beuchamp RD, Evers BM, Mattox KL, eds. *Sabiston Textbook of Surgery.* 18th ed. Philadelphia, PA: Saunders Elsevier; 2008.

۰۲۱-۶۶۱۹۸۵۱۴ www.myuptodate.com دریافت آخرین نسخه آپتودیت آفلاین

2G05

Key word: Diagnosis of VIPoma

Author: Ibrahim Sultan, MD
Editor: Richard D. Schulick, MD, MBA, FACS

A 52-year-old man presents to the emergency room with abdominal pain, weight loss, and dehydration. He has had large-volume diarrhea (>3 L/day) over the past few weeks. Abdominal computed tomography (CT) reveals a small mass in the tail of the pancreas, and a plasma vasoactive intestinal polypeptide (VIP) is sent. Which of the following would be most consistent with a diagnosis of Verner–Morrison syndrome?

(A) Abdominal pain

(B) Osmotic diarrhea

(C) Stool osmotic gap of 300 mOsm/kg

(D) VIP plasma level of 600 pg/mL

(E) Weight loss

Answer: (D) VIP plasma level of 600 pg/mL

Rationale:

A VIP level greater than 75 pg/mL in a patient with large-volume diarrhea and a pancreatic mass is highly suggestive of VIPoma or Verner–Morrison syndrome. The diagnostic triad for a VIPoma is secretory diarrhea, high plasma VIP levels, and a pancreatic tumor. Patients with low-volume diarrhea (<700 mL/day) are unlikely to have a VIPoma. Weight loss and abdominal pain are both nonspecific findings that are not necessarily present in a patient with a VIPoma.

VIPoma is a quite rare tumor, and patients commonly present with severe electrolyte disturbances (the syndrome is also known as watery diarrhea, hypokalemia, and achlorhydria syndrome [WDHA] syndrome). Stool osmotic gap in patients with VIPoma is usually <50 mOsm/kg, reflecting a secretory diarrhea. A stool osmotic gap of >125 mOsm/kg suggests an osmotic diarrhea (e.g., from ingestion of laxatives or excessive sugar or salt).

Diagnosis VIPoma

Parameter	Description
Symptoms	Watery diarrhea
	Weakness
	Lethargy
	Nausea
Diagnostic tests	Hypokalemia
	Achlorhydria
	Metabolic acidosis
	Serum VIP levels elevated
Anatomic localization	Most in body and tail of pancreas, with liver metastases

VIP, vasoactive intestinal peptide.

Reprinted with permission from: Kennedy EP, Brody JR, Yeo CJ. Neoplasms of the endocrine pancreas. In: Mulholland MW, Lillemoe KD, Doherty GM, Maier RV, Upchurch GR, eds. *Greenfield's Surgery: Scientific Principles & Practice*. 5th ed. Philadelphia, PA: Lippincott Williams & Wilkins, 2011:866.

References:

Kennedy EP, Brody JR, Yeo CJ. Neoplasms of the endocrine pancreas. In: Mulholland MW, Lillemoe KD, Doherty GM, Maier RV, Upchurch GR, eds. *Greenfield's Surgery: Scientific Principles & Practice.* 5th ed. Philadelphia, PA: Lippincott Williams and Wilkins; 2011.

Ladner D, Norton JA. Neuroendocrine tumors of the pancreas. In: Yeo CJ, ed. *Shackelford's Surgery of the Alimentary Tract.* 6th ed. Philadelphia, PA: Elsevier; 2007:1375–1386.

Morrow EH, Norton JA. Management of pancreatic islet cell tumors excluding gastrinoma. In: Cameron JL, Cameron AM, eds. *Current Surgical Therapy.* 10th ed. Philadelphia, PA: Elsevier; 2010:456–460.

۰۲۱-۶۶۱۹۸۵۱۴ www.myuptodate.com دریافت آخرین نسخه آپتودیت آفلاین

2G06

Key word: Etiology of Increased Enzymes with Common Bile Duct Injury

Author: Andrew P. Dhanasopon, MD
Editor: Christopher L. Wolfgang, MD, PhD

A 45-year-old woman undergoes a laparoscopic cholecystectomy for symptomatic cholelithiasis. On postoperative day 10, she presents to the emergency room with 4 days of low-grade fevers, nausea, and right upper quadrant abdominal pain. Laboratory studies reveal mildly elevated bilirubin, liver enzymes, and white blood cell count. Computed tomography demonstrates a subhepatic fluid collection. Hepatobiliary iminodiacetic acid (HIDA) scan shows some drainage enterically but also peritoneal leakage, and a percutaneous drain is placed into the collection. What is the next step in management?

(A) Endoscopic retrograde cholangiopancreatography (ERCP) with stenting
(B) Immediate open common bile duct exploration
(C) Immediate open hepaticojejunostomy
(D) Observation
(E) Percutaneous transhepatic cholangiogram

Answer: (A) Endoscopic retrograde cholangiopancreatography (ERCP) with stenting

Rationale:
A bile duct injury cannot be treated with observation alone. Identification of the site of injury is the key at this step in management. A percutaneous transhepatic cholangiogram will allow for identification of the site of leakage, but ERCP is both a diagnostic and therapeutic modality and is therefore the better choice. Immediate open surgery is not indicated until the site and extent of biliary injury has been determined. If bile duct injury is recognized after the first week, hepaticojejunostomy is generally not recommended.

References:
Connor S, Garden OJ. Bile duct injury in the era of laparoscopic cholecystectomy. *Br J Surg.* 2006;93(2):158–168.
Rauws EAJ, Gouma DJ. Endoscopic and surgical management of bile duct injury after laparoscopic cholecystectomy. *Best Pract Res Clin Gastroenterol.* 2004;18(5):829–846.

2G07

Key word: Evaluation of Foregut Symptoms

Author: Betsy King, MD
Editor: Richard D. Schulick, MD, MBA, FACS

A 56-year-old male with a significant history of tobacco use complains of progressively worsening odynophagia and dysphagia and a 4.5-kg (10-lb) weight loss over the past several months. He initially had trouble swallowing solid food and has more recently developed difficulty swallowing liquids and a sensation that food gets caught in his chest. What is the most valuable diagnostic study to obtain?

(A) Barium swallow
(B) Computed tomography (CT) of the chest and abdomen
(C) Endoscopic ultrasound
(D) Esophageal manometry
(E) Esophagogastroduodenoscopy

Answer: (E) Esophagogastroduodenoscopy

Rationale:
The differential diagnosis for dysphagia includes benign etiologies such as achalasia as well as malignant etiologies such as esophageal cancer. The history of tobacco use and weight loss in this patient should signal a red flag that cancer must be ruled out. Although all of the choices are acceptable means of evaluating esophageal pathology, esophagogastroduodenoscopy is the most valuable in establishing a diagnosis. Endoscopy allows for direct visualization of the esophagus and for collection of biopsies.

Fluoroscopic imaging, such as barium swallow, is useful for evaluating esophageal function and giving a gross representation of the mucosal surface. It is useful for identifying certain motility disorders and gastroesophageal reflux but provides limited information regarding the diagnosis of cancer. Likewise, CT is useful in examining extraluminal esophageal disease that can often be present with esophageal carcinoma. However, cross-sectional imaging does not provide evaluation of the mucosal surface where most cancers originate.

Endoscopic ultrasound is very sensitive for determining the depth of invasion of a known cancer, but it is not typically used as the initial diagnostic assessment. Endoscopic ultrasound can also be utilized for fine-needle aspiration and lymph node sampling. Esophageal manometry is generally reserved for evaluation of esophageal pathology once a structural etiology has been ruled out. It is the preferred diagnostic study for disorders of esophageal motility.

References:
Callender GG, Ferguson MK. Management of esophageal tumors. In: Cameron JL, Cameron AL, eds. *Current Surgical Therapy.* 10th ed. Philadelphia, PA: Saunders Elsevier; 2011:47–53.
Chandrasekhara V, Jagannath S. Esophageal function tests. In: Cameron JL, Cameron AL, eds. *Current Surgical Therapy.* 10th ed. Philadelphia, PA: Saunders Elsevier; 2011:1–14.

۰۲۱-۶۶۱۹۸۵۱۴ www.myuptodate.com دریافت آخرین نسخه آپتودیت آفلاین

2G08

Key word: Initial Treatment of Diverticular Disease

Author: Ibrahim Sultan, MD
Editor: Susan L. Gearhart, MD

A 50-year-old man presents to the emergency room with left lower quadrant abdominal pain. He is febrile to 38.7°C with a pulse of 100 beats per minute and blood pressure of 120/70 mm Hg. On examination of his abdomen, he is found to have focal left lower quadrant tenderness without peritonitis. His white blood cell count is 15,000/μL, and a computed tomography (CT) scan demonstrates diverticular disease in the sigmoid colon with a 6-cm rim-enhancing pericolic collection. Antibiotics are started. What is the next step in management of this patient?

(A) Careful observation on antibiotic therapy

(B) Exploratory laparotomy and washout without operative resection of the colon

(C) Percutaneous drainage of the collection

(D) Sigmoid colectomy with end colostomy and Hartmann pouch

(E) Sigmoid colectomy with primary anastomosis

Answer: (C) Percutaneous drainage of the collection

Rationale:

This patient presents with complicated diverticulitis, that is, diverticular disease with abscess, perforation, stricture, or fistulous disease. Uncomplicated disease involves abdominal pain, fever, leukocytosis, and obstipation in the absence of the complications noted for complicated disease.

Complicated diverticular disease is further classified according to the Hinchey classification. Stage 1 involves a pericolic or intramesenteric abscess. Stage 2 presents with a pelvic abscess. Stage 3 presents with generalized purulent peritonitis without gross intestinal perforation. Stage 4 presents with fecal peritonitis.

The initial management of stage 1 disease in the absence of peritonitis or hemodynamic instability consists of percutaneous drainage and intravenous antibiotics. If operative management is pursued, the choice of operation would be sigmoid resection with primary anastomosis. The anastomotic leak rate is approximately 4% in this setting, and a diverting ostomy is not recommended.

Reference:

Gearhart SG. Diverticular disease of the colon. In: Cameron JL, Cameron AM, eds. *Current Surgical Therapy.* 10th ed. Philadelphia, PA: Elsevier; 2010:132–136.

2G09

Key word: Initial Treatment of Appendiceal Abscess

Author: Vicente Valero III, MD
Editor: Mark D. Duncan, MD, FACS

A 26-year-old man with no significant past medical history arrives to the emergency department complaining of right lower quadrant pain. His pain initially began in the periumbilical region, and he ignored the pain for the last 48 hours. His temperature is 39°C and his white blood cell count is 16,000/μL. Computed tomography (CT) scan of the abdomen and pelvis shows a 6- × 8-cm rim-enhancing fluid collection in the right pelvis. What is the best next step in the management of this patient's disease?

(A) Admission to the surgical ward, intravenous antibiotics, and laparoscopic appendectomy during this hospitalization

(B) Admission to the surgical ward, intravenous antibiotics, and repeat CT of the abdomen and pelvis in 5 days

(C) Admission to the surgical ward, intravenous antibiotics, percutaneous drainage of the fluid collection, and interval appendectomy

(D) Discharge patient on oral antibiotics

(E) Discharge patient on oral antibiotics and then perform interval appendectomy

Answer: (C) Admission to the surgical ward, intravenous antibiotics, percutaneous drainage of the fluid collection, and interval appendectomy

Rationale:

Perforated appendicitis is a common complication due to delayed presentation or erroneous diagnosis. Usually the inflammatory process has been present for 5 to 7 days before rupture. The overall incidence of appendiceal perforation is about 25%. Rupture is more common in the extremes of age, occurring more frequently in children younger than 5 years of age and adults older than 65 years of age. Patients typically present with localized peritonitis, as the omentum and bowels wall off the abscess preventing generalized peritonitis in most patients.

Patients with appendiceal abscess should be admitted to the surgical ward and administered intravenous antibiotics. An interventional radiology consult should be obtained for percutaneous drainage of the collection. Intravenous antibiotics should be continued for several days and then the patient can be transitioned to an oral regimen and discharged from the hospital. Definitive management with removal of the appendix should be undertaken with an elective laparoscopic appendectomy performed around 6 weeks from initial presentation.

Reference:

Jaffe BM, Berger DH. The appendix. In: Brunicardi FC, Brandt ML, Andersen DK, Billiar TR, Dunn DL, Hunter JG, Matthews JB, Pollock RE, eds. *Schwartz's Principles of Surgery.* 9th ed. New York, NY: McGraw-Hill; 2010:1119–1137.

۰۲۱-۶۶۱۹۸۵۱۴ www.myuptodate.com دریافت آخرین نسخه آپتودیت آفلاین

2G10

Key word: Initial Treatment of Echinococcal Liver Cyst

Author: Bonnie E. Lonze, MD, PhD
Editor: Michael A Choti, MD, MBA

A 22-year-old male college student presents with anorexia and vague abdominal pain 6 months after returning from a semester abroad in Argentina. A computed tomography (CT) scan of his abdomen reveals a 10-cm, thick-walled cystic lesion and several smaller neighboring cysts. He is afebrile, has a normal white blood cell count, and normal total bilirubin. This patient is most appropriately managed with:

(A) Immediate surgical resection followed by albendazole
(B) Immediate surgical resection followed by metronidazole
(C) Medical monotherapy with metronidazole
(D) Preoperative albendazole followed by surgical therapy
(E) Preoperative metronidazole followed by surgical resection

Answer: (D) Preoperative albendazole followed by surgical therapy

Rationale:
Hydatid cysts of the liver develop as a consequence of infection with the tapeworm Echinococcus, a parasite endemic to regions of South America, Central Asia, and the Mediterranean. Dogs are carriers of the parasite, and sheep and goats are intermediate hosts. Ingestion of contaminated food products or contact with infected animals can lead to human infection. After ingestion of eggs, parasitic embryos circulate and lead to formation of hydatid cysts, most commonly in the liver.

Ultrasound and CT scanning are the most useful imaging studies for establishing a diagnosis of hydatid cysts of the liver. Hydatid cysts classically are large lesions with thick and often calcified walls. Daughter cysts, which appear as neighboring smaller cystic lesions, may also be evident. Infection with the species *Echinococcus multilocularis* can produce a picture of multiple small cysts.

Surgery is the primary treatment for hydatid cysts, although the antihelminthic agent albendazole should be administered preoperatively as an adjunct. Albendazole has been found to accumulate in cysts at higher concentrations than mebendazole and is therefore the first-line medical therapy. Medical therapy alone is used only for patients who are particularly poor operative candidates. The goal of surgical therapy is to remove the viable cyst components without spillage of cyst contents. The extent of operation required ranges from cystectomy to partial hepatectomy to even liver transplantation in rare circumstances. Endoscopic retrograde cholangiopancreatography (ERCP) should be performed preoperatively to evaluate for cyst communication with the biliary tree to assist in determination of the extent of necessary liver resection.

Reference:
Hong JC. Echinococcal disease of the liver. In: Cameron JL, Cameron AM, eds. *Current Surgical Therapy.* 10th ed. Philadelphia, PA: Mosby; 2011:276–281.

2G11

Key word: Initial Treatment for Respiratory Complications with Pancreatic Ascites

Author: Jens U. Berli, MD
Editor: Christopher L. Wolfgang, MD, PhD

A 51-year-old male with a history of chronic pancreatitis and pseudocysts presents to the emergency room with subjective dyspnea and ascites. His ascitic fluid has an amylase value of 2,476 Units/L. The patient is admitted and managed nonoperatively. Despite these measures, he develops increasing respiratory symptoms. You relieve his immediate symptoms with a bedside thoracentesis. Which next step in management is most appropriate?

(A) Drain placement by interventional radiology
(B) Endoscopic retrograde cholangiopancreatography (ERCP) with pancreatic stent placement
(C) Minilaparotomy and evacuation of the ascites
(D) Transjugular portosystemic shunt
(E) Whipple procedure

Answer: (B) Endoscopic retrograde cholangiopancreatography (ERCP) with pancreatic stent placement

Rationale:
Pancreatic ascites is most commonly due to pancreatic duct disruption (e.g., traumatic injury, ruptured pseudocyst, iatrogenic injury). The patient above has a history of chronic pancreatitis with formation of pseudocysts. Most likely a pseudocyst has ruptured, exposing an ongoing leakage from a pancreatic duct. Conservative measures (nothing by mouth, nasogastric decompression, and octreotide administration) lead to resolution in 40% to 60% of patients. Should this management fail (as in this patient), more invasive methods are then used that aim to decrease the rate of the leakage. An ERCP with stent placement and papillotomy is the least invasive method and also gives diagnostic opportunity to localize the exact area of extravasation. A Whipple or a distal pancreatectomy is the most invasive choice if other methods fail.

Other causes of ascites such as malignancy or liver disease have to be excluded prior to any interventions. Transjugular portosystemic shunt would not help this patient since the etiology of his ascites is not portal hypertension. Endoscopic gastrocystostomy is not a therapy of choice for a cyst that has already ruptured.

Reference:
Steer ML. Exocrine pancreas. In: Townsend CM, Beauchamp RD, Evers MB, Mattox KL, eds. *Sabiston Textbook of Surgery: The Biological Basis of Modern Surgical Practice.* 18th ed. Philadelphia, PA: Saunders Elsevier; 2008:1605–1606.

۰۲۱-۶۶۱۹۸۵۱۴ www.myuptodate.com دریافت آخرین نسخه آپتودیت آفلاین

2G12

Key word: Procedure with the Greatest Risk of Postoperative Small Bowel Obstruction

Author: Betsy King, MD
Editor: Susan L. Gearhart, MD

A 65-year-old man presents to the emergency room with bilious vomiting and abdominal pain. He is of status post a sigmoidectomy 6 weeks ago for diverticular disease. He is afebrile, pulse is 110 beats per minute, and blood pressure is 120/70 mm Hg. Which of the following is the most likely cause for his symptoms?

(A) Anastomotic leak
(B) Perforated diverticulum
(C) Recurrent diverticular disease
(D) Small bowel obstruction
(E) Urinary tract infection

Answer: (D) Small bowel obstruction

Rationale:
The most likely cause for this patient's presentation is small bowel obstruction. The leading cause of small bowel obstruction in the United States is surgical adhesions. This patient underwent abdominal surgery 6 weeks prior to presentation and is at risk of developing postoperative adhesions. In the United States, nearly 90% of all small bowel obstructions occur in patients with history of prior surgery secondary to the development of surgical adhesions. Postoperative small bowel obstruction is more likely to occur greater than 30 days following the surgery, when there has been sufficient time for scar formation. Furthermore, adhesions are more likely to form in the setting of active inflammation such as inflammatory bowel disease, diverticulitis, or operations involving penetrating abdominal trauma with contamination.

The patient above has no symptoms of active inflammation making recurrent diverticular disease, urinary tract infection, or bowel perforation less likely. An anastomotic leak would be expected much earlier in the patient's postoperative course, and by 6 weeks the anastomosis should be well healed.

References:
Arnaoutakis GJ, Eckhauser FE. Small bowel obstruction. In: Cameron JL, Cameron AL, eds. *Current Surgical Therapy.* 10th ed. Philadelphia, PA: Saunders Elsevier; 2011:93–96.
Stewart RM, Page CP, Brender J, et al. The incidence and risk of early postoperative small bowel obstruction. A cohort study. *Am J Surg.* 1987;154:643–647.

Symptoms and Signs of Bowel Obstruction

Symptom/ Sign	Proximal Small Bowel (Open Loop)	Distal Small Bowel (Open Loop)	Small Bowel (Closed Loop)	Colon/Rectum
Pain	Intermittent, intense, colicky, often relieved by vomiting	Intermittent to constant	Progressive, intermittent to constant, rapidly worsens	Continuous
Vomiting	Large volumes, bilious and frequent	Low volume and frequency, progressively feculent with time	May be prominent (reflex)	Intermittent, not prominent; when present, feculent
Tenderness	Epigastric or periumbilical; quite mild, unless strangulation is present	Diffuse, progressive	Diffuse, progressive	Diffuse
Distention	Absent	Moderate to marked	Often absent	Marked
Obstipation	May not be present	Present	May not be present	Present

Adapted from: Schuffler MD, Sinanan MN. Intestinal obstruction and pseudo-obstruction. In: Sleisenger MH, Fordtran JS, eds. *Gastrointestinal Disease.* 5th ed. Philadelphia, PA: WB Saunders; 1993:898–916.

۰۲۱-۶۶۱۹۸۵۱۴ www.myuptodate.com دریافت آخرین نسخه آپتودیت آفلاین

2G13

Key word: Risk of Rebleeding of Duodenal Ulcer

Author: Kyle J. Van Arendonk, MD, PhD
Editor: Pamela A. Lipsett, MD, MHPE, FACS, FCCM

A 65-year-old man presents with hematemesis. He is resuscitated and started on a pantoprazole infusion. Upper endoscopy identifies a posterior duodenal ulcer with a nonbleeding visible vessel that is coagulated and clipped. Which of the following is true regarding the potential for rebleeding in this duodenal ulcer?

(A) An episode of rebleeding after endoscopic treatment mandates surgical exploration

(B) Continuation of the intravenous proton pump inhibitor after endoscopic therapy is unnecessary

(C) The posterior location of the ulcer is associated with a lower risk of rebleeding

(D) The presence of a nonbleeding visible vessel is associated with a higher risk of rebleeding than an adherent clot

(E) Younger patients have a higher risk of rebleeding

Answer: (D) The presence of a nonbleeding visible vessel is associated with a higher risk of rebleeding than an adherent clot

Rationale:

Hemodynamically stable patients with upper gastrointestinal bleeding should undergo upper endoscopy after appropriate resuscitation. The endoscopic findings can then be used to predict the likelihood of recurrent hemorrhage and guide management decisions. Specifically, these so-called "stigmata of recent hemorrhage" include the following potential appearances of the ulcer base, in descending risk of rebleeding: Active spurting, nonbleeding visible vessel, active oozing, adherent clot, flat pigmented spot, and clean base.

In addition to these stigmata seen on endoscopy, increased patient age, anemia at presentation, hypovolemic shock, the need for blood transfusion, posterior location of the ulcer, and significant comorbidities, in particular hepatic or renal failure or metastatic cancer, are also associated with an increased risk of recurrent bleeding.

Successful endoscopic hemostasis in patients with high-risk stigmata should be followed with continuation of intravenous proton pump inhibitor in order to decrease the risk of further bleeding. In patients who do develop signs of rebleeding, repeat endoscopy with additional endoscopic therapy can still be performed, as most patients with recurrent bleeding will be able to avoid surgery via successful repeat endoscopic therapy. If rebleeding occurs again after a second endoscopic treatment, the patient should proceed to surgery or arterial embolization by interventional radiology.

References:

Laine L, Jensen DM. Management of patients with ulcer bleeding. *Am J Gastroenterol.* 2012;107(3):345–360.

Mulholland MW. Gastroduodenal ulceration. In: Mulholland MW, Lillemoe KD, Doherty GM, Maier RV, Simeone DM, Upchurch GR, eds. *Greenfield's Surgery: Scientific Principles & Practice.* 5th ed. Philadelphia, PA: Lippincott Williams & Wilkins; 2011:706–707.

۰۲۱-۶۶۱۹۸۵۱۴ www.myuptodate.com دریافت آخرین نسخه آپتودیت آفلاین

2G14

Key word: Treatment of Adenocarcinoma of the Appendix

Author: Ibrahim Sultan, MD
Editor: Jonathan E. Efron, MD

A 37-year-old man undergoes a laparoscopic appendectomy for presumed appendicitis and is discharged home without any complications. Pathologic examination reveals a 1-cm adenocarcinoma of the tip of the appendix that is margin negative. What is the next step in management?

(A) Chemotherapy

(B) Close surveillance with computed tomography scan in 6 months

(C) No further therapy

(D) Positron emission tomography scan to evaluate for residual disease

(E) Right hemicolectomy

Answer: **(E)** Right hemicolectomy

Rationale:

Appendiceal tumors are found in approximately 1% of pathologic specimens. Most of these tumors are carcinoid tumors, which typically arise from the tip of the appendix. Carcinoid tumors that are less than 1 cm in size and do not involve the base are managed only with an appendectomy. Carcinoid tumors that are greater than 2 cm in size are managed with a right hemicolectomy. However, the optimal management of all adenocarcinomas of the appendix involves a right hemicolectomy to remove the lymph node drainage of the appendix along the ileocolic mesentery.

References:

Compton C, Hawk E, Grochow L, et al. Colon cancer. In: Abeloff MD, Armitage JO, Niederhuber JE, Kastan MB, McKenna WG. *Abeloff's Clinical Oncology.* 4th ed. Philadelphia, PA: Churchill Livingstone Elsevier; 2008: 1477–1524.

Sugarbaker PH. Cancer of the appendix and pseudomyxoma peritonei syndrome. In: Fazio VW, Church JM, Delaney CP, eds. *Current Therapy in Colon and Rectal Surgery.* 2nd ed. Philadelphia, PA: Elsevier; 2005:369–378.

2G15

Key word: Treatment of Amebic Liver Abscess

Author: Bonnie E. Lonze, MD, PhD
Editor: Michael A. Choti, MD, MBA

A 29-year-old surgery resident presents with anorexia, weight loss, and right upper quadrant pain. A month ago, she returned from a 1-year medical mission to Mexico. Shortly after she had arrived in Mexico, she had a brief bout of self-limited diarrhea but otherwise remained in good health for the duration of the trip. A computed tomography (CT) scan of the abdomen reveals a right-sided intrahepatic rim-enhancing fluid-filled lesion. The first-line treatment option for this patient is:

(A) Intravenous metronidazole

(B) Intravenous praziquantel

(C) Intravenous praziquantel followed by percutaneous drainage

(D) Oral paromomycin

(E) Percutaneous abscess drainage

Answer: **(A)** Intravenous metronidazole

Rationale:

Amebic hepatic abscesses are caused by infection with the protozoan *Entamoeba histolytica.* Infection is transmitted by the fecal–oral route, and typically initial infection leads to a diarrheal disease referred to as amebic dysentery. While the liver is the most common site of extra-intestinal infection, only a small percentage of patients develop hepatic abscesses, which typically present in a delayed fashion following amebic dysentery.

Amebic abscesses are almost always successfully treated with metronidazole, which is able to achieve high concentrations in the liver. Drainage by any route, percutaneous or open, is almost never required. Paromomycin is a luminal antimicrobial that is administered to eradicate the amoeba from the intestinal tract. It is often administered in conjunction with metronidazole to prevent recurrence of hepatic abscesses but is not by itself an appropriate therapy for treatment of the extraintestinal amebic diseases. Praziquantel is an antihelminthic agent used for the treatment of schistosomiasis and is ineffective in the treatment of amebic abscesses.

References:

Edil B, Pitt H. Hepatic abscess. In: Cameron JL, Cameron AM, eds. *Current Surgical Therapy.* 10th ed. Philadelphia, PA: Mosby; 2011:301–305.

Subramanian A, Gurakar A, Klein A, et al. Hepatic infection and acute hepatic failure. In: Mulholland MW, Lillemoe KD, Doherty GM, Maier RV, Upchurch GR, eds. *Greenfield's Surgery: Scientific Principles & Practice.* 5th ed. Philadelphia, PA: Lippincott Williams and Wilkins; 2011.

۰۲۱-۶۶۱۹۸۵۱۴ www.myuptodate.com دریافت آخرین نسخه آپتودیت آفلاین

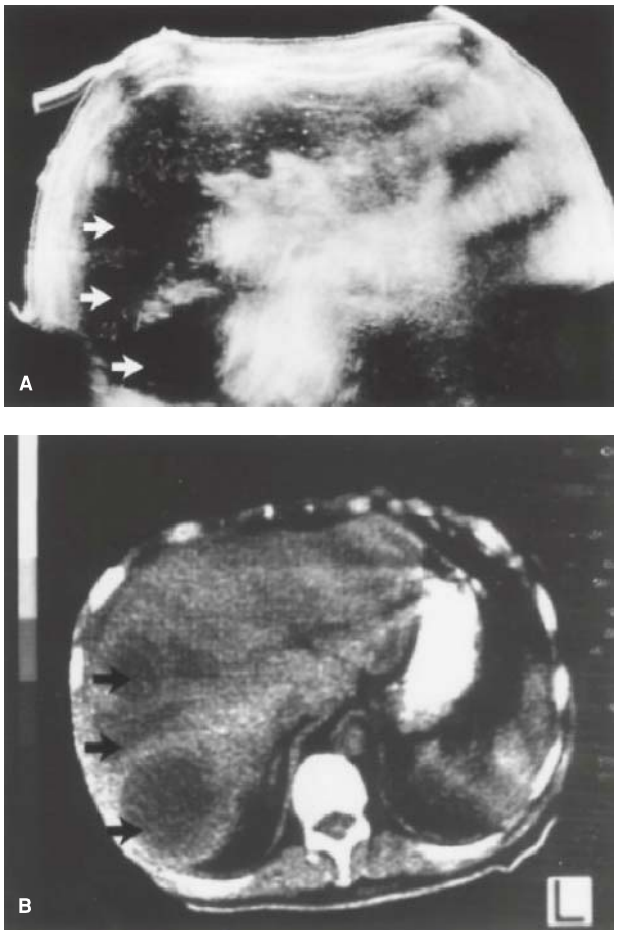

Sonogram **(A)** and computed tomogram **(B)** in a patient with multiple amebic abscesses (*arrows*). Reprinted with permission from: Subramanian A, Gurakar A, Klein A, et al. Hepatic infection and acute hepatic failure. In: Mulholland MW, Lillemoe KD, Doherty GM, Maier RV, Upchurch GR, eds. *Greenfield's Surgery: Scientific Principles & Practice*. 5th ed. Philadelphia, PA: Lippincott Williams & Wilkins; 2011:890.

2G16

Key word: Treatment of Autoimmune Pancreatitis

Author: Ibrahim Sultan, MD
Editor: Richard D. Schulick, MD, MBA, FACS

A 57-year-old man with a history of psoriasis presents to the hospital with signs and symptoms of acute pancreatitis. Computed tomography (CT) shows diffuse enlargement of the pancreas. The pancreatic duct appears to be diminutive. He has elevated levels of IgG4 and after ruling out malignancy with endoscopic ultrasound and biopsy, a diagnosis of autoimmune pancreatitis is made. What is the next step in management of this patient?

(A) Frey procedure
(B) Glucocorticoids
(C) Intravenous antibiotics
(D) No further management
(E) Puestow procedure

Answer: **(B)** Glucocorticoids

Rationale:
Autoimmune pancreatitis is a form of chronic pancreatitis characterized by a mixed inflammatory infiltrate with prominent lymphocytic infiltration. The inflammatory process centers on the pancreatic duct, causing pancreatic duct stenosis. The resulting fibrosis of the pancreas causes organ dysfunction. Some patients will have other associated autoimmune conditions such as Sjögren syndrome, psoriasis, primary sclerosing cholangitis, or inflammatory bowel disease.

Autoimmune pancreatitis can be difficult to differentiate from pancreatic adenocarcinoma. Patients can present with a pancreatic mass and may need additional workup such as an endoscopic ultrasound with biopsy or rather a laparoscopic or open biopsy in order to rule out malignancy. A serum IgG4 level greater than 140 mg/dL is highly suggestive of autoimmune pancreatitis but cannot definitely rule out pancreatic cancer.

Autoimmune pancreatitis is initially managed medically with steroids (prednisone 30 to 40 mg/day) for approximately 4 to 6 weeks. Patients typically respond in 2 to 4 weeks. If there is no response to steroids, an alternative diagnosis should always be considered.

References:
Krasinskas AM, Raina A, Khalid A, et al. Autoimmune pancreatitis. *Gastroenterology Clin North Am.* 2007;36(2):239–257.
Vollmer CM, Kent TS, Callery MP. Unusual pancreatic tumors. In: Cameron JL, Cameron AM, eds. *Current Surgical Therapy.* 10th ed. Philadelphia, PA: Elsevier; 2010:444–449.

۰۲۱-۶۶۱۹۸۵۱۴ www.myuptodate.com دریافت آخرین نسخه آپتودیت آفلاین

2G17

Key word: Treatment of Tracheo-neoesophageal Fistula after Esophagectomy

Author: Jens U. Berli, MD
Editor: Robert A. Meguid, MD, MPH

A 64-year-old woman who is postoperative day 23 status post Ivor Lewis esophagectomy for esophagogastric junction cancer is readmitted to the surgical intensive care unit with fever, hypotension, and a productive cough. She is resuscitated with fluid and started on broad-spectrum antibiotics. Chest x-ray demonstrates right lower lobe consolidation but no pleural fluid collection. Esophagogram reveals a small tracheo-neoesophageal fistula at the level of the esophagogastric anastomosis. The patient is made NPO and total parenteral nutrition (TPN) is initiated. Which of the following is the most appropriate next step in management of this complication?

(A) Primary surgical repair
(B) Reintubation
(C) Tracheal ring resection
(D) Tracheal stent
(E) Video-assisted thoracoscopic decortication and tube thoracostomy placement

Answer: **(D)** Tracheal stent

Rationale:

Tracheo-neoesophageal fistulas are a dreaded complication after esophagectomy occurring in approximately 3% to 4% of cases. Most often this is an early complication, but it can also occur several years after the operation. The injury can result from endotracheal tube pressure, anastomotic leak, chronic reflux, or ischemic lesions due to mediastinal devascularization or radiation. The principles of treatment are drainage of any fluid collections that may represent leakage of enteric contents, control of ongoing leakage, and definitive repair.

The approach to this complication depends on the clinical scenario. Any intra-abdominal or intrathoracic collections must be drained. If the fistula is discovered in the early postoperative period (the first few days after surgery) and the patient is not critically ill, return to the operating room for a primary repair may be attempted. Operative repair consists of resection of the fistula with primary repair of the trachea and neoesophagus conduit along with a muscular flap to separate the two suture lines. If the patient has a larger defect or is critically ill, a tracheal stent is the initial therapy of choice. This strategy allows for source control of ongoing leak and gives the patient time to recover from infection. The patient should remain on TPN or postpyloric alimentation. Should a small fistula fail to heal after stent placement, the patient is brought back to the operating room once clinically stable for definite repair of the fistula and muscle flap coverage.

Tube thoracostomy placement is necessary for drainage of enteric contents that are present at the time of diagnosis, and thoracoscopic or open decortication may be necessary if a rind has already developed on the lung or infection does not resolve with thoracostomy drainage. Reintubation with placement of the tracheal cuff distal to the fistula might be necessary in the case of pulmonary failure.

References:

Bartels HE, Stein HJ, Siewert JR. Tracheobronchial lesions following oesophagectomy: Prevalence, predisposing factors and outcome. *Br J Surg.* 1998;85(3):403–406.

Nardella JE, Van Raemdonck D, Piessevaux H, et al. Gastrotracheal fistula—unusual and life threatening complication after esophagectomy for cancer: A case report. *J Cardiothorac Surg.* 2009;4:69.

۰۲۱-۶۶۱۹۸۵۱۴ www.myuptodate.com دریافت آخرین نسخه آپتودیت آفلاین

2G18

Key word: Treatment of Duodenal Carcinoid

Author: Vicente Valero III, MD
Editor: Richard D. Schulick, MD, MBA, FACS

A 56-year-old woman with a history of gastroesophageal reflux disease presents with dyspepsia, belching, and epigastric pain. She undergoes esophagogastroduodenoscopy (EGD), which identifies a 1.8-cm smooth mucosal nodule on the lateral wall of the second portion of the duodenum. Biopsies of the lesion reveal a duodenal carcinoid tumor. What treatment should be recommended?

(A) Expectant management
(B) Pancreaticoduodenectomy
(C) Repeat EGD in 6 months
(D) Repeat EGD with endoscopic excision
(E) Transduodenal excision with primary repair of duodenum and lymphadenectomy

Answer: (E) Transduodenal excision with primary repair of duodenum and lymphadenectomy

Rationale:
Duodenal carcinoid is a rare and typically indolent disease, appearing like carcinomas but acting in a more benign fashion. These neoplasms account for only 2.5% of gastrointestinal carcinoids. Symptoms are nonspecific and include epigastric pain, bloating, and bleeding. The most common location of these masses is the first portion of the duodenum.

Management of these tumors is typically determined by the size of the lesion. Tumors less than 1 cm are amenable to endoscopic excision during EGD. Endoscopic ultrasound should be used to ensure that complete excision is attainable. Tumors greater than 1 cm should be excised in their entirety via a duodenotomy followed by transverse closure of the incision. Lymphadenectomy is recommended for complete staging and locoregional control. Controversy still exists regarding periampullary lesions due to their aggressive biology; many surgeons advocate a pancreaticoduodenectomy for these tumors.

References:
Grau AM, Broome JT, Tarpley JL. Small bowel carcinoid/neuroendocrine tumors. In: Cameron JL, Cameron AM, eds. *Current Surgical Therapy.* 10th ed. Philadelphia, PA: Elsevier-Saunders; 2011:110–115.
Mullen JT, Wang H, Yao JC, et al. Carcinoid tumors of the duodenum. *Surgery.* 2005;138(6):971–977.

2G19

Key word: Complications of Colonoscopic Polyp Removal

Author: Vicente Valero III, MD
Editor: Jonathan E. Efron, MD

A 50-year-old man undergoes a routine screening colonoscopy during which several polyps are removed. While in the recovery room he reports significant abdominal pain and is noted to have abdominal distention on physical examination. A portable chest radiograph shows free intraperitoneal air. Where is the perforation most likely to have occurred?

(A) Ascending colon
(B) Descending colon
(C) Rectum
(D) Sigmoid colon
(E) Transverse colon

Answer: (D) Sigmoid colon

Rationale:
Colonoscopy is a high-volume intervention that millions of Americans undergo each year, and it is imperative that surgeons be trained to recognize and manage the potential complications that can occur. Colonic perforation occurs in approximately 0.03% to 0.8% of diagnostic colonoscopies and 0.15% to 3% of therapeutic colonoscopies. Perforations occur via three mechanisms: The use of electrocautery as part of therapeutic interventions, mechanical forces that are exerted on the bowel wall with the endoscope, and overinsufflation of the bowel. The most common site of perforation is the sigmoid colon, seen in approximately 60% to 75% of perforations. If perforation is suspected in a hemodynamically stable patient, a portable upright chest radiograph is the most rapid and inexpensive modality to diagnose iatrogenic colonic injury, with intraperitoneal free air seen under either hemidiaphragm to confirm the presence of a perforated viscus. Once the diagnosis is confirmed, exploratory laparotomy should be performed promptly. If the patient is unstable or has frank peritonitis, immediate surgical exploration is warranted without any confirmatory diagnostic studies.

Reference:
Luning TH, Keemers-Gels ME, Barendregt WB, et al. Colonoscopic perforations: a review of 30366 patients. *Surg Endosc.* 2007;21(6):994–997.

۰۲۱-۶۶۱۹۸۵۱۴ www.myuptodate.com دریافت آخرین نسخه آپتودیت آفلاین

2G20

Key word: Treatment of Gallstone Pancreatitis

Author: Ibrahim Sultan, MD
Editor: Pamela A. Lipsett, MD, MHPE, FACS, FCCM

A 64-year-old man is admitted to the hospital with a 1-day history of abdominal pain, nausea, and vomiting. He has an elevated serum amylase and lipase (500 and 600 Units/L respectively). His liver function tests including bilirubin are within normal limits with the exception of an elevated alkaline phosphatase (188 Units/L). He has an unremarkable past medical history, does not use any medications, and has no history of alcohol use. A right upper quadrant ultrasound demonstrates cholelithiasis without evidence of cholecystitis. Apart from admission to the hospital and resuscitation, what is the most appropriate step in the overall management of this patient?

(A) Cholecystectomy as an outpatient
(B) Cholecystectomy prior to discharge from the hospital
(C) Urgent cholecystectomy on admission
(D) Urgent endoscopic retrograde cholangiopancreatography (ERCP) on admission
(E) Urgent magnetic resonance cholangiopancreatography (MRCP) on admission

Answer: (B) Cholecystectomy prior to discharge from the hospital

Rationale:
This patient has mild acute pancreatitis with nausea and vomiting. He will be admitted to the hospital for hydration and bowel rest. The etiology appears to be related to gallstones. At this time he does not appear to have an impacted gallstone, which one can deduce from his normal bilirubin level and the absence of common bile duct dilation on ultrasound. However, his elevated alkaline phosphatase level may be indicative of the patient passing a stone through the bile duct. MRCP or ERCP may not elucidate any additional information in this situation. Patients with gallstone pancreatitis who are not at high surgical risk should undergo a cholecystectomy prior to discharge. The risk of recurrent pancreatitis in a 90-day period can be as high as 50% without cholecystectomy.

References:
Donahue TR, Reber HA. Gallstone pancreatitis. In: Cameron JL, Cameron AM, eds. *Current Surgical Therapy.* 10th ed. Philadelphia, PA: Elsevier; 2010:388–392.
Steer ML. Exocrine pancreas. In: Towsend CM, Beauchamp RD, Evers BM, Mattox KL, eds. *Sabiston Textbook of Surgery.* 18th ed. Philadelphia, PA: Elsevier; 2008:1589–1623.

2G21

Key word: Treatment of Gastric Adenocarcinoma of the Lesser Curvature

Author: Vicente Valero III, MD
Editor: Barish H. Edil, MD

A 67-year-old Japanese immigrant presents to your clinic complaining of early satiety, generalized weakness, weight loss, and mild epigastric pain. Upper endoscopy reveals a 3-cm friable lesion along the lesser curvature of the stomach. The lesion abuts the gastric cardia and is 4 cm from the gastroesophageal junction. Biopsies reveal gastric adenocarcinoma. Staging workup including computed tomography of the chest, abdomen, and pelvis and an endoscopic ultrasound reveals no metastatic disease. What is the best surgical approach for this lesion?

(A) Endoscopic mucosal resection
(B) Gastrotomy with excision of mass and primary repair of stomach
(C) Subtotal gastrectomy with Billroth II reconstruction
(D) Subtotal gastrectomy with Roux-en-Y gastrojejunostomy reconstruction
(E) Total gastrectomy with Roux-en-Y esophagojejunostomy

Answer: (E) Total gastrectomy with Roux-en-Y esophagojejunostomy

Rationale:
Gastric adenocarcinoma is diagnosed in about 20,000 individuals in the United States every year. People from Japan, Korea, and South America have a much higher incidence than those from North America and Europe. Risk factors include *Helicobacter pylori* infection, gastric polyps, previous gastric surgery, tobacco use, and exposure to nitrosamines. Operative therapy remains the only definitive management of this disease. Optimal surgical margins are 5 cm due to the propensity for gastric cancer to spread along the submucosa. Tumors involving the lesser curvature are particularly close to the gastroespohageal junction and thus are typically not amenable to subtotal gastrectomy. The lesions usually necessitate a total gastrectomy with a Roux-en-Y esophagojejunostomy in order to achieve 5-cm margins free of disease.

Reference:
McFadden DW, Schneider JG. Gastric adenocarcinoma. In: Cameron JL, Cameron AM, eds. *Current Surgical Therapy.* 10th ed. Philadelphia, PA: Elsevier-Saunders; 2011:110–115.

۰۲۱-۶۶۱۹۸۵۱۴ www.myuptodate.com دریافت آخرین نسخه آپتودیت آفلاین

2G22

Key word: Treatment of Common Bile Duct Injury during Laparoscopic Cholecystectomy

Author: Vicente Valero III, MD
Editor: Barish H. Edil, MD

You are performing a laparoscopic cholecystectomy on a 25-year-old woman with acute cholecystitis. The gall bladder is edematous and inflamed, and the tissue planes are difficult to discern. After clipping and dividing what you believed was the cystic duct, you realize that you have transected the common bile duct (CBD) with loss of length of the CBD. What operative procedure should be performed to repair this injury?

(A) Direct end to end primary repair over a T-tube
(B) Direct end to side primary repair over a T-tube
(C) Kocher maneuver with end-to-end primary repair
(D) Pancreaticoduodenectomy
(E) Roux-en-Y hepaticojejunostomy

Answer: (E) Roux-en-Y hepaticojejunostomy

Rationale:
Intraoperative recognition of a CBD injury during laparoscopy requires several important decisions. The first is to accurately define the anatomy of the biliary tree, and thus cholangiography should be performed. Once the anatomy is clear, the surgeon must decide whether referral to a tertiary center would benefit the patient. This decision depends on one's personal experience and comfort level in the repair of these biliary injuries, as well as the available services at the institution where the operation is being performed. If transfer is elected, placement of drains in the gallbladder fossa is advised prior to closing.

Partial CBD lacerations can be repaired primarily over a T-tube; however, typically most injuries are complete transections. If there is no loss of length of the CBD, a Kocher maneuver with primary end-to-end anastomosis using absorbable suture can be performed. However, this approach may place tension on the repair, inducing ischemia and subsequent biliary stricture. Therefore, in the setting of loss of length after injury to the CBD, a Roux-en-Y hepaticojejunostomy should be performed. This allows for a tension-free anastomosis and the lowest incidence of postoperative biliary stricture.

Reference:
Pappas T, Ceppa EP. Benign biliary strictures. In: Cameron JL, Cameron AM, eds. *Current Surgical Therapy.* 10th ed. Philadelphia, PA: Elsevier-Saunders; 2011:348–353.

2G23

Key word: Treatment of Obstruction of the Ampulla during Laparoscopic Cholecystectomy

Author: Betsy King, MD
Editor: Barish H. Edil, MD

A 48-year-old female is undergoing laparoscopic cholecystectomy for history of gallstone pancreatitis. An intra-operative cholangiogram demonstrates a dilated common bile duct, and no filling of the duodenum. What is the most appropriate management?

(A) Convert to an open procedure and perform common bile duct exploration
(B) Delay cholecystectomy and perform endoscopic retrograde cholangiopancreatography (ERCP)
(C) Finish laparoscopic cholecystectomy with no further intervention
(D) Perform T-tube placement
(E) Place percutaneous transhepatic biliary drain

Answer: (A) Convert to an open procedure and perform common bile duct exploration

Rationale:
Intraoperative cholangiogram is indicated in patients undergoing cholecystectomy with a history of jaundice, pancreatitis, or elevated liver function tests. In addition, it can be used to delineate biliary anatomy to avoid bile duct injuries. Absence of duodenal filling in the presence of ductal dilation is suggestive of choledocholithiasis. The most appropriate management is to perform an open exploration of the common bile duct for stone retrieval. A sphincterotomy can be considered with this procedure to decrease the risk of further biliary obstruction. It is possible to perform the exploration laparoscopically if within the surgeon's expertise. Placement of a T-tube and closure of the bile duct over the tube is appropriate following common bile duct exploration and extraction of stones.

Placement of a percutaneous transhepatic biliary drain would be indicated preoperatively for treatment of obstructive jaundice not relieved by ERCP. In the intraoperative setting with suspected choledocholithiasis, definitive management is more appropriate; transhepatic biliary drainage is merely temporizing.

Another acceptable option for management of suspected choledocolithiasis identified intraoperatively is to finish the laparoscopic cholecystectomy and refer the patient for postoperative ERCP. Delaying cholecystectomy, however, would leave the patient at risk for developing recurrent biliary obstruction due to gallstones.

۰۲۱-۶۶۱۹۸۵۱۴ www.myuptodate.com دریافت آخرین نسخه آپتودیت آفلاین

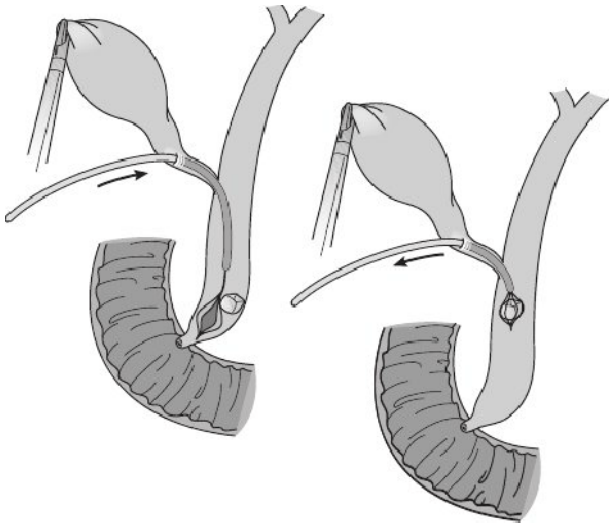

Laparoscopic transcystic bile duct exploration. Reprinted with permission from: Pitt HA, Ahrendt SA, Nakeeb A. Calculous biliary disease. In: Mulholland MW, Lillemoe KD, Doherty GM, Maier RV, Upchurch GR, eds. *Greenfield's Surgery: Scientific Principles & Practice.* 5th ed. Philadelphia, PA: Lippincott Williams & Wilkins; 2011:979.

References:

Curet MJ. Management of common bile duct stones. In: Cameron JL, Cameron AL, eds. *Current Surgical Therapy.* 10th ed. Philadelphia, PA: Saunders Elsevier; 2011:342–345.

Pitt HA, Ahrendt SA, Nakeeb A. Calculous biliary disease. In: Mulholland MW, Lillemoe KD, Doherty GM, Maier RV, Upchurch GR, eds. *Greenfield's Surgery: Scientific Principles & Practice.* 5th ed. Philadelphia, PA: Lippincott Williams and Wilkins; 2011.

2G24

Key word: Treatment of Persistent Fistula-in-ano

Author: Betsy King, MD
Editor: Jonathan E. Efron, MD

A 35-year-old man with a history of recurrent perianal abscesses presents with feculent drainage from around his anus. On examination under anesthesia, injection of hydrogen peroxide into the tract and insertion of a fistula probe reveals an intersphincteric fistula with the internal opening well below the dentate line. Which of the following would provide the most appropriate repair?

(A) Anal fistula plug
(B) Cutting seton
(C) Endoanal advancement flap
(D) Fibrin glue
(E) Fistulotomy

Answer: **(E)** Fistulotomy

Rationale:

The treatment with the lowest recurrence rate for fistula-in-ano is fistulotomy, which results in a recurrence rate of 10% or less. Recurrence is often due to inaccurate identification of the internal opening. Division of greater than one-half to two-thirds of the external sphincter greatly increases the risk of postoperative incontinence. The proximal third of the external sphincter lies above the dentate line, which suggests that the risk for incontinence with fistulotomy in this patient would be relatively low.

For patients with high transsphinteric fistulas, there are several other options for repair. Setons can be utilized and come in two varieties. Draining setons are often used prior to definitive surgical repair to keep the fistula tract open and allow for adequate drainage of perianal infection and scarring of the tract. Cutting setons are used to provide a gradual division of the sphincter muscles and scarring of the remaining fistulotomy tract. The seton is placed tightly around the muscle after dividing the skin and anoderm and is progressively tightened over the course of weeks to successfully obliterate the tract. The gradual muscle separation decreases the risk of incontinence in patients with higher transsphincteric fistulas.

Endoanal advancement flaps and anal fistula plugs are both considered sphincter-sparing techniques, which can be useful for deeper fistulas with high internal openings. In creation of an advancement flap, a proximal portion of the anal mucosa, submucosa, and underlying muscle is mobilized and used to cover the internal opening of the fistula. Although the sphincter is not cut during flap creation, postoperative incontinence can still occur. Endorectal advancement flaps have a recurrence rate ranging from 10% to 40%. Fistula plugs are sutured into the internal opening of the anal fistula and through the tract to the skin. The success of the plug procedure is still debated.

۰۲۱-۶۶۱۹۸۵۱۴ www.myuptodate.com دریافت آخرین نسخه آپتودیت آفلاین

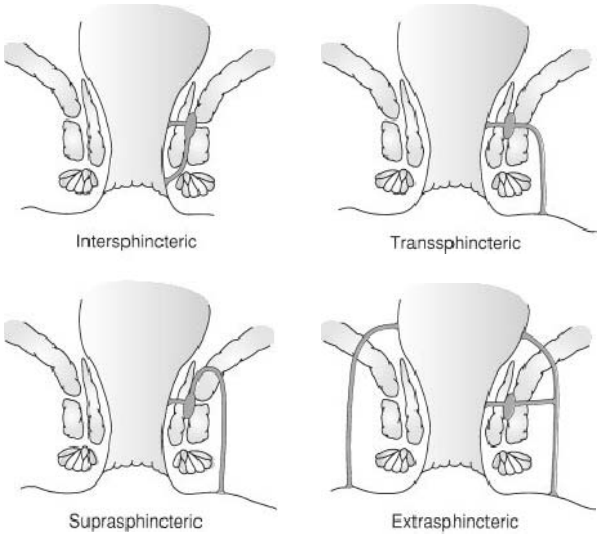

The four main anatomic types of fistula. Reprinted with permission from: Cosman BC, Morris AM, Nivatvongs S, et al. Anorectal disorders. In: Mulholland MW, Lillemoe KD, Doherty GM, Maier RV, Upchurch GR, eds. *Greenfield's Surgery: Scientific Principles & Practice.* 5th ed. Philadelphia, PA: Lippincott Williams & Wilkins, 2011:1148.

References:

Cosman BC, Morris AM, Nivatvongs S, et al. Anorectal disorders. In: Mulholland MW, Lillemoe KD, Doherty GM, Maier RV, Upchurch GR, eds. *Greenfield's Surgery: Scientific Principles & Practice.* 5th ed. Philadelphia, PA: Lippincott Williams and Wilkins; 2011.

Steele SR, Johnson EK, Armstrong DN. Anorectal abscess and fistula. In: Cameron JL, Cameron AL, eds. *Current Surgical Therapy.* 10th ed. Philadelphia, PA: Saunders Elsevier; 2011:233–240.

2G25

Key word: Treatment of Pharyngeal Diverticulum

Author: Joshua H. Wolf, MD
Editor: Robert A. Meguid, MD, MPH

A 43-year-old otherwise healthy man presents with 3 months of progressive dysphagia and regurgitation of solid food several hours after eating. Barium swallow reveals a 3.5-cm pharyngeal diverticulum. Which of the choices below describes the best surgical treatment?

(A) Cricopharyngeal myotomy

(B) Transcervical diverticulectomy and cricopharyngeal myotomy

(C) Transcervical diverticulopexy

(D) Transcervical diverticulopexy and lymph node dissection

(E) Transcervical inversion of the diverticulum

Answer: (B) Transcervical diverticulectomy and cricopharyngeal myotomy

Rationale:

Zenker diverticulum is a pulsion diverticulum that protrudes through Killian triangle, a weakness in the pharyngeal wall that occurs between the cricopharyngeus muscle and the thyropharyngeus part of the inferior constrictor muscle. Excluding or removing the diverticulum is the only definitive treatment. The standard surgical approach involves an incision along the anterior border of the left sternocleidomastoid (SCM) muscle from the level of the hyoid to just above the clavicle, raising subplatysmal flaps, division of the fascia just anterior to the SCM, retraction of the strap muscles, and blunt dissection to expose the diverticulum. There are multiple methods for managing the diverticulum itself (including diverticulopexy or inversion with a purse-string suture and diverticulectomy), but any method must be coupled with a cricopharyngeal myotomy in order to reduce the risk of recurrence and postoperative stricture. Performing these techniques without myotomy is inadequate management. Several studies have argued that cricopharyngeal myotomy alone may be adequate for small diverticulum (<1 to 2 cm).

Endoscopic staple diverticulectomy is emerging as an alternative method for select patients with Zenker diverticula and should be considered when applicable because of lower complication rates. However, this approach may not be possible in patients with difficult endoscopic exposure or limited neck extension (kyphosis, large osteophytes, small oropharynx, etc.) or in cases in which malignancy is suspected and a complete biopsy specimen is required.

Reference:

Scher RL. Zenker's diverticulum. In: Flint PW, Haughey BH, Lund VJ, Niparko JK, Richardson MA, Robbins TK, Thomas JR, eds. *Cummings Otolaryngology—head and Neck Surgery.* 5th ed. Philadelphia, PA: Mosby Elsevier; 2010:987–997.

۰۲۱-۶۶۱۹۸۵۱۴ www.myuptodate.com دریافت آخرین نسخه آپتودیت آفلاین

2G26

Key word: Treatment of Pneumatosis Intestinalis and Inguinal Hernia

Author: Joshua C. Grimm, MD
Editor: Nicole M. Chandler, MD

A 2-month-old boy with no significant past medical history presents with a persistent mass in his right groin. The patient has been febrile, and his mother reports decreased oral intake and no bowel movements over the preceding 48 hours. The child appears very uncomfortable, and the mass is not reducible. Imaging shows nondependent gas in the bowel wall, which is trapped within a hernia. What is true of this condition?

(A) After hernia reduction, conservative management with nasogastric tube decompression is typically sufficient

(B) All cases of pneumatosis intestinalis represent a surgical emergency

(C) This is a normal bowel gas pattern found on imaging

(D) This is a surgical emergency requiring immediate attempts at hernia reduction

(E) This is a surgical emergency that may require laparotomy

Answer: **(E)** This is a surgical emergency that may require laparotomy

Rationale:

Inguinal hernias become an emergency in cases of incarceration and strangulation. For incarcerated hernias lacking signs of strangulation, reduction should be attempted prior to surgical intervention. However, this patient presents with an incarcerated, and also likely strangulated, inguinal hernia evidenced by the presence of pneumatosis intestinalis, indicating likely bowel ischemia. This situation is a surgical emergency and will likely require bowel resection. Fluid resuscitation and nasogastric decompression should be initiated immediately. Strangulated inguinal hernias can be approached using the conventional open inguinal technique, but upon assessment of bowel viability, the need to resect ischemic bowel may require additional exposure via a laparotomy incision. In addition, upon initiation of anesthesia, inguinal hernias have the potential to spontaneously reduce, precluding the surgeon's inspection of the bowel for viability through an inguinal incision. For these reasons, laparotomy is often required for strangulated inguinal hernias.

There are two major etiologies hypothesized to lead to air within the bowel wall (pneumatosis intestinalis). First is the mechanical theory, which describes the process in which weakness in the serosal and mucosal surfaces allow air to dissect via the mesenteric vessels into the bowel wall. Second is the bacterial theory, in which gas-producing organisms translocate into the bowel wall and form cystic air pockets.

Pneumatosis intestinalis can be handled in several different fashions depending upon its etiology. If the patient presents with a surgical emergency, as is the case with this child, then conservative management is not a feasible option. However, if the pneumatosis is not accompanied by other worrisome signs, the child can be managed with intravenous fluids, nasogastric tube decompression, nothing by mouth, and antibiotic therapy if indicated. In the neonatal period, children with necrotizing enterocolitis who are clinically stable are treated conservatively in this fashion. In addition, there are also reports of benign pneumatosis occurring in older immunocompromised pediatric patients.

References:

Heng Y, Schuffler MD, Haggitt RC, et al. Pneumatosis intestinalis: a review. *Am J Gastroenterol.* 1995;90(10):1747.

Knechtle SJ, Davidoff AM, Rice RP. Pneumatosis intestinalis. Surgical management and clinical outcome. *Ann Surg.* 1990;212(2):160.

Sherman V, Macho JR, Brunicardi FC. Inguinal hernias. In: Brunicardi FC, Andersen DK, Billiar TR, Dunn DL, Hunter JG, Matthews JB, Pollock RE, eds. *Schwartz's Principles of Surgery.* 9th ed. New York, NY: McGraw-Hill; 2010.

Snyder CL. Inguinal hernias and hydroceles. In: Holcomb III GW, Murphy JP, Ostlie DJ, eds. *Ashcraft's Pediatric Surgery.* 5th ed. Philadelphia, PA: Elsevier; 2010:669–675.

۰۲۱-۶۶۱۹۸۵۱۴ www.myuptodate.com دریافت آخرین نسخه آپتودیت آفلاین

2G27

Key word: Treatment of Pyogenic Liver Abscess

Author: Bonnie E. Lonze, MD, PhD
Editor: Michael A. Choti, MD, MBA

A 49-year-old man presents with fever, malaise, and right upper quadrant pain. Computed tomography (CT) of the abdomen reveals a rim-enhancing lesion in segment IV of the liver. You determine that the most appropriate course of action is treatment with intravenous piperacillin/tazobactam followed by percutaneous drainage of the liver lesion. The history you are mostly likely to have obtained to direct your clinical management of this patient is which of the following?

(A) History of appendicitis as a child
(B) History of recent travel to Argentina
(C) History of recent travel to Mexico
(D) History of recurrent diverticulitis
(E) Recent development of a maculopapular rash

Answer: (D) History of recurrent diverticulitis

Rationale:
This scenario describes a pyogenic hepatic abscess, an uncommon condition but one that carries a significant mortality rate if not diagnosed and treated promptly. Pyogenic abscesses can derive from various gastrointestinal or biliary sources of infection. These include direct extension of infection in the setting of ascending cholangitis or severe cholecystitis or seeding of the liver by portal blood flow in the setting of acute (not remote) appendicitis or diverticulitis.

For patients who are hemodynamically stable, pyogenic abscesses are typically managed with appropriately targeted intravenous antibiotics and percutaneous drainage. Definitive management must also include addressing the primary source of infection. The choice of antibiotic depends upon the primary source of infection, with gram-negative rods and *Bacteroides* being the most common organisms seen with underlying diverticulitis or appendicitis.

History of travel to Argentina would be most suggestive of Echinococcal cyst, which would be treated with albendazole and surgical resection. History of travel to Mexico would be most consistent with an amebic abscess, which would be treated with metronidazole and would only rarely require drainage. Schistosomiasis, which can present with a maculopapular rash, leads to hepatosplenomegaly and esophageal varices but not hepatic abscesses and is treated with the antihelminthic medication praziquantel.

Reference:
Edil B, Pitt H. Hepatic abscess. In: Cameron JL, Cameron AM, eds. *Current Surgical Therapy.* 10th ed. Philadelphia, PA: Mosby; 2011:301–305.

2G28

Key word: Treatment of Villous Adenoma

Author: Said C. Azoury, MD
Editor: Susan L. Gearhart, MD

A 49-year-old male with a history of chronic diarrhea is scheduled for a routine colonoscopy. At the time of colonoscopy, a 2-cm multilobulated polyp without ulceration is found in the cecum. Biopsies demonstrate a villous adenoma without dysplasia. The next most appropriate step would be which of the following?

(A) Laparoscopic right hemicolectomy
(B) Laparoscopic total abdominal colectomy
(C) Piecemeal polypectomy
(D) Repeat surveillance in 3 months
(E) Snare polypectomy with complete removal of the polyp

Answer: (E) Snare polypectomy with complete removal of the polyp

Rationale:
There are multiple classifications of colorectal polyps. Hyperplastic polyps are the most common type and are non-neoplastic in nature. These polyps rarely develop into colorectal cancers. Hamartomatous polyps are a disorganized mass of tissue elements normally found at that site. Adenomatous polyps are neoplastic polyps, and two-thirds of all intestinal polyps are adenomas. Adenomas are categorized morphologically as sessile, pedunculated, flat, or depressed, pathologically as high- or low-grade dysplasia, and structurally as tubular, villous, or tubulovillous.

Tubular adenomas are the most common intestinal neoplastic polyp, with an incidence of 75% and are generally pedunculated. Villous adenomas are most likely to produce symptoms and are generally sessile and larger than tubular adenomas.

Generally, removal is not necessary for hyperplastic polyps, and the interval before subsequent colonoscopy should be 10 years. Patients with only one or two tubular adenomas measuring <1 cm with low-grade dysplasia should have their next follow-up colonoscopy in 5 to 10 years. Patients with greater than two adenomas or any greater than 1 cm or with villous features or high-grade dysplasia should have complete removal of the polyp, likely with a segmental resection depending on the exact pathology. These individuals need follow-up colonoscopy generally 3 years later (but sooner if the polyp was removed piecemeal).

References:
O'Brien MJ, Winawer SJ, Zauber AG, et al. The National Polyp Study. Patient and polyp characteristics associated with high-grade dysplasia in colorectal adenomas. *Gastroenterology.* 1990;98:371–379.
Rembacken BJ, Fujii T, Cairns A, et al. Flat and depressed colonic neoplasms: A prospective study of 1000 colonoscopies in the UK. *Lancet.* 2000;355:1211–1214.
Winawer SJ, Zauber AG, Fletcher RH, et al. Guidelines for colonoscopy surveillance after polypectomy: A consensus update by the US Multi-Society task force on Colorectal Cancer and the American Cancer Society. *Gastroenterology.* 2006;130:1872–1885.

۰۲۱-۶۶۱۹۸۵۱۴ www.myuptodate.com دریافت آخرین نسخه آپتودیت آفلاین

2G29

Key word: Surgical Treatment of *Clostridium difficile* Colitis

Author: Ibrahim Sultan, MD
Editor: Jonathan E. Efron, MD

A 51-year-old woman is admitted with abdominal pain, diarrhea, and hypotension requiring vasopressors. A diagnosis of *Clostridium difficile* colitis is established, and you are consulted for surgical management when her condition fails to improve. Upon exploratory laparotomy, her colon appears to have healthy serosa with a very dilated transverse colon. The next appropriate step in management is:

(A) Colonic lavage with vancomycin and metronidazole without resection

(B) Total abdominal colectomy and end ileostomy

(C) Total abdominal colectomy with ileorectal anastomosis

(D) Transverse colectomy with colostomy leaving a long Hartmann pouch

(E) Transverse colectomy with primary anastomosis

Answer: (B) Total abdominal colectomy and end ileostomy

Rationale:

Patients with *C. difficile*-associated diarrhea may progress from mild to severe disease, such as this patient who requires hemodynamic support. Organ failure, shock, and vasopressor dependence are indications for surgical intervention. Other indications include toxic megacolon and colonic perforation. The operation of choice is a total colectomy with end ileostomy. The colonic serosa may or may not appear healthy, and this finding should not change the surgeon's choice of operation. In addition, segmental resection should not be undertaken simply because the disease appears to be confined to one part of the colon. To keep the operation as expeditious as possible, the operation is performed open. Attempts at anastomosis should be avoided in these critically ill patients.

Unfortunately, mortality among those requiring colectomy for severe *C. difficile* colitis is quite high, with estimates ranging from 35% to 80%. An alternative to total colectomy would therefore be ideal if a lower mortality rate could be achieved. A recent case series reported the laparoscopic creation of a loop ileostomy after visually assessing the colon to ensure viability, followed by intraoperative colonic lavage and postoperative antegrade vancomycin flushes through the ileostomy coupled with the continuation of intravenous metronidazole. Mortality was found to be significantly lower with this approach, although compared only to historical controls.

References:

Farres H, Lipsett PA. *Clostridium difficile* colitis. In: Cameron JL Cameron AM, eds. *Cameron: Current Surgical Therapy.* 10th ed. Philadelphia, PA: Elsevier; 2010:151–154.

Neal MD, Alverdy JC, Hall DE, et al. Diverting loop ileostomy and colonic lavage: an alternative to total abdominal colectomy for the treatment of severe, complicated Clostridium difficile associated disease. *Ann Surg.* 2011;254(3):423–427.

2G30

Key word: Surgical Treatment of Rectal Prolapse

Author: Joshua H. Wolf, MD
Editor: Susan L. Gearhart, MD

A 45-year-old man with no significant past medical or surgical history presents to clinic with 6 months of constipation and straining and is found to have full-thickness rectal prolapse on examination. The most durable surgical treatment for this patient is:

(A) Abdominal rectopexy

(B) Abdominal rectopexy and sigmoidectomy

(C) Delorme procedure

(D) Mucosal sleeve resection

(E) Perineal rectosigmoidectomy

Answer: (B) Abdominal rectopexy and sigmoidectomy

Rationale:

There are a variety of surgical approaches to rectal prolapse. In general, those techniques with an abdominal approach (resection, with or without rectopexy) have higher risk of perioperative morbidity and lower risk of recurrence compared with perineal procedures, including perineal rectosigmoidectomy (Altemeier procedure) and mucosal sleeve resection (Delorme procedure). The abdominal approach should therefore be reserved for those patients, such as the one described above, with low operative risk.

Abdominal suture rectopexy is the most common prolapse procedure and has a very low recurrence rate. It is coupled with a sigmoid resection if the patient's clinical presentation includes constipation (Frykman–Goldberg procedure). Though this procedure can be performed using laparoscopy, the benefits of doing so are not clear at this time.

References:

Vernava AM, Beck DE. Rectal prolapse. In: Wolff BG, Fleshman JW, Beck DE, Pemberton JH, Wexner SD, eds. *The ASCRS Textbook of Colon and Rectal Surgery.* New York, NY: Springer; 2007:665–677.

Wexner SD, Cera SM. Procedures for rectal prolapse. In: Souba WW, Fink MP, Jurkovich, GJ, Kaiser LR, Pearce WH, Pemberton JH, Soper NJ, eds. *ACS Surgery: Principles and Practice.* New York, NY: WebMD Inc.; 2005.

۰۲۱-۶۶۱۹۸۵۱۴ www.myuptodate.com دریافت آخرین نسخه آپتودیت آفلاین

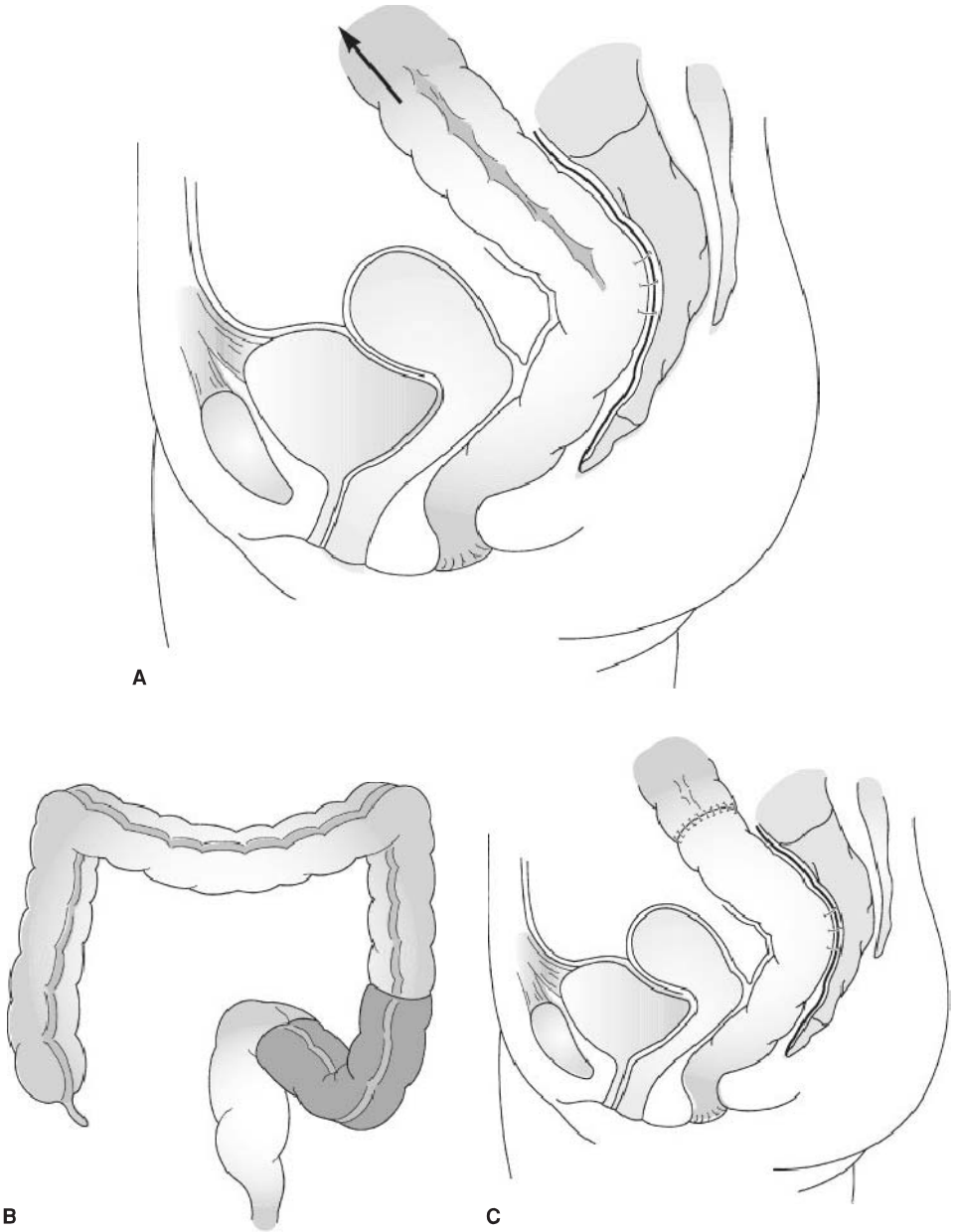

Transabdominal rectopexy. After full mobilization of the rectum, the endorectal fascia and peritoneum on each side is sutured to presacral fascia, below the promontory of the sacrum, as shown in figures **A** and **C.** Concurrent sigmoid resection may be performed if the patient's clinical presentation includes constipation (Frykman–Goldberg procedure), as in figure **B.** Reprinted with permission from: Cosman BC, Morris AM, Nivatvongs S, et al. Anorectal disorders. In: Mulholland MW, Lillemoe KD, Doherty GM, Maier RV, Upchurch GR, eds. *Greenfield's Surgery: Scientific Principles & Practice*. 5th ed. Philadelphia, PA: Lippincott Williams & Wilkins, 2011:1142.

۰۲۱-۶۶۱۹۸۵۱۴ www.myuptodate.com دریافت آخرین نسخه آپتودیت آفلاین

2G31

Key word: Timing of Cholecystectomy after Myocardial Infarction

Author: Joshua H. Wolf, MD
Editor: Mark D. Duncan, MD, FACS

A 46-year-old man with no history of cardiac disease has a myocardial infarction (MI) 5 days prior to his scheduled laparoscopic cholecystectomy for symptomatic cholelithiasis. He undergoes percutaneous angiography with revascularization and bare-metal stent placement and has a favorable outcome with no immediate cardiac complications. Prior to discharge, the medical team would like to know when his cholecystectomy will be performed. Which of the following is the most appropriate plan?

(A) Delay surgery for 1 year

(B) Perform surgery before the patient leaves the hospital

(C) Place a cholecystostomy tube for acute management and plan for a cholecystectomy in 6 weeks

(D) Proceed with the operation as scheduled

(E) Wait at least 6 weeks before performing cholecystectomy

Answer: **(E)** Wait at least 6 weeks before performing cholecystectomy

Rationale:

Acute (<7 days) and recent (8 to 30 days) MI are associated with high perioperative morbidity and mortality, and therefore any elective procedures must be carefully timed in this setting. According to practice guidelines from the American College of Cardiology and the American Heart Association (ACC/AHA) in 2007, nonemergent, noncardiac surgeries should be delayed 4 to 6 weeks following an MI. This interval allows injured myocardium to heal and ensures a complete course of antiplatelet therapy and endothelial growth over a newly placed stent.

Follow-up testing at 3 weeks post-MI can also help risk stratify patients and identify those who still remain unsuitable for elective surgery (i.e., patients with ongoing ischemia, arrhythmia, or new infarction). This risk stratification is critical because, as acknowledged by the ACC/AHC committee, "4 to 6 weeks" is not appropriate for all patients and is not based on prospective clinical trials (none have been performed). Earlier recommendations had suggested a 6-month window, and a recent study by Livhits et al. looked at the rate of MI specifically after cholecystectomy and reported a high risk of perioperative reinfarction (17.8%) and mortality (6.9%) even after a waiting period of 1 month (31 to 60 days). It is important therefore to identify the subset of patients for whom 4 to 6 weeks is inappropriately short and who require further cardiac management. If cardiac stents were placed, the type of stent determines the length of clopidogrel therapy and can therefore also influence the timing of surgery in more elective cases. The duration of clopidogrel treatment is 6 weeks following bare-metal stent placement and 1 year following drug-eluting stent placement.

In the above case, there is no indication for a cholecystostomy tube, although this could be used as a temporizing measure in patients with acute cholecystitis whose cardiac risk is too great to safely proceed with the more definitive operation.

References:

Fleisher LA, Beckman JA, Brown KA, et al. ACC/AHA 2007 Guidelines on Perioperative Cardiovascular Evaluation and Care for Noncardiac Surgery: Executive Summary: A Report of the American College of Cardiology/American Heart Association Task Force on Practice Guidelines (Writing Committee to Revise the 2002 Guidelines on Perioperative Cardiovascular Evaluation for Noncardiac Surgery) Developed in Collaboration With the American Society of Echocardiography, American Society of Nuclear Cardiology, Heart Rhythm Society, Society of Cardiovascular Anesthesiologists, Society for Cardiovascular Angiography and Interventions, Society for Vascular Medicine and Biology, and Society for Vascular Surgery. *J Am Coll Cardiol.* 2007;50(17):1707–1732.

Livhits M, Ko CY, Leonardi MJ, et al. Risk of surgery following recent myocardial infarction. *Ann Surg.* 2011;253(5):857–864.

Nuttall GA, Brown MJ, Stombaugh JW, et al. Time and cardiac risk of surgery after bare-metal stent percutaneous coronary intervention. *Anesthesiology.* 2008;109(4):588–595.

Semark A, Rodseth RN, Biccard BM. When is the risk acceptable to proceed to noncardiac surgery following an acute myocardial infarction? *Minerva Anestesiol.* 2011;77(1):64–73.

۰۲۱-۶۶۱۹۸۵۱۴ www.myuptodate.com دریافت آخرین نسخه آپتودیت آفلاین

2G32

Key word: Anatomy of the Normal Upper Esophageal Sphincter

Author: Trevor A. Ellison, MD, MBA
Editor: Robert A. Meguid, MD, MPH

A 46-year-old man presents with dysphagia, halitosis, and regurgitation. When reviewing his fluoroscopic swallow study, the area of highest likelihood for a suspected upper esophageal diverticulum is:

(A) Between the circular and longitudinal muscle layers of the upper esophagus

(B) Between the cricopharyngeus muscle and the longitudinal muscle of the upper esophagus

(C) Between the thyropharyngeus and the cricopharyngeus muscles

(D) Distal to the cricopharyngeus muscle

(E) Proximal to the inferior pharyngeal constrictor muscle

Answer: (C) Between the thyropharyngeus and the cricopharyngeus muscles

Rationale:

This patient likely has a Zenker diverticulum, a false diverticulum that contains only mucosa and submucosa, located in Killian triangle. The upper esophageal sphincter is a high-pressure zone at the level of the cricopharyngeus muscle found approximately 15 cm from the incisor teeth and constitutes the first esophageal constriction seen on fluoroscopic examinations (with the other three constrictions being the arch of the aorta at about 22.5 cm, the crossing of the main left bronchus at approximately 27.5 cm, and the diaphragm at about 40 cm). The inferior pharyngeal constrictor muscle is made up of the thyropharyngeus muscle (originating in the median raphe and attaching to the lateral borders of the thyroid cartilage) and the cricopharyngeus muscle (originating in the median raphe and attaching to the lateral borders of the cricoid cartilage). The thyropharyngeus muscle has oblique fibers while the cricopharyngeus has horizontal circular fibers, so the transition between these oblique and circular fibers is an area of sparse muscle fibers. This area of weakness where Zenker diverticula form is known as Killian's triangle.

The esophagus is divided into four segments: The pharyngoesophagus (between the laryngopharynx and cervical esophagus including the superior, middle, and inferior constrictors as well as the stylopharyngeus muscle), the cervical esophagus (between the cricopharyngeal muscle and T1), the thoracic esophagus (between T1 and the diaphragmatic hiatus), and the abdominal esophagus (between the diaphragmatic hiatus and the gastric cardia). The layers of the esophagus include mucosa, submucosa, inner circular muscle, and outer longitudinal muscle. Notably, there is no serosa.

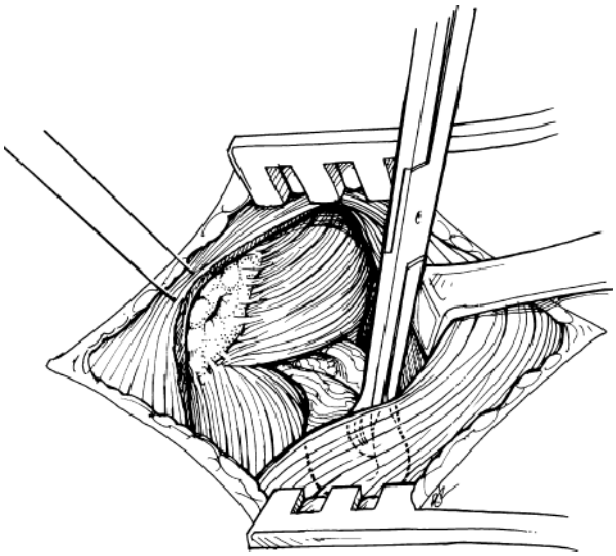

Exposure of Zenker diverticulum. The sac, being grasped by an atraumatic clamp, can be seen exiting the posterior wall of the esophagus at Killian triangle, between the thyropharyngeus and the cricopharyngeus muscles. Reprinted with permission from: Rascoe PA, Smythe WR. Excision of esophageal diverticula. In: Kaiser LR, Kron IL, Spray TL, eds. *Mastery of Cardiothoracic Surgery*. 2nd ed. Philadelphia, PA: Lippincott Williams & Wilkins, 2007:189.

References:

Maish MS. Esophagus. In: Towsend CM, Beauchamp RD, Evers BM, Mattox KL, eds. *Sabiston Textbook of Surgery.* 19th ed. Philadelphia, PA: Saunders Elsevier; 2012:1014–1017.

Moore K, Dalley A. *Clinically Oriented Anatomy.* 4th ed. Baltimore, MD: Lippincott Williams & Wilkins; 1999:221–222.

Rascoe PA, Smythe WR. Excision of esophageal diverticula. In: Kaiser LR, Kron IL, Spray TL, eds. *Mastery of Cardiothoracic Surgery.* 2nd ed. Philadelphia, PA: Lippincott Williams & Wilkins; 2007:187–193.

۰۲۱-۶۶۱۹۸۵۱۴ www.myuptodate.com دریافت آخرین نسخه آپتودیت آفلاین

2G33

Key word: Vitamin K-dependent Clotting Factors

Author: Trevor A. Ellison, MD, MBA
Editor: Christopher L. Wolfgang, MD, PhD

A 68-year-old woman is started on long-term total parenteral nutrition (TPN) via a subclavian central line She is noted to have a catheter-related clot in her superior vena cava. She is immediately started on warfarin and upon re-imaging 2 days later due to increased facial swelling, it is noted that the clot is even larger. Warfarin's inhibition of which pair of factors is most likely responsible for this scenario?

(A) Factors V and VI
(B) Factors V and VIII
(C) Factors XI and XII
(D) Protein C and factor V
(E) Proteins C and S

Answer: **(E)** Proteins C and S

Rationale:
Warfarin is a vitamin K antagonist that inhibits the vitamin K-dependent clotting factors (factors II/prothrombin, VII, IX, and X and proteins C and S). Proteins C and S are endogenous anticoagulants. Since protein C has one of the shortest half-lives of the clotting factors, the effects of its inhibition by warfarin are seen first. This early inhibition of proteins C and S results in a period of increased coagulability before the other clotting factors, which have longer half-lives, are also inhibited. For this reason, patients are typically started on another anticoagulant until their warfarin levels reach the therapeutic window. While in the past this anticoagulation was initiated as an inpatient with an intravenous heparin infusion, the availability of low-molecular-weight heparin now allows for this anticoagulation bridge to be completed as an outpatient if the clinical scenario is appropriate.

Reference:
Freischlag JA, Heller JA. Venous disease. In: Towsend CM, Beauchamp RD, Evers BM, Mattox KL, eds. *Sabiston Textbook of Surgery.* 19th ed. Philadelphia, PA: Saunders Elsevier; 2012:1812–1817.

2G34

Key word: Most Specific Diagnostic Imaging of Meckel Diverticulum

Author: Ibrahim Sultan, MD
Editor: Elizabeth C. Wick, MD

For a patient who is suspected of having a symptomatic Meckel diverticulum, which of the following tests is most sensitive and specific for the diagnosis?

(A) Abdominal ultrasound
(B) Magnetic resonance imaging (MRI)
(C) Standard computed tomography (CT) of the abdomen and pelvis with oral contrast
(D) Technetium scan
(E) Upper gastrointestinal series with small bowel follow-through

Answer: **(D)** Technetium scan

Rationale:
Meckel diverticulum is the most commonly encountered congenital anomaly of the small intestine and is seen in 2% of the population based on autopsy studies. Fifty percent of all patients with Meckel diverticulum and up to 75% of patients with symptomatic Meckel diverticulum have ectopic gastric mucosa. In patients who have gastric mucosa, a technetium scan with ^{99m}Tc-pertechnetate can be highly accurate in identifying a Meckel diverticulum because ^{99m}Tc-pertechnetate is absorbed by gastric mucosa, and the uptake can then be detected scintigraphically. Pentagastrin or cimetidine given prior to the study can enhance detection. The sensitivity and specificity of this study for patients with Meckel diverticulum (with gastric mucosa present) is 85% and 95%, respectively.

References:
Jarman BT. Small bowel imaging. *Surg Clin North Am.* 2011; 91:109–125.
Stone MC, Arcuni JC, Kellum JM. Small intestine diverticula. In: Yeo CJ, ed. *Shackelford's Surgery of the Ailmentary Tract,* 6th ed. Philadelphia, PA: Elsevier; 2007:775–790.

۰۲۱-۶۶۱۹۸۵۱۴ www.myuptodate.com دریافت آخرین نسخه آپتودیت آفلاین

2G35

Key word: Sequence of Return of Bowel Motility

Author: Trevor A. Ellison, MD, MBA
Editor: Christopher L. Wolfgang, MD, PhD

A 54-year-old man undergoes major abdominal surgery, and his diet is advanced on the first postoperative day when bowel sounds are heard. The following morning, the patient has a large amount of emesis and a distended abdomen and reports abdominal pain. A plain abdominal radiograph shows a diffuse pattern of air throughout the entire digestive tract. Why is the patient having emesis with positive bowel sounds?

(A) It is an effect of anesthesia so he should continue to be fed as this episode is unlikely to recur

(B) The colon recovers motility before the small intestine

(C) The colon recovers motility before the stomach

(D) The small intestine recovers motility before the colon or stomach

(E) The stomach recovers motility before the small intestine

Answer: (D) The small intestine recovers motility before the colon or stomach

Rationale:
This patient is suffering from a postoperative ileus, which is nearly ubiquitous after abdominal operations. The etiologies of the ileus are multifactorial and include surgery-induced sympathetic reflexes, anesthesia, analgesia, and inflammatory mediator release. The sequence of bowel recovery is small intestine by 24 hours, stomach by 48 hours, and colon by 3 to 5 days.

References:
Brunicardi FC, Brandt ML, Andersen DK, Billiar TR, Dunn DL, Hunter JG, Matthews JB, Pollock RE, eds. *Schwartz's Principles of Surgery: ABSITE and Board Review.* 9th ed. New York, NY: McGraw-Hill Professional; 2011:293.

Snyder M.J. Is a nasogastric tube necessary following alimentary tract surgery? In: Cameron JL, Cameron AM, eds. *Current Surgical Therapy.* 10th ed. Philadelphia, PA: Mosby; 2011:1074–1076.

2G36

Key word: Characteristics of Hepatic Adenoma

Author: Trevor A. Ellison, MD, MBA
Editor: Christopher L. Wolfgang, MD, PhD

A 26-year-old female presents with increased liver function tests that were drawn after a computed tomography (CT) scan of the abdomen revealed a 2-cm mass in the right lobe of the liver. The mass is further evaluated with a sulfur colloid scan that reveals a cold nodule. The sulfur colloid scan is most helpful when needing to distinguish between which two entities?

(A) Focal nodular hyperplasia and hemangioma

(B) Focal nodular hyperplasia and hepatic metastases from distant sites

(C) Hepatic adenoma and focal nodular hyperplasia

(D) Hepatic adenoma and hemangioma

(E) Hepatic adenoma and hepatic abscess

Answer: (C) Hepatic adenoma and focal nodular hyperplasia

Rationale:
Magnetic resonance imaging has the highest sensitivity and specificity in diagnosing hepatic lesions, although imaging with CT scan and ultrasound is also acceptable. If the hepatic lesion is still not defined by the above studies, a sulfur colloid scan can be carried out to distinguish between a hepatic adenoma and focal nodular hyperplasia (FNH). Kupffer cells take up the sulfur colloid so FNH, which has Kupffer cells, appears as "hot," while an adenoma, which does not contain Kupffer cells, appears "cold."

Reference:
Ferrone CR. Benign liver tumors. In: Cameron JL, Cameron AM, eds. *Current Surgical Therapy.* 10th ed. Philadelphia, PA: Mosby; 2011:284–287.

۰۲۱-۶۶۱۹۸۵۱۴ www.myuptodate.com دریافت آخرین نسخه آپتودیت آفلاین

2G37

Key word: Diagnostic Tests for the Etiology of Lower GI Bleeding

Author: Trevor A. Ellison, MD, MBA
Editor: Jonathan E. Efron, MD

An 80-year-old woman comes to the emergency room with a 2-day history of moderate bleeding per rectum and has a bloody bowel movement upon presentation. She is hemodynamically stable, and a nasogastric tube aspirate returns bile and no blood. Which diagnostic test should be performed next?

(A) Angiography
(B) Capsule endoscopy
(C) Colonoscopy
(D) Meckel scan
(E) Tagged red blood cell scan

Answer: (C) Colonoscopy

Rationale:

The risk of lower gastrointestinal bleeding (LGIB) increases with age and is associated with a variety of age-related factors such as diverticular disease (30% to 40%), ischemia (5% to 10%), anorectal disease (5% to 15%), neoplasia (5% to 10%), infectious colitis (3% to 8%), postpolypectomy state (3% to 7%), inflammatory bowel disease (3% to 4%), angiodysplasia (3%), and radiation colitis/proctitis (1% to 3%). Of all LGIB, 95% originate from the large bowel, and only 5% originate from the small bowel.

In a stable patient with a slow to moderate bleed who has an NGT aspirate positive for bile and no blood, the next diagnostic test is colonoscopy since colonoscopy may be both diagnostic and therapeutic. One step to consider before moving to a colonoscopy is to perform anoscopy or sigmoidoscopy to rule out anorectal bleeding. Colonoscopy will reveal the source of the bleed in about 95% of patients. A thorough examination must be carried out, as about 40% of patients have more than one source of bleeding. Even though blood is a cathartic, polyethylene glycol by mouth or through the NGT to gently prepare the colon within the first 24 hours of admission is required. Performing a rapid bowel preparation within 4 hours and then an endoscopy in the first 12 hours of admission greatly increases the chances of identifying the bleeding source.

Tagged red blood cell scans use the patient's own red blood cells, which are tagged with technetium-99 m and then reinjected. This technique is 90% sensitive, although localization is achieved in only about 40% to 60% due to lack of spatial resolution. The tagged red blood cell scan is usually not used as the definitive localizing study before surgery but is used to assess the utility of angiography. If the tagged red blood cell scan is negative or is positive only after several hours, then angiography is unlikely to be effective and can be avoided as it carries significant morbidity (hematomas, acute renal failure, contrast reactions, arterial thrombosis, and bowel ischemia). Tagged red blood cell scan can detect bleeding down to a range of 0.1 mL/min.

Mesenteric angiography can detect bleeding down to a range of 0.5 mL/min and is only used if there is ongoing hemorrhage. Angiography is also both diagnostic and therapeutic. The superior mesenteric artery is usually injected first since most colonic bleeding originates from the right side. If there is no bleeding found on injection of the superior mesenteric artery, the inferior mesenteric artery is then injected to evaluate the left side of the colon, followed by injection of the celiac axis. Treatment options include highly selective or selective embolization of the bleeding site.

Bleeding from a Meckel diverticulum is usually found in the young adult population and can be localized through intravenous injection of technetium-99 m pertechnetate. This compound is taken up and secreted by the gastric mucous cells, so the scan will localize a Meckel diverticulum (since ectopic gastric mucosa is the source of the bleeding).

Capsule endoscopy can be performed if colonoscopy and tagged red blood cell scan are negative in the face of persistent bleeding to identify a potential small intestine site. If the patient has massive bleeding and is unstable, then the patient is taken directly to the operating room where localization of the bleeding is performed intra-operatively with serial clamping or enteroscopy. Depending on the stability of the patient, an intra-operative esophagogastroduodenoscopy may be appropriate as well to rule out upper gastrointestinal bleeding.

References:

Moss AK, Hodin RA. Approach to lower gastrointestinal bleeding. In: Cameron JL, Cameron AM, eds. *Current Surgical Therapy.* 10th ed. Philadelphia, PA: Mosby; 2011: 268–270.

Tavakkolizadeh A, Ashley SW. Acute gastrointestinal hemorrhage. In: Towsend CM, Beauchamp RD, Evers BM, Mattox KL, eds. *Sabiston Textbook of Surgery.* 19th ed. Philadelphia, PA: Saunders Elsevier; 2012:1160–1181.

۰۲۱-۶۶۱۹۸۵۱۴ www.myuptodate.com دریافت آخرین نسخه آپتودیت آفلاین

2G38

Key word: Diagnostic Test for Suspected Boerhaave Syndrome

Author: Vicente Valero III, MD
Editor: Robert A. Meguid, MD, MPH

A 64-year-old man with a history of diabetes mellitus and hypertension presents to the emergency department complaining of sudden severe chest pain after a night of heavy drinking complete with multiple episodes of vomiting and retching. He denies hematemesis or hemoptysis. An electrocardiogram displays sinus tachycardia with no signs of ischemia, and a chest radiograph reveals a pneumomediastinum and a small left-sided pleural effusion. What is the definitive study that should be ordered to confirm a diagnosis in this patient?

(A) Computed tomography (CT) scan of the chest and abdomen
(B) Echocardiogram
(C) Esophagogram
(D) Flexible bronchoscopy
(E) Serum troponin level

Answer: (C) Esophagogram

Rationale:

Boerhaave syndrome is spontaneous esophageal perforation that classically presents after episodes of persistent vomiting and retching. The prolonged increase in intra-abdominal pressure that occurs with such episodes of vomiting and retching can result in transmural lacerations of the esophagus. Boerhaave syndrome accounts for approximately 15% of esophageal ruptures and is classically seen in patients with alcoholism. Mackler triad is often seen, consisting of chest pain, emesis, and subcutaneous emphysema. Hamman sign, which is a crunching sound over the precordium, can also be observed in Boerhaave syndrome. A chest radiograph is the initial screening study of choice and may reveal pneumomediastinum and subcutaneous air. If obtained soon after the event associated with perforation, chest radiographs may appear normal. However, within 12 hours of the event, 75% of chest radiographs demonstrate pathology. A left-sided pleural effusion can also be seen in a subset of patients. Serum amylase can be elevated due to the resorption of saliva, which can sometimes confuse the diagnosis and lead one to suspect pancreatitis.

A contrast esophagogram is the confirmatory test for esophageal perforation, and differentiates between mucosal tears, leaks contained within the mediastinum, and perforations into the pleural space. Esophagograms with water-soluble contrast have a false-negative rate up to 50%. If the study does not demonstrate leak, and suspicion for perforation is high, it should be followed with dilute barium. The study should be repeated a few hours later if still negative, as contrast esophagograms have an overall false-negative rate of 10%. CT imaging with oral contrast is often performed during workup and may reveal signs of perforation, but CT is not reliably sensitive to detect perforations, potentially resulting in a false-negative result. In addition, the dynamic study of an esophagogram can demonstrate location of the perforation, aiding in surgical management, while an adynamic CT study may fail to reveal the site of the perforation.

Early diagnosis and appropriate management within 24 hours is paramount because of the potential for development of sepsis. The overall survival declines over time from 90% to less than 50% with delay in appropriate management. Resuscitation, administration of broad-spectrum antibiotics and antifungal agents, and source control and drainage of infection are the principles of management. Operative approach is via thoracotomy on the side where the perforation drains into as seen on esophagogram. This is usually through a left-sided thoracotomy, as the typical site of injury is just above the gastroesophageal junction on the left lateral wall of the esophagus. In the absence of associated pathology, such as cancer or a stricture, surgical management includes drainage of the chest, debridement of the lung, and repair of the esophageal laceration. The perforation of the mucosa of the esophagus is often longer than the perforation of the muscle wall. Therefore, a tenant of repair is to open the muscle layer longitudinally to fully expose the mucosa and facilitate mucosal apposition of the full length of the tear after debridement of necrotic tissue. An intercostal muscle flap or other vascularized tissue flap is used to reinforce the repair. If the esophagogram demonstrates bilateral drainage, then placement of tube thoracostomies contralateral to the thoracotomy is indicated, and more extensive contralateral chest exploration may be warranted.

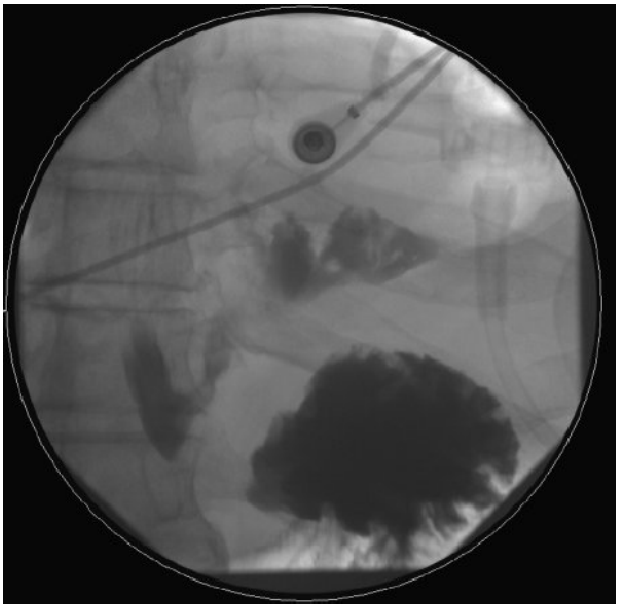

A contrast esophagram of a Boerhaave perforation of the esophagus at the gastroesophageal junction resulting in a left pleural contamination. Reprinted with permission from: Blackmon SH, Krasna MJ. Esophageal leaks and fistulas (esophageal perforation). In: Franco KL, Thourani VH, eds. *Cardiothoracic Surgery Review*. Philadelphia, PA: Lippincott Williams & Wilkins; 2012:1419.

References:

Jobe BA, Hunter JG, Peters JH. Esophagus and diaphragmatic hernia. In: Brunicardi FC, Brandt ML, Andersen DK, Billiar TR, Dunn DL, Hunter JG, Matthews JB, Pollock RE, eds. *Schwartz's Principles of Surgery.* 9th ed. New York, NY: McGraw-Hill; 2010:906–908.

Wright CD. Management of esophageal perforation. In: Sugarbaker DJ, Bueno R, Krasna MJ, Mentzer SJ, Zellos L, eds. *Adult Chest Surgery.* New York, NY: McGraw Hill; 2009:353–360.

۰۲۱-۶۶۱۹۸۵۱۴ www.myuptodate.com دریافت آخرین نسخه آپتودیت آفلاین

2G39

Key word: Treatment of Recurrent Sigmoid Volvulus

Author: Trevor A. Ellison, MD, MBA
Editor: Elizabeth C. Wick, MD

An 89-year-old female is brought into the Emergency Department with a second episode of "enlarged belly" and not passing stool for 2 days. Upon examination, the patient has baseline dementia, the abdomen is markedly distended and tympanic, and there is involuntary guarding with rebound tenderness. Abdominal radiograph reveals a classic "bent inner tube" sign. What is the best management?

(A) Go to the operating room for sigmoidectomy

(B) Go to the operating room for total abdominal colectomy

(C) Perform a sigmoidoscopy and leave a rectal tube in place

(D) Place a nasogastric tube and follow the patient with serial abdominal radiographs

(E) Proceed with a barium enema to confirm the diagnosis

Answer: (A) Go to the operating room for sigmoidectomy

Rationale:

This patient has a recurrent sigmoid volvulus (in this instance, recurrence is determined by the history of a similar event). Sigmoid volvulus occurs when the sigmoid is disproportionately long compared to the mesenteric base so it twists in either a clockwise or counterclockwise manner (more commonly counterclockwise), with the most common being a 360-degree twist (50%), 180-degree twist (35%), or 540-degree twist (10%). This torsion usually occurs about 15 to 25 cm from the anus.

Sigmoid volvulus is most common in the elderly (—seventh to eighth decade of life), those with psychiatric or neurologic disease (medications for these conditions have been implicated in decreased bowel motility), and those who are institutionalized. Sigmoid volvulus constitutes 66% to 75% of those with a colonic volvulus.

The diagnosis of sigmoid volvulus is made 80% of the time with a plain abdominal radiograph where the air-distended bowel gives the appearance of a "bent inner tube." A barium enema may show a "bird's beak" or "ace of spades" image. While barium enema can reduce the volvulus in 5% of cases, it is contraindicated if strangulation with gangrene is suspected (as in this case). If further imaging is required, a computed tomography (CT) scan may be performed and may show the characteristic "whirl sign."

Initial treatment for a first-time sigmoid volvulus that is not suspected to be gangrenous is nonsurgical, with decompression by a flexible or rigid endoscope successfully detorsing the bowel in 70% to 90%, although there is a 40% to 90% recurrence rate. Some type of active decompression is necessary, however, as only 2% will decompress spontaneously. After decompression, a rectal tube that passes the point of torsion must be left in place for 48 to 72 hours, and surgery can then be scheduled electively during the same admission (due to the high recurrence rate).

In patients with suspected gangrene, emergency resection is necessary. Mortality in these emergent resections is 31% compared to 8% in elective resections. Resection should be performed without untwisting the volvulus to avoid releasing bacteria and inflammatory mediators from the vessels and lymphatics. The sigmoidectomy can be completed with either a colostomy and mucous fistula (Hartmann procedure) or with a primary anastomosis. Primary anastomosis should be avoided in acidotic, cold, coagulopathic, and hemodynamically unstable patients with questionable bowel viability.

If the bowel is found to be viable at the time of operation, colopexy is also an option, but recurrence of the volvulus is higher with this option compared to resection.

References:

Cocanour CS. Colonic volvulus. In: Cameron JL, Cameron AM, eds. *Current Surgical Therapy.* 10th ed. Philadelphia, PA: Saunders Elsevier; 2011:162–165.

Fry RD, Mahmoud N, Maron DJ, et al. Colon and rectum. In: Townsend CM, Beauchamp RD, Evers BM, Mattox KL, eds. *Sabiston Textbook of Surgery.* 18th ed. Philadelphia, PA: Saunders Elsevier; 2008:1369–1371.

۰۲۱-۶۶۱۹۸۵۱۴ www.myuptodate.com دریافت آخرین نسخه آپتودیت آفلاین

2G40

Key word: Most Common Etiology of Peptic Ulcer Disease

Author: Trevor A. Ellison, MD, MBA
Editor: Mehran Habibi, MD, MBA

A 72-year-old man develops sudden, sharp pain in his abdomen and starts feeling weak with a racing heart rate. He is brought to the Emergency Department where upright and supine abdominal radiographs reveal air under the diaphragm. If this patient is found to have a perforated peptic ulcer, which clinical entity must be addressed after surgery?

(A) Bacterial overgrowth of the stomach and duodenum
(B) *Campylobacter jejuni* infection
(C) *Helicobacter pylori* infection
(D) Level of activity and exercise
(E) Malnutrition

Answer: (C) *Helicobacter pylori* infection

Rationale:
The National Institutes of Health has issued guidelines that require *H. pylori* management in the treatment of peptic ulcer disease. It is believed that 90% of duodenal ulcers and 75% of gastric ulcers are associated with *H. pylori* infection. Once the *H. pylori* infection is treated, ulcer recurrence is very rare. Although the mechanism through which *H. pylori* induces ulcers is not fully understood, three potential mechanisms are the direct production of toxic factors that damage the local mucosa, the increased production of gastrin contributing to increased acid secretion, and the induction of a mucosal immune response.

Reference:
Mercer DW, Robinson EK. Stomach. In: Townsend CM, Beauchamp RD, Evers BM, Mattox KL, eds. *Sabiston Textbook of Surgery.* 18th ed. Philadelphia, PA: Saunders Elsevier; 2008:1236–1237.

2G41

Key word: Site of Gastrointestinal Protein Absorption

Author: Trevor A. Ellison, MD, MBA
Editor: Christopher L. Wolfgang, MD, PhD

The majority of uptake of small peptides (dipeptides and tripeptides), as opposed to single amino acids, occurs in which part of the digestive tract?

(A) Colon
(B) Duodenum
(C) Ileum
(D) Jejunum
(E) Stomach

Answer: (D) Jejunum

Rationale:
Small peptides (dipeptides and tripeptides) are preferentially taken up in the jejunum via a secondary active transport mechanism. The small peptides are co-transported into the cell with a hydrogen ion; the hydrogen ion gradient is established by a sodium–hydrogen exchanger on the cell membrane. Single amino acids are preferentially taken up in the ileum via diffusion, secondary active uptake, and facilitated transport. Large peptides and intact proteins are not taken up in any nutritionally significant manner by the human digestive tract. Glutamine, glutamate, and aspartate are the preferred energy source for intestinal epithelial cells, while the short-chain fatty acid butyrate is the principal energy source for colonocytes (followed by acetoacetate, glutamine, and glucose).

References:
Berne RM, Levy MN, eds. Digestion and absorption. *Physiology.* 4th ed. Philadelphia, PA: Mosby; 1998:652–653.
Tawa NE, Fischer JE. Metabolism in surgical patients. In: Towsend CM, Beauchamp RD, Evers BM, Mattox KL, eds. *Sabiston Textbook of Surgery.* 18th ed. Philadelphia, PA: Saunders Elsevier; 2008:182–183.

۰۲۱-۶۶۱۹۸۵۱۴ www.myuptodate.com دریافت آخرین نسخه آپتودیت آفلاین

2G42

Key word: GI Hemorrhage and Inhibition of Gastric Acid Secretion

Author: Trevor A. Ellison, MD, MBA
Editor: Christopher L. Wolfgang, MD, PhD

A 56-year-old woman with known peptic ulcer disease is rushed to the operating room for massive upper gastrointestinal bleeding found to be originating from an ulcer situated near the gastroesophageal junction on the lesser curvature of the stomach. During the operation, she will also need:

(A) Gastroduodenal artery ligation

(B) Highly selective vagotomy

(C) Selective vagotomy

(D) Truncal vagotomy

(E) Ulcer resection only

Answer: (E) Ulcer resection only

Rationale:

This patient has a type IV gastric ulcer. Like type I and type V gastric ulcers, it is not associated with acid hypersecretion and therefore does not require an acid-reducing operation. This patient instead needs resection and closure or a Csendes' procedure (subtotal gastrectomy with a Roux-en-Y jejunal reconstruction). Type II and type III ulcers are associated with acid hypersecretion and require acid reduction either medically or surgically.

Gastric ulcers are divided into five types based on their location as well as their acid-secretory status. Type I ulcers (60%) are found on the lesser curvature between the fundus and the antrum (just proximal to the incisura), type II ulcers (15%) are simultaneous ulcers with one in the body of the stomach near the incisura and the other in the duodenum, type III ulcers (20%) are prepyloric and can be multiple, type IV ulcers (<10%) are on the lesser curvature near the gastroesophageal junction, and type V ulcers can occur anywhere in the stomach and are related to NSAID use.

References:

Mercer DW, Robinson EK. Stomach. In: Towsend CM, Beauchamp RD, Evers BM, Mattox KL, eds. *Sabiston Textbook of Surgery.* 18th ed. Philadelphia, PA: Saunders Elsevier; 2008:1238–1239.

Newman NA, Mufeed S, Makary MA. Benign gastric ulcer. In: Cameron JL, Cameron AM, eds. *Current Surgical Therapy.* 10th ed. Philadelphia, PA: Mosby; 2011:63–68.

2G43

Key word: Surveillance for Recurrent Colorectal Cancer

Author: Kyle J. Van Arendonk, MD, PhD
Editor: Michael A. Choti, MD, MBA

A 65-year-old man presents for follow-up after an uneventful left hemicolectomy for stage IIA colon cancer. Which of the following is true regarding surveillance for recurrence of colorectal cancer?

(A) Follow-up colonoscopies are recommended to detect anastomotic recurrences and metachronous lesions

(B) Intense surveillance programs may decrease morbidity but provide no survival benefit

(C) Measurement of carcinoembryonic antigen (CEA) is not recommended

(D) Measurement of liver function tests must be included in surveillance

(E) Routine computed tomography (CT) is not recommended

Answer: (A) Follow-up colonoscopies are recommended to detect anastomotic recurrences and metachronous lesions

Rationale:

Despite appropriate surgery and the administration of adjuvant and neoadjuvant therapies for colorectal cancer, disease relapse occurs in the form of either local recurrence or metastatic disease in approximately 30% to 50% of patients. The incidence of recurrence of course varies widely according to the stage of the cancer, as well as tumor grade, location, venous/perineural invasion, and aneuploidy and technical factors such as obtaining adequate margins of resection.

Early detection of these relapses when they are still surgically treatable provides the best chance for secondary cure, and therefore postoperative surveillance programs for locoregional recurrence and distant metastases are vital. A Cochrane review of randomized controlled trials comparing different follow-up strategies found an overall survival benefit for intensifying the follow-up of patients after curative surgery for colorectal cancer. Given the wide variation in the specifics of the follow-up programs, the review could not identify, however, the precise best frequency or combination of follow-up examinations.

A variety of groups including the American Society of Colon and Rectal Surgeons (ASCRS), the American Society of Clinical Oncology (ASCO), and the National Cancer Comprehensive Network (NCCN) have published guidelines recommending various surveillance strategies. Although each strategy varies with regard to details, the guidelines in general recommend a regular history and physical examination, CEA testing, chest and abdominal imaging, and colonoscopy.

A thorough history may provide symptoms of recurrence such as weight loss or change in bowel habits. Physical examination may reveal signs of advanced disease such as an abdominal mass. CT of the chest is recommended annually for the first 3 years by ASCO and NCCN. The same groups

۰۲۱-۶۶۱۹۸۵۱۴ www.myuptodate.com دریافت آخرین نسخه آپتودیت آفلاین

also recommend CT of the abdomen and pelvis every 6 to 12 months for approximately 3 years. Colonoscopy is recommended to detect anastomotic recurrences and metachronous lesions. The recommended frequency is approximately 3- to 5-year intervals but greatly depends upon the presence of genetic predisposition and other risk factors. CEA has a sensitivity of just 64% but a specificity of 90% for detecting recurrence of colorectal cancer and is recommended every 3 to 6 months for the first several years. Of note, other routine blood work including liver function tests are not helpful as they are abnormal only rarely and typically in only the presence of advanced, unresectable disease.

References:

Jeffery GM, Hickey BE, Hider P. Follow-up strategies for patients treated for non-metastatic colorectal cancer. *Cochrane Database Syst Rev*. 2002;(1):CD002200.

Mathis KL, Nelson H. Recurrent and metastatic colorectal cancer. In: Yeo CJ, ed. *Shackelford's Surgery of the Alimentary Tract.* 7th ed. Philadelphia, PA: Elsevier; 2013:2133–2148.

2G44

Key word: Cell Type for Benign Gastric Ulcer

Author: Betsy King, MD
Editor: Mehran Habibi, MD, MBA

A 35-year-old male with no significant medical history presents with a 1-month history of postprandial epigastric pain and a 4.54 kg (10 lb) weight loss. He undergoes esophagogastroduodenoscopy, which demonstrates a large ulcer within the fundus of the stomach. If this is a benign gastric ulcer, which of the following findings would you expect on biopsy?

(A) Intestinalization of the gastric mucosa

(B) Polymorphic neutrophils surrounding spiral-shaped organisms

(C) Mucin-rich vacuoles within the cell apices

(D) Poorly demarcated border

(E) Signet ring cells

Answer: (B) Polymorphic neutrophils surrounding spiral-shaped organisms

Rationale:

Gastric malignancy will often ulcerate through the gastric mucosa. If ulceration is identified on endoscopy, a biopsy should therefore be performed to determine the underlying cause and to rule out malignancy. Ulceration from cancer is much more likely in older patients who lack risk factors for gastric ulcer disease.

The three main risk factors for benign gastric ulcer disease are NSAID use, cigarette smoking, and infection with *Helicobacter pylori. H. pylori* colonization is found in as many as 90% of patients with gastric ulcer disease. Failure to eradicate the organism is the most common cause of recurrent ulceration. Benign gastric ulcers are typically small, <1-cm, well-demarcated lesions with surrounding normal mucosa. Unlike gastric cancers, which tend to occur in the stomach antrum, benign ulcers are found anywhere in the stomach. The base of the ulcer will often appear brown or black due to acidic digestion of blood. Benign ulcers are often found alongside evidence of acute or chronic gastritis. *H. pylori* colonization is often associated with the presence of inflammatory cells, and silver staining will reveal polymorphic neutrophils within the lamina propria and crossing the basement membrane. In addition, the organism itself can be seen as a spiral on silver stain.

Gastric adenocarcinoma can present with intestinal-type neoplastic cells, which are often rich in mucin-filled vacuoles. Likewise, signet ring cells are a malignant cell type often seen in gastric cancers.

References:

Newman NA, Mufeed S, Makary MA. Benign gastric ulcer. In: Cameron JL, Cameron AL, eds. *Current Surgical Therapy.* 10th ed. Philadelphia, PA: Saunders Elsevier; 2011:63–68.

Turner JR. The gastrointestinal tract. In: Perkins JA, ed. *Robbins and Cotran Pathologic Basis of Disease.* 8th ed. Philadelphia, PA: Saunders Elsevier; 2010:763–831.

۰۲۱-۶۶۱۹۸۵۱۴ www.myuptodate.com دریافت آخرین نسخه آپتودیت آفلاین

2G45

Key word: Etiology of Urinary Stones

Author: Ibrahim Sultan, MD
Editor: Mohamad E. Allaf, MD

Calcium-based urinary stones are typically seen with which of the following conditions?

(A) Cystinuria

(B) Gout

(C) Myeloproliferative disorders

(D) Proteus colonization or infection of the genitourinary tract

(E) Sarcoidosis

Answer: (E) Sarcoidosis

Rationale:
Calcium-based kidney stones and calcium oxalate stones in particular are the most common kind of kidney stones in the United States and other industrialized countries. These stones are often found in patients with sarcoidosis, hyperparathyroidism, renal tubular acidosis, and hyperabsorption of oxalates (e.g., after ileal resection). Uric acid stones are found in patients with gout, myeloproliferative disorders, and acidic urine. Uric acid stones are typically radiolucent on x-ray, unlike calcium-based stones, which are radiopaque.

Struvite (magnesium ammonium phosphate) stones occur in patients with chronic urinary tract infection with bacteria (Proteus and Klebsiella species) that produce urease, which causes alkaline urine to promote formation of these stones. Struvite stones can occur as branched stones in the collecting system (staghorn stones). Cystine stones occur in patients with the autosomal recessive condition cystinuria in which cystine is inadequately reabsorbed in the kidney.

References:
Ferrandino MN, Pietro PK, Preminger GM. Evaluation and medical management of urinary lithiasis. In: Wein AJ, Kavoussi LR, Novick AC, Partin AW, Peters CA, eds. *Campbell-Walsh Urology.* 10th ed. Philadelphia, PA: Elsevier; 2012:1287–1323.

Olumi AF, Richie JP. Urologic surgery. In: Towsend CM, Beauchamp RD, Evers BM, Mattox KL, eds. *Sabiston Textbook of Surgery.* 18th ed. Philadelphia, PA: Elsevier; 2008:2251–2286.

2G46

Key word: Origin of Bilirubin

Author: Joshua H. Wolf, MD
Editor: Michael A. Choti, MD, MBA

Which of the following is a step in the biosynthesis of conjugated bilirubin?

(A) Bacterial β-glucuronidases assist with active transport of bilirubin into bile canaliculi

(B) Bilirubin reductase conjugates bilirubin to glucuronic acid

(C) Ferroprotoporphyrin IX (heme) is broken down into biliverdin, iron, and carbon monoxide

(D) Microsomal heme oxygenase converts bilirubin into biliverdin

(E) Uridine diphosphate-glucuronosyltransferase (UDPGT) hydrolyzes conjugated bilirubin and forms urobilinogens, which are mostly excreted

Answer: (C) Ferroprotoporphyrin IX (heme) is broken down into biliverdin, iron, and carbon monoxide

Rationale:
The body produces approximately 250 to 350 mg of bilirubin each day, 70% to 80% of which comes from hemoglobin degradation. The first two steps in the pathway are oxidation and reduction of heme and biliverdin and occur primarily in reticuloendothelial cells (spleen, liver):

1. Ferroprotoporphyrin IX (heme) $\xrightarrow{\text{Heme Oxygenase}}$ biliverdin, iron, carbon monoxide

2. Biliverdin $\xrightarrow{\text{Biliverdin Reductase}}$ bilirubin
   Bilirubin is insoluble and unable to enter the bloodstream, but it noncovalently binds to albumin and can thereby be transported to the liver where it is conjugated to glucoronic acid in the hepatocyte endoplasmic reticulum.

3. Bilirubin $\xrightarrow{\text{UDPGT*}}$ bilirubin monoglucuronide and bilirubin diglucuronide (conjugated bilirubin)
   *Uridine diphosphate-gluconosyl trasnferase

Conjugated bilirubin (soluble) is actively transported into the bile canaliculi via multiple drug resistance protein 2 (MDR2). Bilirubin is eventually excreted through the biliary tree into the small bowel and flows to the terminal ileum. There, bacterial flora assist in the hydrolysis and deconjugation of conjugated bilirubin to urobilinogen and urobilin (oxidized form) in the stool (80% to 90%). A smaller portion (20%) is reabsorbed and returns to the liver.

4. Conjugated bilirubin $\xrightarrow{\text{Bacterial β-glucuronidases}}$ urobilinogen

Reference:
Kaplan MM. Jaundice. In: Longo DL, Fauci AS, Kasper DL, Hauser SL, Jameson JL, Loscalzo J, eds. *Harrison's Principles of Internal Medicine.* 18th ed. New York, NY: McGraw-Hill; 2012.

۰۲۱-۶۶۱۹۸۵۱۴ www.myuptodate.com دریافت آخرین نسخه آپتودیت آفلاین

2G47

Key word: Preoperative Measurement of Portal Venous Pressure

Author: Betsy King, MD
Editor: Andrew M. Cameron, MD, PhD

A patient with cirrhosis is undergoing evaluation for a solitary 3-cm mass suspicious for hepatocellular carcinoma based on imaging. Preoperative measurement of the portal venous pressure reveals a portal–systemic pressure gradient of 11 mm Hg with preserved liver synthetic function, no ascites, and no encephalopathy. The best choice for management should be:

(A) The patient should be followed with repeat abdominal imaging in 3 months

(B) The patient should be started on sorafenib therapy

(C) The patient should undergo liver transplantation

(D) The patient should undergo nonanatomic liver resection

(E) The patient should undergo radiofrequency ablation

Answer: (E) The patient should undergo radiofrequency ablation

Rationale:

Preoperative evaluation and risk stratification for patients with liver cirrhosis prior to surgery traditionally included the Child–Pugh score calculated by the degree of encephalopathy, ascites, bilirubin, albumin, and International Normalized Ratio (INR) of the prothrombin time (see accompanying table). Portal hypertension, despite not being taken into account by this classification system, is associated with the development of complications associated with decompensated cirrhosis. Portal hypertension is defined as an increase in the portal venous pressure above 10 mm Hg and is measured as the pressure gradient between the portal vein and the inferior vena cava. Normal portal venous pressure is between 1 and 5 mm Hg. Complications such as varices, ascites, renal failure, and encephalopathy are highly correlated with portal hypertension. A gradient greater than 10 mm Hg is required for varices to form, and pressures higher than 12 mm Hg are associated with variceal bleeding.

The model for end stage liver disease, or MELD score, is a measurement of 90-day mortality in cirrhotic patients based on serum creatinine, serum bilirubin, and INR. The MELD score is used to prioritize patients for liver transplantation and more recently is being validated as a better predictor of surgical outcome in cirrhotic patients.

Treatment of hepatocellular carcinoma is surgical resection in patients with normal liver function and no portal hypertension who have a solitary liver nodule <5 cm or up to 3 nodules <3 cm. However, in patients with portal hypertension, otherwise resectable tumors can lead to increased intra-operative and postoperative complications, making radiofrequency ablation a better option. Liver transplantation is also an option; however in the patient described above, the MELD score would be unlikely to qualify the patient for a timely liver transplantation. Repeat imaging with observation is only indicated in lesions <1 cm in size, as these lesions are more likely areas of patchy cirrhosis rather than hepatocellular carcinoma.

Child–Pugh Classification

	1 Point	2 Points	3 Points
Bilirubin (mg/dL)	<2	2–3	>3
Albumin (g/dL)	>3.5	2.8–3.5	<2.8
Ascites	Absent	Moderate	Severe
Encephalopathy	Absent	Moderate	Severe
Prothrombin time			
Seconds prolonged	<4	4–6	>6
INR	<1.7	1.7–2.3	>2.3

INR, international normalized ratio.

A: 5–6 points; B: 7–9 points; C: 10–15 points.

Reprinted with permission from: Schulick RD. Hepatobiliary anatomy. In: Mulholland MW, Lillemoe KD, Doherty GM, Maier RV, Simeone DM, Upchurch GR, eds. *Greenfield's Surgery: Scientific Principles & Practice*. 5th ed. Philadelphia, PA: Lippincott Williams & Wilkins, 2011:883.

References:

Bosch J, Abraldes JG, Berigotti A, et al. The clinical use of HVPG measurements in chronic liver disease. *Nat Rev Gastroenterol Hepatol.* 2009;6:573–582.

Rikkers LF. Surgical complications of cirrhosis and portal hypertension. In: Towsend CM, Beuchamp RD, Evers BM, Mattox KL, eds. *Sabiston Textbook of Surgery.* 18th ed. Philadelphia, PA: Saunders Elsevier; 2008.

Ripoll C, Groszmann R, Garcia-Tsao G, et al. Hepatic venous pressure gradient predicts clinical decompensation in patients with compensated cirrhosis. *Gastroenterology.* 2007; 133:481–488.

۰۲۱-۶۶۱۹۸۵۱۴ www.myuptodate.com دریافت آخرین نسخه آپتودیت آفلاین

2G48

Key word: Treatment of Increased Homocysteine Levels

Author: Andrew P. Dhanasopon, MD
Editor: Christopher L. Wolfgang, MD, PhD

Your patient is concerned that her coronary artery disease may be caused by elevated levels of homocysteine. Treatment with which of the following can help lower plasma homocysteine levels?

(A) Cysteine
(B) Phosphate
(C) Vitamin B1
(D) Vitamin B12
(E) Vitamin B3

Answer: (D) Vitamin B12

Rationale:
Prospective studies and case-control studies have shown that elevated levels of plasma homocysteine increase the risk of atherosclerosis of the coronary, cerebral, and peripheral arteries and of cardiovascular death. Rare homozygous defects of cystathionine β-synthase cause homocystinuria and homocysteinemia and are also associated with premature atherosclerosis, recurrent thromboses of coronary, cerebral, or peripheral arteries, and venous thrombosis. Since folate, Vitamin B6, and Vitamin B12 are essential cofactors in the metabolism of homocysteine, and their dietary intake show a strong inverse correlation with plasma homocysteine levels, it is thought that they may help decrease these adverse events.

However, lowering homocysteine levels may not improve outcomes. Two large, randomized, double-blind secondary prevention trials called HOPE2 and NORVIT compared treatment with vitamin B12, folic acid, or both for lowering plasma homocysteine levels, and showed that although the treatments lowered plasma homocysteine levels, there were no reductions in morbidity or mortality.

Reference:
Zachariah JP, Vasan RS, D'Agostino RB. The burden of increasing worldwide cardiovascular disease. In: Fuster V, Walsh RA, Harrington RA, eds. *Hurst's The Heart.* 13th ed. New York, NY: McGraw-Hill; 2011. http://www.accessmedicine.com/content.aspx?aID=7800303. Accessed April 15, 2013.

2G49

Key word: Site of Intrinsic Factor Secretion

Author: Emmanouil Pappou, MD
Editor: Mehran Habibi, MD, MBA

The site of intrinsic factor production and secretion in the stomach is:

(A) Antrum, by chief cells
(B) Antrum, by enteroendocrine cells
(C) Cardia, by mucous neck cells
(D) Fundus, by mucous neck cells
(E) Fundus, by parietal cells

Answer: (E) Fundus, by parietal cells

Rationale:
Intrinsic factor is produced by parietal cells, which are found in the fundus and body of the stomach. The stomach is divided into five arbitrarily defined regions, each with different cells and functions: The cardia, fundus, body, antrum, and pylorus. The cardia is the narrow part that surrounds the opening of the esophagus to the stomach. The fundus forms the upper curvature of the stomach. The body is the central region. The antrum is the funnel-shaped distal part of the stomach, and the pylorus is the distal end that connects the stomach with the duodenum.

The cardia contains mucous neck cells, which produce a mucous gel layer that protects gastric epithelium from the acidic environment. The fundus and body contain parietal (oxyntic) and chief (zymogenic) cells. Parietal cells secrete gastric acid and intrinsic factor, which is extremely important in the absorption of vitamin B12. Parietal cells also produce histamine, which is a strong stimulus for acid secretion. Chief cells secrete pepsinogen and gastric lipase. In the acidic environment of the stomach, pepsinogen is converted into pepsin, a highly active proteolytic enzyme. The fundus and body also contain enteroendocrine cells. These cells produce serotonin and endorphin, which act not only as gastrointestinal hormones but also as neurotransmitters in the central nervous system when released into the bloodstream. The antrum contains G cells that secrete gastrin and mucus-secreting cells. Gastrin stimulates secretion of gastric acid by the parietal cells. The cells of the pyloric glands produce mucus and appreciable amounts of lysozyme.

The protein-bound vitamin B12 (cobalamin) is liberated in the stomach by peptic digestion and is bound to R-protein, which is produced by the salivary glands in response to eating. The B12–R-protein complex passes the pylorus and is degraded by pancreatic proteases in the duodenum. It is only after this process that vitamin B12 is bound to intrinsic factors. The B12–intrinsic factor complex migrates through the small bowel and attaches to the receptors in the distal ileum. Subsequently, vitamin B12 is transported across the cell membrane and from there to the portal bloodstream bound to transcobalamin. B12 circulates in the enterohepatic circulation, and 90% of B12 secreted into the bile is reabsorbed.

۰۲۱-۶۶۱۹۸۵۱۴ www.myuptodate.com دریافت آخرین نسخه آپتودیت آفلاین

Normally, about 2 mg of B12 is stored in the liver and another 2 mg elsewhere in the body. Thus, the reservoir of vitamin B12 is sufficient for 3 to 6 years if B12 absorption were suddenly to stop.

Secretion of intrinsic factor is stimulated via all pathways known to stimulate gastric acid secretion: Histamine, gastrin, and acetylcholine. Vitamin B12 deficiency can be caused by inadequate dietary intake (strict vegan diet), gastric abnormalities (pernicious anemia with autoantibodies against intrinsic factor, gastrectomy, or chronic gastritis causing a decline in intrinsic factor production), small bowel disease (malabsorption, Crohn disease, prior ileal resection), or pancreatic insufficiency.

References:

Festen HP. Intrinsic factor secretion and cobalamin absorption. Physiology and pathophysiology in the gastrointestinal tract. *Scand J Gastroenterol Suppl.* 1991;188:1–7.

Nicolas JP, Gueant JL. Gastric intrinsic factor and its receptor. *Baillieres Clin Haematol.* 1995;8(3):515–531.

Seetharam B, Alpers DH. Absorption and transport of cobalamin (vitamin B12). *Annu Rev Nutr.* 1982;2:343–369.

2G50

Key word: Most Common Hepatic Duct Aberration

Author: Joshua H. Wolf, MD
Editor: Barish H. Edil, MD

In preparation for a right lobe hepatectomy as part of a living donor liver transplantation, a potential living donor undergoes magnetic resonance imaging to evaluate the biliary tree. He is found to have the most common hepatic duct aberration, which is:

(A) A "triple confluence" made up of the right anterior, right posterior, and left hepatic ducts

(B) An accessory right posterior hepatic duct that drains into the common hepatic duct

(C) Anomalous drainage of the right posterior duct into the common hepatic duct

(D) The right posterior duct drains into the left hepatic duct

(E) The right posterior duct empties into the left aspect of the right anterior duct

Answer: (D) The right posterior duct drains into the left hepatic duct

Rationale:

Only 58% of the population has "classic" biliary anatomy. Because of this variation, detailed preoperative evaluation of biliary anatomy is necessary in liver donors in order to prevent biliary complications, which are the most common cause of donor morbidity after living donor liver transplantation.

In most patients, the right posterior duct runs posterior to the right anterior and merges onto its left side. In the most common hepatic duct aberration, the right posterior duct instead crosses to the left liver, joining the left hepatic duct before its junction with the right anterior. This variant is estimated to occur in approximately 13% to 19% of the population. In preparation for any hepatectomy that may involve these structures, the patient's precise anatomy should be clarified to avoid inadvertently dividing the right posterior drainage.

The alternative answer choices describe additional, less common variants. Of particular note, an "aberrant right hepatic duct" exists in approximately 5% of the population and occurs when the right posterior duct drains directly into the common hepatic duct. In this scenario, the aberrant duct is the only available drainage for segments VI and VII. If during laparoscopic cholecystectomy it is mistaken for the cystic duct and ligated, the patient may require biliary reconstruction. The presence of an accessory right hepatic drainage is less common (2%) and is typically less consequential because even if it is unintentionally divided, biliary drainage may still occur through the normal conduit.

۰۲۱-۶۶۱۹۸۵۱۴ www.myuptodate.com دریافت آخرین نسخه آپتودیت آفلاین

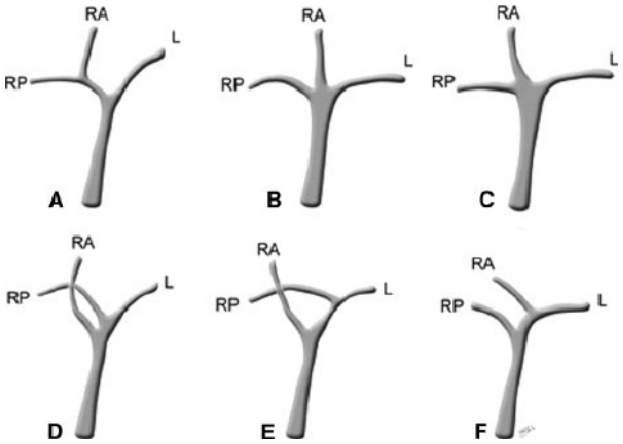

Normal and variant bile duct anatomy. L, left hepatic duct; RA, right anterior hepatic duct; RP, right posterior hepatic duct. Drawings show the normal anatomy **(A)**, trifurcation **(B)**, a short right hepatic duct **(C)**, continuation of the right anterior hepatic duct into the common hepatic duct **(D)**, drainage of the right posterior hepatic duct into the left hepatic duct **(E)**, and drainage of the right anterior hepatic duct into the left hepatic duct **(F)**. Reprinted with permission from: Catalano OA, Singh AH, Uppot RN, et al. Vascular and biliary variants in the liver: Implications for liver surgery. *Radiographics*. 2008;28(2):359–378.

References:

Catalano OA, Singh AH, Uppot RN, et al. Vascular and biliary variants in the liver: implications for liver surgery. *Radiographics*. 2008;28(2):359–378.

Mortele KJ, Ros PR. Anatomic variants of the biliary tree: MR cholangiographic findings and clinical applications. *AJR Am J Roentgenol*. 2001;177(2):389–394.

۰۲۱-۶۶۱۹۸۵۱۴ www.myuptodate.com دریافت آخرین نسخه آپتودیت آفلاین

3
CARDIOVASCULAR AND RESPIRATORY

CONTENTS:

Number:	Key word:	Page:
2C01	Diagnosis of Pericardial Tamponade after Stab Wounds to the Chest	422
2C02	Treatment of Postoperative Arrhythmia	422
2C03	Anesthetic Improving Outcomes after Rib Fractures	423
2C04	Best Treatment of Aortic Stenosis	424
2C05	Changes in Cardiac Physiology during Pregnancy	425
2C06	Diagnosis of Alveolar Hypoventilation	425
2C07	Indication for CABG for Chronic Angina	426
2C08	Initial Treatment of Vascular Steal Syndrome	427
2C09	Risk Factors for Abdominal Aortic Aneurysm	427
2C10	Treatment of Patient with AAA and Sigmoid Colon Cancer	428
2C11	Treatment of Empyema	429
2C12	Treatment of Endovascular Graft Failure Types I to V	430
2C13	Treatment of Graft Infection after Abdominal Aortic Aneurysm Repair	431
2C14	Treatment of Spontaneous Pneumothorax	431
2C15	Anatomy of the Left Vertebral Artery	432
2C16	Anatomy of Thoracic Duct Drainage	434
2C17	Characteristics of Functional Residual Capacity	435
2C18	Characteristics of Left Ventricular Performance	436
2C19	Characteristics of Primary Pulmonary Hypertension	437
2C20	Characteristics of Oncotic Pressure in Pulmonary Circulation	438
2C21	Conditions Associated with Persistent Fetal Circulation	439
2C22	Definition of Vital Capacity	440
2C23	Effect of Inhaled Nitric Oxide in Acute Respiratory Distress Syndrome Treatment	440
2C24	Etiology of Hand Ischemia Following Arteriovenous Fistula Placement	441
2C25	Hemodynamic Effects of Tension Pneumothorax	442
2C26	Response to Alveolar Hypoxia	443
2C27	Normal Cardiac Physiology in Infants	443

۰۲۱-۶۶۱۹۸۵۱۴ www.myuptodate.com دریافت آخرین نسخه آپتودیت آفلاین

2C01

Key word: Diagnosis of Pericardial Tamponade after Stab Wounds to the Chest

Author: Timothy J. George, MD
Editor: Glenn J.R. Whitman, MD

A 22-year-old male presents to the emergency department with a stab wound in the right sixth intercostal space just lateral to the sternal border. His blood pressure is 90/70 mm Hg, his pulse is 130 beats per minute, and he complains of shortness of breath. His trachea is midline and his neck veins are bulging. The most likely diagnosis is:

(A) Esophageal injury
(B) Pericardial tamponade
(C) Pneumothorax
(D) Pulmonary contusion
(E) Tracheobronchial injury

Answer: (B) Pericardial tamponade

Rationale:
In pericardial tamponade, the pericardium fills with fluid, often blood. Once the pericardium is maximally stretched, the building pressure compresses the heart itself, decreasing diastolic compliance and thus compromising venous return. This results in hypotension and also distention of neck veins from the elevated central venous pressure.

In penetrating trauma, cardiac injury should be suspected when any penetrating injury occurs in "the box," a rectangle bordered superiorly by the clavicles, inferiorly by the costal margins, and laterally by the midclavicular line. However, while cardiac injury must be suspected, patients who are hypotensive and short of breath with penetrating thoracic trauma can also have other injuries. In this case, while the dyspnea is consistent with pneumothorax and pulmonary contusion, the bulging neck veins are not associated with either entity. Moreover, patients with a tension pneumothorax are likely to have tracheal deviation, and pulmonary contusions are more commonly associated with blunt trauma. While both tracheobronchial injury and esophageal injury are possible, they are less likely, given the clinical presentation.

References:
Nagy KK, Lohmann C, Kim DO, et al. Role of echocardiography in the diagnosis of occult penetrating cardiac injury. *J Trauma.* 1995;38(6):859–862.
Spodick DH. Acute cardiac tamponade. *N Engl J Med.* 2003; 349(7):684–690.

2C02

Key word: Treatment of Postoperative Arrhythmia

Author: Timothy J. George, MD
Editor: Glenn J.R. Whitman, MD

On postoperative day 3 after a classic Whipple procedure, a 54-year-old man is found to be lethargic and tachycardic with a pulse of 180 beats per minute and blood pressure of 50 mm Hg/palpable. An EKG reveals an irregularly irregular rhythm. What is the most appropriate treatment of his arrhythmia?

(A) 1-mg IV atropine
(B) A bolus of 1 L of normal saline
(C) A bolus of amiodarone 150-mg IV followed by an amiodarone infusion
(D) Repeated boluses of metoprolol IV until heart rate normalizes
(E) Synchronized cardioversion

Answer: (E) Synchronized cardioversion

Rationale:
New onset atrial fibrillation is a common complication after surgery, particularly following cardiothoracic surgery. After abdominal surgery, atrial fibrillation generally occurs on postoperative days 2 to 5 when the patient is no longer requiring fluid resuscitation and is beginning to mobilize extravascular fluid. This fluid mobilization results in atrial distention, which can result in atrial fibrillation.

Atrial fibrillation classically results in an irregularly irregular rhythm. Hemodynamic stability is dependent on the ventricular response. Patients with rapid ventricular response can achieve elevated heart rates resulting in hemodynamic instability.

In patients with new onset atrial fibrillation who are hemodynamically unstable and manifesting signs of organ hypoperfusion, as in this vignette, urgent synchronized cardioversion is indicated. While there are many antiarrhythmic drugs than can cause chemical cardioversion, electrical cardioversion is most prudent in hemodynamically unstable patients.

In hemodynamically stable patients, initial treatment with antiarrhythmics is indicated. In the acute setting, simply rate control will lead to conversion to sinus rhythm in close to 50% of cases. However, rate control without conversion to sinus rhythm may require long-term anticoagulation in selected patients. Therefore, in patients with new onset atrial fibrillation, early elective cardioversion to obviate the need for any anticoagulation is reasonable. If the duration of atrial fibrillation exceeds 48 hours (or is unknown), an atrial thrombus needs to be ruled out with echocardiography before cardioversion to minimize the risk of embolization.

Amiodarone is a newer and effective drug for chemical cardioversion. Metoprolol does not facilitate cardioversion but can be effective for rate control. However, it is also likely to lower blood pressure. Atropine will increase the heart rate and is inappropriate. A fluid bolus may temporarily help with

۰۲۱-۶۶۱۹۸۵۱۴ www.myuptodate.com دریافت آخرین نسخه آپتودیت آفلاین

blood pressure, but fluid overload is also a likely cause of this patient's atrial fibrillation. After cardioversion and stabilization, diuresis is likely indicated.

References:

Gage BF, Waterman AD, Shannon W, et al. Validation of clinical classification schemes for predicting stroke: results from the National Registry of Atrial Fibrillation. *JAMA.* 2001;285(22):2864–2870.

Roy D, Talajic M, Nattel S, et al. Rhythm control versus rate control for atrial fibrillation and heart failure. *N Engl J Med.* 2008;358:2667–2677.

Wyse DG, Waldo AL, DiMarco JP, et al. A comparison of rate control and rhythm control in patients with atrial fibrillation. *New Engl J Med.* 2002;347:1825–1833.

Zimetbaum P. Amiodarone for atrial fibrillation. *New Engl J Med.* 2007;356:935–941.

2C03

Key word: Anesthetic Improving Outcomes after Rib Fractures

Author: Clinton D. Kemp, MD
Editor: Stephen C. Yang, MD, FACS, FCCP

A 48-year-old male painter falls from a ladder and presents to the emergency room. Primary and secondary surveys are notable for left-sided chest pain on palpation. He is splinting with deep inspiration. Radiography demonstrates nondisplaced fifth to ninth rib fractures. Which of the following options for pain control has been shown to provide superior outcomes in patients with rib fractures?

(A) Epidural anesthesia

(B) Intercostal nerve blockade

(C) Intravenous opioid medication

(D) Oral nonsteroidal anti-inflammatory medication

(E) Oral opioid medication

Answer: **(A)** Epidural anesthesia

Rationale:

Rib fractures are common following blunt traumatic injury to the chest. The severity of injury is proportional to the number of ribs fractured. The presence of three or more fractured ribs is associated with a higher incidence of underlying solid organ injuries and should prompt referral to a dedicated trauma center for evaluation and management. The finding of rib fractures should alert the clinician to the possibility of pneumothorax, hemothorax, and pulmonary contusion, and consideration must be given to admission of these patients for observation, pain control, and aggressive pulmonary toilet.

Even in the absence of underlying injuries, patients with rib fractures are at increased risk for development of atelectasis, pneumonia, and even respiratory failure due to splinting from pain and poor respiratory effort. Avoidance of the development of respiratory failure and intubation decreases the risk of pneumonia in these patients. The use of binders or taping of the chest for comfort interferes with proper pulmonary toilet by limiting chest excursion during inspiration and should be avoided.

Inadequate analgesia among patients with rib fractures is associated with hypoventilation, atelectasis, decreased clearance of secretions, and respiratory failure. Methods for pain management include oral and intravenous opioids, nonsteroidal anti-inflammatory agents, local therapy (intercostal nerve blockade, pleural blockade), and epidural-based therapies. The specific regimen is determined by the clinical scenario and patient response to a trial of pain management therapy.

The only method that has been demonstrated to have an impact on clinical outcomes following rib fractures is epidural anesthesia, typically delivered as a synergistic combination of opioids and local anesthetics. This method of pain relief is associated with improved pulmonary mechanics (increased

۰۲۱-۶۶۱۹۸۵۱۴ www.myuptodate.com دریافت آخرین نسخه آپتودیت آفلاین

vital capacity and negative inspiratory force), increased oxygenation as measured by partial pressure of oxygen (PaO_2), and improved ventilation as measured by decreased partial pressure of carbon dioxide ($PaCO_2$). In addition, epidural use leads to decreased ventilator dependence and decreased rates of nosocomial pneumonia.

Reference:

Livingston DH, Hauser CJ. Chest wall and lung. In: Feliciano DV, Mattox KL, Moore EE, eds. *Trauma.* 6th ed. New York, NY: McGraw Hill Professional; 2007:525–552.

2C04

Key word: Best Treatment of Aortic Stenosis

Author: Timothy J. George, MD
Editor: William A. Baumgartner, MD

An otherwise healthy 54-year-old male presents with stable angina. Echocardiography reveals an ejection fraction of 50% with an aortic valve area of 0.9 cm^2, a mean pressure gradient of 45 mm Hg, and a jet velocity of 4.5 m/sec. Which of the following is the best definitive therapy?

(A) Aortic valve replacement (AVR)

(B) Medical management with antihypertensive therapy

(C) Orthotopic heart transplantation

(D) Percutaneous balloon valvotomy

(E) Transcatheter AVR

Answer: (A) Aortic valve replacement (AVR)

Rationale:

The timing of aortic valve intervention is largely determined by two factors: The severity of the stenosis and the presence or absence of symptoms. Aortic stenosis is graded as follows.

Degree of Aortic Stenosis	Aortic Valve Area	Mean Gradient	Jet Velocity
Mild	≥1.5 cm^2	<25 mm Hg	<3.0 meters/second
Moderate	1–1.5 cm^2	25–40 mm Hg	3.0–4.0 meters/second
Severe	<1.0 cm^2	>40 mm Hg	>4.0 meters/second

Patients with severe aortic stenosis and symptoms (classically angina, syncope, or dyspnea) should undergo AVR. Asymptomatic patients with severe aortic stenosis can be followed closely unless they develop symptoms during exercise testing, have an ejection fraction <50%, have severe valvular calcification, have rapid progression of their stenosis, or are undergoing another cardiac operation.

There is no indication for medical management alone in patients with severe aortic stenosis who are healthy enough to undergo surgery. Percutaneous balloon valvotomy might be reasonable as a bridge to AVR in a hemodynamically unstable patient or in a patient with severe comorbidities and prohibitively high surgical risk. Neither is the case in this vignette, however. Transcatheter AVR is currently indicated in the United States only for clinical trials in patients at very high surgical risk. Traditional open AVR remains the standard of care. There is no indication for orthotopic heart transplantation in this patient.

Reference:

Bonow RO, Carabello BA, Chatterjee K, et al. 2008 focused update incorporated into the ACC/AHA 2006 guidelines for the management of patients with valvular heart disease. *Circulation.* 2008;118(15):e523–e661.

۰۲۱-۶۶۱۹۸۵۱۴ www.myuptodate.com دریافت آخرین نسخه آپتودیت آفلاین

2C05

Key word: Changes in Cardiac Physiology during Pregnancy

Author: Timothy J. George, MD
Editor: Glenn J.R. Whitman, MD

During pregnancy, a woman's blood volume:

(A) Decreases by 10% to 20%

(B) Decreases by 30% to 50%

(C) Does not change

(D) Increases by 10% to 20%

(E) Increases by 30% to 50%

Answer: (E) Increases by 30% to 50%

Rationale:
During pregnancy, women experience an expansion of plasma volume and a concomitant but less substantial increase in red cell volume resulting in a modest hematocrit reduction. Total plasma volume increases by 1.1 to 1.6 L resulting in a total plasma volume of 4.7 to 5.2 L by 34 weeks of gestation. Concomitantly, red blood cell mass increases by 15% to 30%. The resulting physiologic anemia results in decreased blood viscosity, which aids in placental perfusion and lower cardiac work. The increased plasma volume also provides some reserve against peripartum blood loss and increases cardiac output to aid in placental perfusion.

References:
Lund CJ, Donovan JC. Blood volume during pregnancy. Significance of plasma and red cell volumes. *Am J Obstet Gynecol.* 1967;98:394–403.

Pritchard JA. Changes in the blood volume during pregnancy and delivery. *Anesthesiology.* 1965;26:393–399.

Ueland K. Maternal cardiovascular dynamics. VII. Intrapartum blood volume changes. *Am J Obstet Gynecol.* 1976;126:671–677.

2C06

Key word: Diagnosis of Alveolar Hypoventilation

Author: Clinton D. Kemp, MD
Editor: Glenn J.R. Whitman, MD

A 70-year-old man with a 1-cm non–small-cell adenocarcinoma of his right upper lobe presents to your office for evaluation for resection of his tumor. He is thin, and although comfortable, he is breathing in a shallow and somewhat rapid fashion. Spirometry demonstrates an obstructive defect with a forced expiratory volume in 1 second (FEV_1)/forced vital capacity (FVC) of less than 70% of predicted and an FEV_1 of less than 50% of predicted. Which of the following regarding alveolar ventilation is true?

(A) Alveolar hypoventilation results in an increase in the partial pressure of carbon dioxide and hypercapnia

(B) Alveolar ventilation and minute ventilation are synonymous

(C) Alveolar ventilation can be directly measured using spirometry

(D) There is a direct relationship between alveolar ventilation and the partial pressure of carbon dioxide in the blood

(E) There is an indirect relationship between alveolar ventilation and the partial pressure of oxygen in the blood

Answer: (A) Alveolar hypoventilation results in an increase in the partial pressure of carbon dioxide and hypercapnia

Rationale:
Alveolar ventilation is defined as the gas exchange between the external environment and the alveoli and is a process which allows oxygen in the air to be delivered to the lungs during inspiration and carbon dioxide from the systemic circulation to be eliminated during expiration. There is no method for direct measurement of alveolar ventilation; rather it must be determined by measuring the tidal volume, respiratory rate, and the anatomic dead space.

There is a direct relationship between the partial pressure of oxygen and alveolar ventilation such that increases in alveolar ventilation will cause an increase in the partial pressure of oxygen, but this will eventually reach a plateau as the oxygen-carrying capacity of the blood is maximized. There is an inverse relationship between alveolar ventilation and the partial pressure of carbon dioxide in the blood. As ventilation increases, the partial pressure of carbon dioxide will decrease.

Alveolar hypoventilation exists when there is inadequate ventilation for the normal removal of carbon dioxide from the systemic circulation, leading to an increase in the partial pressure of carbon dioxide and hypercapnia. Eventually, this hypoventilation can also lead to a decreased partial pressure of oxygen and hypoxemia.

Alveolar hypoventilation can be acute or chronic and congenital or acquired. Congenital causes include congenital

۰۲۱-۶۶۱۹۸۵۱۴ www.myuptodate.com دریافت آخرین نسخه آپتودیت آفلاین

central hypoventilation syndrome (CCHS) or Ondine's curse. Acquired causes include obesity hypoventilation syndrome (OHS), chronic obstructive pulmonary disease (COPD), neuromuscular disorders (myasthenia gravis, amyotrophic lateral sclerosis, muscular dystrophy, and Guillain–Barré syndrome), or chest wall deformities (kyphoscoliosis). Often these patients can compensate for their alveolar hypoventilation by increasing their respiratory rate, effectively lowering the partial pressure of carbon dioxide in the blood and correcting their hypercapnia and hypoxia. These compensatory mechanisms can cause fatigue, however, and eventual respiratory failure may ensue.

Reference:

Levitsky MG, ed. Alveolar ventilation. *Pulmonary Physiology.* 7th ed. New York, NY: McGraw Hill; 2007:54–84.

2C07

Key word: Indication for CABG for Chronic Angina

Author: Timothy J. George, MD
Editor: William A. Baumgartner, MD

A 57-year-old male presents to clinic with chronic stable angina that limits his ability to climb stairs and perform activities of daily living. Cardiac catheterization reveals a 70% occlusion in the left anterior descending artery, an 80% occlusion in the left circumflex artery, and an 85% occlusion in the right coronary artery with an ejection fraction of 50%. What is the recommended management of this patient?

(A) Coronary artery bypass grafting

(B) Optimal medical management including aspirin, clopidogrel, beta-blocker, and a statin

(C) Percutaneous balloon angioplasty

(D) Percutaneous balloon angioplasty with stenting of all three lesions

(E) Transmyocardial laser revascularization

Answer: (A) Coronary artery bypass grafting

Rationale:

Asymptomatic patients and patients with stable angina have similar criteria for coronary artery bypass grafting. Indications include: (1) Left main coronary artery disease (≥50% stenosis of the left coronary artery); (2) left main coronary equivalent disease (≥70% stenosis of the proximal left anterior descending artery and the circumflex artery); (3) triple vessel disease (≥70% occlusion of the left anterior descending artery, the circumflex artery, and the right coronary artery); (4) proximal left anterior descending artery stenosis with single or double vessel disease with a left ventricular ejection fraction <50%; or (5) single or double vessel disease without proximal left anterior descending artery stenosis but with large areas of viable at-risk myocardium.

In patients who meet these criteria, coronary artery bypass grafting is thought to be superior to medical management and stenting. In patients with stable angina who do not meet these criteria, bypass grafting is indicated only if the patient has severely disabling angina despite maximal medical therapy. Transmyocardial laser revascularization is experimental at present.

Reference:

Chan V, Selke FW, Ruel M. Coronary artery bypass grafting. In: Selke FW, del Nido PJ, Swanson SJ, eds. *Sabiston and Spencer Surgery of the Chest.* 8th ed. Philadelphia, PA: Saunders; 2010:1367–1377.

۰۲۱-۶۶۱۹۸۵۱۴ www.myuptodate.com دریافت آخرین نسخه آپتودیت آفلاین

2C08

Key word: Initial Treatment of Vascular Steal Syndrome

Author: Babak J. Orandi, MD, MSc
Editor: Ying Wei Lum, MD

A 51-year-old male reports episodic light-headedness and vision changes that usually occur when he is working as a custodian. His pulse is 72 beats per minute; blood pressure is 126/87 mm Hg in the left arm and 147/103 mm Hg in the right arm. On physical examination, he is an obese man with a regular heart rate, no murmurs, clear lung sounds, a 2+ radial pulse on the right and a 1+ radial pulse on the left, and a carotid bruit present on the left but not on the right. The most appropriate next step in the diagnosis and management of his condition is:

(A) Carotid–subclavian bypass
(B) Computed tomography (CT) angiography
(C) Diagnostic angiography
(D) Duplex ultrasonography
(E) Endovascular stent placement

Answer: (D) Duplex ultrasonography

Rationale:
The patient is suffering from subclavian steal syndrome, which occurs when stenosis of the subclavian artery proximal to the origin of the vertebral artery results in retrograde blood flow in the ipsilateral vertebral artery. Blood flow is shunted preferentially away from the posterior circulation to the subclavian artery. Most stenoses are the result of atherosclerotic lesions. Patients are dependent on collateral blood flow through the circle of Willis, and any concomitant compromise of flow through the circle of Willis, the carotid arteries, or the contralateral vertebral artery will lead to symptoms.

Symptoms can include transient ischemic attacks, dizziness, vertigo, syncope, drop attacks, vision loss, ataxia, arm claudication, diminished or absent radial pulse, and a reduced blood pressure in the affected arm, and often occur after exercising the affected limb. The initial diagnostic test of choice is duplex ultrasonography as it has the benefit of being a noninvasive, relatively inexpensive, ionizing radiation-free imaging modality.

References:
Lum CF, Ilsen PF, Kawasaki B. Subclavian steal syndrome. *Optometry.* 2004;75:147–160.
Sidhu PS. Ultrasound of the carotid and vertebral arteries. *Br Med Bull.* 2000;56:346–366.

2C09

Key word: Risk Factors for Abdominal Aortic Aneurysm

Author: Babak J. Orandi, MD, MSc
Editor: Ying Wei Lum, MD

Which of the following is the strongest risk factor for the development of an abdominal aortic aneurysm (AAA)?

(A) Age over 75
(B) Current cigarette smoking
(C) Diabetes mellitus
(D) Family history of AAA
(E) History of previous or current antihypertensive medications

Answer: (B) Current cigarette smoking

Rationale:
In a large, population-based study in Norway, Singh et al. determined that advanced age, a history of previous or current antihypertensive medication use, and a family history of aneurysmal disease are all significant risk factors for the development of an AAA. Male gender is also associated with a four-fold increase in risk. However, the strongest risk factor for AAA was cigarette smoking, particularly current smoking (OR 7.37 [3.70–14.69] $p < 0.001$ for men; OR 5.82 [2.92–11.58] $p < 0.001$ for women). A Canadian case-control study confirmed those results and found a dose–response effect between pack-years of cigarettes smoked and the risk of AAA, underscoring the importance of smoking cessation. Diabetes mellitus is not a risk factor for the development of AAA.

References:
Blanchard JF, Armenian HK, Friesen PP. Risk factors for abdominal aortic aneurysm: Results of a case-control study. *Am J Epidemiol.* 2000;151:575–583.
Singh K, Bønaa KH, Jacobsen BK, et al. Prevalence of and risk factors for abdominal aortic aneurysms in a population-based study: The Tromsø Study. *Am J Epidemiol.* 2001;154:236–244.

۰۲۱-۶۶۱۹۸۵۱۴ www.myuptodate.com دریافت آخرین نسخه آپتودیت آفلاین

2C10

Key word: Treatment of Patient with AAA and Sigmoid Colon Cancer

Author: Babak J. Orandi, MD, MSc
Editor: Jonathan E. Efron, MD

An 82-year-old otherwise healthy and asymptomatic male with a recently diagnosed sigmoid colon cancer was noted on computed tomography (CT) to have a 6.1-cm infrarenal abdominal aortic aneurysm (AAA). The rest of his CT scan was unremarkable. The most appropriate management for this patient is:

(A) Endovascular aneurysm repair (EVAR), then left hemicolectomy at a later date

(B) Left hemicolectomy and continued surveillance for AAA growth

(C) Left hemicolectomy first, then EVAR at a later date

(D) Open AAA repair first, then left hemicolectomy at a later date

(E) Simultaneous open AAA repair and left hemicolectomy

Answer: (A) Endovascular aneurysm repair (EVAR), then left hemicolectomy at a later date

Rationale:

The management of synchronous colon cancer and AAA is a challenging scenario that requires the clinician to weigh the risk of delaying oncologic care and the possible metastatic spread of cancer with the risk of aneurysm rupture, particularly in the perioperative period. The literature is relatively sparse on this topic, particularly in the endovascular era, although several guidelines can help with decision making.

The aneurysm must first be large enough or symptomatic to warrant treatment. A 6.1-cm AAA found with an asymptomatic colon cancer has a high risk of rupture, mandating treatment of the AAA prior to resection of the colon cancer. In addition, whichever process poses a more immediate risk to the patient and/or is symptomatic ought to be dealt with first. For example, a rapidly expanding or symptomatic aneurysm should be treated first, as should an obstructing colon cancer. In this scenario, these special considerations do not apply.

The results of two retrospective studies with a combined 191 patients provide further guidance. Both studies found that open AAA repair followed by colorectal cancer resection at a later date had the highest rates of morbidity and mortality, as well as a significant delay in resecting the cancer. Both studies also demonstrated a 2.2% mortality rate secondary to aneurysm rupture in patients undergoing cancer resection first. While simultaneous management might seem attractive, there is, at least theoretically, an increased risk of bacteremia from the colon resection that could seed the aortic graft leading to graft infection.

In the larger of the two studies, survival analysis revealed a significant advantage to EVAR and subsequent colon resection. There was also a significant morbidity and mortality advantage of EVAR compared to open aneurysm repair. Given the infrequency of this clinical problem, it is unlikely that a randomized trial will ever be conducted to shed further light on this clinical conundrum.

References:

Baxter NN, Noel AA, Cherry K, et al. Management of patients with colorectal cancer and concomitant abdominal aortic aneurysm. *Dis Colon Rectum.* 2002;45:165–170.

Lin PH, Barshes NR, Albo D, et al. Concomitant colorectal cancer and abdominal aortic aneurysm: Evolution of treatment paradigm in the endovascular era. *J Am Coll Surg.* 2008;206:1065–1075.

۰۲۱-۶۶۱۹۸۵۱۴ www.myuptodate.com دریافت آخرین نسخه آپتودیت آفلاین

2C11

Key word: Treatment of Empyema

Author: Clinton D. Kemp, MD
Editor: Stephen C. Yang, MD, FACS, FCCP

After 1 week of antibiotics for right lower lobe pneumonia, a 55-year-old woman still has intermittent fevers and a leukocytosis. Chest radiography demonstrates a large pleural effusion. Thoracentesis demonstrates thick fluid with polymorphonuclear cells and bacteria, and a thoracostomy tube is placed. Over the next week the drainage from the thoracostomy tube decreases, yet she continues to have fevers, leukocytosis, and a persistent oxygen requirement. Computed tomography of her chest demonstrates loculated fluid collections in her right hemithorax that are not in communication with the thoracostomy tube, pleural thickening, and an incompletely expanded right lower lobe. Which of the following is the most appropriate therapy?

(A) Broadening antibiotic therapy with addition of antifungal coverage

(B) Noninvasive ventilation with positive pressure therapy

(C) Placement of an additional thoracostomy tube

(D) Thoracoscopic or open decortication

(E) Thoracoscopic or open resection of the involved right lower lobe

Answer: (D) Thoracoscopic or open decortication

Rationale:

Empyema describes the presence of purulent fluid in the pleural space and can occur following a pulmonary infection such as pneumonia or after a thoracic surgical procedure. Over half of patients with pneumonia will develop a pleural effusion that is known as a parapneumonic effusion, and the majority of these are not infected and will resolve on their own. In approximately 10% of cases, this parapneumonic effusion will become infected and lead to an empyema that warrants further therapy.

Three phases are used to describe the development of parapneumonic empyema. In the first phase (exudative), a pleural effusion develops secondary to increased pulmonary interstitial fluid from the underlying parenchymal infection as well as increased permeability of the pleural capillaries. Without treatment of the underlying pulmonary infection, this fluid can become secondarily infected, and loculations may develop, leading to the second phase (fibrinopurulent). If this infected fluid is not adequately drained, the third phase (organizing) develops when a dense inflammatory reaction occurs, and fibroblasts expand over the visceral and parietal pleura to cause a rind to form, which prevents full expansion of the lung. Once the rind has developed, decortication is necessary to drain any loculated collections and to allow for re-expansion of the lung and reapposition of the pleura.

This patient has developed a parapneumonic effusion that progressed through the three stages into a parapneumonic empyema. Despite appropriate antibiotic coverage and initial drainage, she has developed an additional loculated effusion as well as a pleural rind that is trapping her right lower lobe and preventing it from expanding. The best treatment for this patient is operative decortication to remove the pleural rind and allow for full pulmonary expansion, reapposition of the visceral and parietal pleura, and wide drainage of the right hemithorax.

Broadening antibiotic coverage will not address the incompletely drained empyema. Insertion of an additional thoracostomy tube will drain the residual empyema but will not allow for re-expansion of the right lower lobe. Noninvasive ventilation alone will not allow the right lower lobe to re-expand, nor will it address the undrained infection. Resection of the collapsed right lower lobe is not indicated for entrapped lung.

Reference:

Yu L, Krasna MJ. Parapneumonic empyema. In: Shields TW, Locicero J, Reed CE, Feins RH, eds. *General Thoracic Surgery.* 7th ed. Philadelphia, PA: Lippincott Williams and Wilkins; 2009:775–779.

۰۲۱-۶۶۱۹۸۵۱۴ www.myuptodate.com دریافت آخرین نسخه آپتودیت آفلاین

2C12

Key word: Treatment of Endovascular Graft Failure Types I to V

Author: Babak J. Orandi, MD, MSc
Editor: Ying Wei Lum, MD

Which of the following is correct regarding endoleaks following endovascular repair of abdominal aortic aneurysms?

(A) The sole indication for intervention for type II endoleaks is patient symptoms

(B) Type I and type II endoleaks generally require timely intervention

(C) Type I and type III endoleaks generally require timely intervention

(D) Type IV endoleak is defined as persistent sac pressurization in the absence of radiographic findings consistent with type I, II, or III endoleak

(E) Type V endoleak typically occurs during the procedure and resolves with the withdrawal of anticoagulation

Answer: (C) Type I and type III endoleaks generally require timely intervention

Rationale:

The term endoleak refers to the persistent flow of blood into an aneurysm sac following endovascular repair. A variety of endoleaks have been described and depending on the type, further action may be required. Type I endoleaks results from blood flowing into the aneurysm sac from around the proximal edge of the stent graft (type Ia) or from around the distal limb (type Ib). Type II endoleaks occur via retrograde blood flow into the aneurysm sac from an excluded blood flow, typically the inferior mesenteric artery or a lumbar artery.

Blood flow into the aneurysm sac through a rupture or tear in the fabric of the stent graft, or, in the case of multiple components in the stent graft, blood flow between components that have separated, occurs in type III endoleaks. Type IV endoleaks result from blood flow across the stent graft itself and is secondary to the graft's porosity. Type V endoleaks, also known as endotension, occurs when continued pressurization of the aneurysm sac persists in the absence of evidence of another type of endoleak.

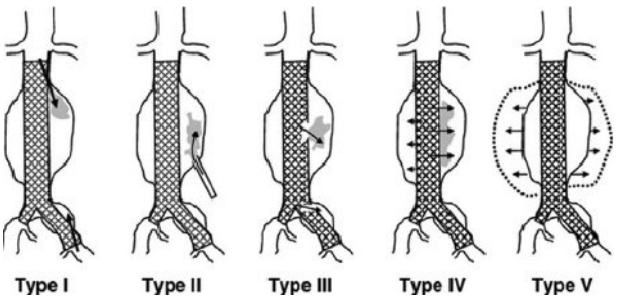

Reprinted with permission from: Pelberg RA, Mazur W. Abdominal aortic CT angiography. *Vascular CT Angiography Manual.* London: Springer-Verlag; 2011:229.

Type I and III endoleaks are considered high-pressure findings and generally require urgent intervention. Type II and V endoleaks may ultimately require intervention if the patient is symptomatic and/or there is continued aneurysm growth; however, these lesions can often be observed in the absence of symptoms or growth. Type IV endoleaks are usually intraoperative findings that resolve with the reversal of anticoagulation.

Reference:

Bashir MR, Ferral H, Jacobs C, et al. Endoleaks after endovascular abdominal aortic aneurysm repair: Management strategies according to CT findings. *Am J Roentgenol.* 2009; 192:W178–W186.

۰۲۱-۶۶۱۹۸۵۱۴ www.myuptodate.com دریافت آخرین نسخه آپتودیت آفلاین

2C13

Key word: Treatment of Graft Infection after Abdominal Aortic Aneurysm Repair

Author: Babak J. Orandi, MD, MSc
Editor: Ying Wei Lum, MD

A 74-year-old man who underwent open infrarenal abdominal aortic aneurysm (AAA) repair recently developed sigmoid diverticulitis with a 4-cm abscess that was successfully treated with percutaneous drainage and antibiotics. He now returns to the emergency department 2 months after treatment of his diverticulitis with persistent fevers, malaise, leukocytosis, and back pain. He is found to be bacteremic, and computed tomography (CT) scan demonstrates complete resolution of his diverticular abscess but with periaortic stranding and some gas bubbles surrounding the prior aortic repair. The most appropriate management of this patient is:

(A) Excision of the aortic graft and axillary–bifemoral bypass

(B) Exploratory laparotomy with abdominal washout

(C) Long-term intravenous antibiotics

(D) Repeat percutaneous drainage

(E) Sigmoid colectomy

Answer: (A) Excision of the aortic graft and axillary–bifemoral bypass

Rationale:

Infection of an aortic graft is a rare but serious complication that can occur following aneurysm repair and is associated with a mortality rate as high as 50%. Occasionally, the source of infection is via direct contact with the bacterial source, as in the case of aortoenteric fistula. Other times, bacteremia can seed the graft and lead to infection, likely the case in this scenario. There is no one-size-fits-all treatment for this condition, and because of the heterogeneity of the patients' severity of infection and overall health status, treatment must be tailored to the individual patient and their likelihood of surviving another operation. Treatment options include removal of the infected graft with extra-anatomic bypass, in situ graft replacement with autologous deep femoral vein, homograft, or rifampin-soaked graft, or in the case of poor surgical candidates, medical therapy with long-term antibiotics.

In a relatively large series, mortality with surgical therapy was approximately 14% compared to 36% for medical therapy, though the retrospective nature of the study does raise concern for selection bias. Of note, in general, regardless of the approach pursued, most patients are typically placed on long-term intravenous antibiotics followed by oral antibiotic suppressive therapy for life.

References:

Ducasse E, Calisti A, Speziale F, et al. Aortoiliac stent graft infection: current problems and management. *Ann Vasc Surg.* 2004;18(5):521–526.

Sambol EB, McKinsey JF. Local complications: Endovascular. In: Cronenwett JL, Johnston KW, eds. *Rutherford's Vascular Surgery.* 7th ed. Philadelphia, PA: Elsevier; 2010:697–715.

2C14

Key word: Treatment of Spontaneous Pneumothorax

Author: Clinton D. Kemp, MD
Editor: Stephen C. Yang, MD, FACS, FCCP

A 25-year-old tall and thin male presents to the emergency room with sudden onset of dyspnea and right-sided pleuritic chest pain. Although in pain, he is breathing with 97% oxygen saturation on room air. Physical examination is normal but chest radiograph demonstrates a 2.5-cm apical pneumothorax which does not track down the lateral wall. He reports that a similar episode happened 1 year ago, at which time he was admitted for observation but discharged the following day after his lung re-expanded on its own. Definitive management of his underlying condition is best accomplished by which of the following?

(A) Admission to the hospital for pulse oximetry and serial chest radiographs

(B) Discharge from the emergency department with clinic follow-up in 1 week

(C) Placement of a thoracostomy tube and chemical pleurodesis with doxycycline or talc

(D) Placement of a thoracostomy tube with removal following resolution of the pneumothorax

(E) Video-assisted thoracoscopic surgery (VATS) with resection of any residual bullae and mechanical pleurodesis

Answer: (E) Video-assisted thoracoscopic surgery (VATS) with resection of any residual bullae and mechanical pleurodesis

Rationale:

Spontaneous pneumothorax (SP) is defined as the development of pneumothorax in the absence of antecedent trauma or instrumentation. The pathophysiology is related to spontaneous rupture of underlying bullous disease. Primary SP occurs in patients with normal lung parenchyma and isolated blebs, while secondary SP occurs in patients with multiple bullae and underlying structural lung disease such as COPD.

The typical patient with primary SP is young (10 to 30 years of age), tall, and thin. Associated risk factors for development of primary SP include cigarette smoking. The incidence in the United States has been estimated to be approximately 20,000 cases per year and is higher in men (7.4 to 18 cases/100,000 population) than in women (1.2 to 6 cases/100,000 population).

The typical presentation of primary SP is the sudden onset of pleuritic chest pain with or without dyspnea, and signs include decreased breath sounds and hyper-resonance on percussion of the affected hemithorax. The presence of a pneumothorax can be detected on plain film radiography; computed tomography is not necessary but can be used as an adjunct diagnostic tool for evaluation of the pulmonary parenchyma and identification of additional bullous disease.

The management of primary SP depends on several factors: Clinical stability, size of the pneumothorax, number of

۰۲۱-۶۶۱۹۸۵۱۴ www.myuptodate.com دریافت آخرین نسخه آپتودیت آفلاین

previous episodes, presence of associated bullous disease, and patient factors such as lifestyle, occupation, and access to medical resources. Asymptomatic patients with small (<3 cm), apical pneumothoraces may be admitted to the hospital for observation and discharged without intervention if they remain asymptomatic with resolution of the pneumothorax. Evacuation of pneumothorax can be accomplished with simple aspiration, but for those with large (>3 cm) or symptomatic pneumothoraces, tube thoracostomy is recommended. The efficacy of tube thoracostomy for resolution of primary SP is estimated to be 90% for the first episode and decreases to 50% after the first recurrence and just 15% after the second recurrence.

Indications for surgical intervention in patients with primary SP typically include primary episodes with large or persistent air leaks, incomplete re-expansion of the lung, presenting in extremis, or having a prior contralateral pneumonectomy. Other relative indications include subsequent recurrent episodes, patients whose occupations (e.g., travels frequently) or recreational activities (e.g., scuba/sky diving) place them at higher risk for recurrence, and patients who live in communities without immediate access to medical care. The risk for a contralateral pneumothorax is about 10%. These cases are approached in a minimally invasive fashion using VATS to remove any remaining bullous disease and to perform mechanical pleurodesis to achieve full lung expansion and reapposition of the visceral and parietal pleura.

Chemical pleurodesis (talc or doxycycline solutions administered directly into the pleural space) can also be used to reestablish apposition of the visceral and parietal pleura to reduce the likelihood of recurrent primary SP. VATS with mechanical pleurodesis is typically preferred over chemical pleurodesis, however, because it allows for simultaneous examination and resection of any bullous disease that may be present.

References:

Baumann MH, Strange C, Heffner JE, et al. Management of spontaneous pneumothorax: an American College of Chest Physicians Delphi consensus statement. *Chest.* 2001; 119:590–602.

Reyes KG, Mason DP. Spontaneous pneumothorax. In: Selke FW, del Nido PJ, Swanson SJ, eds. *Sabiston's Surgery of the Chest.* 8th ed. Philadelphia, PA: Saunders Elsevier; 2009: 409–412.

2C15

Key word: Anatomy of the Left Vertebral Artery

Author: Babak J. Orandi, MD, MSc
Editor: Ying Wei Lum, MD

The left vertebral artery most commonly:

(A) Arises from the left common carotid artery

(B) Is distal to the left costocervical trunk

(C) Is the first branch arising from the left subclavian artery

(D) Is the source of the deep cervical artery

(E) Joins the anterior communicating artery to form the anterior component of the Circle of Willis

Answer: (C) Is the first branch arising from the left subclavian artery

Rationale:

The vertebral artery is the first branch of the subclavian artery. It arises directly from the subclavian artery proximal to the thyrocervical trunks. The most common anomalous variant in the origin of the vertebral artery (5% of population) involves the left vertebral artery originating directly from the arch of the aorta. The vertebral arteries enter deep to the transverse process of the C6 vertebrae and travel superiorly in the transverse foramen of the cervical vertebra until C1. They then proceed to join and form the basilar artery, which contributes to the posterior cerebral circulation.

References:

Brott TG, Halperin JL, Abbara S, et al. Guideline on the management of patients with extracranial carotid and vertebral artery disease. *J Neurointervent Surg.* 2011;3(2):100–130.

Netter F. *Atlas of Human Anatomy.* 2nd ed. Teterboro, NJ: Icon Learning Systems; 1997:130–131.

۰۲۱-۶۶۱۹۸۵۱۴ www.myuptodate.com دریافت آخرین نسخه آپتودیت آفلاین

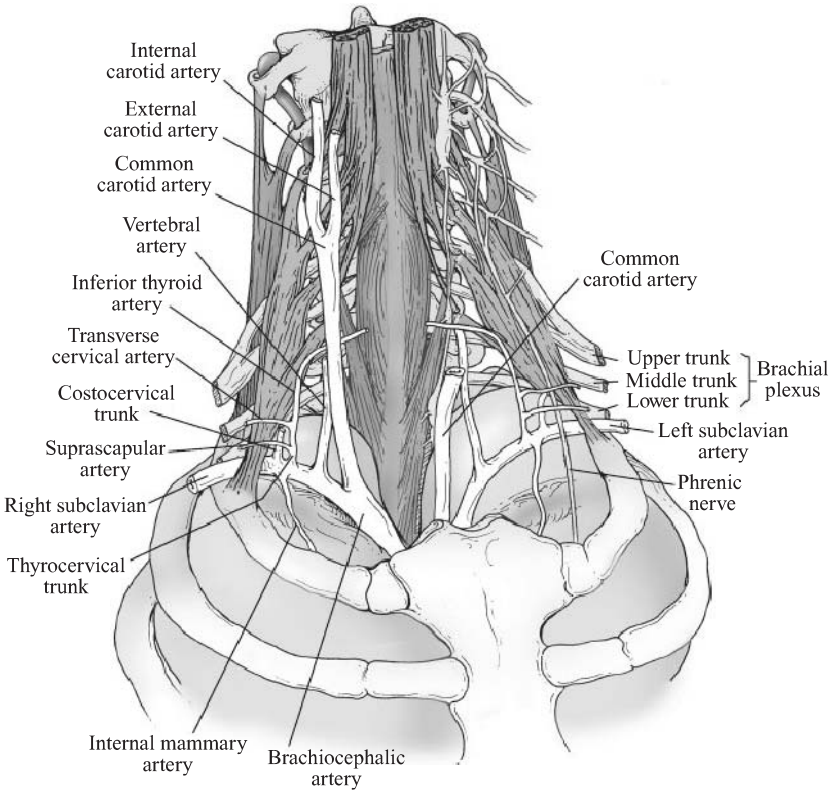

Structures of the Neck. Branches of the aortic arch. Reprinted with permission from: Ruhalter A. Anatomy of the head and neck. In: Fischer JF, Jones DB, Pomposelli FB, Upchurch GR, eds. *Mastery of Surgery*. 6th ed. Philadelphia, PA: Lippincott Williams & Wilkins; 2012:276.

۰۲۱-۶۶۱۹۸۵۱۴ www.myuptodate.com دریافت آخرین نسخه آپتودیت آفلاین

2C16

Key word: Anatomy of Thoracic Duct Drainage

Author: Clinton D. Kemp, MD
Editor: Stephen C. Yang, MD, FACS, FCCP

A 65-year-old male undergoes transhiatal esophagectomy for adenocarcinoma of the distal esophagus. Chest radiograph on postoperative day 5 is notable for a right-sided effusion, which is drained and found to have elevated levels of triglycerides, consistent with a chylothorax. Where is the most common location for termination of the thoracic duct?

(A) Directly into the superior vena cava

(B) Into the confluence of the left internal jugular and subclavian veins

(C) Into the confluence of the right internal jugular and subclavian veins

(D) Into the cisterna chyli

(E) Into the main portal vein

Answer: (B) Into the confluence of the left internal jugular and subclavian veins

Rationale:

The role of the thoracic duct is to collect lymphatic fluid from the body and to return it to the systemic venous circulation. This system drains the entire body except the right face, neck, arm, and hemithorax, which are drained through the right lymphatic duct.

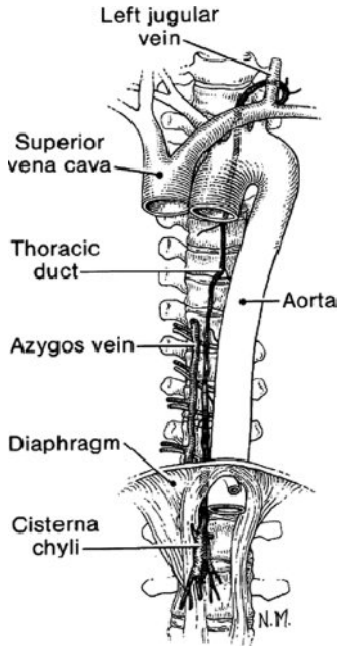

Usual anatomic pattern of the thoracic duct. Reprinted with permission from: Johnstone DW. Anatomy of the thoracic duct and chylothorax. In: Shields TW, Locicero J, Reed CE, Feins RH, eds. *General Thoracic Surgery*. 7th ed. Philadelphia, PA: Lippincott Williams & Wilkins. 2009:827–833.

The thoracic duct arises in the embryo from the venous system and begins as connections between the cisterna chyli inferiorly and bilateral jugular lymphatic sacs superiorly that then fuse to become a common thoracic duct. Although anatomic variations can occur up to 50% of the time, the most common course of the thoracic duct is outlined in the figure below. The cisterna chyli forms as a confluence of lymphatics below the diaphragm and gives rise to the thoracic duct, which passes through the diaphragmatic hiatus along with the aorta at the level of the 12th thoracic vertebra. The thoracic duct travels in the right hemithorax posterior to the esophagus between the azygous vein and the aorta before crossing the midline to the left at approximately the level of the fifth or sixth thoracic vertebrae. It then ascends posterior to the arch of the aorta where it traverses the thoracic inlet to the left of the esophagus and terminates in the posterior confluence of the left internal jugular and subclavian veins to enter the systemic venous circulation.

The thoracic duct is vulnerable to injury anywhere along its course and disruption can lead to chylous ascites in the abdomen or chylothorax in the chest. Specific operations where the thoracic duct is at risk for injury include retroperitoneal lymphadenectomy, abdominal sympathectomy, esophagectomy, thoracic aortic aneurysm repair, pulmonary resections, left-sided lymph node excisions, and radical neck dissections.

Reference:

Johnstone DW. Anatomy of the thoracic duct and chylothorax. In: Shields TW, Locicero J, Reed CE, Feins RH, eds. *General Thoracic Surgery*. 7th ed. Philadelphia, PA: Lippincott Williams and Wilkins; 2009:827–833.

۰۲۱-۶۶۱۹۸۵۱۴ www.myuptodate.com دریافت آخرین نسخه آپتودیت آفلاین

2C17

Key word: Characteristics of Functional Residual Capacity

Author: Clinton D. Kemp, MD
Editor: Stephen C. Yang, MD, FACS, FCCP

A 65-year-old male patient with a 50 pack-year smoking history undergoes pulmonary function testing for evaluation of chronic obstructive pulmonary disease. His results demonstrate a forced expiratory volume in 1 second (FEV_1)/forced vital capacity (FVC) ratio of less than 70% of predicted and an FEV_1 of less than 50% of predicted. Which of the following is true about functional residual capacity?

(A) It can be measured directly using normal spirometry

(B) It is the sum of expiratory reserve volume and residual volume

(C) It is typically decreased among patients with chronic obstructive pulmonary disease

(D) It is typically increased in patients with idiopathic pulmonary fibrosis

(E) It represents the total lung volume remaining after maximal exhalation

Answer: (B) It is the sum of expiratory reserve volume and residual volume

Rationale:

Pulmonary ventilation can be further characterized by four main volumes and four capacities as shown in a typical pulmonary spirogram.

These definitions can be summarized in the following table.

Parameter	Definition	Approximate Normal Volume (ml)
Tidal Volume (TV)	Volume of air during normal inspiration/expiration	500
Inspiratory Reserve Volume (IRV)	Additional inspired volume with maximal effort beyond TV	3000
Expiratory Reserve Volume (ERV)	Additional expired volume with maximal effort beyond TV	1100
Residual Volume (RV)	Volume of air remaining in lungs after maximal expiration	1200
Inspiratory Capacity (IC)	Maximum total inspired volume TV + IRV	3500
Functional Residual Capacity (FRC)	Volume left after normal expiration ERV + RV	2300
Vital Capacity (VC)	Volume expired with maximal expiration after maximal inspiration TV + ERV + IRV	4600
Total Lung Capacity (TLC)	Volume with maximal inspiration VC + RV	5800

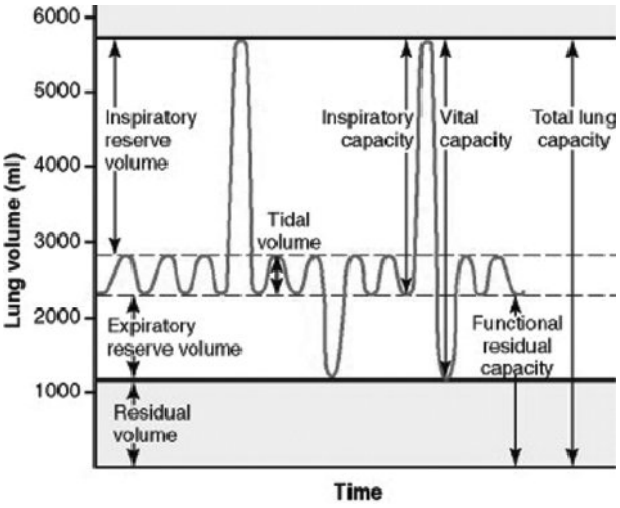

Spirogram demonstrating pulmonary volumes and capacities. Reprinted with permission from: Hall JE. Pulmonary ventilation. In: Hall JE, ed. *Guyton and Hall Textbook of Medical Physiology*. 12th ed. Philadelphia, PA: Saunders Elsevier; 2011:465–476.

FRC must be measured indirectly via methods such as helium oximetry and cannot be directly measured with the usual bedside spirometry. FRC is typically increased among patients with obstructive diseases such as chronic obstructive pulmonary disease and decreased among those with restrictive diseases such as idiopathic pulmonary fibrosis.

Reference:

Hall JE. Pulmonary ventilation. In: Hall JE, ed. *Guyton and Hall Textbook of Medical Physiology.* 12th ed.. Philadelphia, PA: Saunders Elsevier; 2011:465–476.

۰۲۱-۶۶۱۹۸۵۱۴ www.myuptodate.com دریافت آخرین نسخه آپتودیت آفلاین

2C18

Key word: Characteristics of Left Ventricular Performance

Author: Timothy J. George, MD
Editor: William A. Baumgartner, MD

The relationship of a patient's stroke volume and left ventricular end-diastolic pressure is depicted below. If a patient's current status is depicted by point A, a bolus of fluid will cause which of the following changes?

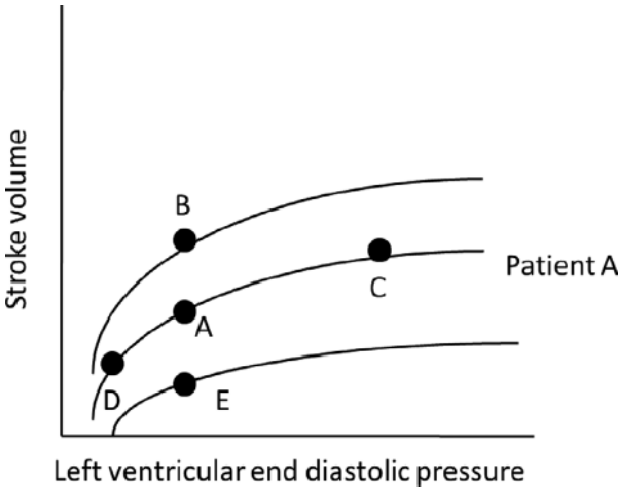

(A) From A to B
(B) From A to C
(C) From A to D
(D) From A to E
(E) No change

Answer: (B) From A to C

Rationale:
The graph depicting the relationship between left ventricular end-diastolic pressure and stroke volume is known as the Frank–Starling relationship. Stroke volume has three main determinants: Preload (in this case left ventricular end-diastolic pressure), afterload, and contractility. The question focuses on changing preload by administering fluid. The Frank–Starling relationship says that as muscular stretch at rest increases, the force of the resulting contraction increases. As a patient's left ventricular end-diastolic pressure (or stretch) increases, the stroke volume (or contraction) increases. The heart's filling pressure, or end-diastolic pressure, is largely determined by a patient's fluid status. Increasing a patient's total vascular volume will increase the left ventricular end-diastolic pressure and move the patient to the right on the same curve. Thus a fluid bolus will result in a move from A to C.

Stroke volume can also be affected by changing contractility. Increasing contractility, for example, by adding inotropic support, will shift a patient's curve without changing their left ventricular end-diastolic pressure. This would result in a move from A to B. Decreasing contractility, for example, after a myocardial infarction, will shift a patient's curve downward without changing their left ventricular end-diastolic volume. This would result in a move from A to E.

Decreasing vascular volume, for example, by diuresis, will decrease preload by decreasing left ventricular end-diastolic pressure without changing contractility, resulting in a change from A to D.

Reference:
Francis GS, Tang WHW, Walsh RA. Pathophysiology of heart failure. In: Fuster V, Walsh RA, Harrington RA, eds. *Hurst's The Heart.* 13th ed. New York, NY: McGraw-Hill; 2011:719–738.

۰۲۱-۶۶۱۹۸۵۱۴ www.myuptodate.com دریافت آخرین نسخه آپتودیت آفلاین

2C19

Key word: Characteristics of Primary Pulmonary Hypertension

Author: Timothy J. George, MD
Editor: William A. Baumgartner, MD

A 47-year-old female presents with increasing dyspnea on exertion. Chest x-ray is normal, and echocardiography reveals normal left ventricular function but a hypertrophied right ventricle with paradoxical systolic septal motion and significant tricuspid regurgitation. Right heart catheterization reveals a mean pulmonary artery pressure of 30 mm Hg and a pulmonary capillary wedge pressure of 10 mm Hg. Which of the following diagnoses is most likely?

(A) Chronic bronchitis

(B) Chronic obstructive pulmonary disease

(C) Idiopathic pulmonary arterial hypertension

(D) Left ventricular diastolic dysfunction

(E) Mitral stenosis

Answer: (C) Idiopathic pulmonary arterial hypertension

Rationale:

Pulmonary hypertension has recently been reclassified into groups. Group 1 includes pulmonary arterial hypertension including idiopathic pulmonary arterial hypertension, also known as primary pulmonary hypertension. Group 2 includes pulmonary hypertension secondary to left-sided heart disease including valvular disease. Group 3 includes pulmonary hypertension due to lung disease and/or hypoxemia. Group 4 includes pulmonary hypertension due to thrombotic or embolic disease. Group 5 includes miscellaneous etiologies (e.g., histiocytosis X).

Dyspnea on exertion is a common presentation of all forms of pulmonary hypertension secondary to an inability to increase cardiac output with exercise due to right heart failure. Radiography can be normal. Echocardiography can be helpful in demonstrating elevated pulmonary pressures, resultant tricuspid regurgitation, signs of right ventricular pressure overload, and paradoxical septal movement. Perhaps more importantly, echocardiography helps rule out other cardiac problems and can help distinguish group 2 diagnoses of pulmonary hypertension from group 1. Right heart catheterization is diagnostic of pulmonary hypertension. Pulmonary hypertension is defined as a mean pulmonary artery pressure >25 mm Hg and/or mean pulmonary artery pressure >30 mm Hg with exercise. Right heart catheterization can help rule out the left heart being the cause of pulmonary hypertension when it demonstrates a normal pulmonary capillary wedge pressure (4–12 mm Hg).

Idiopathic pulmonary arterial hypertension is ultimately a diagnosis of exclusion; thus other causes must first be ruled out. In this vignette, however, the absence of left heart findings on echocardiography and normal pulmonary artery wedge pressure make mitral stenosis and left ventricular diastolic dysfunction unlikely. The normal chest x-ray makes chronic obstructive pulmonary disease and chronic bronchitis unlikely. This leaves idiopathic pulmonary arterial hypertension as the best choice.

Reference:

Simonneau G, Robbins IM, Beghetti M, et al. Updated clinical classification of pulmonary hypertension. *J Am Coll Cardiol.* 2009;54(1 Suppl):S43–S54.

۰۲۱-۶۶۱۹۸۵۱۴ www.myuptodate.com دریافت آخرین نسخه آپتودیت آفلاین

2C20

Key word: Characteristics of Oncotic Pressure in Pulmonary Circulation

Author: Clinton D. Kemp, MD
Editor: Glenn J.R. Whitman, MD

A 75-year-old woman with known congestive heart failure undergoes an elective low anterior resection for adenocarcinoma of the colon. On postoperative day 3 she develops hypoxia from cardiogenic pulmonary edema and is treated with intravenous furosemide. Which of the following correctly describes the physiology of the pulmonary capillary circulation and pulmonary interstitium?

(A) In cardiogenic pulmonary edema there is an increase in the net flow of fluid from the pulmonary interstitium into the pulmonary capillaries

(B) In pneumonia there is a decrease in the net flow of fluid from the pulmonary capillaries into the pulmonary interstitium

(C) In the normal lung there is a net movement of fluid from the pulmonary capillaries into the pulmonary interstitium

(D) In the normal lung there is a net movement of fluid from the pulmonary interstitium into the pulmonary capillaries

(E) In the normal lung there is no net movement of fluid between the capillaries and the pulmonary interstitium

Answer: (C) In the normal lung there is a net movement of fluid from the pulmonary capillaries into the pulmonary interstitium

Rationale:

Deoxygenated blood is pumped from the right ventricle through the pulmonary arteries to the pulmonary capillary bed where alveolar gas exchange occurs. In addition to diffusion of carbon dioxide into the alveoli and oxygen into the capillaries, there are characteristic movements of fluid that occur in this location that can be defined by the various pressure gradients that exist in the pulmonary capillaries and interstitium (see figure).

The forces causing movement of fluid from the pulmonary capillaries into the pulmonary interstitium are a positive hydrostatic pressure of the capillaries (7 mm Hg), a negative interstitial fluid colloid oncotic pressure (14 mm Hg), and a negative interstitial fluid pressure (8 mm Hg), with a net sum of 29 mm Hg. The force causing movement of fluid from the interstitium into the capillaries is the plasma oncotic pressure (28 mm Hg).

With a sum of 29 mm Hg causing movement of fluid from the capillaries into the interstitium and 28 mm Hg causing movement of fluid from the interstitium into the capillaries, there is a net force of 1 mm Hg, the mean filtration pressure, that causes a net movement of fluid from the pulmonary capillaries into the pulmonary interstitium.

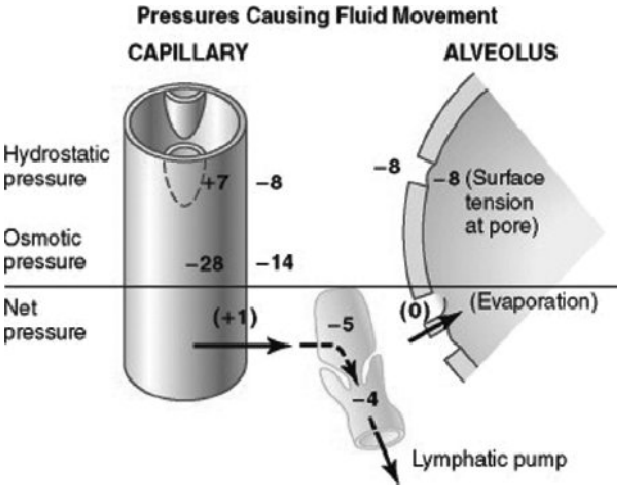

Normal physiology of the pulmonary capillaries and interstitium. Reprinted with permission from: Hall JE. Pulmonary circulation, pulmonary edema, pleural fluid. In: Hall JE, ed. *Guyton and Hall Textbook of Medical Physiology*. 12th ed. Philadelphia, PA: Saunders Elsevier; 2010:477–484.

Under normal circumstances, the fluid that moves into the pulmonary interstitium is drained by the pulmonary lymphatic system, keeping the alveoli dry and preventing pulmonary edema. In circumstances such as cardiogenic pulmonary edema, plasma hydrostatic pressure increases, causing an increase in the mean filtration pressure and leading to an increase in fluid that overwhelms the drainage capability of the pulmonary lymphatics, causing fluid accumulation in the alveoli. In conditions such as pneumonia, damage to the pulmonary capillaries causes leakage of both proteins and fluid into the interstitial space, causing an increase in the movement of fluid from the capillaries into the interstitium.

Reference:

Hall JE. Pulmonary circulation, pulmonary edema, pleural fluid. In: Hall JE , ed. *Guyton and Hall Textbook of Medical Physiology.* 12th ed. Philadelphia, PA: Saunders Elsevier; 2010:477–484.

۰۲۱-۶۶۱۹۸۵۱۴ www.myuptodate.com دریافت آخرین نسخه آپتودیت آفلاین

2C21

Key word: Conditions Associated with Persistent Fetal Circulation

Author: Timothy J. George, MD
Editor: William A. Baumgartner, MD

A newborn infant has persistent cyanosis on day of life 5. Echocardiography reveals d-transposition of the great arteries. Which of the following associated defects will help the child compensate until definitive repair can be completed?

(A) Abnormal coronary anatomy

(B) An atrial septal defect

(C) Coarctation of the aorta

(D) Pulmonary atresia

(E) Tricuspid insufficiency

Answer: **(B)** An atrial septal defect

Rationale:

Transposition of the great arteries (TGA) is a congenital anomaly in which the aorta arises from the right ventricle and the pulmonary artery arises from the left ventricle. Thus the right ventricle pumps deoxygenated blood through the aorta to the body, which then returns to the right atrium and the right ventricle without being oxygenated by the lungs. The left ventricle pumps deoxygenated blood through the pulmonary arteries to the lungs, which return oxygenated blood to the left atrium and left ventricle. This anatomy effectively creates two separate circuits and in the absence of persistent fetal circulation, the newborn will not be able to deliver oxygenated blood to the systemic circulation.

In utero, the fetus receives oxygenated blood from the mother. This blood enters the right atrium and most of the blood passes through the patent foramen ovale to the left atrium, after which it is pumped to the systemic circulation. Pulmonary vascular resistance is high in the fetus; thus a limited amount of blood is pumped from the right ventricle to the pulmonary artery. Because of the high resistance of the pulmonary vascular bed, most of the blood that enters the pulmonary artery is shunted into the lower resistance systemic circulation via the ductus arteriosus that connects the pulmonary artery to the aorta. At birth, systemic vascular resistance rises and pulmonary vascular resistance falls, resulting in closure of the ductus arteriosus and the foramen ovale. Gradually, the infant shifts to normal adult circulation.

In TGA, if the fetal circulation does not mix, blood in the systemic circulation will not be oxygenated, and the patient will die. Fortunately, many of these infants have associated cardiac defects. A persistent atrial septal defect or patent ductus arteriosus will allow mixing of the systemic and pulmonary circulation until an arterial switch operation can be performed. Ventricular septal defects also allow for some mixing, though this tends to be less efficient. Similarly, persistent fetal circulation also allows mixing of systemic and pulmonary circulation in other types of congenital defects including tetralogy of Fallot, truncus arteriosus, and total anomalous pulmonary venous return.

All the other listed anomalies can be associated with TGA; however, none of them will help with oxygenation.

Reference:

Pigula FA, del Nido PJ. Transposition of the great arteries: Simple and complex forms. In: Selke FW, del Nido PJ, Swanson SJ, eds. *Sabiston and Spencer Surgery of the Chest.* 8th ed. Philadelphia, PA: Saunders; 2010:1952–1981.

۰۲۱-۶۶۱۹۸۵۱۴ www.myuptodate.com دریافت آخرین نسخه آپتودیت آفلاین

2C22

Key word: Definition of Vital Capacity

Author: Clinton D. Kemp, MD
Editor: Stephen C. Yang, MD, FACS, FCCP

A 45-year-old woman with idiopathic pulmonary fibrosis is referred to you for evaluation for lung transplantation. She describes progressive dyspnea and says that even with minimal exertion she now finds herself breathing by inspiring as much as she can and expiring to her fullest extent. Which pulmonary volume is she describing with her abnormal breathing pattern?

(A) Expiratory reserve volume

(B) Inspiratory reserve volume

(C) Residual volume

(D) Total lung capacity

(E) Vital capacity (VC)

Answer: (E) Vital capacity (VC)

Rationale:
Idiopathic pulmonary fibrosis is a restrictive lung disease characterized by a reduction in pulmonary compliance and therefore overall lung volumes. Patients may compensate for these reduced volumes by increasing the frequency or the volume of each breath. VC refers to the volume in the lungs that is expired with maximal effort following maximal inspiration and represents the maximum volume of ventilation.

See table in rationale for question 2C17 for definitions of pulmonary function measurements.

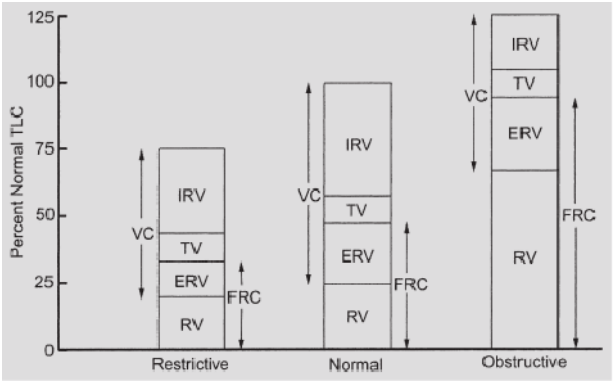

Relative changes in lung volumes associated with lung diseases. Reprinted with permission from: Ferguson MK. Pulmonary physiologic assessment of operative risk. In: Shields TW, LoCicero J, Reed CE, Feins RH, eds. *General Thoracic Surgery*. 7th ed. Philadelphia, PA: Lippincott Williams & Wilkins; 2009:328.

References:

Hall JE. Pulmonary ventilation. In: Hall JE, ed. *Guyton and Hall Textbook of Medical Physiology,* 12th ed. Philadelphia, PA: Saunders Elsevier; 2011:465–476.

Levitsky MG, ed. Alveolar ventilation. *Pulmonary Physiology.* 7th ed. New York, NY: McGraw Hill; 2007:54–84.

2C23

Key word: Effect of Inhaled Nitric Oxide in Acute Respiratory Distress Syndrome Treatment

Author: Joshua C. Grimm, MD
Editor: Glenn J.R. Whitman, MD

A 24-year-old female is involved in an automobile accident. She has bilateral femoral fractures, a flail chest with pulmonary contusions, and solid organ injuries. She is stabilized in the intensive care unit, but her clinical course deteriorates after several days. She exhibits labored breathing, episodes of hypotension, and an increase in her creatinine from baseline. A chest radiograph reveals bilateral pulmonary infiltrates. The results of her arterial blood gas are as follows:

pH 7.38, $PaCO_2$ 30 mm Hg, PaO_2 56 mm Hg, HCO_3^- 12 mEq/L, FiO_2 50%

Administration of inhaled nitric oxide is begun. Which of the following is true of this therapy?

(A) Due to vasodilation, pulmonary blood is redistributed to nonventilated regions

(B) In addition to pulmonary vasodilation, nitric oxide causes a concomitant decrease in systemic vascular resistance

(C) Inhaled nitric oxide therapy has minimal effects on the PaO_2:FiO_2 in the initial phase of treatment

(D) Several large, randomized controlled trials have failed to show a survival benefit in patients with acute respiratory distress syndrome (ARDS) who were treated with inhaled nitric oxide

(E) When the treatment is effective, there is an increase in the pulmonary right-to-left shunt

Answer: (D) Several large, randomized controlled trials have failed to show a survival benefit in patients with acute respiratory distress syndrome (ARDS) who were treated with inhaled nitric oxide

Rationale:
ARDS is a complication of several pathologic processes, including trauma, pneumonia, and septic shock to name just a few. Typically, ARDS presents within a week after the original insult and manifests as hypotension, end-organ failure, labored breathing, and generalized respiratory failure. Several criteria have been established as sensitive indicators of ARDS: Acute onset (within 1 week of known cause), bilateral pulmonary infiltrates on chest radiograph, and measurement of the PaO_2:FiO_2 ratio, which define the condition as mild (PaO_2:FiO_2 ratio 200 to 300 with positive end-expiratory pressure [PEEP] or CPAP ≥5 cm H_2O), moderate (PaO_2:FiO_2 ratio 100 to 200 with PEEP ≥5 cm H_2O), or severe (PaO_2:FiO_2 ratio <100 with PEEP ≥5 cm H_2O). When a cause has not been identified, echocardiography should be obtained to rule out cardiogenic causes of the pulmonary infiltrates.

۰۲۱-۶۶۱۹۸۵۱۴ www.myuptodate.com دریافت آخرین نسخه آپتودیت آفلاین

Treatment strategies of ARDS have taken many forms. It is now generally accepted that lung protective strategies (permissive hypercapnia, lower peak and driving pressures, higher PEEP, and tidal volume less than 6 mL/kg of ideal body weight) minimize the deleterious effects of mechanical ventilation on the pulmonary parenchyma. Inhaled nitric oxide use is more controversial, and no convincing data exist on its overall effects on morbidity or mortality.

Inhaled nitric oxide results in vessel dilation via its effects on cGMP. This regional, and not systemic, vasodilation results in redistribution of blood from nonventilated to ventilated regions of the lung and, accordingly, a decrease in the pulmonary right-to-left shunt and a resulting increase in PaO_2. While these physiologic effects are promising, several large randomized trials have shown no benefit in mortality reduction when using inhaled nitric oxide.

References:

Amato MB, Barbas CS, Medeiros DM, et al. Effect of a protective-ventilation strategy on mortality in the acute respiratory distress syndrome. *N Engl J Med.* 1998;338:347–354.

ARDS Definition Task Force, Ranieri VM, Rubenfeld GD, et al. Acute respiratory distress syndrome: the Berlin Definition. *JAMA.* 2012;307(23):2526–2533.

Dellinger RP, Zimmerman JL, Taylor RW, et al. Effects of inhaled nitric oxide in patients with acute respiratory distress syndrome: Results of a randomized phase II trial. *Crit Care Med.* 1998;26:15–23.

Lundin S, Mang H, Smithies M, et al. Inhalation of nitric oxide in acute lung injury: Results of a European multicenter study. *Intensive Care Med.* 1999;25:911–919.

Rossaint R, Gerlach H, Schmidt-Ruhnke H, et al. Efficacy of inhaled nitric oxide in patients with severe ARDS. *Chest.* 1995;107:1107–1115.

2C24

Key word: Etiology of Hand Ischemia Following Arteriovenous Fistula Placement

Author: Babak J. Orandi, MD, MSc
Editor: Ying Wei Lum, MD

A 62-year-old right-handed woman with end-stage renal disease secondary to diabetes mellitus and hypertension has a history of multiple failed left upper extremity vascular access sites. She is 9 months out from a right upper extremity brachiocephalic arteriovenous fistula (AVF). Over the past month, she has developed right hand pain with activity that has now progressed to rest pain. In addition, she has an ischemic ulcer on the tip of her index finger. The most appropriate treatment is:

(A) Banding of the venous limb of the fistula

(B) Ligation of the fistula and placement of a tunneled hemodialysis access catheter

(C) Mechanical thrombolysis

(D) Performing a bypass of the fistula and ligating the brachial artery distal to the fistula

(E) Prescribing an arm exercise regimen to improve collateral circulation

Answer: (D) Performing a bypass of the fistula and ligating the brachial artery distal to the fistula

Rationale:

Ischemic steal syndrome (ISS) is a relatively rare complication of arteriovenous access surgery that occurs when the majority of antegrade arterial flow is distributed through the venous limb of the AVF, causing inadequate distal arterial flow and an ischemic state in the tissues distal to the AVF. While some degree of physiologic steal is common, symptoms of ISS include hand pain during dialysis sessions, rest pain, neurologic dysfunction, and/or tissue loss.

The best treatment for ISS is the distal revascularization–interval ligation (DRIL) procedure, which entails performing a bypass using either autologous vein or synthetic graft material from the artery proximal to the fistula to an area on the artery distal to the fistula with ligation of the artery just distal to the origin of the fistula (see figure). This procedure allows revascularization of the extremity while preserving arteriovenous access. In a large retrospective series, Knox et al. reported symptom alleviation in 90% of patients undergoing the DRIL procedure, with a primary patency rate of the DRIL procedure of 86% at 12 months.

Banding has been proposed as a treatment for ISS by increasing the resistance of flow across the fistula, thereby allowing more blood flow to the distal extremity. However, this approach is associated with a high rate of graft thrombosis and a significantly lower patency rate at 12 months. Ligation of the fistula would relieve this woman's symptoms, but she would then lose this site as a location for arteriovenous access, making this a less favorable option that should only be pursued as a last resort if the DRIL procedure fails. While

۰۲۱-۶۶۱۹۸۵۱۴ www.myuptodate.com دریافت آخرین نسخه آپتودیت آفلاین

exercise may promote the development of collateral blood flow, it is not an effective treatment for ISS and will not occur quickly enough to prevent further tissue loss. Graft thrombosis is a much more common complication of arteriovenous access surgery and can be treated with mechanical thrombolysis; however, the situation above describes ISS.

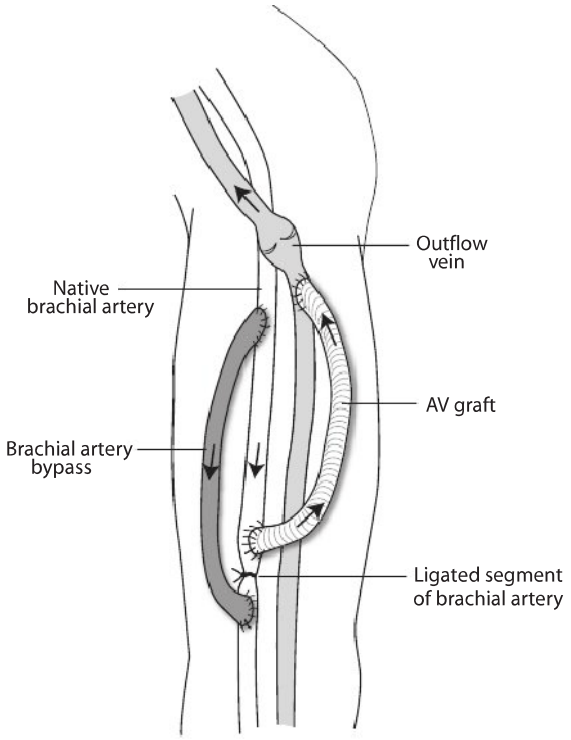

The distal revascularization–interval ligation (DRIL) procedure can be used to treat ischemic steal, which occurs with an incidence of about 5% with vascular access procedures. In the upper extremity, a brachial–brachial bypass is constructed to restore blood flow to the hand, and the segment of brachial artery between the distal bypass anastomosis and the distal access anastomosis is ligated to prevent steal. Long-term patency of the DRIL is 80% to 90%. Reprinted with permission from: Rasmussen TE, Clouse WD, Tonnessen BH. Hemodialysis access. *Handbook of Patient Care in Vascular Diseases*. 5th ed. Philadelphia, PA: Lippincott Williams & Wilkins; 2008:346.

References:

Knox RC, Berman SS, Hughes JD, et al. Distal revascularization–interval ligation: A durable and effective treatment for ischemic steal syndrome after hemodialysis access. *J Vasc Surg.* 2002;36:250–256.

Odland MD, Kelly PH, Ney AL, et al. Management of dialysis-associated steal syndrome complicating upper extremity arteriovenous fistulas: use of intraoperative digital photoplethysmography. *Surgery.* 1991;110:664–669.

2C25

Key word: Hemodynamic Effects of Tension Pneumothorax

Author: Clinton D. Kemp, MD
Editor: Stephen C. Yang, MD, FACS, FCCP

A 25-year-old male is brought to the emergency department after being stabbed in the left chest. His airway is intact, but his breathing is rapid and shallow. He is tachycardic to 120 beats per minute and hypotensive to 80/40 mm Hg. Left breath sounds are absent. Emergent placement of a left thoracostomy tube is met with a rush of air, and his vital signs improve to a heart rate of 90 beats per minute and blood pressure of 120/70 mm Hg. Which of the following best explains the pathophysiology responsible for these hemodynamic changes?

(A) Constriction of the ventricles by hemopericardium

(B) Decreased delivery of oxygen to the myocardium

(C) Decreased systemic venous return from compression of the vena cava

(D) Increased sympathetic nervous system activity

(E) Massive hemorrhage during transport

Answer: (C) Decreased systemic venous return from compression of the vena cava

Rationale:

Tension pneumothorax describes the clinical scenario in which pneumothorax leads to hemodynamic compromise. Entry into the pleural space creates a pneumothorax, and the entry wound can act like a one-way valve, allowing air into the chest but not out. With each successive breath, more air enters the lung, eventually causing ipsilateral pulmonary collapse and a contralateral shift of the mediastinum. This shift can cause distortion and compression of the superior and inferior vena cava leading to decreased systemic venous return and decreased cardiac output, leading to tachycardia and hypotension.

Tension pneumothorax is a clinical, not radiologic, diagnosis. This injury can be rapidly fatal if not promptly recognized and treated. Treatment involves immediate decompression with tube thoracostomy, or if not immediately available, needle decompression of the ipsilateral hemithorax by placement of an intravenous catheter in the second intercostal space in the midclavicular line, followed by definitive placement of a tube thoracostomy.

Reference:

Livingston DH, Hauser CJ. Chest wall and lung. In: Feliciano DV, Mattox KL, Moore EE, eds. *Trauma.* 6th ed. New York, NY: McGraw Hill Professional; 2007:525–552.

۰۲۱-۶۶۱۹۸۵۱۴ www.myuptodate.com دریافت آخرین نسخه آپتودیت آفلاین

2C26

Key word: Response to Alveolar Hypoxia

Author: Clinton D. Kemp, MD
Editor: Glenn J.R. Whitman, MD

A 65-year-old female who underwent a low anterior resection 1 day prior develops hypoxia with oxygen saturations of 88% on room air. A chest x-ray is obtained which shows bibasilar atelectasis, and you explain to the patient that she needs to use her incentive spirometer to fully expand the inferior portions of her lungs to avoid alveolar collapse and hypoxia. She complies, and with pulmonary toilet, her oxygen saturations return to normal levels. What is the normal physiologic response to alveolar hypoxia?

(A) Decreased pulmonary arterial blood flow to the affected alveoli

(B) Increase in overall respiratory rate

(C) Increase in the volume of an inspired breath

(D) Increased oxygen absorption from the affected alveoli

(E) Increased pulmonary arterial blood flow to the affected alveoli

Answer: (A) Decreased pulmonary arterial blood flow to the affected alveoli

Rationale:
Blood flows from branches of the pulmonary artery to the alveoli where oxygen and carbon dioxide exchange occur in the pulmonary capillary bed. Oxygenated blood then flows back through branches of the pulmonary veins to the left heart where it is distributed to the systemic circulation.

When alveoli are not adequately ventilated (e.g., with atelectasis), the concentration of oxygen in the affected alveoli falls to below normal levels. When this drop reaches a critical level (typically below 70% of normal or less than 73 mm Hg), the surrounding pulmonary arteries constrict, which increases pulmonary vascular resistance to the affected pulmonary segment, effectively diverting blood flow from an underventilated segment with low oxygen concentrations to other better ventilated segments with higher oxygen concentrations.

Reference:
Hall JE. Pulmonary circulation, pulmonary edema, pleural fluid. In: Hall JE, ed. *Guyton and Hall Textbook of Medical Physiology.* 12th ed. Philadelphia, PA: Saunders Elsevier; 2010:477–484.

2C27

Key word: Normal Cardiac Physiology in Infants

Author: Timothy J. George, MD
Editor: William A. Baumgartner, MD

As a normal newborn transitions from intrauterine to extrauterine life, which of the following occurs?

(A) A contraction of lung volume

(B) A decrease in pulmonary blood flow

(C) A decrease in pulmonary vascular resistance

(D) A decrease in systemic vascular resistance

(E) An increase in pulmonary vascular resistance

Answer: (C) A decrease in pulmonary vascular resistance

Rationale:
In a normal fetus, oxygenated blood is delivered to the fetus from the mother via the placenta. This blood enters the right atrium, and most of the blood then passes through the patent foramen ovale to the left atrium. The blood is then pumped from the left heart to the systemic circulation. Because the lungs are filled with fluid, pulmonary vascular resistance is high in the fetus. Therefore, a limited amount of blood is pumped from the right ventricle to the pulmonary artery. Most of the blood that enters the pulmonary artery is shunted into the lower resistance systemic circulation via the ductus arteriosus that connects the pulmonary artery to the aorta.

At birth, when the umbilical cord is clamped, the low vascular resistance of the placental circulation is removed from the systemic vascular bed, increasing overall systemic vascular resistance. As the newborn takes its first breath, fluid is expelled from the lungs, the lungs expand, and pulmonary vascular resistance is decreased. These changes result in increased blood flow through the pulmonary arteries and the lungs, thereby increasing neonatal oxygen saturation, which then stimulates closure of the ductus arteriosus. In addition, as left atrial pressure increases and right atrial pressure falls, right-to-left shunting of blood through the foramen ovale decreases, resulting in its closure.

Reference:
Brown DW, Fulton DR. Congenital heart disease in children and adolescents. In: Fuster V, Walsh RA, Harrington RA, eds. *Hurst's The Heart.* 13th ed. Columbus, OH: McGraw-Hill; 2011.

۰۲۱-۶۶۱۹۸۵۱۴ www.myuptodate.com دریافت آخرین نسخه آپتودیت آفلاین

دریافت آخرین نسخه آپتودیت آفلاین www.myuptodate.com ۰۲۱-۶۶۱۹۸۵۱۴

4
MISCELLANEOUS (GENITOURINARY, HEAD AND NECK, SKIN, MUSCLE, AND NERVOUS SYSTEM)

CONTENTS:

Number:	Key Word:	Page:
2M01	Characteristics of Malignant Transformation of Nevi	446
2M02	Complication of Late Reduction of Posterior Hip Dislocation	447
2M03	Concomitant Injury with Bilateral Calcaneal Fractures	447
2M04	Diagnostic Findings of Digital Paresthesias	449
2M05	Diagnosis of Paralysis of the Common Peroneal Nerve	449
2M06	Diagnostic Testing of a Testicular Mass	450
2M07	Ethical Issues in Injury Prevention	450
2M08	Etiology of Secondary Traumatic Brain Injury	451
2M09	Etiology of Bleeding Pelvic Fractures	452
2M10	Findings with Temporal Bone Fractures	453
2M11	Fracture Associated with Major Vascular Compromise	454
2M12	Human Factors in Injury Prevention	454
2M13	Ineffective Injury Prevention Strategy	455
2M14	Most Important Measure in Injury Outcome	455
2M15	Treatment of Compression Fractures at the Thoracolumbar Junction	456
2M16	Treatment of Depressed Skull Fracture	457
2M17	Diagnosis of Ectopic Pregnancy	458
2M18	Treatment of Head Injury with Hypotension	459
2M19	Treatment of Ovarian Cysts	459
2M20	Diagnosis of Pelvic Inflammatory Disease/Tubo-ovarian Abscess	460
2M21	Treatment of Recurrent Laryngeal Nerve Injury	461
2M22	Treatment of Testicular Torsion	462
2M23	Treatment of Tracheoinnominate Fistula	462
2M24	Treatment of Warthin Tumor	464
2M25	Treatment of Thrombosed Ovarian Vein	464
2M26	Treatment of Penile Cancer	465
2M27	Clinical Features of Pituitary Tumors	465
2M28	Treatment of Tongue Cancer	467
2M29	Repair of Extraperitoneal Bladder Rupture	468
2M30	Treatment of Postoperative Parotitis	468
2M31	Significance of Actinic Keratosis	469
2M32	Urinary Stones after Ileal Resection	470
2M33	Urine Concentrations with Aldosterone-secreting Tumors	471
2M34	Antihypertensive Drug Associated with Chronic Cough	472

۰۲۱-۶۶۱۹۸۵۱۴ www.myuptodate.com دریافت آخرین نسخه آپتودیت آفلاین

2M01

Key word: Characteristics of Malignant Transformation of Nevi

Author: Joshua C. Grimm, MD
Editor: Lisa K. Jacobs, MD

A 39-year-old female has been followed regularly by her dermatologist for a mole located on her left shoulder. Due to a family history of melanoma and her fair complexion, she is concerned that this nevus might eventually progress to malignant disease. Which of the following is true concerning the malignant transformation from melanocytic nevus to frank melanoma?

(A) Abnormal adhesion receptors make cells resistant to the typical progression from nevus to melanoma

(B) All melanocytic nevi that change shape, color, or size are considered malignant

(C) All melanomas arise from pre-existing nevi

(D) Melanocytic nevi are not considered direct precursor lesions to melanoma

(E) The BRAF mutation is found in a majority of patients with melanoma and nevi

Answer: **(E)** The BRAF mutation is found in a majority of patients with melanoma and nevi

Rationale:

The incidence of melanoma has risen in the past several decades. Screening consists of regular physical examinations, especially in those patients who have identifiable risk factors for and precursors to melanoma, such as melanocytic nevi. These lesions should be followed with regard to symmetry, border, color, size, and evolution over time, which may indicate that malignant transformation has occurred. However, it is important to note that histologic evidence, via a punch, incisional, or excisional biopsy, is necessary to diagnose an individual with melanoma.

A number of gene mutations have been identified as proto-oncogenes, which impact an individual's risk of developing cancer. The BRAF gene is significant in melanoma. It codes for the BRAF protein, a protein kinase that modifies intracellular signaling as well as cell proliferation and differentiation. Alterations in these signaling pathways can allow tumor cells to evade the normal cell–cell adhesion controls that prevent melanocyte growth and invasion into surrounding tissues. Thus, a key component of malignant transformation is the expression of abnormal receptors that allow melanocytes to differentiate and expand unchecked.

References:

Li G, Herlyn M. Dynamics of intercellular communication during melanoma development. *Mol Med Today.* 2000;6(4):163–169.

Pollock PM, Harper UL, Hansen KS, et al. High frequency of BRAF mutations in nevi. *Nat Genet.* 2003;33(1):19–20.

Tsao H, Bevona C, Goggins W, et al. The transformation rate of moles (melanocytic nevi) into cutaneous melanoma: A population-based estimate. *Arch Dermatol.* 2003;139(3):282–288.

Zaal LH, Mooi WJ, Klip H, et al. Risk of malignant transformation of congenital melanocytic nevi: A retrospective nationwide study from The Netherlands. *Plast Reconstr Surg.* 2005;116(7):1902–1909.

۰۲۱-۶۶۱۹۸۵۱۴ www.myuptodate.com دریافت آخرین نسخه آپتودیت آفلاین

2M02

Key word: Complication of Late Reduction of Posterior Hip Dislocation

Author: Raja Mohan, MD
Editor: Frank J. Frassica, MD

A 20-year-old man was an unrestrained passenger in a motor vehicle collision. Upon impact, his left leg hit the dashboard and caused a posterior hip dislocation. This was reduced in the emergency department approximately 20 hours after the accident. What is the most likely complication?

(A) Avascular necrosis of femoral head
(B) Femoral head fracture
(C) Heterotopic ossification
(D) Sciatic nerve injury
(E) Shortening of leg

Answer: (A) Avascular necrosis of femoral head

Rationale:
A number of complications can occur with hip dislocations, but the two most common are hip arthritis and avascular necrosis of the femoral head. The risk of these complications increases when reduction of the dislocation is performed late. After reduction, an MRI should be performed to rule out avascular necrosis of the femoral head. The incidence is approximately 15% in patients who had a posterior hip dislocation.

Reference:
McKee MD, Garay ME, Schemitsch EH, et al. Irreducible fracture-dislocation of the hip: A severe injury with a poor prognosis. *J. Orthop Trauma.* 1998;12(4):223–229.

2M03

Key word: Concomitant Injury with Bilateral Calcaneal Fractures

Author: Isaac Howley, MD
Editor: Frank J. Frassica, MD

A 30-year-old male is brought to the emergency room after falling off a second story balcony and landing on both feet before striking his head. He arrives intubated with normal hemodynamic parameters and a Glasgow Coma Scale score of 6T (withdraws to pain). His physical examination reveals bilateral swollen, erythematous heels but is otherwise free of other obvious deformities. In addition to computed tomography (CT) imaging of his head, cervical spine, abdomen, and pelvis, and x-rays of his chest and bilateral feet, what other plain film imaging should be obtained?

(A) Bilateral ankles, thoracic spine, lumbar spine
(B) Bilateral ankles, tibia/fibula, femurs, lumbar spine, thoracic spine
(C) Bilateral ankles, tibia/fibula, femurs, pelvis, lumbar spine
(D) Bilateral ankles, tibia/fibula, femurs, pelvis, thoracic spine
(E) Bilateral ankles, tibia/fibula, lumbar spine

Answer: (C) Bilateral ankles, tibia/fibula, femurs, pelvis, lumbar spine

Rationale:
Calcaneal fractures are relatively rare fractures that typically occur in young patients following motor vehicle collisions or falls from significant height onto the feet. The force of impact is frequently transmitted not only from the ground onto the patient's hindfoot, but also along the vertical axis in an axial load injury pattern. Calcaneal fractures are bilateral or are accompanied by lumbar spine fractures 10% to 15% of the time; anteroposterior and lateral plain films of the lumbar spine should therefore be obtained routinely. Other common accompanying injuries include fractures of the tibial plateau, proximal femur, and pelvis. These bones should be carefully assessed as part of the secondary or tertiary survey in patients who present with calcaneal fractures, and a low threshold should be maintained for obtaining radiographic studies.

Calcaneal fractures involve the subtalar joint approximately 75% of the time. Thin slice (2 to 3 mm) CT imaging is useful in defining the fracture anatomy. When uncorrected, calcaneal fractures may cause permanent and debilitating widening of the heel, making it difficult for patients to wear shoes. Edema can be significant, and compartment syndrome of the foot may occur in 10% of cases, warranting careful monitoring for this complication. Controversy remains as to the relative merits of operative and nonoperative management. Although nonoperative management can cause significant disability, operative management is frequently plagued by complications, especially with wound healing. Patient factors such as smoking, age, and medical

۰۲۱-۶۶۱۹۸۵۱۴ www.myuptodate.com دریافت آخرین نسخه آپتودیت آفلاین

comorbidities play a large role in the risk for operative complications and should be taken into account in treatment decision making.

Patterns of Injury to the Head, Neck, Trunk, and Extremities Associated with Orthopedic Injuries

Diagnosed Injury	Associated Injury
Fracture—temporal, parietal bone	Epidural hematoma
Maxillofacial fracture	Cervical spine fracture
Sternal fracture	Cardiac contusion
First and second rib fracture	Descending thoracic aorta, intra-abdominal bleeding
Fractured scapula	Pulmonary contusion
Fractured ribs 8–12, right	Lacerated liver
Fractured ribs 8–12, left	Lacerated spleen
Fractured pelvis	Ruptured bladder, urethral transection
Fractured humerus	Radial nerve injury
Supracondylar humerus fracture	Brachial artery injury
Distal radius fracture	Median nerve compression
Supracondylar femur fracture	Popliteal artery thrombosis
Anterior dislocation shoulder	Axillary nerve injury
Posterior dislocation of hip	Sciatic nerve injury
Posterior dislocation of knee	Popliteal artery thrombosis

Reprinted with permission from: Maier RV. Trauma and trauma care: General considerations. In: Mulholland MW, Lillemoe KD, Doherty GM, Maier RV, Upchurch GR, eds. *Greenfield's Surgery: Scientific Principles & Practice*. 5th ed. Philadelphia, PA: Lippincott Williams & Wilkins, 2011:322.

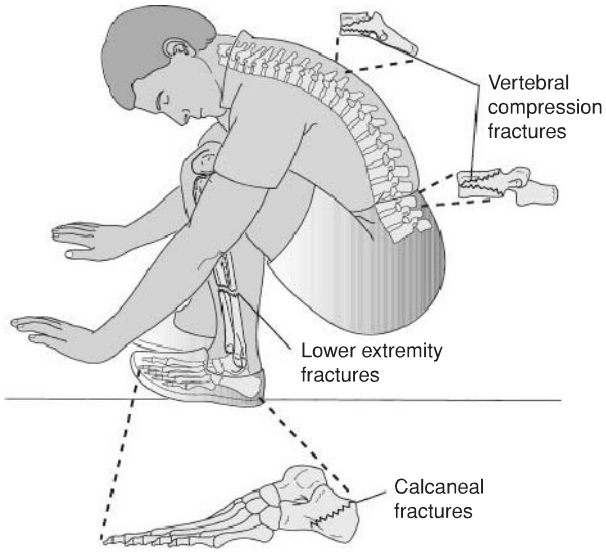

Hyperflexion and axial loading injury after a fall. Reprinted with permission from: Maier RV. Trauma and trauma care: General considerations. In: Mulholland MW, Lillemoe KD, Doherty GM, Maier RV, Upchurch GR, eds. *Greenfield's Surgery: Scientific Principles & Practice*. 5th ed. Philadelphia, PA: Lippincott Williams & Wilkins, 2011:322.

References:

Banerjee R, Nickisch F, Easley ME, et al. Foot injuries. In: Browner BD, Jupiter JB, Levine AM, Trafton PG, Krettek C, eds. *Skeletal Trauma: Basic Science, Management, and Reconstruction.* 4th ed. Philadelphia, PA: W.B. Saunders; 2008:2585–2748.

Maier RV. Trauma and trauma care: General considerations. In: Mulholland MW, Lillemoe KD, Doherty GM, Maier RV, Upchurch GR, eds. *Greenfield's Surgery: Scientific Principles & Practice.* 5th ed. Philadelphia, PA: Lippincott Williams & Wilkins; 2011.

۰۲۱-۶۶۱۹۸۵۱۴ www.myuptodate.com دریافت آخرین نسخه آپتودیت آفلاین

2M04

Key word: Diagnostic Findings of Digital Paresthesias

Author: Raja Mohan, MD
Editor: Frank J. Frassica, MD

A 34-year-old woman presents with pain in her right hand and neck that has been going on for 1 year. She experiences occasional numbness in her arm and hand. She works as a seamstress and reports that her symptoms are worsened when shooting a basketball. What is the most likely diagnosis?

(A) Brachial plexopathy
(B) Carpal tunnel syndrome
(C) Complex regional pain syndrome
(D) Medial epicondylitis
(E) Thoracic outlet syndrome

Answer: (E) Thoracic outlet syndrome

Rationale:
Thoracic outlet syndrome is a condition that can cause impingement or irritation of the subclavian artery, subclavian vein, or brachial plexus. Neurologic findings are the most common symptoms seen in those with symptomatic thoracic outlet syndrome. Neurologic findings can include numbness, tingling, or weakness in the patient's neck, shoulders, or arm. Thoracic outlet syndrome can be caused by a cervical rib, trauma, enlarged scalene muscle, or narrowing between the clavicle and the first rib.

Carpal tunnel syndrome is only confined to the hand, and medial epicondylitis only involves the medial forearm. Any neck or upper arm symptoms rule out these conditions. Brachial plexopathy can cause pain or paresthesia but would not explain why the patient in this vignette has worse symptoms while playing basketball. Patients with thoracic outlet syndrome tend to have exacerbation of symptoms when raising their arms above their head.

Reference:
Brooke BS, Freischlag JA. Contemporary management of thoracic outlet syndrome. *Curr Opin Cardiol.* 2010;25(6):535–540.

2M05

Key word: Diagnosis of Paralysis of the Common Peroneal Nerve

Author: Raja Mohan, MD
Editor: Frank J. Frassica, MD

A 25-year-old man was involved in a motor vehicle accident and suffered a tibial plateau fracture that was splinted in the emergency department. Several days after admission he develops difficulty with dorsiflexion of his foot and also reports numbness and tingling sensations in the injured leg. In which region of the leg would he most likely feel numbness and tingling?

(A) Dorsum of foot
(B) Lateral plantar surface of foot
(C) Medial plantar surface of foot
(D) Over lateral malleolus
(E) Over medial malleolus

Answer: (A) Dorsum of foot

Rationale:
The common peroneal (fibular) nerve gives rise to two branches: The superficial peroneal nerve and the deep peroneal nerve. This nerve can be compressed by a lower extremity splint and begin to cause sensory and motor deficits. The superficial peroneal nerve provides cutaneous sensation to the dorsum of the foot and all digits except the lateral portion of the fifth digit and the first web space. The deep peroneal nerve provides cutaneous sensation to the first web space. On the plantar surface or sole of the foot, the medial and lateral plantar nerves (terminal branches of the tibial nerve) provide cutaneous sensation to the medial and lateral portions of the plantar surface, respectively. The cutoff between these two regions is a line drawn from the middle of the fourth digit of the foot. The saphenous nerve (branch of the femoral nerve) provides cutaneous sensation for the medial malleolus, and the sural nerve for the lateral malleolus.

Injury to the common peroneal nerve also results in difficulty with dorsiflexion—foot drop. The superficial peroneal nerve innervates the muscles of the lateral compartment (peroneus longus, peroneus brevis) of the leg, whereas the deep peroneal nerve innervates the muscles of the anterior compartment (tibialis anterior, extensor hallucis longus, extensor digitorum longus, peroneus tertius) of the leg. The anterior compartment of the leg is responsible for dorsiflexion of the foot, and therefore foot drop can result from peroneal nerve compression.

Reference:
Hansen JT. Lower limb. In: Hansen JT, ed. *Netter's Clinical Anatomy.* 2nd ed. Philadelphia, PA: Saunders Elsevier; 2010:227–291.

۰۲۱-۶۶۱۹۸۵۱۴ www.myuptodate.com دریافت آخرین نسخه آپتودیت آفلاین

2M06

Key word: Diagnostic Testing of a Testicular Mass

Author: Said C. Azoury, MD
Editor: Arthur L. Burnett, MD, MBA, FACS

A 25-year-old male notices a painless mass in his scrotum for the first time while showering. Which of the following is an accurate statement regarding the diagnosis of testicular masses?

(A) Biopsy of the testicle is generally required prior to radical inguinal orchiectomy in order to provide a histologic diagnosis

(B) Cystic or fluid-filled masses detected on scrotal ultrasound are typically seminomas

(C) Physical examinations can be performed less frequently with the availability of scrotal ultrasounds

(D) Scrotal ultrasound can distinguish extrinsic from intrinsic testicular lesions and can detect intratesticular lesions as small as 1 to 2 mm

(E) Transillumination studies are sufficient in discerning between malignant versus benign testicular masses

Answer: **(D)** Scrotal ultrasound can distinguish extrinsic from intrinsic testicular lesions and can detect intratesticular lesions as small as 1 to 2 mm.

Rationale:
Testicular cancer is the most common solid malignancy in men of 15 to 35 years of age. All solid testicular masses discovered on physical examination and documented on ultrasound are malignant until proven otherwise. Initial studies must include physical examination, ultrasound, and tumor markers, such as alpha fetoprotein and β-human chorionic gonadotropin. Ultrasound can distinguish extrinsic from intrinsic lesions with great accuracy and can detect lesions as small as 1 mm. A fluid-filled or cystic mass is unlikely to represent malignancy. Nonseminomatous germ cell tumors typically appear heterogenous with calcifications, cystic areas, and indistinct margins. Seminomas appear as well-defined hypoechoic lesions without cystic areas. Scrotal ultrasound has become an extension of the physical examination but should not be a substitute for the latter.

Chest and abdominal imaging with computed tomography (CT) or magnetic resonance imaging (MRI) should be performed to evaluate for metastasis. There is no role for percutaneous biopsy of testicular masses due to the risk of altering the natural retroperitoneal lymphatic drainage of the testicles and seeding the scrotal wall. Radical inguinal orchiectomy is used to provide both histologic diagnosis and local tumor control.

References:
Benson CB. The role of ultrasound in diagnosis and staging of testicular cancer. *Semin Urol.* 1988;6(3):189–202.

Rochelle LJ, Schuch B, Belldegrun A. Urology. In: Brunicardi FC, ed. *Schwartz's Principles of Surgery.* 9th ed. New York, NY: McGraw-Hill; 2010:1462.

2M07

Key word: Ethical Issues in Injury Prevention

Authors: Lisa M. Kodadek, MD, and Kyle J. Van Arendonk, MD, PhD
Editor: Kent A. Stevens, MD, MPH

A 17-year-old woman brings her 11-month-old infant boy to the emergency department for seizure activity. Despite no report of trauma, the child has a bruise on his scalp and is found to have a subarachnoid hemorrhage on computed tomography. Which of the following is true with regard to the potential for nonaccidental injury?

(A) Head injury is the most common manifestation of nonaccidental injury

(B) Nonaccidental injury is seen similarly across parent age and socioeconomic status

(C) Nonaccidental injury is the most common cause of hemorrhagic stroke in children

(D) Skeletal survey is unnecessary in this patient

(E) This patient should undergo ophthalmologic examination

Answer: **(E)** This patient should undergo ophthalmologic examination

Rationale:
Physical abuse, or nonaccidental injury, is unfortunately quite common in children. Nonaccidental injury can occur in any child but is more common among boys, children under 2 years of age, children born to young mothers, children living in poverty, and children with special needs.

Providers must be aware of clues suggesting nonaccidental injury, such as a lack of explanation for an injury, an injury severity that is incompatible with the reported mechanism, a changing report of what happened, and delay in seeking medical care. Any incident of suspected nonaccidental injury must be reported to allow for a thorough investigation with the assistance of child protection services.

The most common manifestation of nonaccidental injury is bruising and other soft tissue injuries. Multiple bruises of various colors and in unusual locations and soft tissue injuries matching specific instruments (belt, etc.) may be seen. The second most common manifestation of nonaccidental injury is fracture. In children with other evidence of abuse or with a suspicious fracture, such as a femoral fracture in a nonambulatory child, a skeletal survey should be performed to search for other fractures. Multiple fractures at various stages of healing are especially concerning for nonaccidental injury.

Abusive head trauma may present with intracranial hemorrhage with no apparent history of trauma. Other findings consistent with abusive head trauma include scalp or ear bruising, retinal hemorrhages in multiple retinal layers, and chronic failure to thrive. Retinal hemorrhages are common in nonaccidental trauma but not in accidental trauma, and therefore ophthalmologic examination is an important component in any abuse investigation. Although a high level of suspicion is important given the morbidity and mortality

۰۲۱-۶۶۱۹۸۵۱۴ www.myuptodate.com دریافت آخرین نسخه آپتودیت آفلاین

associated with abusive head trauma, it is also important not to presume that a child's presentation is secondary to abuse unless there is specific evidence to warrant concern. The most common cause of hemorrhagic stroke in children is in fact arteriovenous malformation rather than nonaccidental injury.

Reference:

Keenan HT, Runyan DK, Marshall SW, et al. A population-based study of inflicted traumatic brain injury in young children. *JAMA*. 2003;290(5):621–626.

2M08

Key word: Etiology of Secondary Traumatic Brain Injury

Author: Isaac Howley, MD
Editor: Albert Chi, MD

An 11-year-old boy presents to the emergency department after falling out of a tree at a height of approximately 6.1 m (20 ft). His primary survey is negative. On secondary survey, you note a Glasgow Coma Scale (GCS) score of 12, tenderness and rigidity of his abdomen, and extremity injuries. Computed tomography scans of his head, abdomen, and pelvis reveal an occipital subarachnoid hemorrhage and a grade 2 splenic laceration. Which of the following is true with regard to secondary brain injury?

(A) According to the Monro–Kellie doctrine, the cranial vault is a closed space, and thus an increase in one constituent volume must be compensated by reduction in another constituent volume

(B) All patients with moderate or severe brain injuries should have an intracranial pressure monitor placed

(C) Hyperventilation decreases PCO_2, causing intracranial vasodilation and thus increased cerebral blood flow

(D) Steroids have been proven to reduce the risks of herniation and death in patients with severe brain injuries

(E) The brain matter 180 degrees away from the site of primary brain injury is at risk for a secondary *contrecoup* injury

Answer: **(A)** According to the Monro–Kellie doctrine, the cranial vault is a closed space, and thus an increase in one constituent volume must be compensated by reduction in another constituent volume

Rationale:

Traumatic brain injury may be divided into two phases: Primary and secondary. Primary injury is a result of the transfer of mechanical force in the initial traumatic episode and includes skull fractures, hematoma formation, and diffuse axonal injuries. Primary injuries may consist of both *coup* and opposite *contrecoup* injuries, in which the brain's momentum causes it to strike the side of the calvarium opposite the original impact. The Monro–Kellie doctrine states that the cranial vault is a closed space; the volume increase due to hemorrhage or cerebral edema must be compensated by decrease in other volumes such as intravascular blood. Secondary injury occurs when this compensation becomes pathologic.

Multiple maneuvers may be attempted to improve cerebral perfusion pressure (CPP) by maintaining mean arterial pressure (MAP) and mitigating increases in intracerebral pressure (ICP). Patients with severe brain injuries (GCS score <9) should be considered for placement of an ICP monitor to guide therapy. The head of the bed should be elevated to 30 degrees, and hypertonic saline and mannitol may be given to reduce cerebral edema and thus ICP. Hyperventilation causes intracerebral vasoconstriction, reducing intracerebral blood volume, and thus ICP; however, it also reduces cerebral blood

۰۲۱-۶۶۱۹۸۵۱۴ www.myuptodate.com دریافت آخرین نسخه آپتودیت آفلاین

flow, potentially worsening hypoxia. Steroids have not been shown to be effective in prevention of secondary injury.

Reference:

Patterson JT, Hanbali F, Franklin RL, et al. Neurosurgery. In: Townsend CM, Beauchamp RD, Evers BM, Mattox KL, eds. *Sabiston Textbook of Surgery.* 18th ed. Philadelphia, PA: Saunders Elsevier; 2008:2112–2115.

2M09

Key word: Etiology of Bleeding Pelvic Fractures

Author: Jens U. Berli, MD
Editor: Albert Chi, MD

A 42-year-old male construction worker is brought to the emergency room after a 120-kg concrete plate landed on his lower anterior torso. The patient has a heart rate of 110 beats per minute and blood pressure of 95/55 mm Hg. His pelvis is unstable on examination, and you temporarily stabilize the pelvis using a binder and complete your assessment, which is otherwise negative. His vital signs respond only transiently to crystalloid resuscitation. You decide to take him to the angiography suite for potential pelvic embolization. What is the most likely source of hemorrhage in this patient?

(A) Bridging veins in the pelvis

(B) Common iliac artery

(C) Internal iliac artery

(D) Internal iliac vein

(E) Superior gluteal artery

Answer: (E) Superior gluteal artery

Rationale:

Pelvic fractures are a difficult to manage entity in trauma and orthopedic surgery. The patient described above suffered from an anterior to posterior compression-type fracture. It is mentioned that the fracture is unstable so likely one or both of his sacroiliac joints are disrupted. The most prevalent

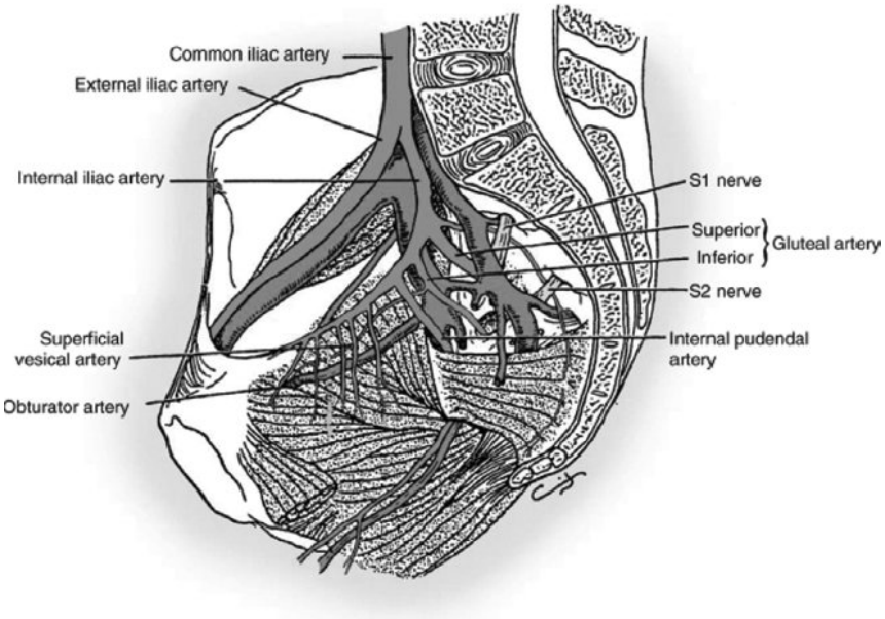

Internal iliac plexus of arteries and veins. Reprinted with permission from: Tile R. Anatomy of the pelvic ring. In: Tile M, Helfet DL, Kellam JF, eds. *Fractures of the Pelvis and Acetabulum.* 3rd ed. Philadelphia, PA: Lippincott Williams & Wilkins, 2003.

۰۲۱-۶۶۱۹۸۵۱۴ www.myuptodate.com دریافت آخرین نسخه آپتودیت آفلاین

arteries to be injured during such a mechanism are the superior gluteal (due to its relation to the sharp fascia of the piriformis and the sacroiliac joint, see figure) and the internal pudendal (runs through pelvic floor with its ligaments, see figure).

Arterial injuries are present in about 5% to 10% of pelvic fractures. By far the most common source of bleeding is venous from bridging veins and osseous surfaces. This form responds relatively well to pelvic binding with reapproximation of the anatomy. If the peritoneum is intact, the retroperitoneum helps to tamponade venous bleeding. In this patient, signs of continued bleeding despite correct pelvic binding and without any signs of intraperitoneal blood loss make arterial bleeding the highest concern on the differential until proven otherwise.

Knowledge of anatomy, fracture classification, presentation, and initial management are crucial to good outcome in this population. Early mortality from pelvic fractures in first-world countries is still around 5% to 10%. Initial management is directed at hemostasis, pelvic stabilization, and urogenital assessment. For active bleeding, treatment options are pelvic binding, angiography, and preperitoneal pelvic packing, typically escalating in the order provided. Angiography requires a fluid-responsive patient. If the patient cannot be stabilized, emergent preperitoneal pelvic packing with external pelvic stabilization is the safest option.

References:

Ben-Menachem Y, Coldwell DM, Young JW, et al. Hemorrhage associated with pelvic fractures: Causes, diagnosis, and emergent management. *AJR Am J Roentgenol.* 1991; 157(5):1005–1014.

Burlew CC, Moore EE, Smith WR, et al. Preperitoneal pelvic packing/external fixation with secondary angioembolization: Optimal care for life-threatening hemorrhage from unstable pelvic fractures. *J Am Coll Surg.* 2011;212(4):628–635; discussion 635–637.

Guyton JL, Perez EA. Fractures of acetabulum and pelvis. In: Canale ST, Beaty JH, eds. *Campbell's Operative Orthopaedics.* 12th ed. Philadelphia, PA: Mosby Elsevier; 2013: 2777–2828.

Hak DJ, Smith WR, Suzuki T. Management of hemorrhage in life-threatening pelvic fracture. *J Am Acad Orthop Surg.* 2009;17(7):447–457.

2M10

Key word: Findings with Temporal Bone Fractures

Author: Lisa M. Kodadek, MD
Editor: Albert Chi, MD

A 23-year-old man presents after sustaining blunt head trauma during a physical altercation. He is noted to have drooping of his right nasolabial fold and inability to wrinkle his right forehead or close his right eye. The most likely cause of his symptoms is:

(A) Bell palsy
(B) Intracranial malignancy
(C) Parietal bone fracture
(D) Stroke
(E) Temporal bone fracture

Answer: (E) Temporal bone fracture

Rationale:

The most common causes of facial nerve injury are temporal bone fractures, penetrating injuries, and iatrogenic injuries. Injury of the facial nerve in temporal bone fractures can result from bony fragment compression, intraneural hematoma, or loss of nerve continuity. Parietal bone fractures are not associated with facial nerve injury. The patient's symptoms are consistent with Bell palsy but given his clinical history, temporal bone fracture is a more likely etiology. Intracranial malignancy is a less likely cause of facial nerve paralysis. Stroke may have a similar presentation but would be unlikely in a young person without any risk factors. Furthermore, motor innervation to the forehead is typically preserved in stroke.

Reference:

Mattox DE. Clinical disorders of the facial nerve. In: Flint PW, Haughey BH, Lund VJ, Niparko JK, Richardson MA, Robbins KT, Thomas JR, eds. *Cummings Otolaryngology: Head & Neck Surgery.* 5th ed. Philadelphia, PA: Mosby Elsevier; 2010:2391–2402.

۰۲۱-۶۶۱۹۸۵۱۴ www.myuptodate.com دریافت آخرین نسخه آپتودیت آفلاین

2M11

Key word: Fracture Associated with Major Vascular Compromise

Author: Raja Mohan, MD
Editor: Ying Wei Lum, MD

A 12-year-old boy tripped and fell on his outstretched right hand. Upon presentation to the emergency department, the boy has a swollen and extremely tender right elbow. On physical examination, the hand appears warm, but the radial pulse is absent. An x-ray reveals a displaced supracondylar humerus fracture. What is the next step in management of this patient?

(A) Closed reduction of fracture with application of a splint
(B) External fixation of fracture
(C) Observation
(D) Operative exploration for vascular injury
(E) Place in splint

Answer: (A) Closed reduction of fracture with application of a splint

Rationale:
Supracondylar fractures in children are very common and usually occur following a fall with an outstretched arm. Neurovascular injury can occur as a result of stretch injury with such fractures. Fortunately, the pulse frequently returns after reduction of the fracture, and thus reduction of the fracture and application of a splint is recommended when patients have a warm, well-perfused hand despite the absence of a palpable pulse. Direct vascular injury is uncommon, but if it does happen, immediate operative repair is required.

Reference:
White L, Mehlman CT, Crawford AH. Perfused, pulseless, and puzzling: A systematic review of vascular injuries in pediatric supracondylar humerus fractures and results of a POSNA questionnaire. *J Pediatr Orthop.* 2010;30(4): 328–335.

2M12

Key word: Human Factors in Injury Prevention

Author: Lisa M. Kodadek, MD
Editor: Kent A. Stevens, MD, MPH

A trimodal distribution exists for mortality after traumatic injury. How can mortality during the first mortality peak best be prevented?

(A) Early intubation and mechanical ventilation
(B) Early operative intervention
(C) Injury prevention and control strategies
(D) Prehospital resuscitation with intravenous fluids
(E) Transport to a level one trauma center within 1 hour of injury

Answer: (C) Injury prevention and control strategies

Rationale:
A trimodal distribution for mortality exists after traumatic injury. The first mortality peak is within seconds or minutes of injury and accounts for half of all trauma deaths. These deaths result from injury to the aorta, heart, brainstem, spinal cord, or acute respiratory distress. The only proven way to prevent death among patients in this first mortality peak is through injury prevention and control practices such as seatbelt use; helmet use; airbags; antilock brakes; laws to prevent intoxicated and impaired drivers; speed limit laws; and improved road lighting, signage, and safety design.

The second mortality peak occurs within hours of injury and accounts for approximately 30% of trauma deaths. These patients are best served by rapid transport to a level one trauma center within the so-called "golden hour." Prehospital resuscitation and early operative intervention may also be of benefit to this subset of trauma patients. The third mortality peak occurs greater than 24 hours after injury and typically is caused by infection or multiple organ failure. Early intubation and mechanical ventilation have an important role in treating these patients with sepsis or respiratory failure after injury.

Reference:
Hoyt DB, Coimbra R, Acosta J. Management of acute trauma. In: Townsend CM, Beauchamp RD, Evers MB, Mattox KL, eds. *Sabiston Textbook of Surgery.* 18th ed. Philadelphia, PA: Elsevier Saunders; 2008:477–479.

۰۲۱-۶۶۱۹۸۵۱۴ www.myuptodate.com دریافت آخرین نسخه آپتودیت آفلاین

2M13

Key word: Ineffective Injury Prevention Strategy

Author: Lisa M. Kodadek, MD
Editor: Kent A. Stevens, MD, MPH

Which of the following represents the most effective long-term injury prevention strategy?

(A) Economic incentives
(B) Education
(C) Engineering
(D) Environment
(E) Law enforcement

Answer: (C) Engineering

Rationale:
Engineering represents the most effective long-term injury prevention strategy. It has been shown that passive approaches to injury prevention are more effective than active approaches. For example, an airbag is a passive, engineered mechanism that can limit or prevent injury in motor vehicle crashes. This strategy requires no effort or cooperation from the occupants of the car to ensure its proper function. An active mechanism such as seatbelt use, on the other hand, requires cooperation from the occupants and therefore is a less effective injury prevention mechanism.

While education is an important injury prevention strategy and rests upon the theory that knowledge supports change in behavior, this method in practice is a less effective method for injury prevention. Law enforcement and economic incentives (e.g., avoidance of a speeding ticket) can help prevent injury, but there still exists a subset of the population for whom this will not be an effective prevention strategy. Finally, environmental factors can be addressed to prevent injury, but again this method is not as effective as engineering products that automatically provide a layer of injury prevention without cooperation or input from the individual subject to injury.

Reference:
Hoyt DB, Coimbra R, Acosta J. Management of acute trauma. In: Townsend CM, Beauchamp RD, Evers MB, Mattox KL eds. *Sabiston Textbook of Surgery.* 18th ed. Philadelphia, PA: Elsevier Saunders; 2008:477–482.

2M14

Key word: Most Important Measure in Injury Outcome

Author: Brenessa M. Lindeman, MD
Editor: Kent A. Stevens, MD, MPH

A 24-year-old male is brought to the emergency department 1 hour following an assault with a baseball bat in which he suffered repeated head trauma. On arrival, he is hemodynamically stable. He opens his eyes to command, is speaking in incoherent statements, and moves his extremities to command. Which of the following is the most important predictor of outcome in this patient?

(A) Cranial nerve responses
(B) Glasgow Coma Scale (GCS) score on hospital admission
(C) Initial vital signs on presentation
(D) Transport time from field to emergency department
(E) Verbal responses to questions

Answer: (B) Glasgow Coma Scale (GCS) score on hospital admission

Rationale:
Outcome (mortality, level of disability, etc.) after traumatic brain injury correlates quite well with GCS score in patients in whom a GCS score can reliably be obtained upon admission. Research has shown that the predictive ability of the GCS score is improved when correlated with other significant predictive variables in head trauma such as patient age,

Glasgow Coma Scale (GCS)

Eye Opening	
Spontaneous	4
To voice	3
To pain	2
None	1
Verbal Response	
Oriented	5
Confused	4
Inappropriate words	3
Incomprehensible sounds	2
None	1
Motor Response	
Obeys commands	6
Purposeful movement (pain)	5
Withdraw (pain)	4
Flexion (pain)	3
Extension (pain)	2
None	1
GCS Subtotal	3–15

Reprinted with permission from: Bulger EM. Prehospital and resuscitation care. In: Mulholland MW, Lillemoe KD, Doherty GM, Maier RV, Upchurch GR, eds. *Greenfield's Surgery: Scientific Principles & Practice*. 5th ed. Philadelphia, PA: Lippincott Williams & Wilkins, 2011:332.

۰۲۱-۶۶۱۹۸۵۱۴ www.myuptodate.com دریافت آخرین نسخه آپتودیت آفلاین

pupillary diameter, response to light, episodes of hypotension, and pathologic findings on initial computed tomography. In addition, use of the motor component of the GCS score alone, rather than the summed GCS score, has been shown to yield similar or improved outcome prediction rates in head-injured patients. A higher correlation exists between particular ranges of GCS scores and measures of outcomes. In general, the GCS is best at predicting very good or very poor outcomes.

References:

Bulger EM. Prehospital and resuscitation care. In: Mulholland MW, Lillemoe KD, Doherty GM, Maier RV, Upchurch GR, eds. *Greenfield's Surgery: Scientific Principles & Practice.* 5th ed. Philadelphia, PA: Lippincott Williams & Wilkins; 2011.

Chesnut RM, Ghajar J, Maas AIR, et al. Early Indicators of Prognosis in Severe Traumatic Brain Injury. Brain Trauma Foundation; 2000. http://www.braintrauma.org/pdf/protected/prognosis_guidelines.pdf. Accesssed May 9, 2013.

2M15

Key word: Treatment of Compression Fractures at the Thoracolumbar Junction

Author: Isaac Howley, MD
Editor: Frank J. Frassica, MD

A 74-year-old female is brought to the emergency room after a fall. She has normal vital signs and a Glasgow Coma Scale (GCS) score of 14. Her past medical history is notable for hypertension, osteoporosis, and colon cancer. Her physical examination reveals minimal tenderness to palpation of her upper lumbar spine. She has no motor or sensory neurologic deficits of the lower extremities, and her rectal examination demonstrates normal tone. Computed tomography is notable only for wedge compression fractures of the L1 and L2 spinal bodies. What is the most appropriate acute management of her spinal injury?

(A) Bed rest, custom orthosis, and analgesia

(B) No intervention—discharge home with appropriate analgesia

(C) Open reduction and plate fixation via anterior approach

(D) Open reduction and plate fixation via posterior approach

(E) Percutaneous vertebroplasty

Answer: **(A)** Bed rest, custom orthosis, and analgesia

Rationale:

Acute management of thoracolumbar compression fractures hinges upon the determination of spinal stability and thus risk for injury to the spinal cord. The need for operative fixation is based on the fracture mechanism, integrity of the posterior ligamentous complex, and resulting neurologic deficits. Compression fractures are due to flexion injuries, frequently in patients with underlying osteoporosis. They are rarely associated with injury to the posterior ligaments and almost never result in neurologic impairment unless multiple spinous processes are involved. However, wedge compression fractures may decrease the size of the thoracic cavity, decreasing forced vital capacity (FVC) by 9% per spinal body fractured, perhaps contributing to an increased risk of mortality compared to age-matched controls.

Operative fixation is not indicated in the absence of neurologic deficits; hardware does not attach well to the attenuated spinal bone of osteoporotic patients. When operative intervention is indicated for spinal fractures, there is no clear evidence of superiority for anterior or posterior approaches. In patients with normal neurologic function and no evidence of posterior column instability, the acute management of compression fractures consists only of bed rest, custom bracing, analgesia, and physical therapy. Pain is not universally present with these fractures, but when present will generally subside within 1 to 8 months.

Minimally invasive techniques have evolved to improve pain associated with compression fractures. Vertebroplasty is the injection of cement into the anterior portion of the spinal

۰۲۱-۶۶۱۹۸۵۱۴ www.myuptodate.com دریافت آخرین نسخه آپتودیت آفلاین

body. This procedure does nothing to restore spinal alignment but improves pain in 70% to 90% of patients. There is a major complication rate of approximately 4.5%, with pulmonary embolization of cement being a major risk. Balloon kyphoplasty uses a balloon to create a larger space for injected cement, thus reducing and fixating the deficit and restoring some degree of the original spinal anatomy. However, this also leads to increased stress on adjacent vertebrae, which may then fracture in as many as 17% of patients. Kyphoplasty, which has a pulmonary embolus risk that appears to be about the same as for vertebroplasty, is not routinely performed for patients whose pain is controlled with nonoperative management.

Reference:

Wood GW II. Fractures, dislocations, and fracture-dislocations of the spine. In: Canale ST, Beatty JH. *Campbell's Operative Orthopaedics.* 11th ed. Philadelphia, PA: Mosby Elsevier; 2008:1761–1850.

2M16

Key word: Treatment of Depressed Skull Fracture

Author: Kyle J. Van Arendonk, MD, PhD
Editor: Pamela A. Lipsett, MD, MHPE, FACS, FCCM

A patient with traumatic head injury is brought to the emergency room. Which of the following scenarios is MOST appropriate for conservative, nonoperative management?

(A) A 79-year-old neurologically intact man with an open depressed skull fracture (depression of 6 mm) and no evidence of intracranial hematoma

(B) A 24-year-old neurologically intact woman with a closed depressed skull fracture (depression of 13 mm) and no evidence of intracranial hematoma

(C) A 35-year-old neurologically intact man with an open depressed fracture involving the frontal sinus with radiologic evidence of a dural tear

(D) An unresponsive 1-year-old female with an obvious concave deformity of the parietal aspect of her skull (a "ping-pong" fracture) and an underlying 2-cm intracranial hematoma

(E) A 40-year-old neurologically intact woman with an open depressed skull fracture contaminated with soil and glass

Answer: (A) A 79-year-old neurologically intact man with an open depressed skull fracture (depression of 6 mm) and no evidence of intracranial hematoma

Rationale:

The presence of a skull fracture after traumatic head injury has consistently been associated with intracranial lesions (contusions or hematomas), neurologic deficits, and poorer outcomes. Skull fractures can be categorized as open or closed (based upon the presence or absence of an overlying scalp laceration in continuity with the fracture site) and depressed or nondepressed (based upon the relationship of the bone fragments to each other).

Depressed skull fractures often cause injury to the underlying brain. In addition, most depressed skull fractures are open and should be assumed to be so until proven otherwise. Depressed skull fractures are treated surgically with debridement and elevation when any of the following indications are present: The depression is greater than the thickness of the skull (approximately 8 to 10 mm), a focal neurologic deficit results from compression of the brain parenchyma, a significant underlying intracranial hematoma is present, pneumocephalus is seen, the frontal sinus is involved, gross cosmetic deformity exists, gross wound contamination is present, or intraparenchymal bone fragments are seen, indicating laceration of the dura mater and an increased risk of infection. Nonoperative management is appropriate for patients with depressed skull fractures (even if open) that possess none of these findings.

۰۲۱-۶۶۱۹۸۵۱۴ www.myuptodate.com دریافت آخرین نسخه آپتودیت آفلاین

A "ping-pong fracture" is a type of greenstick fracture typically seen in newborns that appears as a local concavity of the skill without sharp edges. This type of fracture occurs because of the plasticity of the skull in children at this age. Unless the depression is deeper than the thickness of the skull (or another indication for surgery is present), these fractures usually do not require surgical intervention because the skill will remodel and smooth out the defect during growth.

Indications for Nonoperative Management of Compound Depressed Skull Fractures

No clinical or radiographic evidence of:
- Gross wound contamination
- Significant intracranial hematoma
- Gross cosmetic deformity
- Frontal sinus involvement
- Dural penetration
- Depression >1 cm
- Wound infection
- Pneumocephalus

Reprinted with permission from: Chesnut RM. Head trauma. In: Mulholland MW, Lillemoe KD, Doherty GM, Maier RV, Upchurch GR, eds. *Greenfield's Surgery: Scientific Principles & Practice.* 5th ed. Philadelphia, PA: Lippincott Williams & Wilkins, 2011:349.

References:

Bullock MR, Chesnut R, Ghajar J, et al. Surgical management of depressed cranial fractures. *Neurosurgery.* 2006;58(3): S56–S60; discussion Si–Siv.

Post AF, Boro T, Ecklund JM. Injury to the brain. In: Mattox KL, Moore EE, Feliciano DV, eds. *Trauma.* 7th ed. New York, NY: McGraw-Hill; 2013. http://www.accesssurgery.com/content.aspx?aID=56890421. Accessed May 21, 2013.

2M17

Key word: Diagnosis of Ectopic Pregnancy

Author: Lisa M. Kodadek, MD
Editor: Mehran Habibi, MD, MBA

A 37-year-old G1P1 woman presents to the emergency department with sudden-onset, severe abdominal pain. Her history is notable for current tobacco use and an intrauterine contraceptive device placed 3 years ago. She is afebrile with a heart rate of 130 beats per minute, blood pressure of 80/50 mm Hg, respiratory rate of 24 breaths per minute, and oxygen saturation of 93% on room air. Her examination is notable for peritonitis and adnexal tenderness. The most probable cause of her symptoms is:

(A) Appendicitis
(B) Pelvic inflammatory disease
(C) Ruptured ectopic pregnancy
(D) Ruptured uterus
(E) Tubo-ovarian abscess

Answer: (C) Ruptured ectopic pregnancy

Rationale:

This patient has several risk factors for ectopic pregnancy including advanced maternal age, current use of an intrauterine contraceptive device, and smoking. The overall rate of ectopic pregnancy is 16 per 1,000 pregnancies. Among women aged 35 to 44 years, the rate is 27 per 1,000 pregnancies. Other risk factors for ectopic pregnancy include a history of pelvic inflammatory disease, tubal sterilization, congenital anomalies of the fallopian tube, prior ectopic pregnancy, progestin-only contraceptive methods, prior pelvic surgery, and conception via reproductive technology.

In obtaining the clinical history, it is important to assess for amenorrhea, irregular vaginal bleeding, and abdominal pain. This triad is present in 50% of women with ectopic pregnancy. Abdominal pain is the most common symptom at presentation in the patient with a ruptured ectopic pregnancy and may result after the development of hemoperitoneum. Other findings associated with ruptured ectopic pregnancy are tachycardia, hypotension, peritonitis, and cervical motion tenderness.

Reference:

Saunders BA, Stovall TG. Ectopic pregnancy. In: Bieber EJ, Sanfilippo JS, Horowitz IR, eds. *Clinical Gynecology.* 1st ed. Philadelphia, PA: Churchill Livingstone Elsevier; 2006: 205–217.

۰۲۱-۶۶۱۹۸۵۱۴ www.myuptodate.com دریافت آخرین نسخه آپتودیت آفلاین

2M18

Key word: Treatment of Head Injury with Hypotension

Author: Lisa M. Kodadek, MD
Editor: Kent A. Stevens, MD, MPH

A 39-year-old male who was not wearing a helmet presents after a motorcycle crash with a Glasgow Coma Scale score of 4, significant craniofacial injury, and asymmetric pupils. Vital signs are as follows: Pulse of 115 beats per minute, blood pressure of 70/50 mm Hg, and respiratory rate of 30 breaths per minute. The patient is intubated and noted to have bilateral breath sounds. Which of the following is the most important next step in management?

(A) Bilateral carotid Doppler/ultrasonography (duplex)
(B) Computed tomography (CT) scan of head without contrast
(C) CT of chest, abdomen, and pelvis with contrast
(D) Focused abdominal sonography for trauma (FAST)
(E) Plain radiograph of chest and pelvis

Answer: (D) Focused abdominal sonography for trauma (FAST)

Rationale:
The clinician must determine the etiology of this patient's hypotension in order to correct the underlying cause and appropriately treat it. Hypotension is usually not due to a brain injury itself, except perhaps in terminal stages when medullary failure ensues. An airway has been established, and bilateral breath sounds are present; the next step is then to perform a FAST to search for the cause of hypotension.

Although a CT scan of the head may be valuable in this patient's evaluation, it is not the most important test to perform at this time, and it is never advisable to send a hemodynamically unstable patient to the CT scanner for imaging. Even if the patient has a significant head injury, measures to avoid hypotension and maintain cerebral perfusion pressure are the main priority, so precedence should be given toward identifying the source of hypotension. Plain films may be a helpful adjunct study but should not delay FAST in a hemodynamically unstable trauma patient. A carotid duplex may be indicated if physical examination reveals injury to this area but would not be the next step in management.

Reference:
Hoyt DB, Coimbra R, Acosta J. Management of acute trauma. In: Townsend CM, Beauchamp RD, Evers MB, Mattox KL, eds. *Sabiston Textbook of Surgery.* 18th ed. Philadelphia, PA: Elsevier Saunders; 2008:477–519.

2M19

Key word: Treatment of Ovarian Cysts

Author: Issac Howley, MD
Editor: Mark D. Duncan, MD, FACS

A 22-year-old female presents with 1 day of anorexia, nausea, and periumbilical pain progressing over time to right lower quadrant pain. Her greatest tenderness is over McBurney point, she has a positive Rovsing sign, and there is no cervical motion tenderness on bimanual pelvic examination. She has a white blood cell count of $15.8 \times 10^3/\mu L$, a negative urine pregnancy test, and a negative urine test for *Neisseria gonorrhoeae* and *Chlamydia trachomatis.* Upon laparoscopic exploration, a grossly inflamed appendix and a 4-cm smooth, white, mobile, unilocular cystic mass arising from the left ovary are noted. The remaining ovarian tissue appears normal. After performing an appendectomy, what is the most appropriate management of the ovarian mass?

(A) Aspiration
(B) Cystectomy
(C) No intervention
(D) Oophorectomy
(E) Oophoropexy

Answer: (C) No intervention

Rationale:
Asymptomatic ovarian cysts in reproductive-aged women are nearly always benign functional cysts, serous or mucinous cystadenomas, or hemorrhagic cysts. As few as 10% of pelvic masses seen at laparotomy in women under 30 years of age are malignant, and even those malignancies are usually of much lower malignant potential than ovarian epidermal carcinoma. This patient's cyst has characteristics indicative of a benign nature, and had it instead been discovered on pelvic ultrasound, there would be no indication for laparscopic evaluation. Larger, multiloculated, fixed masses with papillae and increased blood flow seen on duplex ultrasound imaging are more likely to be malignant. Treatment depends on diagnosis and symptomatology.

Follicular cysts and corpus luteum cysts, both of which are unilocular, and theca lutein cysts, which are multilocular and may be associated with pregnancies or molar neoplasms, comprise the "functional" cysts. These cysts frequently resolve with expectant management. There is a low risk of rupture, which could cause peritonitis or hemorrhage. However, smaller asymptomatic cysts without evidence of rupture are best managed expectantly. Symptomatic cysts may be aspirated or enucleated by cystectomy; however, both procedures may lead to adhesions that may compromise fertility. Oral contraceptives are protective against the development of functional cysts but have not been shown to speed their resolution. Other non-neoplastic ovarian masses include endometriomas and polycystic ovaries; these do not warrant operative therapy when asymptomatic.

۰۲۱-۶۶۱۹۸۵۱۴ www.myuptodate.com دریافت آخرین نسخه آپتودیت آفلاین

Ovarian torsion may mimic appendicitis in presentation, although this patient's ovary does not appear torsed by the description given. Therapy is exclusively surgical and consists of detorsion when viable or oophorectomy if infarcted. The efficacy of oophoropexy has not been established.

Neoplastic ovarian masses include dermoid tumors (cystic teratomas), serous tumors, mucinous tumors, sarcomas, and epidermal carcinomas. Dermoid tumors are by far the most likely in reproductive aged women; they are nearly always benign and may be treated by simple cystectomy. Serous and mucinous tumors exist along a continuum of malignant potential, with as many as 25% of serous and 10% of mucinous tumors being malignant. Growth over time, presence of a solid component to the cyst, septations, and the presence of otherwise unexplained ascites are all concerning for malignancy. Concerning cystic neoplasms warrant radical resection with salpingo-oophorectomy. They should not be aspirated, as this could potentially cause the dissemination of malignant cyst contents throughout the peritoneal cavity.

References:

Adams Hillard PJ. Benign diseases of the female reproductive tract. In: Berek JS, ed. *Berek and Novak's Gynecology.* 15th ed. Philadelphia, PA: Lippincott Williams & Wilkins; 2012:374–437.

Entman SS, Graves CR, Jarnagin BK, et al. Gynecologic surgery. In: Townsend CM, Beauchamp RD, Evers BM, Mattox KL, eds. *Sabiston Textbook of Surgery.* 18th ed. Philadelphia, PA: Saunders Elsevier; 2008:2201–2235.

2M20

Key word: Diagnosis of Pelvic Inflammatory Disease/Tubo-ovarian Abscess

Author: Lisa M. Kodadek, MD
Editor: Mark D. Duncan, MD, FACS

A 19-year-old sexually active woman presents with acute pleuritic right upper quadrant pain radiating to her right shoulder. Laboratory findings are notable for a leukocytosis and mildly elevated transaminases. Her laboratory studies are otherwise normal. Her presentation is most consistent with:

(A) Asherman syndrome
(B) Fitz-Hugh–Curtis syndrome
(C) Meigs syndrome
(D) Mirizzi syndrome
(E) Sheehan syndrome

Answer: (B) Fitz-Hugh–Curtis syndrome

Rationale:

Acute perihepatitis (Fitz-Hugh–Curtis syndrome) is localized inflammation marked by a purulent or fibrinous exudate affecting the anterior surface of the liver (Glisson capsule) and the adjacent parietal peritoneum. This syndrome is most often associated with acute pelvic inflammatory disease (PID) even in the absence of symptoms to suggest PID. Clinical presentation is characterized by acute onset of severe right upper quadrant pain, which may be difficult to distinguish from acute cholecystitis. *Chlamydia trachomatis* is the most common causative pathogen. Associated signs and symptoms include fever, leukocytosis, abdominal pain, cervicitis, and mildly elevated transaminases.

A late consequence of Fitz-Hugh–Curtis syndrome may be the finding of incidental hepatic adhesive capsulitis. This does not require treatment unless lysis of these attachments is necessary to facilitate mobilization of the liver for traction on the gallbladder (i.e., in laparoscopic cholecystectomy).

Asherman syndrome is the presence of intrauterine adhesions frequently associated with endometrial curettage and often presenting as secondary amenorrhea. Meigs syndrome presents as a benign fibroma of the ovary with ascites and pleural effusion. Sheehan syndrome is pituitary cell destruction as a result of hypotension during pregnancy. Mirizzi syndrome is an uncommon condition involving impaction of a stone in the infundibulum of the gallbladder with subsequent mechanical obstruction and inflammation of the common hepatic duct.

References:

Bayram J, Malik M. Gynecologic infections. In: Adams JG, Nadel ES, DeBlieux PM, Barton ED, Collings J, eds. *Emergency Medicine.* 1st ed. Philadelphia: Saunders Elsevier; 2008:1386–1387.

Eckert LO, Lentz GM. Infections of the lower and upper genital tracts. In: Lobo RA, Lentz GM, Gershenson DM, Katz VL, eds. *Comprehensive Gynecology.* 6th ed. Philadelphia, PA: Mosby Elsevier; 2012:544–558.

۰۲۱-۶۶۱۹۸۵۱۴ www.myuptodate.com دریافت آخرین نسخه آپتودیت آفلاین

Pappas TN, Ceppa EP. Benign biliary strictures. In: Cameron JL, Cameron AM, eds. *Current Surgical Therapy.* 10th ed. Philadelphia, PA: Elsevier Saunders; 2011:352–353.

Sweet RL. Sexually transmitted diseases. In: Bieber EJ, Sanfilippo JS, Horowitz IR, eds. *Clinical Gynecology.* 1st ed. Philadelphia, PA: Churchill Livingstone Elsevier; 2006: 259–284.

2M21

Key word: Treatment of Recurrent Laryngeal Nerve Injury

Author: Joshua H. Wolf, MD
Editor: Anthony P. Tufaro, DDS, MD, FACS

During a total thyroidectomy for papillary thyroid cancer, the left recurrent laryngeal nerve (RLN) is inadvertently ligated with a 4-0 silk suture and divided. The best management strategy is:

(A) Free the nerve and perform an emergency tracheostomy

(B) Free the nerve endings and perform a laryngoscopy to assess cord motion

(C) Medialization of the ipsilateral cord

(D) Reinnervation with direct nerve repair using a branch of the ansa cervicalis

(E) Reinnervation with direct nerve repair using the spinal accessory nerve

Answer: (D) Reinnervation with direct nerve repair using a branch of the ansa cervicalis

Rationale:

Injury to the RLN can result in permanent vocal cord paralysis and occurs at a rate of approximately 1% to 2% during thyroidectomy. Most commonly the nerve is damaged bluntly from the stretch or strain of a retractor and not completely transected. Such cases of blunt or crush injury to the RLN may be managed expectantly with a strong likelihood of full recovery. If the nerve is mistaken for an expendable structure and tied off with a suture but not divided, there is also a reasonable chance of recovery as long as the tie is removed expediently.

Full transection of the RLN can be addressed with one of several reinnervation techniques. The exact method depends somewhat on the patient's anatomy and the location of the transection, but the most commonly reported technique is ansa cervicalis-to-RLN anastomosis. Others include primary RLN repair, ansa-to-RLN with cricothyroid muscle–nerve–muscle pedicle, and hypoglossal-to-RLN repair. In the event of a bilateral RLN injury and bilateral cord paralysis, the patient will require a tracheostomy to maintain a patent airway.

References:

Aynehchi BB, McCoul ED, Sundaram K. Systematic review of laryngeal reinnervation techniques. *Otolaryngol Head Neck Surg.* 2010;143(6):749–759.

Slough CM, Dralle H, Machens A, et al. Diagnosis and treatment of thyroid and parathyroid disorders. In: Bailey BJ, Johnson JT, Newlands SD, eds. *Head and Neck Surgery—Otolaryngology.* 3rd ed. Philadelphia, PA: Lippincott Williams & Wilkins; 2006:1640–1642.

۰۲۱-۶۶۱۹۸۵۱۴ www.myuptodate.com دریافت آخرین نسخه آپتودیت آفلاین

2M22

Key word: Treatment of Testicular Torsion

Author: Said C. Azoury, MD
Editor: Arthur L. Burnett, MD, MBA, FACS

A 21-year-old football player presents with acute scrotal pain. Review of symptoms is positive for nausea and vomiting. For which of the following would immediate emergent surgical exploration be most appropriate?

(A) Epididymitis
(B) Hydrocele
(C) Reducible inguinal hernia
(D) Testicular torsion
(E) Varicocele

Answer: (D) Testicular torsion

Rationale:
With testicular torsion, blood supply to the testicle is compromised due to twisting of the spermatic cord within the tunica vaginalis, resulting in ischemia to the epididymis and the testis. Clinical history is critical, as patients generally describe a sudden onset of pain with subsequent swelling. Clinical examination often finds a horizontal and somewhat high, rather than oblique/vertical, position of a testis that has had torsion. Doppler ultrasound typically shows decreased intratesticular blood flow compared to the unaffected testis. Immediate surgical exploration can salvage an ischemic testis. More than 80% of testes can be salvaged if surgery is performed within 6 hours. This percentage decreases to 20% or less as time progresses beyond 12 hours.

Varicoceles are venous dilations that are associated with infertility and are worrisome for renal cell cancer when present on the left. Varicoceles, however, do not generally present acutely and do not require emergent surgical intervention. Infectious epididymitis can be acute, subacute, or chronic and is generally treated with intravenous antibiotics. Inguinal hernias are generally noticed over a prolonged period of time but may worsen acutely. Generally, although the hernia should be surgically corrected, emergent intervention is not needed provided the hernia is not incarcerated and there is no concern for strangulation.

Hydrocele is a collection of peritoneal fluid between the parietal and the visceral layers of the tunica vaginalis, the investing layer that directly surrounds the testis and the spermatic cord. Most hydroceles are congenital and close spontaneously within several months. Adult hydroceles usually arise over a long period of time. Although treatment is surgical removal of the hydrocele sac and fluid, it is not emergent.

References:
Cummings JM, Boullier JA, Sekhon D, et al. Adult testicular torsion. *J Urol.* 2002;167(5):2009.
Rochelle LJ, Schuch B, Belldegrun A. Urology. In: Brunicardi FC, ed. *Schwartz's Principles of Surgery.* 9th ed. New York, NY: McGraw-Hill; 2010:1469.

2M23

Key word: Treatment of Tracheoinnominate Fistula

Author: Vicente Valero III, MD
Editor: Robert A. Meguid, MD, MPH

A 72-year-old woman is diagnosed with gastric adenocarcinoma and undergoes a total gastrectomy. Her postoperative course is complicated by aspiration pneumonia, leading to intubation, ventilator dependence, and eventual tracheostomy. You are called to see her 2 weeks after her tracheostomy when her nurse sees bright red blood emanating from her tracheostomy site. Your examination reveals profuse, pulsatile bleeding from the tracheostomy. What is the first step in the management of this condition?

(A) Obtain a chest x-ray
(B) Overinflate the tracheostomy tube cuff
(C) Perform a bedside thoracotomy
(D) Perform flexible bronchoscopy
(E) Remove the tracheostomy tube

Answer: (B) Overinflate the tracheostomy tube cuff

Rationale:
Tracheoinnominate artery fistula (TIF) is a rare but often fatal complication following tracheostomy. It occurs when the tracheostomy tube causes pressure necrosis and ultimately erosion of the tracheal rings into the innominate artery. There is often a herald bleed before the onset of overt, massive, and often fatal hemorrhage. This complication occurs in <1% of patients with tracheostomy. To prevent TIF, the tracheostomy should be placed at the level of the second or third tracheal rings and not further inferior.

The typical presentation of TIF occurs 2 to 4 weeks after tracheostomy placement. The innominate artery usually passes anterior to the trachea around the ninth tracheal ring. When TIF is suspected, the first step one should take at the bedside is overinflation of the tracheostomy cuff. This can be done by injecting air into the cuff until the hemorrhage is controlled. This is successful in temporizing the bleeding in as many as 80% of cases. If this fails, one must place an endotracheal tube via the oropharynx, remove the tracheostomy tube, and apply digital pressure to the artery against the sternum via the tracheostomy. The patient should be transported to the operating room immediately, with ongoing occlusion of the innominate artery. Definitive management then consists of median sternotomy followed by ligation of the innominate artery or aortoaxillary bypass graft for patients with significant atherosclerotic disease. Mortality from this complication is approximately 90%.

۰۲۱-۶۶۱۹۸۵۱۴ www.myuptodate.com دریافت آخرین نسخه آپتودیت آفلاین

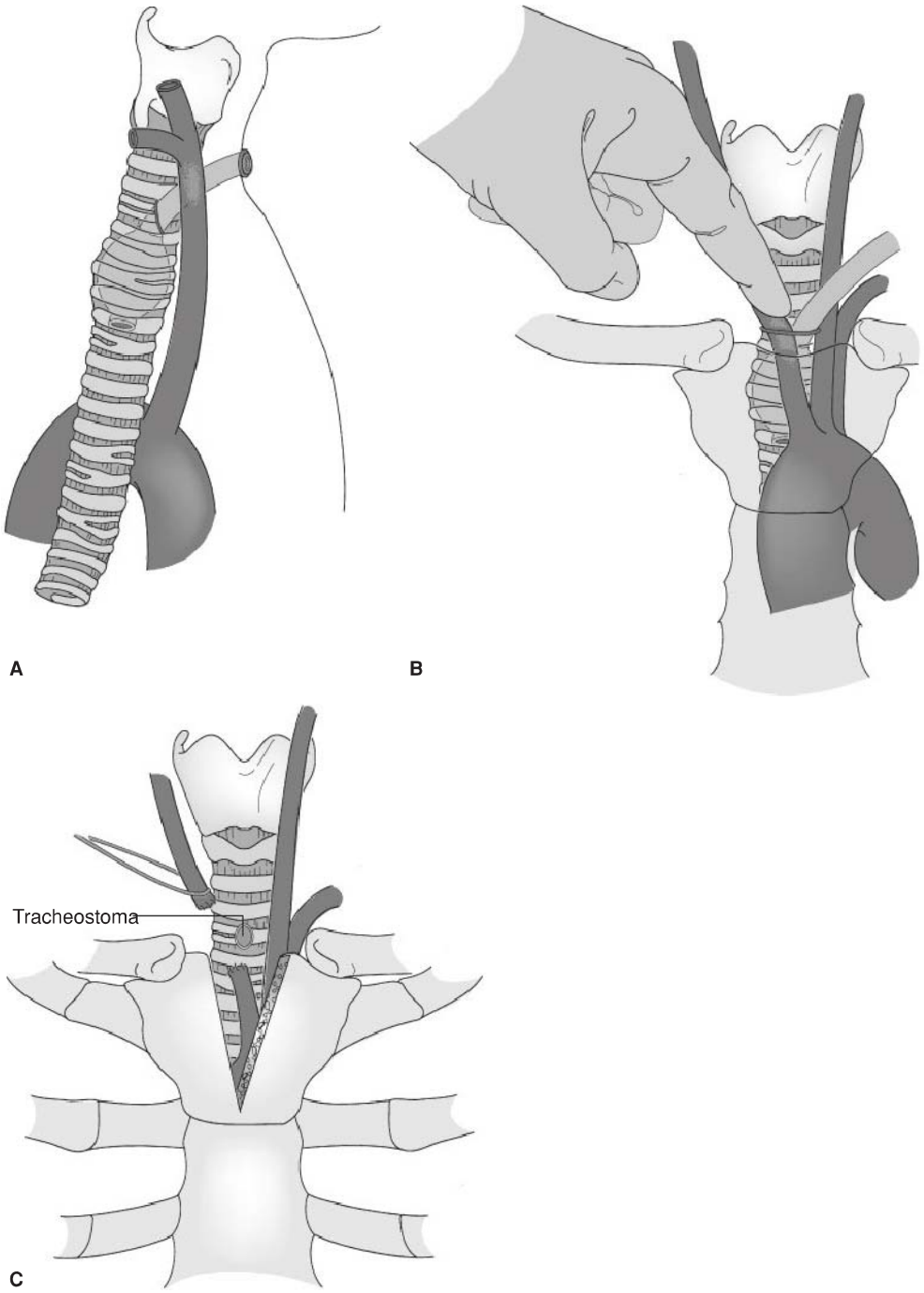

Management of tracheoinnominate artery fistula. **A:** Common mechanism of injury from erosion of innominate artery by adjacent tracheostomy tube. **B:** Emergency treatment of hemorrhage involves insertion of an endotracheal tube into the tracheostomy stoma, inflation of the cuff, and downward and outward pressure on the fistula by the finger inserted through the tracheostomy incision to further tamponade the bleeding. **C:** Through a partial upper sternal split, the segment of involved innominate artery is resected and the oversewn ends covered with adjacent mediastinal fat or muscle. Tracheal resection is usually not necessary. A new tracheostomy tube may have to be inserted higher in the trachea or, if possible, the tracheostomy tube removed and the stoma covered with a sternohyoid muscle flap. Reprinted with permission from: Reddy RM. Chest wall, pleura, mediastinum, and non-neoplastic lung disease. In: Mulholland MW, Lillemoe KD, Doherty GM, Maier RV, Upchurch GR, eds. *Greenfield's Surgery: Scientific Principles & Practice*. 5th ed. Philadelphia, PA: Lippincott Williams & Wilkins, 2011:1418.

References:

Gelman JJ, Aro M, Weiss SM. Tracheo-innominate artery fistula. *J Am Coll Surg.* 1994;179(5):626–634.

Reddy RM. Chest wall, pleura, mediastinum, and non-neoplastic lung disease. In: Mulholland MW, Lillemoe KD, Doherty GM, Maier RV, Upchurch GR, eds. *Greenfield's Surgery: Scientific Principles & Practice.* 5th ed. Philadelphia, PA: Lippincott Williams & Wilkins; 2011.

Seybt MW, Jackson LL, Terris DJ. Tracheostomy. In: Cameron JL, Cameron AM, eds. *Current Surgical Therapy.* 10th ed. Philadelphia, PA: Mosby; 2011:1120–1122.

۰۲۱-۶۶۱۹۸۵۱۴ www.myuptodate.com دریافت آخرین نسخه آپتودیت آفلاین

2M24

Key word: Treatment of Warthin Tumor

Author: Said C. Azoury, MD
Editor: Anthony P. Tufaro, DDS, MD, FACS

A 45-year-old man is seen by his primary care physician for painless swelling at the angle of his left mandible. Biopsy of the lesion reveals a Warthin tumor at the inferior aspect of his parotid gland. Which of the following is the appropriate definitive management and treatment for this tumor based on the pathology of the disease?

(A) Bilateral superficial or conservative parotidectomy followed by bilateral radiation therapy

(B) Simple enucleation, or shelling out, of the tumor on the affected side

(C) Superficial or conservative parotidectomy on the affected side and evaluation of the contralateral side for tumor

(D) Superficial or conservative unilateral parotidectomy on the affected side

(E) Superficial or conservative unilateral parotidectomy on the affected side followed by radiation therapy on the same side

Answer: (C) Superficial or conservative parotidectomy on the affected side and evaluation of the contralateral side for tumor

Rationale:

Most parotid tumors, 75% to 80%, are benign. The superficial and deep parotid lobes are divided by the facial nerve. Preservation of the facial nerve while adequately resecting the tumor is critical to the treatment and management of Warthin tumors.

Parotidectomy is classified as superficial, total, or conservative. A conservative or limited superficial parotidectomy is less extensive than a superficial parotidectomy and does not fully dissect the facial nerve. A superficial parotidectomy involves resection of the entire superficial lobe and dissection along all branches of the facial nerve. A total parotidectomy involves dissection and preservation of the facial nerve and removal of the parotid tissue in the deep as well as superficial lobe. Simple enucleation, or shelling out, of a tumor is rarely performed.

Due to the multifocality and bilaterality of Warthin tumors, evaluation of the contralateral side with imaging for disease is critical. Radiation is generally not indicated for the management of these benign tumors. Prophylactic contralateral parotidectomy is not recommended.

References:

Helmus C. Subtotal parotidectomy: A 10-year review (1985 to 1994). *Laryngoscope.* 1997;107(8):1024–1027.

Lim YC, Lee SY, Kim K, et al. Conservative parotidectomy for the treatment of parotid cancers. *Oral Oncol.* 2005;41(10): 1021–1027.

O'Brien CJ. Current management of benign parotid tumors—the role of limited superficial parotidectomy. *Head Neck.* 2003;25(11):946–952.

2M25

Key word: Treatment of Thrombosed Ovarian Vein

Author: Joshua C. Grimm, MD
Editor: Elizabeth C. Wick, MD

A 25-year-old G2P2 female presents to the emergency department 1 week after an uncomplicated vaginal delivery with a 1-day history of fever and pelvic pain. Her white blood cell count is 22 × 10^3/μL. An ultrasound reveals a tubular, hypoechoic structure extending from her left adnexa. Which of the following is true concerning this condition?

(A) Complicates 10% to 15% of pregnancies

(B) Intravenous antibiotic therapy and systemic anticoagulation is the treatment of choice

(C) Most commonly affects the left ovarian vein

(D) Pulmonary embolism occurs in less than 1% of cases

(E) Ultrasonographic evaluation is always diagnostic

Answer: (B) Intravenous antibiotic therapy and systemic anticoagulation is the treatment of choice

Rationale:

Ovarian vein thrombosis complicates less than 1% of pregnancies, but if this diagnosis is missed or undertreated, it can have serious consequences, including pulmonary embolism in 10% to 15% of cases. Women usually present with pelvic pain, fever, tachycardia, and leukocytosis. In 80% to 90% of cases, it affects the right ovarian vein due in part to its increased length and number of valves compared to the left ovarian vein. Ultrasonography is the initial imaging modality of choice, but due to overlying gas-filled bowel, computed tomography (CT) and magnetic resonance imaging are often necessary to establish an accurate diagnosis. Ultrasonography usually reveals a hypoechoic mass within the lumen of the vein and decreased flow on Doppler. On CT, an enlarged ovarian vein with central hypodensity is seen. The treatment of choice is broad-spectrum antibiotics and anticoagulation therapy. Quite frequently, the pain associated with ovarian vein thrombosis is confused with appendicitis, and exploratory laparotomy is undertaken.

Reference:

Basili G, Romano N, Bimbi M, et al. Postpartum ovarian vein thrombosis. *JSLS.* 2011;15(2):268–271.

۰۲۱-۶۶۱۹۸۵۱۴ www.myuptodate.com دریافت آخرین نسخه آپتودیت آفلاین

2M26

Key word: Treatment of Penile Cancer

Author: Isaac Howley, MD
Editor: Arthur L. Burnett, MD, MBA, FACS

A 63-year-old man presents to the emergency room with an exophytic 1.5-cm lesion on the glans of his uncircumcised penis. His physical examination is unremarkable except for the penile lesion; he has no palpable inguinal lymphadenectomy. Biopsy of the lesion reveals a grade 1, T1a squamous cell carcinoma without evidence of vascular, lymphatic, or perineural invasion. Which of the following is the most appropriate treatment strategy?

(A) Partial penectomy (i.e., amputation)

(B) Partial penectomy with superficial inguinal lymphadenectomy

(C) Topical therapy with imiquimod

(D) Wide local excision alone

(E) Wide local excision with sentinel lymph node biopsy

Answer: (D) Wide local excision alone

Rationale:
Partial penectomy is the gold standard for management of penile cancer, providing optimal local control of disease. However, it presents significant challenges to patient's sexual function and well-being and as such is reserved for locally advanced disease (i.e., grade 3 or 4 T1 lesions, or T2 to T4 lesions). A variety of less invasive treatment strategies have been studied for early stage lesions. Topical therapy with imiquimod or 5-fluorouracil is appropriate for carcinoma in situ only. Wide local excision, Mohs micrographic surgery, and laser ablation are all appropriate treatment strategies for low-grade, T1 lesions without clinical evidence of metastasis.

Squamous cell carcinoma of the penis nearly always metastasizes to regional lymph nodes before distant organs, and complete excision of lymphatic metastases is associated with long-term survival rates of 30% to 60%. Sentinel lymph node biopsy has a false-negative rate of approximately 10% by several series, with failures frequently progressing to metastatic disease and death, and as such is not a recommended procedure. Metastases progress in a well-defined order from superficial inguinal nodes to deep (to the fascia lata) inguinal nodes and then to pelvic nodes. Inguinal lymph node dissection for patients with T1 lesions is indicated only in the presence of clinically palpable nodes. Patients with T2 and more advanced primary lesions should undergo bilateral modified inguinal lymphadenectomy to complete their staging and remove potential local metastases.

Reference:
Pettaway CA, Lance RS, Davis JL. Tumors of the penis. In: Wein AJ, Kavoussi LR, Novick AC, Partin AW, Peters CA, eds. *Campbell-Walsh Urology.* 10th ed. Philadelphia, PA: Elsevier Saunders; 2012:901–933.

2M27

Key word: Clinical Features of Pituitary Tumors

Author: Kelly Olino, MD
Editor: Pamela A. Lipsett, MD, MHPE, FACS, FCCM

A 22-year-old woman is found to have headaches, lethargy, weight gain, amenorrhea, nausea, vomiting, and double vision. She undergoes a magnetic resonance image (MRI) of the head and is found to have a pituitary tumor 2.5 cm in size. Serum prolactin is measured and is found to be mildly elevated to 100 ng/mL. The best possible treatment for this patient will be:

(A) Estrogen treatment

(B) Stereotactic radiation therapy

(C) Surgical resection of the mass through a trans-sphenoidal approach

(D) Treatment with bromocriptine

(E) Treatment with cabergoline

Answer: (C) Surgical resection of the mass through a trans-sphenoidal approach

Rationale:
Pituitary tumors are classified by size, the presence of a clinical syndrome related to endocrine function, and the presence of neurologic symptoms caused by the tumor. Microadenomas are usually <1 cm in size and if functionally active will cause symptoms, while macroadenomas are larger (>1 cm) and cause symptoms due to mass effect. This can lead to symptoms of hypopituitarism and neurologic symptoms, as described above in this patient. Hormonally active pituitary tumors secrete prolactin, growth hormone, ACTH, TSH, or FSH/LH and cause infertility or amenorrhea, acromegaly, Cushing disease, hyperthyroidism, or hypogonadism, respectively.

Surgical treatment via trans-sphenoidal resection is the most frequent surgical approach for pituitary tumors, although a transfrontal approach is sometimes necessary for larger tumors. Radiation treatment is used as an adjuvant therapy following surgery in most cases.

In the patient described above, the tumor is causing mass effect leading to the observed symptoms. The mildly elevated prolactin level is caused by mass effect on the dopaminergic neurons traveling through the pituitary stalk, not by a prolactinoma. If the mass were a prolactinoma (see figure), prolactin levels would likely be much higher for a tumor of this size. Cabergoline and bromocriptine are treatment options for a prolactinoma, although trans-sphenoidal resection can often provide cure without the need for long-term treatment with these dopamine agonists.

۰۲۱-۶۶۱۹۸۵۱۴ www.myuptodate.com دریافت آخرین نسخه آپتودیت آفلاین

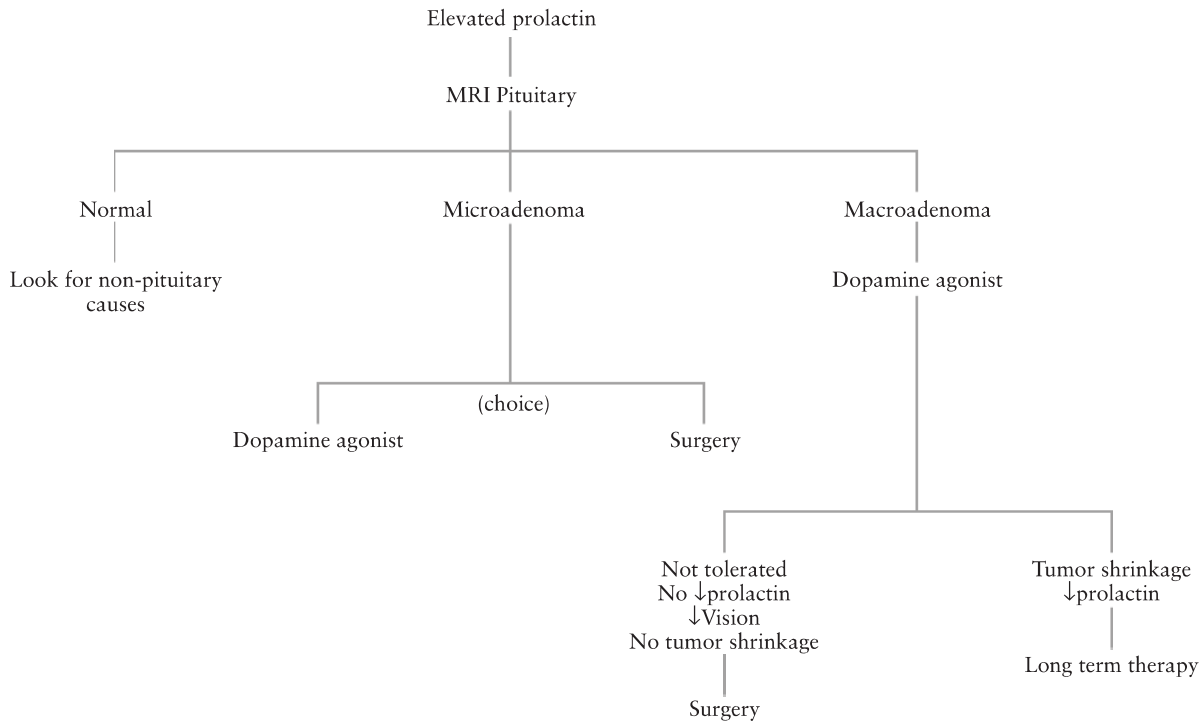

Diagnostic tests and treatment for hyperprolactinemia. Reprinted with permission from: Chandler WF, Barkan AL, Lloyd RV. Pituitary gland. In: Mulholland MW, Lillemoe KD, Doherty GM, Maier RV, Upchurch GR, eds. *Greenfield's Surgery: Scientific Principles & Practice*. 5th ed. Philadelphia, PA: Lippincott Williams & Wilkins, 2011:1354.

References:

Chandler WF, Barkan AL, Lloyd RV. Pituitary gland. In: Mulholland MW, Lillemoe KD, Doherty GM, Maier RV, Upchurch GR, eds. *Greenfield's Surgery: Scientific Principles & Practice.* 5th ed. Philadelphia, PA: Lippincott Williams & Wilkins; 2011.

Freda PU, Bruce JN. Tumors of the pituitary gland. In: Rowland LP, Pedley TA, eds. *Merritt's Neurology.* 12th ed. Philadelphia, PA: Lippincott, Williams & Wilkins; 2010:419–425.

۰۲۱-۶۶۱۹۸۵۱۴ www.myuptodate.com دریافت آخرین نسخه آپتودیت آفلاین

2M28

Key word: Treatment of Tongue Cancer

Author: Raja Mohan, MD
Editor: Anthony P. Tufaro, DDS, MD, FACS

A 65-year-old man who currently smokes two packs of cigarettes per day presents to clinic with a 0.6-mm ulcerated lesion on the side of his tongue. A biopsy reveals squamous cell carcinoma. After a thorough workup of the lesion, the patient's tumor stage is T1N0M0. What is the most appropriate management of this lesion?

(A) Chemotherapy
(B) Hemiglossectomy
(C) Radiation therapy
(D) Resection of lesion with 1-cm margins
(E) Total glossectomy

Answer: **(D)** Resection of lesion with 1-cm margins

Rationale:

The most common oral cavity cancer is squamous cell carcinoma of the tongue, and the two major risk factors are smoking and alcohol use. Tumors that are less than 2 cm (T1) should be resected with 1 to 2 cm margins. The 5-year survival rate is approximately 70% for stage I squamous cell carcinoma of the tongue. Neck dissections are reserved for patients with tumors >2 cm or those with clinically positive nodes. Postoperative radiotherapy is administered to those with advanced lesions (>2 cm, positive margins, or nerve/vascular/lymphatic invasion).

References:

Miller MC, Moyer JS, Teknos TN. Head and neck. In: Mulholland MW, Lillemoe KD, Doherty GM, Maier RV, Upchurch GR, eds. *Greenfield's Surgery: Scientific Principles & Practice.* 5th ed. Philadelphia, PA: Lippincott Williams & Wilkins; 2011.

Weinnberger PM, Terris DJ. Otolaryngology—head & neck surgery. In: Doherty GM, ed. *Current Diagnosis and Treatment: Surgery.* 13th ed. New York, NY: McGraw-Hill; 2010.

AJCC Staging Classification for Primary Tumors of the Oropharynx

Tx	Primary tumor cannot be assessed
T0	No evidence of primary tumor
T1	Tumor is 2 cm or less in greatest dimension
T2	Tumor is greater than 2 cm but less than or equal to 4 cm in greatest dimension
T3	Tumor is greater than 4 cm in greatest dimension
T4a	Tumor invades the larynx, deep/extrinsic muscle of tongue, medial pterygoid, hard palate, or mandible
T4b	Tumor invades the lateral pterygoid muscle, pterygoid plates, lateral nasopharynx, or skull base or encases carotid artery

Adapted from: Edge SB, Byrd DR, Compton CC, eds. *AJCC Cancer Staging Manual.* 7th ed. New York, NY: Springer, 2010.

AJCC Staging System for Cervical Lymph Node Metastases

Nx	Nodal status cannot be assessed
N0	No evidence of nodal metastases
N1	Single ipsilateral lymph node metastasis < or = 3 cm
N2a	Single ipsilateral lymph node metastasis >3 cm but <=6 cm
N2b	Multiple ipsilateral lymph node metastases, none greater than 6 cm
N2c	Any bilateral or contralateral lymph node metastases, none greater than 6 cm
N3	Any nodal metastasis greater than 6 cm

Adapted from: Edge SB, Byrd DR, Compton CC, eds. *AJCC Cancer Staging Manual.* 7th ed. New York, NY: Springer, 2010.

۰۲۱-۶۶۱۹۸۵۱۴ www.myuptodate.com دریافت آخرین نسخه آپتودیت آفلاین

2M29

Key word: Repair of Extraperitoneal Bladder Rupture

Author: Joshua H. Wolf, MD
Editor: Arthur L. Burnett, MD, MBA, FACS

A 22-year-old male driver in a high-speed collision is brought to the emergency room for evaluation. He is hemodynamically stable, has a Glasgow Coma Scale (GCS) score of 10, and on secondary survey is found to have blood oozing from his urethral meatus. A pelvic x-ray shows a type II pelvic fracture and a computed tomography (CT) cystogram shows extraperitoneal contrast extravasation and a bony fragment in the bladder. How should his bladder rupture be managed?

(A) Insertion of large bore Foley catheter and follow-up cystography in 14 days

(B) Open bladder repair using a posterior approach

(C) Open bladder repair using an anterior, intravesicular approach

(D) Open bladder repair using an anterior, intravesicular approach only if the patient is going to the operating room for laparotomy or internal fixation

(E) Transurethral cystoscopy to remove the bony fragment followed by Foley catheter decompression and a repeat cystogram in 2 weeks

Answer: (C) Open bladder repair using an anterior, intravesicular approach

Rationale:
Most cases of bladder rupture in blunt trauma result from rapid deceleration injury and are highly associated with pelvic fracture (83% to 95%). In cases of blunt trauma with uncomplicated extraperitoneal bladder rupture, patients may be managed conservatively with Foley catheter drainage and follow-up imaging. However, the presence of any complicating feature, such as an open pelvic fracture, concurrent rectal or vaginal injury, bony fragments projecting into the bladder, or bladder neck injury, carries an increased risk of complication (fistula, abscess, dehiscence) and is an indication to proceed with immediate repair. The repair is performed through the anterior wall of the bladder and with absorbable intravesicular sutures. If a patient with extraperitoneal bladder rupture will undergo laparotomy or internal fixation anyway, the bladder may be repaired at that time even in the absence of any complicating factors.

Reference:
Morey AF, Dugi DD. Genital and lower urinary tract trauma. In: Wein AJ, Kavoussi LR, Novick AC, Partin AW, Peters CA, eds. *Campbell-Walsh Urology.* 10th ed. Philadelphia, PA: Elsevier Saunders; 2011:2513–2516.

2M30

Key word: Treatment of Postoperative Parotitis

Author: Kyle J. Van Arendonk, MD, PhD
Editor: Pamela A. Lipsett, MD, MHPE, FACS, FCCM

An 82-year-old is admitted from the nursing home with a small bowel obstruction that subsequently fails to resolve with conservative measures. After an exploratory laparotomy and lysis of adhesions, his postoperative course is complicated by a prolonged ileus requiring continued nasogastric decompression. Nine days after surgery, he reports pain and tenderness of his right jaw. He is febrile, and you note minor swelling of his right parotid gland without fluctuance. Which of the following is the most appropriate next step in management?

(A) Anticholinergic medications

(B) Immediate incision and drainage

(C) Initiate intravenous antibiotics

(D) Replace nasogastric tube with orogastric tube

(E) Urgent tracheostomy for airway protection

Answer: (C) Initiate intravenous antibiotics

Rationale:
Postoperative parotitis occurs most commonly in elderly patients with poor oral hygiene, poor oral intake and thus decreased saliva production, and prolonged nasogastric tube placement. This condition most commonly presents in the second postoperative week and results from inspissated parotid secretions that become infected, most commonly with *Staphylococcus,* and can progress to form multiple small abscesses if untreated. If not properly treated, these abscesses can even spread beyond the gland into the neck and mouth to cause sepsis and respiratory compromise. Patients initially present with pain, swelling, and/or tenderness at the angle of the jaw; fever, leukocytosis, and parotid erythema and fluctuance can appear as the disease progresses.

The risk of postoperative parotitis can be decreased by increasing fluid intake, avoiding the use of anticholinergics (which decrease salivary flow), maintaining adequate oral hygiene (mouth washes, etc.), and stimulating salivary flow (sour candy, lemon drops, etc.). These simple measures have greatly decreased the frequency of this postoperative complication. When parotitis is identified, prompt initiation of broad-spectrum intravenous antibiotics is indicated. Culture of fluid obtained from Stensen duct with compression of the parotid gland can be used to guide further antibiotic coverage. If parotitis progresses, which is rare if antibiotics are initiated early, incision and drainage of fluctuant areas may be required. If airway compromise ensues, emergency tracheostomy could even be required.

۰۲۱-۶۶۱۹۸۵۱۴ www.myuptodate.com دریافت آخرین نسخه آپتودیت آفلاین

References:
Doherty GM. Postoperative complications. In: Doherty GM, ed. *Current Diagnosis & Treatment: Surgery.* 13th ed. New York, NY: McGraw-Hill; 2010. http://www.accessmedicine.com/content.aspx?aID=5211288. Accessed May 24, 2013.
Kulaylat MN, Dayton MT. Surgical complications. In: Townsend CM, Beauchamp RD, Evers BM, Mattox KL, eds. *Sabiston Textbook of Surgery.* 19th ed. Philadelphia, PA: Saunders Elsevier; 2012:325.

2M31

Key word: Significance of Actinic Keratosis

Author: Joshua C. Grimm, MD
Editor: Lisa K. Jacobs, MD

An 81-year-old female with a history of sun exposure presents to her dermatologist for evaluation of some vascular lesions covered by a thin, red scale on her left hand and arm. Which of the following is true regarding this diagnosis?



Multiple hyperkeratotic tumors over the extensor forearm in a renal transplant patient. Frequent observation, aggressive therapy, and biopsy when necessary are needed to control these premalignant tumors. Reprinted with permission from: Olasz EB, Neuburg M. Skin disease in transplant patients. In: Hall BJ, Hall JC, eds. *Sauer's Manual of Skin Diseases.* 10th ed. Philadelphia, PA: Lippincott Williams & Wilkins, 2010:467.

(A) Lesions can be diagnosed as frank squamous cell carcinoma based on the clinical appearance of thickness, redness, and ulceration

(B) Lesions typically extend beyond the epidermis

(C) Surgical management is the treatment of choice for isolated, superficial lesions

(D) These lesions are more common in patients with a history of transplantation

(E) These lesions are uniformly benign

Answer: **(D)** These lesions are more common in patients with a history of transplantation

Rationale:
Actinic keratosis is a precursor of squamous cell carcinoma (SCC) that is confined to the epidermis. It is common in individuals with exposure to the sun and incidence increases with age. The presence and progression of actinic keratosis lesions to SCC is accelerated in transplant recipients and other immunosuppressed individuals; therefore, heightened awareness is warranted. Thickened, erythematous, and oozing lesions are suggestive of malignant transformation, but a definitive diagnosis cannot be made without a biopsy. In nonimmunosuppressed patients, small, superficial actinic keratoses may undergo spontaneous remission and therefore can

۰۲۱-۶۶۱۹۸۵۱۴ www.myuptodate.com دریافت آخرین نسخه آپتودیت آفلاین

be managed with careful observation. If there is concern, by either the physician or the patient, small lesions are usually treated with cryotherapy. Individuals with thickened, crusted lesions should undergo surgical excision.

Reference:

Habif TP. Premalignant and malignant nonmelanoma skin tumors. In: *Clinical Dermatology.* 5th ed. London: Elsevier; 2010:812–819.

2M32

Key word: Urinary Stones after Ileal Resection

Author: Jens U. Berli, MD
Editor: Arthur L. Burnett, MD, MBA, FACS

A 36-year-old woman with a history of multiple ileal resections presents to the emergency room with acute onset of flank pain. She is restless and diaphoretic on arrival. Except for tachycardia, her vital signs are unremarkable. You suspect a diagnosis of urolithiasis. What is the most likely pathophysiologic mechanism leading to this diagnosis?

(A) Hypercalciuria
(B) Hyperoxaluria
(C) Hyperuricosuria
(D) Low fluid intake
(E) Type I renal tubular acidosis

Answer: (B) Hyperoxaluria

Rationale:

Short gut leads to several physiologic changes including hyperoxaluria. Oxalate is an insoluble molecule that is generated during metabolism and is also abundant in nutrition. Oxalate is excreted by the kidneys in the proximal tubule. Oxalate absorption in the bowel is limited by its binding to calcium. In cases of short bowel with chronic diarrhea and steatorrhea, calcium preferentially binds to fatty acids. As a result, more oxalate is absorbed, which in turn leads to hyperoxaluria. The formation of calcium oxalate stones is further promoted by low urine output due to dehydration (usually due to increased fluid loss rather than low intake).

Hyperuricosuria is a condition associated with increased cell turnover or defects in purine metabolism. Renal tubular acidosis is not associated with short gut syndrome. Eighty percent of renal stones are calcium stones, and calcium oxalate stones are the most frequent calcium stones. Other stone types include calcium phosphate, uric acid, struvite (magnesium ammonium phosphate), and cystine stones. Other conditions associated with short gut syndrome include dehydration, gallstone formation (disruption in enterohepatic circulation of bile acids), electrolyte deficiencies, anemia, and malnutrition.

References:

Canos HJ, Hogg GA, Jeffery JR. Oxalate nephropathy due to gastrointestinal disorders. *Can Med Assoc J.* 1981;124(6): 729–733.

Evers BM. Small intestine. In: Townsend CM, Beauchamp RD, Evers MB, Mattox KL, eds. *Sabiston Textbook of Surgery: the biological basis of modern surgical practice.* 18th ed. Philadelphia, PA: Saunders Elsevier; 2008:1328–1330.

Olumi AF, Richie JP. Urologic surgery. In: Townsend CM, Beauchamp RD, Evers MB, Mattox KL, eds. *Sabiston Textbook of Surgery: the biological basis of modern surgical practice.* 18th ed. Philadelphia, PA: Saunders Elsevier; 2008:2267–2269.

Stoller ML. Urinary stone disease. In: Tanagho EA, McAninch JW, eds. *Smith's General Urology.* 17th ed. New York, NY: McGraw-Hill; 2011:246–278.

۰۲۱-۶۶۱۹۸۵۱۴ www.myuptodate.com دریافت آخرین نسخه آپتودیت آفلاین

2M33

Key word: Urine Concentrations with Aldosterone-secreting Tumors

Author: Joshua C. Grimm, MD
Editor: Mehran Habibi, MD, MBA

A 48-year-old male with a history of hypertension poorly controlled with several agents presents to his primary care physician for regular follow-up. He complains of persistent headaches, waking up several times throughout the night to urinate, and fatigue that increases throughout the day. A computed tomography (CT) scan shows a right-sided 1.3-cm retroperitoneal mass. His serum potassium level is 2.8 mmol/L. What other findings are consistent with this disease?

(A) 24-hour urine aldosterone levels <14 μg after saline loading

(B) Enhanced ability of the kidney to produce concentrated urine

(C) Neutral to alkaline urinary pH

(D) Serum pH <7.25

(E) Symptomatic hypernatremia

Answer: (C) Neutral to alkaline urinary pH

Rationale:
Primary hyperaldosteronism is found in approximately 1% of patients with hypertension. Clinically, patients present with hypokalemia manifesting as fatigue, polyuria, polydipsia, headaches, and hypertension, including diastolic hypertension, after having failed treatment with three or more agents. Most cases involve a unilateral mass producing high levels of aldosterone. A plasma aldosterone:renin ratio >20 is virtually diagnostic. Renin levels are suppressed due to the feedback inhibition of renin release by the juxtaglomerular cells located in the afferent arteriole. A 24-hour urine aldosterone level after saline loading is elevated (>14 μg) due to the kidney's persistent unresponsiveness to salt levels. Classically, potassium levels are described as being lower than normal as aldosterone promotes potassium secretion in the kidney. Recently, however, studies have shown that potassium levels can also be normal at the time of diagnosis.

In order to retain some potassium, a sodium/hydrogen antiporter is activated, resulting in increased losses of hydrogen ions and concomitant hypokalemic metabolic alkalosis (K^+ is also exchanged at a cellular level for H^+, leading to intracellular acidosis). The urine is usually neutral to alkaline due to compensatory ammonium and bicarbonate excretion. Hypernatremia is unusual due to the volume expansion that accompanies increased sodium reabsorption.

Effects of Aldosterone Secretion

Tubular Action	Normal Amounts	Excessive Amounts
Increased resorption of sodium	Protects against low-volume states	Hypertension
		Positive sodium balance
		Hyporeninemia
Decreased resorption of potassium	Protects against hyperkalemia	Hypokalemia
		Metabolic alkalosis
		Hyperglycemia
		Nocturia, polyuria
		Muscle weakness

Reprinted with permission from: Olson JA, Scheri RP. Adrenal gland. In: Mulholland MW, Lillemoe KD, Doherty GM, Maier RV, Upchurch GR, eds. *Greenfield's Surgery: Scientific Principles & Practice*. 5th ed. Philadelphia, PA: Lippincott Williams & Wilkins, 2011:1329.

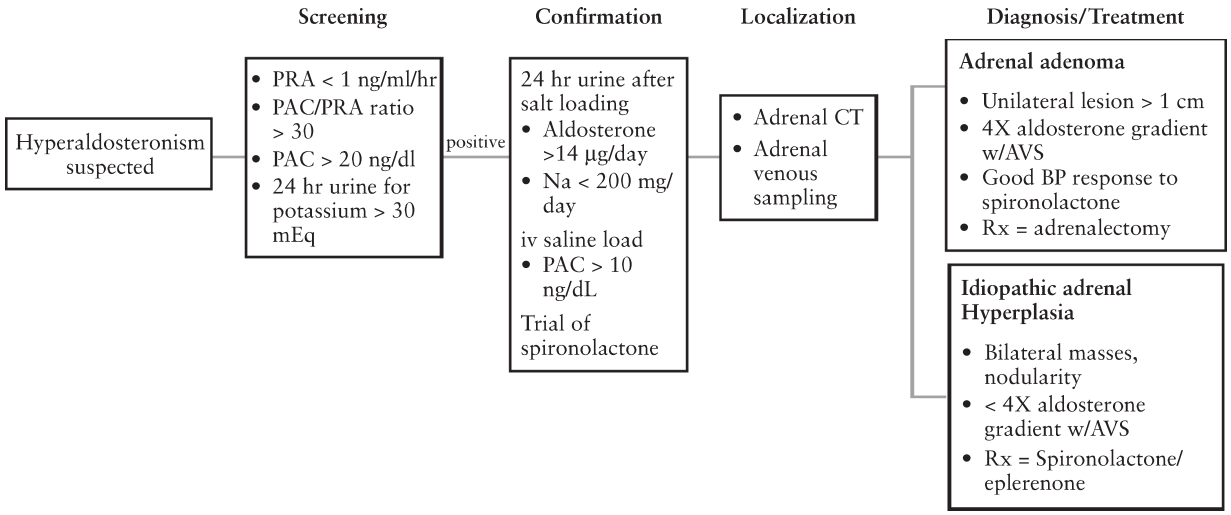

Diagnosis and management of hyperaldosteronism. PRA, plasma renin activity; PAC, plasma aldosterone concentration; CT, computed tomography; AVS, bilateral adrenal venous sampling. Reprinted with permission from: Olson JA, Scheri RP. Adrenal gland. In: Mulholland MW, Lillemoe KD, Doherty GM, Maier RV, Upchurch GR, eds. *Greenfield's Surgery: Scientific Principles & Practice*. 5th ed. Philadelphia, PA: Lippincott Williams & Wilkins, 2011:1333.

۰۲۱-۶۶۱۹۸۵۱۴ www.myuptodate.com دریافت آخرین نسخه آپتودیت آفلاین

References:
Olson JA Jr, Scheri RP. Adrenal gland. In: Mulholland MW, Lillemoe KD, Doherty GM, Maier RV, Upchurch GR, eds. *Greenfield's Surgery: Scientific Principles & Practice.* 5th ed. Philadelphia, PA: Lippincott Williams & Wilkins; 2011.
Williams GH, Dluhy RG. Disorders of the adrenal cortex. In: Jameson JL, ed. *Harrison's Endocrinology.* 2nd ed. New York, NY: McGraw-Hill; 2010:117–119.

2M34

Key Word: Antihypertensive Drug Associated with Chronic Cough

Author: Andrew P. Dhanasopon, MD
Editor: Robert A. Meguid, MD, MPH

A 62-year-old woman of Asian descent is seen in clinic for a 2-week history of a dry, hacking cough. She was recently diagnosed with hypertension and has been sequentially started on a multidrug regimen including metoprolol, lisinopril, amlodipine, and clonidine. Increased levels of which of the following is thought to contribute to the dry, hacking cough caused by one of these medications?

(A) Angiotensin I
(B) Angiotensin II
(C) Angiotensinogen
(D) Bradykinin
(E) Renin

Answer: (D) Bradykinin

Rationale:
Angiotensin-converting enzyme (ACE) inhibitors such as lisinopril have been implicated as the cause of a dry, hacking cough seen in about 5% to 35% of patients taking these medications. ACE inhibitors prevent the conversion of angiotensin I to angiotensin II; however, they also prevent degradation of bradykinin. Bradykinin-induced sensitization of airway sensory nerves is thought to be a potential mechanism of ACE inhibitor-induced cough.

Reference:
Dicpinigaitis PV. Angiotensin-converting enzyme inhibitor-induced cough: ACCP evidence-based clinical practice guidelines. *Chest.* 2006;129(1):169S–173S.

۰۲۱-۶۶۱۹۸۵۱۴ www.myuptodate.com دریافت آخرین نسخه آپتودیت آفلاین

5
ENDOCRINE, HEMATIC, LYMPHATIC, AND BREAST

CONTENTS:

Number:	Key Word:	Page:
2E01	Diagnosis of Division of Intercostobrachial Nerve	474
2E02	Diagnosis of Intraoperative Nerve Injury	474
2E03	Diagnostic Test for Recurrence of ITP	475
2E04	Diagnostic Test for a Tender Breast Mass	475
2E05	Findings of Acute Adrenal Insufficiency	476
2E06	Findings in Vitamin D Deficiency	476
2E07	Indications for Excisional Biopsy of Breast Mass	477
2E08	Initial Treatment of Adrenal Mass	478
2E09	Most Common Nerve Injured during Total Thyroidectomy	479
2E10	Operative Approach to Splenectomy	480
2E11	Pathologic Diagnosis of High-risk Breast Cancer	481
2E12	Treatment of Breast Cancer with Negative Sentinel Lymph Node Biopsy	481
2E13	Treatment of an Incidental Adrenal Mass	482
2E14	Treatment of Invasive Ductal Breast Cancer	484
2E15	Treatment of Medullary Thyroid Cancer	484
2E16	Treatment of Papillary Thyroid Cancer with Lymph Node Metastases	485
2E17	Treatment of Parathyroid Hyperplasia	486
2E18	Treatment of Lymphoma of the Small Bowel	486
2E19	Treatment of Toxic Nodular Goiter	487
2E20	Treatment of Thyroiditis during Pregnancy	488
2E21	Treatment of Thyroid Crisis	488
2E22	Diagnosis of Lymphangiosarcoma	489
2E23	Characteristics of Glucagonoma	489
2E24	Diagnostic Test for Pituitary Tumor	490
2E25	Treatment of Hypercalcemic Crisis	491
2E26	Blood Supply of Latissimus Dorsi Myocutaneous Flap	491
2E27	Etiology of Impaired Glucose in Type II Diabetes	492
2E28	Impairment of PTH Production	492
2E29	Phosphorus Level in Hyperparathyroidism	493
2E30	Components of ACTH Stimulation Test	493
2E31	Conditions Associated with the Zollinger–Ellison Syndrome	494
2E32	Hormone Excess in Male Breast Enlargement	495

۰۲۱-۶۶۱۹۸۵۱۴ www.myuptodate.com دریافت آخرین نسخه آپتودیت آفلاین

2E01

Key word: Diagnosis of Division of Intercostobrachial Nerve

Author: Vicente Valero III, MD
Editor: Bradford D. Winters, MD, PhD

A 62-year-old woman presents to your clinic after undergoing a left modified radical mastectomy for stage III breast carcinoma. She has done well postoperatively and is concerned only about new onset numbness and tingling over the posteromedial aspect of her left upper arm. She has normal strength, no motor deficits, and normal range of motion in her left upper extremity. What structure was likely injured during her operation?

(A) Intercostobrachial nerve
(B) Long thoracic nerve of Bell
(C) Medial cutaneous nerve of arm
(D) Medial pectoral nerve
(E) Thoracodorsal nerve

Answer: (A) Intercostobrachial nerve

Rationale:
The intercostobrachial nerve is a lateral cutaneous branch of the second intercostal nerve arising from T2. It supplies sensation for the posteromedial portion of the upper arm. This nerve is at risk of injury during the axillary lymph node dissection (ALND) portion of a modified radical mastectomy. The course of the intercostobrachial nerve can be traced as it penetrates through the intercostal muscles and the serratus anterior in the midaxillary line. It subsequently traverses the axilla where the posterior branch provides sensation to the posterior axillary fold and then travels into the upper arm. It is important to preserve this nerve during ALND in order to prevent postoperative paresthesias and sensory deficits in the ipsilateral upper arm. A small prospective study demonstrated that preservation of the intercostobrachial nerve increases operative time by a median time of 5 minutes. Due to the variable anatomy associated with the intercostobrachial nerve and the overall sensory supply to the axilla and the upper arm, sensory abnormalities following ALND can still occur despite preservation of the intercostobrachial nerve. It should also be noted that this nerve might need to be sacrificed in some patients in order to achieve a satisfactory oncologic specimen with adequate nodal tissue.

References:
Abdullah TI, Iddon J, Barr L, et al. Prospective randomized controlled trial of preservation of the intercostobrachial nerve during axillary node clearance for breast cancer. *Br J Surg.* 1998;85(10):1443–1445.
Freeman SR, Washington SJ, Pritchard T, et al. Long term results of a randomised prospective study of preservation of the intercostobrachial nerve. *Eur J Surg Oncol.* 2003; 29(3):213–215.
Loukas M, Hullett J, Louis RG Jr, et al. The gross anatomy of the extrathoracic course of the intercostobrachial nerve. *Clin Anat.* 2006;19(2):106–111.

2E02

Key word: Diagnosis of Intraoperative Nerve Injury

Author: Seth D. Goldstein, MD
Editor: Bradford D. Winters, MD, PhD

A 58-year-old woman with biopsy-proven papillary thyroid carcinoma and clinically involved right cervical lymph nodes undergoes total thyroidectomy and right modified radical neck dissection. On the first morning postoperatively, a focused clinical examination should include an assessment of which of the following?

(A) Grip strength
(B) Hand sensation
(C) Plantar flexion
(D) Shoulder shrug
(E) Tongue protrusion

Answer: (D) Shoulder shrug

Rationale:
Radical neck dissection is the en bloc removal of all nodal groups with surrounding structures between the mandible and the clavicle. Modified radical neck dissection attempts the same node removal while sparing the sternocleidomastoid muscle, the internal jugular vein, and the spinal accessory nerve (cranial nerve XI). The spinal accessory nerve runs through the operative field and is at risk for injury. Its function can be assessed by examining the range of motion and strength of the ipsilateral sternocleidomastoid and trapezius muscles. Intraoperative nerve injury affecting grip strength and hand sensation (brachial plexus), tongue protrusion (hypoglossal nerve, cranial nerve XII), or plantar flexion (tibial nerve via sciatic) would not be expected.

Reference:
Mandpe AH. Neck neoplasms and neck dissection. In: Lalwani AK, ed. *Current Diagnosis & Treatment in Otolaryngology–Head & Neck Surgery.* 3rd ed. New York, NY: McGraw-Hill; 2012.

۰۲۱-۶۶۱۹۸۵۱۴ www.myuptodate.com دریافت آخرین نسخه آپتودیت آفلاین

2E03

Key word: Diagnostic Test for Recurrence of ITP

Author: Seth D. Goldstein, MD
Editor: F. Dylan Stewart, MD, FACS

A 15-year-old boy presents 1 year following laparoscopic splenectomy for idiopathic thrombocytopenic purpura (ITP). He reports spontaneous massive epistaxis and is found to have a platelet count of 10,000/μL. In addition to a complete blood count, which of the following is the most helpful initial study to send based on his past history?

(A) Bone marrow aspirate
(B) Partial thromboplastin time
(C) Peripheral blood smear for eosinophils
(D) Peripheral blood smear for Howell–Jolly bodies
(E) Prothrombin time

Answer: (D) Peripheral blood smear for Howell–Jolly bodies

Rationale:
Idiopathic (or immune) thrombocytopenic purpura (ITP) can be acute or chronic. Acute ITP occurs mostly in children; often follows a viral infection; has an excellent prognosis, with most cases resolving spontaneously without treatment; and is the most common type of ITP. Chronic ITP occurs mostly in adults, affects women more often than men, and only rarely resolves spontaneously.

Splenectomy is indicated for ITP refractory to medical management, usually corticosteroids and intravenous immunoglobulin (IVIG), and is efficacious in almost two-thirds of patients. A laparoscopic approach may result in a faster hospital recovery, but controversy exists regarding whether open surgery may more effectively allow for scrutiny of an accessory spleen. Howell–Jolly bodies are histologic findings of asplenia on peripheral blood smear. If Howell–Jolly bodies appeared initially after surgery but are no longer present, an accessory spleen is suspected. Resection of an accessory spleen for recurrent ITP is still controversial due to a lack of strong evidence for its efficacy. Bone marrow aspirate can be checked to rule out an inappropriate initial diagnosis, but peripheral blood smear would still be the first laboratory test performed. A complete history again to look for possible drug-related thrombocytopenia or a new diagnosis of HCV or HIV is also indicated.

Reference:
Fraker DL. Spleen. In: Doherty GM, ed. *Current Diagnosis & Treatment: Surgery.* 13th ed. Columbus, OH: The McGraw-Hill Companies, Inc; 2010.

2E04

Key word: Diagnostic Test for a Tender Breast Mass

Author: Seth D. Goldstein, MD
Editor: Lisa K. Jacobs, MD

A 25-year-old woman presents with a breast mass found on self-examination. A 3-cm tender mass is palpable in the upper outer quadrant of the right breast with no overlying skin changes. The patient has no medical history and takes only an oral contraceptive pill. What is the most appropriate initial imaging modality?

(A) Computed tomography (CT)
(B) Magnetic resonance imaging (MRI)
(C) Mammogram
(D) Positron emission tomography (PET)
(E) Ultrasound

Answer: (E) Ultrasound

Rationale:
Assessment of a breast mass should include clinical examination, imaging, and biopsy. In women under 30, ultrasound is the recommended *initial* imaging modality. Ultrasound can differentiate between solid and cystic masses and can also guide fine-needle aspiration. In this younger age group, mammography is less useful even with the use of digital subtraction technology due to the higher breast density. MRI is highly sensitive but is not used for screening, while PET would only be used for suspicion of metastatic disease.

Reference:
Laronga C, Tollin S, Turaga KK. History, physical examination, and staging. In: Kuerer HM, ed. *Kuerer's Breast Surgical Oncology.* New York, NY: McGraw-Hill; 2010.

۰۲۱-۶۶۱۹۸۵۱۴ www.myuptodate.com دریافت آخرین نسخه آپتودیت آفلاین

2E05

Key word: Findings of Acute Adrenal Insufficiency

Author: Kelly Olino, MD
Editor: Bradford D. Winters, MD, PhD

An otherwise healthy 52-year-old male is in the postoperative care unit hours after undergoing an uncomplicated left-sided laparoscopic adrenalectomy for a 0.5-cm cortisol-producing tumor when he is noted to have a heart rate of 82 beats per minute and blood pressure of 90/40 mm Hg. After administering 2 L of normal saline, the blood pressure is unchanged. The most critical next step in management will be to:

(A) Administer 100-mg IV hydrocortisone

(B) Begin a norepinephrine drip

(C) Check troponin levels

(D) Obtain a 12-lead EKG

(E) Obtain a portable chest x-ray

Answer: (A) Administer 100-mg IV hydrocortisone

Rationale:
Hypotension following abdominal surgery is a common complication encountered in the recovery room. A cortisol-producing tumor leads to suppression of the hypophyseal–pituitary–adrenal axis, and the contralateral adrenal gland is usually atrophied and poorly functional as a result. Suppression of the hypophyseal–pituitary–adrenal axis may last up to a year after surgery. Following the resection of a cortisol-producing tumor, perioperative corticosteroids are therefore required, followed by corticosteroid replacement for several weeks after surgery. In this example, all of the other choices are viable options and should be part of the differential workup, but if steroids are not administered, the hypotension from acute adrenal insufficiency will not resolve.

Reference:
Gauger PG. Complications of adrenal surgery. In: Mulholland MW, Doherty GM, eds. *Complications in Surgery.* Philadelphia, PA: Lippincott, Williams & Wilkins; 2006:535–549.

2E06

Key word: Findings in Vitamin D Deficiency

Author: Kelly Olino, MD
Editor: Elizabeth C. Wick, MD

A 55-year-old postmenopausal woman is found to have osteoporosis and joint and muscle aches 1 year following roux-en-Y gastric bypass surgery and a 68 kg (150 lb) weight loss from her preoperative weight of 163 kg (360 lb). During workup for her condition she is noted to have a calcium level of 7.8 mg/dL. Further laboratory analysis will likely show the following:

(A) PTH = 20 pg/mL, Vitamin D = 15 ng/mL, Phosphate = 3.5 mg/dL

(B) PTH = 25 pg/mL, Vitamin D = 20 ng/mL, Phosphate = 3.5 mg/dL

(C) PTH = 100 pg/mL, Vitamin D = 15 ng/mL, Phosphate = 3.5 mg/dL

(D) PTH = 100 pg/mL, Vitamin D = 15 ng/mL, Phosphate = 6 mg/dL

(E) PTH = 100 pg/mL, Vitamin D = 30 ng/mL, Phosphate = 3.5 mg/dL

Answer: (C) PTH = 100 pg/mL, Vitamin D = 15 ng/mL, Phosphate = 3.5 mg/dL

Rationale:
The patient has secondary hyperparathyroidism due to vitamin D deficiency. The gastric bypass procedure leads to a lack of vitamin D absorption through both the functional partial gastrectomy and the malabsorption caused by the roux limb bypass. With vitamin D deficiency, the calcium level is usually normal, the PTH level is elevated, both vitamin D and 25-OH Vitamin D levels are low, and the phosphate level is normal. Only choice **(C)**, therefore, has laboratory findings consistent with secondary hyperparathyroidism. Vitamin D deficiency is usually asymptomatic but can also manifest in children in the form of rickets or in elderly patients in the form of osteomalacia with concomitant muscle and bony aches.

Reference:
Johnson JM, Maher JW, DeMaria EJ, et al. The long-term effects of gastric bypass on vitamin D metabolism. *Ann Surg.* 2006;243(5):701–704.

۰۲۱-۶۶۱۹۸۵۱۴ www.myuptodate.com دریافت آخرین نسخه آپتودیت آفلاین

2E07

Key word: Indications for Excisional Biopsy of Breast Mass

Author: Seth D. Goldstein, MD
Editor: Lisa K. Jacobs, MD

A 47-year-old woman presents with a palpable breast mass discovered on self-examination. Mammography demonstrates a Breast Imaging-Reporting and Data System (BI-RADS) 4 lesion found to be a 2-cm spiculated mass with heterogeneous calcifications. Core-needle biopsy is read as atypia without malignant features. The best next step would be the following:

(A) Excisional biopsy

(B) Incisional biopsy

(C) Mastectomy

(D) Repeat needle biopsy

(E) Surveillance with yearly mammography

Answer: (A) Excisional biopsy

Rationale:

Needle biopsy is generally sufficient to guide surgical management of a breast mass. Exceptions are tumors that cannot be biopsied (e.g., subareolar, posterior position in a large breast) and when discordance exists between biopsy results and other clinical findings. Lesions with a high level of radiologic suspicion (BI-RADS 4 or 5) are usually evaluated first by using a core-needle biopsy, which is typically diagnostic. However, in this case, benign findings from the biopsy do not match well with the level of radiologic suspicion (BI-RADS 4), which indicates a high likelihood of malignancy. Given this degree of discordance, the biopsy may represent a false negative due to sampling error, necessitating the use of excisional biopsy for ultimate diagnosis.

BI-RADS Classification of Mammographic Abnormalities

Category	Assessment	Recommendation
1	Negative	Routine screening
2	Benign finding	Routine screening
3	Probably benign finding	Short-interval follow-up
4	Suspicious abnormality	Definite probability of malignancy; consider biopsy
5	Highly suggestive of malignancy	High probability of cancer; appropriate action should be taken

BI-RADS, breast imaging reporting and data system.

Reprinted with permission from: King TA, Morrow M. Breast disease. In: Mulholland MW, Lillemoe KD, Doherty GM, Maier RV, Upchurch GR, eds. *Greenfield's Surgery: Scientific Principles & Practice*. 5th ed. Philadelphia, PA: Lippincott Williams & Wilkins, 2011:1247.

References:

King TA, Morrow M. Breast disease. In: Mulholland MW, Lillemoe KD, Doherty GM, Maier RV, Upchurch GR, eds. *Greenfield's Surgery: Scientific Principles and Practice.* 5th ed. Philadelphia, PA: Lippincott Williams and Wilkins; 2011.

Montgomery L. Excisional breast biopsy. In: Kuerer HM, ed. *Kuerer's Breast Surgical Oncology.* New York, NY: McGraw-Hill; 2010.

۰۲۱-۶۶۱۹۸۵۱۴ www.myuptodate.com دریافت آخرین نسخه آپتودیت آفلاین

2E08

Key word: Initial Treatment of Adrenal Mass

Author: Kelly Olino, MD
Editor: Richard D. Schulick, MD, MBA, FACS

A 56-year-old woman is found to have a 2-cm mass in her left adrenal gland following an abdominal computed tomography (CT) scan performed following a motor vehicle collision. Which of the following is the best next step in management of this adrenal mass?

(A) Laparoscopic adrenalectomy

(B) Mammography

(C) Measurement of adrenocorticotropic hormone (ACTH) level, 24-hour urine-free cortisol level, urine metanephrine level, and calculate an aldosterone/renin ratio

(D) Metaiodobenzylguanidine (MIBG) scan

(E) Observation with repeat abdominal CT scan in 1 year

Answer: (C) Measurement of adrenocorticotropic hormone (ACTH) level, 24-hour urine-free cortisol level, urine metanephrine level, and calculate an aldosterone/renin ratio

Rationale:

An adrenal incidentaloma is a lesion greater than 1 cm found by coincidence on a radiographic study done for other reasons. The prevalence of incidentalomas ranges from 1% to 10% and rises with increasing age. The differential diagnosis of an adrenal incidentaloma includes aldosteronoma, pheochromocytoma, cortisol-producing tumor, sex hormone–secreting tumor, metastasis, nonfunctional adenoma/myelolipoma, and adrenocortical carcinoma.

The first step in management is to perform a thorough history and physical examination looking for hypertension or a change in the number of blood pressure medications, hirsutism, weight changes, headaches, flushing, palpitations, or a personal or family history of malignancy or genetic syndromes. Laboratory evaluation is also necessary to rule out the presence of a functional cortisol-secreting mass, and is performed by measuring an ACTH level and a 24-hour urine-free cortisol level or performing a 1-mg overnight dexamethasone suppression test with a morning cortisol level drawn. A pheochromocytoma workup should include urine or plasma metanephrines and normetanephrines. Aldosteronoma workup consists of measuring serum potassium and the serum aldosterone/renin ratio. Sex hormone–secreting tumors are rare, but testosterone or dehydroepiandrosterone (DHEA) levels can be measured if clinical symptoms are present.

Radiographic imaging with triple phase CT imaging or MRI is a useful adjunct as well. Nonfunctional adrenocortical adenomas on triple phase CT scan will measure <10 Hounsfield units (HU) on dry scan and have >50% washout after 10 minutes on delayed phase. Adrenocortical carcinomas are usually >4 cm, irregular, hypervascular, and >10 HU and have <50% washout; they can also have hemorrhage, calcification, or necrosis. Pheochromocytomas are regular, hypervascular, and >10 HU and have <50% washout. They are characteristically hyperintense on T_2-weighted MRI. Aldosteronomas are usually smaller masses, and careful attention has to be made to ensure that bilateral adrenal hyperplasia is not present. Metastases can be bilateral, and radiographic findings associated with primary cancers (especially lung, breast, stomach, kidney, melanoma, and lymphoma) should be sought. Indications for adrenalectomy include a functional adrenal mass, size >4 cm or other features indicative of adrenocortical carcinoma, and an interval increase in size >1 cm.

Reference:

Zeiger MA, Thompson GB, Duh QY, et al. American Association of Clinical Endocrinologists and American Association of Endocrine Surgeons Medical Guidelines for the Management of Adrenal Incidentalomas: executive summary of recommendations. *Endocr Pract.* 2009;15(5):450–453.

Summary of Tests for Evaluation of Incidental Adrenal Mass

Question	Best Test	Alternative Test	Diagnosis
Is it functioning?	Plasma fractionated metanephrines	24-h urine for catecholamines, metanephrines, VMA	Pheochromocytoma
	- mg dexamethasone suppression test	24-h urine for cortisol	Hypercortisolism
	Serum potassium	24-h urine for potassium	Hyperaldosteronism
	Plasma renin/plasma aldosterone ratio		
Is it malignant?	Computed tomography	Magnetic resonance imaging	Cortical adenoma
			Adrenocortical Carcinoma
			Pheochromocytoma
			Myelolipoma
			Cyst
	Fine-needle aspiration		Metastasis

Reprinted with permission from: Olson JA, Scheri RP. Adrenal gland. In: Mulholland MW, Lillemoe KD, Doherty GM, Maier RV, Upchurch GR, eds. *Greenfield's Surgery: Scientific Principles & Practice*. 5th ed. Philadelphia, PA: Lippincott Williams & Wilkins, 2011:1340.

۰۲۱-۶۶۱۹۸۵۱۴ www.myuptodate.com دریافت آخرین نسخه آپتودیت آفلاین

2E09

Key word: Most Common Nerve Injured during Total Thyroidectomy

Author: Jacqueline Garonzik-Wang, MD, PhD
Editor: Alan P.B. Dackiw, MD, PhD, BSc, BSc(Med), FACS, FRCSC

After an uneventful total thyroidectomy, a 58-year-old female is found to have a weak voice and difficulty coughing in the recovery room. She is hemodynamically stable with 95% saturation on 2 L oxygen via nasal canal. Her examination is unremarkable, and her wound is intact without drainage or evidence of a hematoma. Direct laryngoscopy is performed at the bedside, and her right vocal cord is noted to be in a fixed position. What is the most likely cause of her symptoms?

(A) Complete transection of the right recurrent laryngeal nerve (RLN)

(B) Compression from a submuscular bleed and hematoma

(C) Stretch injury to the right RLN

(D) Transection of the external branch of the superior laryngeal nerve (EBSLN)

(E) Trauma secondary to endotracheal intubation

Answer: (C) Stretch injury to the right RLN

Rationale:
Total thyroidectomy has become the preferred treatment for thyroid cancer, especially for lesions larger than 1 cm. Nerve injuries, while infrequent, can lead to significant morbidity, and therefore, appropriate preoperative counseling is warranted. RLN injury is the most common nerve injury identified after total thyroidectomy. Unilateral RLN injury often results in hoarseness and a weak cough. The RLN innervates all intrinsic muscles of the larynx and vocal cords (except the cricothyroid muscle), and therefore, it is not surprising that injury results in altered phonation. Furthermore, on direct visualization, the ipsilateral vocal cord is fixed and can be found in an abducted or paramedian position. Bilateral RLN injury, a possible complication of total thyroidectomy, can result in airway obstruction requiring a tracheostomy.

The EBSLN innervates the cricothyroid muscle. Injury to this nerve results in difficulty with voice projection and fatigue at higher pitches. While endotracheal tube trauma can cause hoarseness, the findings on direct laryngoscopy make RLN injury the correct answer. In addition, given the lack of physical examination findings, a neck hematoma is also unlikely. Finally, while RLN transection always results in ipsilateral cord paralysis, transection is less likely following direct visualization making other forms of temporary neuropraxia more likely, such as stretch injury. If complete transection occurs and is noticed intraoperatively, surgical repair at the time of surgery should be attempted.

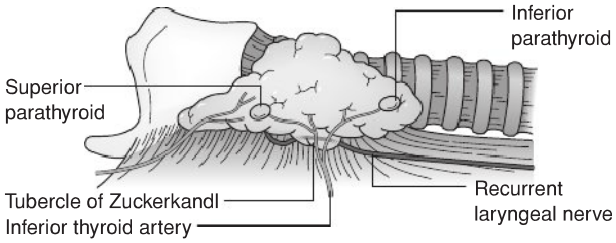

The standard anatomic relationship whereby the recurrent laryngeal nerve (RLN) passes medial to the tubercle of Zuckerkandl before its insertion into the cricothyroid interval. Reprinted with permission from: Miller BS, Gauger PG. Thyroid gland. In: Mulholland MW, Lillemoe KD, Doherty GM, Maier RV, Upchurch GR, eds. *Greenfield's Surgery: Scientific Principles & Practice*. 5th ed. Philadelphia, PA: Lippincott Williams & Wilkins, 2011:1283.

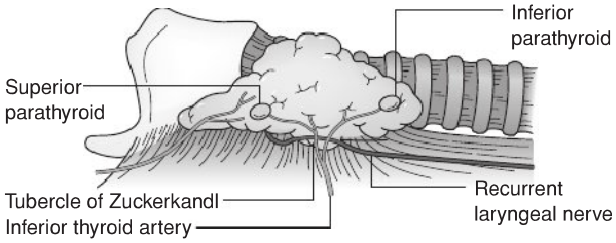

The uncommon but high-risk anatomic variation where the recurrent laryngeal nerve (RLN) courses lateral to the tubercle of Zuckerkandl, which is often enlarged. The nerve is encountered much earlier in the dissection required for thyroidectomy and is at risk of being misidentified as a vascular structure. Reprinted with permission from: Miller BS, Gauger PG. Thyroid gland. In: Mulholland MW, Lillemoe KD, Doherty GM, Maier RV, Upchurch GR, eds. *Greenfield's Surgery: Scientific Principles & Practice*. 5th ed. Philadelphia, PA: Lippincott Williams & Wilkins, 2011:1284.

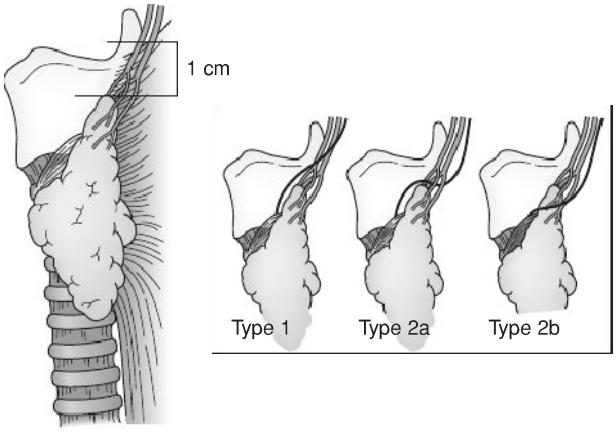

Cernea classification of the anatomic relationships between the external branch of the superior laryngeal nerve (EBSLN), the superior pole of the thyroid, and the superior thyroid artery. With type 1 anatomy, the nerve crosses the superior thyroid vessels 1 cm or more above the superior thyroid pole. With type 2 anatomy, the nerve crosses the vessels less than 1 cm above (type 2a) or even below (type 2b) the superior pole. Type 2 variants are the most vulnerable to iatrogenic injury. Reprinted with permission from: Miller BS, Gauger PG. Thyroid gland. In: Mulholland MW, Lillemoe KD, Doherty GM, Maier RV, Upchurch GR, eds. *Greenfield's Surgery: Scientific Principles & Practice*. 5th ed. Philadelphia, PA: Lippincott Williams & Wilkins, 2011:1284.

۰۲۱-۶۶۱۹۸۵۱۴ www.myuptodate.com دریافت آخرین نسخه آپتودیت آفلاین

References:
Chiang FY, Wang LF, Huang YF, et al. Recurrent laryngeal nerve palsy after thyroidectomy with routine identification of the recurrent laryngeal nerve. *Surgery.* 2005;137:342–347.
Goncalves Filho J, Kowalski LP. Surgical complications after thyroid surgery performed in a cancer hospital. *Otolaryngol Head Neck Surg.* 2005;132:490–494.
Netterville JL, Aly A, Ossoff RH. Evaluation and treatment of complications of thyroid and parathyroid surgery. *Otolaryngol Clin North Am.* 1990;23:529–552.

2E10

Key word: Operative Approach to Splenectomy

Author: Jacqueline Garonzik-Wang, MD, PhD
Editor: Mark D. Duncan, MD, FACS

In which of the following patients is laparoscopic splenectomy contraindicated and an open approach required?

(A) 18-year-old with hereditary spherocytosis and splenomegaly (spleen greater than 20 cm in length)

(B) 36-year-old morbidly obese female with a body mass index (BMI) of 38 kg/m^2

(C) 52-year-old male with cirrhosis and portal hypertension

(D) 61-year-old female with idiopathic thrombocytopenic purpura and a platelet count of 45,000/mm^3

(E) 68-year-old male with a splenic lymphangiosarcoma

Answer: (C) 52-year-old male with cirrhosis and portal hypertension

Rationale:
Laparoscopic splenectomy has become the standard and recommended approach for almost all benign and malignant disorders requiring elective splenectomy. A laparoscopic approach has been shown to decrease operative times, postoperative length of stay, and postoperative complications. This holds true regardless of body habitus and age. In addition, a laparoscopic approach is even recommended for patients with splenomegaly. While splenomegaly used to be considered a relative contraindication to a laparoscopic approach, more recent reports have demonstrated that laparoscopic splenectomy is feasible and safe in the hands of an experienced laparoscopic surgeon and can be attempted regardless of size. Patients with massive splenomegaly might benefit from a "hand-assisted" laparoscopic approach. Splenomegaly does, however, increase the risk of conversion to an open procedure.

While there have been some reports showing that laparoscopic splenectomy can be performed safely in patients with liver disease and cirrhosis, experts in this field still consider portal hypertension secondary to cirrhosis to be a contraindication to the laparoscopic approach. For these patients, the risk of intraoperative hemorrhage is too high. For patients with thrombocytopenia or coagulopathy, attempts should be made to correct their platelet counts and/or coagulopathy prior to surgery (or at the time of surgery in the case of thrombocytopenia), but a laparoscopic approach is still feasible.

Reference:
Habermalz B, Sauerland S, Decker G, et al. Laparoscopic splenectomy: the clinical practice guidelines of the European Association for Endoscopic Surgery (EAES). *Surg Endosc.* 2008;22(4):821–848.

۰۲۱-۶۶۱۹۸۵۱۴ www.myuptodate.com دریافت آخرین نسخه آپتودیت آفلاین

2E11

Key word: Pathologic Diagnosis of High-risk Breast Cancer

Author: Jacqueline Garonzik-Wang, MD, PhD
Editor: Lisa K. Jacobs, MD

A 53-year-old woman was found to have a suspicious lesion on routine screening mammography. She subsequently underwent stereotactic core biopsy of the lesion. Which of the following pathologic findings puts her at greatest risk of breast cancer?

(A) Apocrine metaplasia
(B) Atypical ductal hyperplasia
(C) Intraductal papilloma
(D) Mammary duct ectasia
(E) Sclerosing adenosis

Answer: (B) Atypical ductal hyperplasia

Rationale:
A variety of pathologic variants are commonly found in breast biopsy specimens. To counsel patients appropriately, the clinician must know which lesions put a patient at increased risk for breast cancer and which are associated with no increased risk. All of the above answer choices fall into the category of benign breast diseases. Mammary duct ectasia, solitary intraductal papillomas, and apocrine metaplasia are not associated with an increased risk of breast cancer. However, atypical ductal hyperplasia is associated with a moderately increased risk for invasive breast cancer. While sclerosing adenosis is associated with a mildly elevated cancer risk, atypical ductal hyperplasia places a patient at greater risk for subsequent breast cancer. Other benign breast diseases associated with an increased risk of breast cancer include atypical lobular hyperplasia and ductal and lobular carcinoma in situ.

Indications for Surgical Biopsy after Core Biopsy

- Atypical ductal hyperplasia
- Atypical lobular hyperplasia
- Radial scar
- Lobular carcinoma in situ
- Columnar cell hyperplasia with atypia
- Papillary lesions
- Lack of concordance between appearance of mammographic lesion and histologic diagnosis
- Nondiagnostic specimen (including absence of calcifications on specimen radiograph when biopsy is performed for calcifications)

Reprinted with permission from: King TA, Morrow M. Breast disease. In: Mulholland MW, Lillemoe KD, Doherty GM, Maier RV, Upchurch GR, eds. *Greenfield's Surgery: Scientific Principles & Practice*. 5th ed. Philadelphia, PA: Lippincott Williams & Wilkins, 2011:1248.

Reference:

Wang J, Constantino JP, Tan-Chiu E, et al. Lower-category benign breast disease and the risk of invasive breast cancer. *J Natl Cancer Inst.* 2004;96:616–620.

2E12

Key word: Treatment of Breast Cancer with Negative Sentinel Lymph Node Biopsy

Author: Jacqueline Garonzik-Wang, MD, PhD
Editor: Lisa K. Jacobs, MD

A 58-year-old woman undergoes a lumpectomy and sentinel lymph node biopsy for a 1-cm infiltrating ductal adenocarcinoma in her right breast. Pathologic review of her sentinel nodes is negative for metastatic disease. The next step in management should include:

(A) Chemotherapy
(B) Completion axillary lymph node dissection to confirm that all nodes in the axilla are negative
(C) Completion mastectomy
(D) Radiation therapy to the right breast
(E) Repeat sentinel lymph node biopsy secondary to the high false-negative rate of the procedure

Answer: (D) Radiation therapy to the right breast

Rationale:
The sentinel node is the first node to drain the tumor basin and therefore, is the most likely to harbor metastatic disease if lymph node spread has occurred. Sentinel node biopsies have eliminated the need for routine axillary dissections. In patients with early stage breast cancer and a clinically negative axilla, a negative sentinel lymph node biopsy is sufficient for axillary lymph node assessment and provides similar outcomes to axillary dissections while also resulting in less morbidity. In a randomized study of sentinel lymph node biopsy versus axillary node dissection for clinically node-negative

Contraindications to Breast-conserving Therapy in Invasive Carcinoma

Absolute Contraindications

- Two or more primary tumors in separate quadrants of the breast
- Persistent positive margins after reasonable surgical attempts
- Pregnancy is an absolute contraindication to the use of breast irradiation. When cancer is diagnosed in the third trimester, it may be possible to perform breast-conserving surgery and treat the patient with irradiation after delivery.
- A history of prior therapeutic irradiation to the breast region that would result in re-treatment to an excessively high radiation dose
- Diffuse malignant-appearing microcalcifications

Relative Contraindications

- A history of scleroderma or active systemic lupus erythematosus
- Large tumor in a small breast that would result in cosmesis unacceptable to the patient. In this circumstance, preoperative chemotherapy should be considered.
- Very large or pendulous breasts if reproducibility of patient setup and adequate dose homogeneity cannot be ensured

Reprinted with permission from: King TA, Morrow M. Breast disease. In: Mulholland MW, Lillemoe KD, Doherty GM, Maier RV, Upchurch GR, eds. *Greenfield's Surgery: Scientific Principles & Practice*. 5th ed. Philadelphia, PA: Lippincott Williams & Wilkins, 2011:1267.

۰۲۱-۶۶۱۹۸۵۱۴ www.myuptodate.com دریافت آخرین نسخه آپتودیت آفلاین

patients, NSABP B-32, there was no difference in survival or axillary recurrence between the two groups. This study proves that those patients that are node negative do not require an axillary node dissection.

Radiotherapy is indicated for patients with stage I breast cancer who are treated with breast conservation therapy (such as lumpectomy) to decrease local recurrence rates. Systemic chemotherapy is reserved for patients with metastatic disease and those with high-risk primary lesions.

References:

Bland KI, Beenken SW, Copeland EE. The breast. In: Brunicardi FC, Andersen DK, Billiar TR, Dunn DL, Hunter JG, Pollock RE, eds. *Schwartz's Manual of Surgery.* 8th ed. New York, NY: McGraw-Hill; 2006:344–368.

Greene FL, Page DL, Fleming ID, et al. (eds). *AJCC Cancer Staging Manual.* 6th ed. New York, NY: Springer; 2002: 227–228.

2E13

Key word: Treatment of an Incidental Adrenal Mass

Author: Jacqueline Garonzik-Wang, MD, PhD
Editor: Richard D. Schulick, MD, MBA, FACS

A 65-year-old man recently underwent an abdominal computed tomography (CT) scan as part of a workup following a motor vehicle collision. A 5.5-cm heterogeneous adrenal mass was incidentally found, and he is referred to your clinic for evaluation and management. He otherwise has no past medical history, his blood pressure is normal, and his physical examination is unremarkable. Laboratory studies reveal a normal potassium level, normal serum and urine-free cortisol, and normal overnight dexamethasone test and plasma-free and urine metanephrines are negative. The next step in management is:

(A) Ipsilateral adrenalectomy and nephrectomy

(B) Ipsilateral laparoscopic adrenalectomy

(C) Nothing since the tumor is nonfunctional

(D) Observation and repeat CT scans every 3 to 6 months to see if the tumor is enlarging

(E) Steroid suppression and repeat imaging

Answer: (B) Ipsilateral laparoscopic adrenalectomy

Rationale:

Adrenal incidentalomas are becoming more common with increased utilization of CT scans for evaluation of abdominal pathology (found in 2% to 5% of routine imaging). The differential diagnosis for these masses includes benign adenomas most commonly, functional tumors, metastatic lesions, and primary adrenocortical cancer. All functioning tumors should be resected. Therefore, a detailed history and physical examination is imperative to identify signs or symptoms of a functioning mass (such as hypertension or striae and fat redistribution). In addition, confirmatory laboratory studies should be performed to evaluate for elevated adrenal hormones (such as plasma or urinary metanephrines, urinary cortisol, and a dexamethasone suppression test).

Other indications for surgery include ominous characteristics on imaging (such as border irregularity, heterogeneity, and high attenuation). In addition, lesions greater than 4 cm in size or those enlarging by more than 0.5 cm over 6 months on serial imaging should be resected due to an increased risk of harboring malignancy. Since this lesion in question is 5.5 cm, it meets these criteria and therefore needs to be resected. Laparoscopic adrenalectomy is the procedure of choice for an adrenal mass. A nephrectomy is not necessary unless the mass invades the ipsilateral kidney. Steroid suppression is not indicated because this tumor is nonfunctional.

Also see rationale presented in Question 2E08.

۰۲۱-۶۶۱۹۸۵۱۴ www.myuptodate.com دریافت آخرین نسخه آپتودیت آفلاین

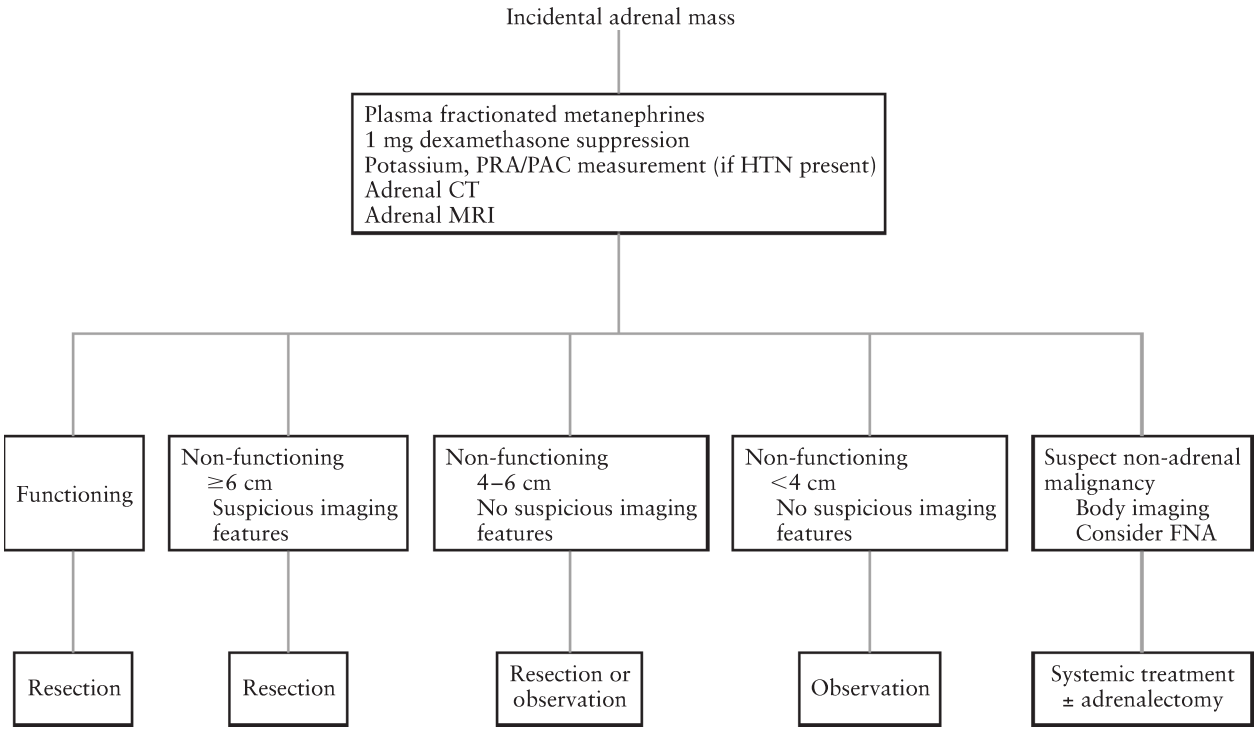

Diagnosis and management of the incidental adrenal mass. PRA, plasma renin activity; PAC, plasma aldosterone concentration; HTN, hypertension; CT, computed tomography; MRI, magnetic resonance imaging; FNA, fine-needle aspiration. Reprinted with permission from: Olson JA, Scheri RP. Adrenal gland. In: Mulholland MW, Lillemoe KD, Doherty GM, Maier RV, Upchurch GR, eds. Greenfield's Surgery: Scientific Principles & Practice. 5th ed. Philadelphia, PA: Lippincott Williams & Wilkins, 2011:1340.

References:

Brunt LM, Moley JF. Adrenal incidentaloma. *World J Surg.* 2001;25(7):905–913.

Grumbach MM, Biller BM, Braunstein GD, et al. Management of the clinically inapparent adrenal mass ("incidentaloma"). *Ann Intern Med.* 2003;138(5):424–429.

۰۲۱-۶۶۱۹۸۵۱۴ www.myuptodate.com دریافت آخرین نسخه آپتودیت آفلاین

2E14

Key word: Treatment of Invasive Ductal Breast Cancer

Author: Jacqueline Garonzik-Wang, MD, PhD
Editor: Lisa K. Jacobs, MD

A 45-year-old female has a 1.5-cm mass in her right breast. There are no palpable axillary nodes and her physical examination is otherwise unremarkable. She undergoes a stereotactic core biopsy which reveals infiltrating ductal carcinoma. What is the most appropriate treatment option for her?

(A) Lumpectomy alone

(B) Lumpectomy and sentinel lymph node biopsy

(C) Lumpectomy and sentinel lymph node biopsy followed by radiation

(D) Lumpectomy followed by radiation

(E) Modified radical mastectomy followed by radiation if axillary nodes are negative

Answer: (C) Lumpectomy and sentinel lymph node biopsy followed by radiation

Rationale:

Large clinical trials have shown equivalent survival outcomes between mastectomy and breast-conserving therapy. Breast-conserving therapy consists of lumpectomy, an assessment of the draining axillary lymph node basin and radiation. A negative sentinel lymph node biopsy performed by an experienced surgeon is sufficient for axillary assessment. However, if positive, a completion lymphadenectomy is considered. For patients with T1 or T2 breast cancer treated with breast preservation and a positive sentinel lymph node biopsy, a randomized trial between sentinel lymph node biopsy and axillary node dissection showed no difference in survival or local recurrence. Regardless of axillary sampling method, all breast-conserving therapies must be followed by radiotherapy to the whole breast to reduce the rate of local recurrence. Patients who are candidates for breast-conserving therapy must have a lesion less than 4 cm in size, favorable breast size to lesion size ratio, no evidence of multicentricity, no contraindication to radiation therapy such as prior radiation therapy or connective tissue disorders (primarily scleroderma), no evidence of skin involvement, and have a preference for breast-conversing therapy.

For patients who are not candidates for breast-conserving therapy, treatment consists of a total mastectomy with sentinel lymph node biopsy. Indications for radiation therapy after a mastectomy include greater than three positive lymph nodes, T4 tumors (skin or chest wall involvement), or positive margins.

References:

Fisher B, Anderson S, Bryant J, et al. Twenty-year follow-up of a randomized clinical trial comparing total mastectomy, lumpectomy, and lumpectomy plus irradiation for the treatment of invasive breast cancer. *N Engl J Med.* 2002;347(16):1233–1241.

Fisher B, Dignam J, Wolmark N, et al. Lumpectomy and radiation therapy for the treatment of intraductal breast cancer: findings from National Surgical Adjuvant Breast and Bowel Project B-17. *J Clin Oncol.* 1998;16(2):441–452.

2E15

Key word: Treatment of Medullary Thyroid Cancer

Author: Jacqueline Garonzik-Wang, MD, PhD
Editor: Alan P.B. Dackiw, MD, PhD, BSc, BSc(Med), FACS, FRCSC

A 45-year-old male is referred to you for management of a 2-cm lesion in his right thyroid lobe, which on biopsy is found to be medullary thyroid carcinoma (MTC). Evaluation of both sides of his neck clinically and radiographically shows no evidence of nodal disease. When discussing management options, you tell him that the treatment of choice for localized MTC is:

(A) Observation, unless he has a family history of MEN

(B) Thyroid lobectomy

(C) Thyroid lobectomy and central lymph node dissection

(D) Total thyroidectomy

(E) Total thyroidectomy and central lymph node dissection

Answer: (E) Total thyroidectomy and central lymph node dissection

Rationale:

MTC is more aggressive than both papillary and follicular carcinoma. In addition, this variant of thyroid cancer is not radio- or chemoresponsive and does not take up radioactive iodine, making adjuvant therapies ineffective. For these reasons, total thyroidectomy, as opposed to thyroid lobectomy, is indicated.

In addition, MTC has a greater predilection for multicentricity and early lymph node involvement than other thyroid cancer types. For this reason, total thyroidectomy with central lymph node dissection is the preferred treatment. Modified radical lymph node dissection is reserved for patients with clinically positive nodes.

References:

Kebebew E, Ituarte P, Siperstein A, et al. Medullary thyroid carcinoma: clinical characteristics, treatment, prognostic factors, and a comparison of staging systems. *Cancer.* 2000; 88:1139–1148.

Kloos R, Evans D, Francis G, et al. Medullary thyroid cancer: management guidelines of the American Thyroid Association. *Thyroid.* 2009;19:565–612.

۰۲۱-۶۶۱۹۸۵۱۴ www.myuptodate.com دریافت آخرین نسخه آپتودیت آفلاین

2E16

Key word: Treatment of Papillary Thyroid Cancer with Lymph Node Metastases

Author: Jacqueline Garonzik-Wang, MD, PhD
Editor: Alan P.B. Dackiw, MD, PhD, BSc, BSc(Med), FACS, FRCSC

A 45-year-old gentleman presents with a 2-cm left thyroid nodule that is biopsy-proven papillary carcinoma. Ipsilateral neck ultrasound demonstrates two suspicious nodes, one of which on biopsy shows papillary carcinoma. Definitive management should include the following.

(A) Total thyroidectomy

(B) Total thyroidectomy with modified radical neck dissection

(C) Total thyroidectomy with selective lymph node sampling

(D) Total thyroidectomy with systemic chemotherapy

(E) Total thyroidectomy with unilateral neck radiotherapy

Answer: (B) Total thyroidectomy with modified radical neck dissection

Rationale:
Papillary thyroid carcinoma has the best overall prognosis of all types of thyroid cancer. In addition, it is the most common thyroid carcinoma. For small lesions (less than 1 cm in diameter), some surgeons advocate thyroid lobectomy. However, for lesions greater than 1 cm in size, total thyroidectomy is indicated along with postoperative radioactive iodine treatment. Conventional radiotherapy is only recommended with recurrent, invasive, or residual disease. For patients with clinically or pathologically identified lymph node metastases, a modified radical neck dissection is warranted. Given the outstanding prognosis of papillary thyroid cancer, systemic chemotherapy is not recommended for local disease.

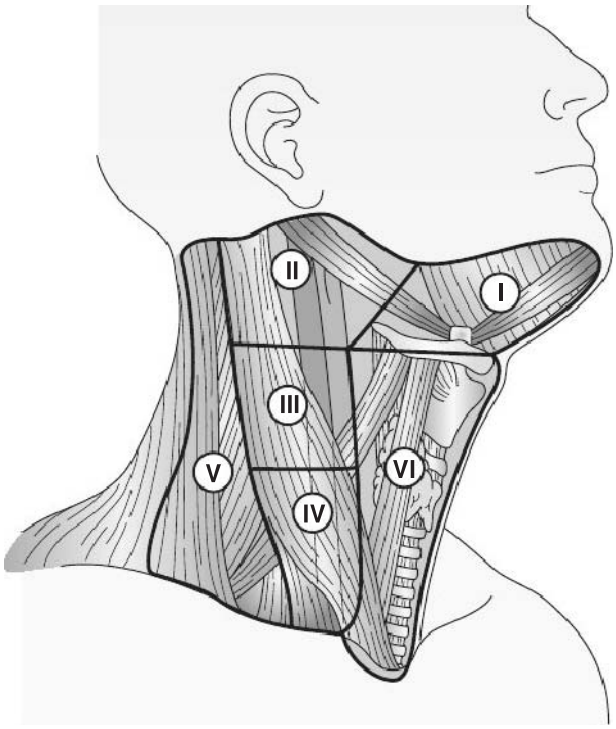

Classification scheme for regional lymph node basins in the neck. Reprinted with permission from: Miller BS, Gauger PG. Thyroid gland. In: Mulholland MW, Lillemoe KD, Doherty GM, Maier RV, Upchurch GR, eds. *Greenfield's Surgery: Scientific Principles & Practice*. 5th ed. Philadelphia, PA: Lippincott Williams & Wilkins, 2011:1284.

Reference:
Burns WR, Zeiger MA. Differentiated thyroid cancer. *Semin Oncol.* 2010;37:557–566.

۰۲۱-۶۶۱۹۸۵۱۴ www.myuptodate.com دریافت آخرین نسخه آپتودیت آفلاین

2E17

Key word: Treatment of Parathyroid Hyperplasia

Author: Jacqueline Garonzik-Wang, MD, PhD
Editor: Alan P.B. Dackiw, MD, PhD, BSc, BSc(Med), FACS, FRCSC

A 49-year-old female is evaluated by her primary care physician for myalgias, recurrent kidney stones, and depression. After a thorough workup, she is diagnosed with primary hyperparathyroidism. Preoperative localization is attempted with a sestamibi scan, but the study failed to identify any abnormal parathyroid glands. The patient is taken to the operating room for definitive treatment. After performing bilateral neck explorations, all four glands are found and appear significantly enlarged and abnormal. Which of the following is the preferred treatment option?

(A) Biopsy of all four parathyroid glands and removal of the most hyperplastic gland

(B) Removal of all four enlarged parathyroid glands

(C) Removal of all four parathyroid glands with autotransplantation of half of a gland into the brachioradialis muscle

(D) Removal of the largest parathyroid gland

(E) Removal of the three largest and most vascular parathyroid glands

Answer: (C) Removal of all four parathyroid glands with autotransplantation of half of a gland into the brachioradialis muscle

Rationale:
The patient in the question has primary four-gland parathyroid hyperplasia. The sensitivity of sestamibi scanning is poor in the setting of multiglandular disease such as parathyroid hyperplasia. Although in rare cases parathyroid hyperplasia can be sporadic, it is normally associated with MEN1, MEN2A, or isolated familial hyperparathyroidism. In patients with parathyroid hyperplasia, the recommended treatment is removal of all four glands with autotransplantation of a portion of one gland in the brachioradialis muscle in the forearm. This treats the hyperparathyroidism by debulking the glands and makes the residual gland easily accessible in case the patient develops recurrent hyperparathyroidism. However, at times the autotransplanted gland does not survive implantation, making the patient permanently hypoparathyroid. For this reason, some surgeons prefer to only remove three and one half glands and leave half of one parathyroid gland in situ in the neck. Removal of anything less than three and one half glands is not sufficient in four-gland parathyroid hyperplasia.

Reference:
Augustine MM, Bravo PE, Zeiger MA. Surgical treatment of primary hyperparathyroidism. *Endocr Pract.* 2011;17: 75–82.

2E18

Key word: Treatment of Lymphoma of the Small Bowel

Author: Jacqueline Garonzik-Wang, MD, PhD
Editor: Barish H. Edil, MD

A 54-year-old man presents with worsening abdominal pain, nausea, vomiting, and obstipation. Plain films reveal dilated loops of small bowel and an abdominal computed tomography is concerning for a high-grade small bowel obstruction secondary to intussusception. The patient is resuscitated and taken to the operating room where he is found to have an ileal intussusception. After reduction and inspection of this segment of bowel, a mass is felt within the involved segment. A frozen section of the mass is concerning for lymphoma. Surgical management should consist of:

(A) *Helicobacter pylori* treatment in the postoperative period

(B) Inguinal lymph node sampling

(C) Reduction of the intusscepted segment of bowel and abdominal closure, followed by systemic chemotherapy

(D) Segmental resection with wide resection of the involved mesentery

(E) Thorough abdominal exploration and random lymph node sampling

Answer: (D) Segmental resection with wide resection of the involved mesentery

Rationale:
Small bowel tumors are rather rare, making up only 2% of new gastrointestinal cancers each year. Small bowel lymphomas account for approximately 15% of tumors found in the small bowel, much less common than carcinoid tumors, which are the most common. Small bowel lymphomas are most commonly found in the ileum. These lesions are more frequent in immunodeficient patients (such as those with AIDS) and are usually non-Hodgkin B-cell type lymphomas.

The treatment of choice for localized, early-stage small bowel lymphoma is surgical resection, including the involved adjacent mesentery. Abdominal exploration, nodal sampling, and liver biopsy of suspicious lesions are essential for staging. Any suspicious-appearing lymph nodes should be sampled, but random lymph node sampling is not warranted. For advanced small bowel lymphoma, surgical treatment consists only of providing tissue diagnosis and palliation for complications. Chemotherapy has variable cure rates for small bowel lymphoma. Even if frozen section were inconclusive in the above scenario, resection with inclusion of the surrounding mesentery would still be warranted because intussusception in an adult is worrisome for malignancy. *H. pylori* treatment for lymphoma is only utilized for gastric mucosa-associated lymphoid tissue (MALT) lymphomas.

۰۲۱-۶۶۱۹۸۵۱۴ www.myuptodate.com دریافت آخرین نسخه آپتودیت آفلاین

References:
Hrabe JE, Cullen JJ. Management of small bowel tumors. In: Cameron JL, Cameron AM, eds. *Current Surgical Therapy.* 10th ed. Philadelphia, PA: Mosby; 2011;106–109.
Rawls RA, Vega KJ, Trotman BW. Small bowel lymphoma. *Curr Treat Options Gastroenterol.* 2003;6:27–34.

2E19

Key word: Treatment of Toxic Nodular Goiter

Author: Kelly Olino, MD
Editor: Alan P.B. Dackiw, MD, PhD, BSc, BSc(Med), FACS, FRCSC

A 36-year-old woman with thyrotoxicosis and a large goiter extending below her sternum undergoes a radioactive iodine uptake study that shows multiple areas of intense uptake. Which of the following is the best management for her condition?

(A) Methimazole
(B) Propylthiouracil
(C) Radioactive iodine-131 ablation
(D) Thyroid lobectomy
(E) Total thyroidectomy

Answer: (E) Total thyroidectomy

Rationale:
The above patient has toxic multinodular goiter extending below her sternum. Radioactive iodine treatment is used for patients with high surgical risk, for patients with previous neck operations, and when the size of the goiter is small and amenable to ablation. Response rates reach 80% by 6 months after treatment, while 1-year rates of hypothyroidism approach 3%, which increases to over 60% after 25 years following treatment. In addition, up to 20% of patients will require retreatment following initial therapy.

Near-total or total thyroidectomy is curative and avoids recurrence but also renders the patient dependent on thyroid hormone replacement. It is indicated in patients who are symptomatic from the size of the gland, in patients who are also in need of surgery for hyperparathyroidism, when there is a concern for cancer, and when immediate relief of symptoms is necessary. In the above example, a goiter of this size is likely to be causing symptoms in the patient due to compression of adjacent structures, making thyroidectomy the best option.

Thyroid lobectomy is only indicated in cases of a solitary toxic adenoma. Methimazole or propylthiouracil are rarely used as primary treatment options. However, pretreatment with methimazole is indicated in patients with hyperthyroidism prior to thyroidectomy in order to obtain euthyroidism, given that surgical risks are increased in the presence of thyrotoxicosis.

Reference:
Bahn R, Burch H, Cooper D, et al. Hyperthyroidism and other causes of thyrotoxicosis: management guidelines of the American Thyroid Association and American Association of Clinical Endocrinologists. *Thyroid.* 2011;2:593–646.

۰۲۱-۶۶۱۹۸۵۱۴ www.myuptodate.com دریافت آخرین نسخه آپتودیت آفلاین

2E20

Key word: Treatment of Thyroiditis during Pregnancy

Author: Kelly Olino, MD
Editor: Alan P.B. Dackiw, MD, PhD, BSc, BSc(Med), FACS, FRCSC

A 32-year-old woman early in her second trimester of pregnancy presents to her obstetrician with tachycardia and excessive sweating. Laboratory evaluation reveals low thyroid-stimulating hormone (TSH) with high T4 and presence of Thyroid Receptor Antibody (TRAb). The most appropriate treatment for this patient is:

(A) Observation
(B) Total thyroidectomy
(C) Treatment with methimazole
(D) Treatment with propylthiouracil (PTU)
(E) Radioactive iodine ablation

Answer: (C) Treatment with methimazole

Rationale:
Treatment for thyroiditis during pregnancy depends on the symptoms and underlying etiology. Radioactive iodine ablation is never an option during pregnancy. Total thyroidectomy is only indicated following failure of medical management in highly symptomatic patients. This option, when necessary, is best performed at the end of the second trimester when risk of preterm labor and miscarriage is lower and the fetus has some intrinsic thyroid function.

In the above case, the patient has Graves disease, which is best managed by pharmacologic therapy. Given that she is in her second trimester, treatment with methimazole is the best treatment option. Historically, PTU was the preferred treatment throughout pregnancy. However, in 2009 the U.S. FDA recommended that treatment should be switched to methimazole starting in the second trimester and continued through the time of delivery. PTU carries a risk of liver toxicity that has been fatal in cases. Methimazole has been found in extremely rare occasions to be teratogenic, which previously limited its use during pregnancy.

Reference:
Stagnaro-Green A, Abalovich M, Alexander E, et al.; American Thyroid Association Taskforce on Thyroid Disease During Pregnancy and Postpartum. Guidelines of the American Thyroid Association for the diagnosis and management of thyroid disease during pregnancy and postpartum. *Thyroid.* 2011;21:1081–1125.

2E21

Key word: Treatment of Thyroid Crisis

Author: Kelly Olino, MD
Editor: Alan P.B. Dackiw, MD, PhD, BSc, BSc(Med), FACS, FRCSC

A 26-year-old female who was recently diagnosed with Graves disease is involved in a serious motor vehicle collision. After undergoing a computed tomography (CT) scan with IV contrast, she is found to have pelvic fractures and multiple rib fractures with underlying pulmonary contusions. While in the intensive care unit hours later, she is noted to have a temperature of 39.5°C, heart rate of 130 beats per minute, oxygen saturation of 84%, and an altered mental status. After securing the patient's airway, the next best step in management is:

(A) 100 mg hydrocortisone
(B) 1,000 mg of propylthiouracil
(C) 20-mg IV metoprolol
(D) Administration of Lugol solution
(E) Subtotal thyroidectomy

Answer: (B) 1,000 mg of propylthiouracil

Rationale:
The patient in the above clinical situation with known Graves disease is in thyroid storm. Signs include hyperpyrexia, change in mental status, tachycardia, congestive heart failure, tachyarrhythmia, and jaundice. While all of the answers except subtotal thyroidectomy are useful in this scenario, treatment for thyroid crisis should start with the administration of up to a 1,000 mg load of propylthiouracil, which blocks both the conversion of T4 to T3 and the synthesis of thyroid-stimulating hormone (TSH). Once this has been administered, Lugol solution or another form of iodine can be administered. This blocks both the synthesis and release of thyroid hormone. Propranolol and hydrocortisone can block T4 to T3 conversion and are used as adjunct treatment.

References:
Bahn RS, Burch HB, Cooper DS, et al. Hyperthyroidism and other causes of thyrotoxicosis: management guidelines of the American Thyroid Association and American Association of Clinical Endocrinologists. *Thyroid.* 2011;21:593–646.
Clark OH. Thyroid & parathyroid. In: Doherty GM, ed. *Current Diagnosis & Treatment: Surgery.* 13th ed. Columbus, OH: McGraw-Hill Companies; 2010.

۰۲۱-۶۶۱۹۸۵۱۴ www.myuptodate.com دریافت آخرین نسخه آپتودیت آفلاین

2E22

Key word: Diagnosis of Lymphangiosarcoma

Author: Seth D. Goldstein, MD
Editor: Lisa K. Jacobs, MD

A 60-year-old woman presents for routine follow-up 12 years after a right-sided mastectomy and complete axillary lymph node dissection for advanced stage breast cancer. She has been in complete remission since postoperative chemotherapy but has suffered from chronic upper extremity lymphedema. An asymptomatic 2-cm blue-purple nodule is noted on the lateral right arm along with several smaller satellite lesions. The diagnosis of primary concern in this context should be:

(A) Basal cell carcinoma
(B) Histiocytoma
(C) Lymphangiosarcoma
(D) Merkel cell carcinoma
(E) Squamous cell carcinoma

Answer: (C) Lymphangiosarcoma

Rationale:
Stewart–Treves syndrome, first described in 1948, is an angiosarcoma that develops in the setting of chronic lymphedema. It generally presents as an acute worsening of edema in the presence of subcutaneous nodules that can bleed or ulcerate. Presentation occurs at a median of about 10 years following the development of lymphedema. Although the etiology behind its development is unknown, it is hypothesized that there may be local immunosuppression. Early amputation or wide local excision, often preceded by chemotherapy and/or radiation, offers the only chance for long-term survival. Even with these interventions, however, the prognosis is poor.

References:
Heitmann C, Ingianni G. Stewart-Treves syndrome: Lymphangiosarcoma following mastectomy. *Ann Plast Surg.* 2000;44:72–75.
Pipinos II, Baxter BT. The lymphatics. In: Towsend CM, Beauchamp RD, Evers BM, Mattox KL, eds. *Sabiston Textbook of Surgery.* 19th ed. Philadelphia, PA: Saunders Elsevier; 2012:1825.

2E23

Key word: Characteristics of Glucagonoma

Author: Seth D. Goldstein, MD
Editor: Barish H. Edil, MD

A 55-year-old woman with a history of hypertension experiences rapid onset of insulin-dependent diabetes. On examination she is slender and athletic. She also reports a rash that has appeared in various places, starting as raised red papules that subsequently blistered and then healed from the center outward. What laboratory serum test is indicated in this patient?

(A) Glucagon
(B) Insulin
(C) Metanephrines
(D) Serotonin
(E) Somatostatin

Answer: (A) Glucagon

Rationale:
Glucagonomas are endocrine tumors of the pancreatic islet alpha cells that present with hyperglycemia and a dermatitis known as necrolytic migratory erythema. Diabetes occurs in 75% to 95% and necrolytic migratory erythema in approximately 65% to 70% of patients with glucagonoma. The diagnosis is confirmed with a markedly elevated plasma glucagon level. Pancreas-protocol triple phase computed tomography is used to localize the disease and evaluate for the presence of possible metastatic disease, which can be present in 50% to 90% of patients. The only curative therapy for glucagonoma is surgical resection. Most glucagonomas are located in the tail or body of pancreas, and are best treated with a distal pancreatectomy and splenectomy. Somatostatin analogues such as octreotide inhibit the release of glucagon and are used to effectively control symptoms related to glucagonoma.

Glucagonoma

Parameter	Description
Symptoms	Dermatitis manifested as necrolytic migratory erythema
	Stomatitis
	Catabolic state: weight loss
Diagnostic tests	Hyperglycemia
	Hypoproteinemia
	Serum glucagon measurement
	Serum amino acid profile
Anatomic localization	Most in body and tail of pancreas, with liver metastases

Reprinted with permission from: Kennedy EP, Brody JB, Yeo CJ. Neoplasms of the endocrine pancreas. In: Mulholland MW, Lillemoe KD, Doherty GM, Maier RV, Upchurch GR, eds. *Greenfield's Surgery: Scientific Principles & Practice.* 5th ed. Philadelphia, PA: Lippincott Williams & Wilkins, 2011:867.

۰۲۱-۶۶۱۹۸۵۱۴ www.myuptodate.com دریافت آخرین نسخه آپتودیت آفلاین

References:
Fisher WE, Anderson DK, Bell RH, et al. Pancreas. In: Brunicardi FC, Andersen DK, Billiar TR, Dunn DL, Hunter JG, Matthews JB, Pollock RE, eds. *Schwartz's Principles of Surgery.* 9th ed. New York, NY: McGraw-Hill; 2010. http://www.accessmedicine.com/content.aspx?aID=5033260. Accessed April 19, 2013.
Kennedy EP, Brody JR, Yeo CJ. Neoplasms of the endocrine pancreas. In: Mulholland MW, Lillemoe KD, Doherty GM, Maier RV, Upchurch GR, eds. *Greenfield's Surgery: Scientific Principles and Practice.* 5th ed. Philadelphia, PA: Lippincott Williams and Wilkins; 2011.

2E24

Key word: Diagnostic Test for Pituitary Tumor

Author: Seth D. Goldstein, MD
Editor: Pamela A. Lipsett, MD, MHPE, FACS, FCCM

A 44-year-old woman presents with a 6-month history of weight gain, worsening diabetes, and abdominal striae. Plasma adrenocorticotropic hormone (ACTH) and serum cortisol levels are high. Serum cortisol does not suppress after low-dose (1-mg) dexamethasone administration but does suppress after high-dose administration. Pituitary magnetic resonance imaging (MRI) is obtained, and no large masses are appreciated. What is the next step in diagnosis?

(A) 24-hour urine ACTH
(B) Bilateral adrenalectomy
(C) Cosyntropin stimulation test
(D) Inferior petrosal sinus sampling
(E) MRI of the chest, abdomen and pelvis

Answer: **(D)** Inferior petrosal sinus sampling

Rationale:
Cushing syndrome is classified by whether it is ACTH independent or ACTH dependent. ACTH-independent Cushing syndrome is most commonly due to exogenous administration of glucocorticoids or less commonly due to autonomous secretion of cortisol by the adrenal glands from a tumor or hyperplasia. In the case of a solitary cortisol-producing tumor, adrenalectomy is curative. ACTH-dependent Cushing syndrome can result from a pituitary source (Cushing disease) or from an ectopic source (such as in paraneoplastic syndromes). In this patient, the serum cortisol and ACTH levels are elevated, with the high-dose dexamethasone suppression test causing suppression of cortisol levels. This strongly points toward a pituitary source for increased ACTH rather than an ectopically producing tumor. MRI only demonstrates pituitary lesions in 50% of cases given that many of these tumors are microadenomas. Thus, inferior petrosal sinus sampling is required for localization of the lesion prior to trans-sphenoidal resection. If the high-dose dexamethasone suppression test was negative, then an ectopic source with computed tomography (CT) or MRI localization would be indicated. Bilateral adrenalectomy would only be indicated for recurrent/refractory Cushing disease.

Reference:
Fitzgerald PA. Endocrine disorders. In: Papadakis MA, McPhee SJ, Rabow MW, eds. *Current Medical Diagnosis & Treatment 2013.* New York, NY: McGraw-Hill; 2013.

۰۲۱-۶۶۱۹۸۵۱۴ www.myuptodate.com دریافت آخرین نسخه آپتودیت آفلاین

2E25

Key word: Treatment of Hypercalcemic Crisis

Author: Seth D. Goldstein, MD
Editor: Alan P.B. Dackiw, MD, PhD, BSc, BSc(Med), FACS, FRCSC

A 50-year-old woman scheduled for parathyroidectomy presents to the emergency department with nausea, vomiting, and altered mental status. Laboratory analysis reveals serum calcium of 16 mg/dL. In addition to IV fluids, the best medication to give immediately would be:

(A) Calcitonin
(B) Furosemide
(C) Mithramycin
(D) Prednisone
(E) Zoledronic acid

Answer: (B) Furosemide

Rationale:
Primary hyperparathyroidism is due to the unregulated secretion of parathyroid hormone (PTH) from the parathyroid glands. Secretion can be from one gland (adenoma or carcinoma) or from multiple glands (hyperplasia or multiple adenomas). Hypercalcemic crisis is characterized by nausea, vomiting, muscle weakness, and polyuria and can occur with hyperparathyroidism, paraneoplastic syndromes (through the release of PTH-related protein), rare cases of parathyroid carcinoma, acute vitamin D intoxication, and granulomatous diseases. Treatment involves aggressive hydration and therapy to excrete calcium. Hydration, preferably with normal saline, is important to correct the volume depletion that is typically present, as urinary excretion of calcium is impaired in states of hypovolemia. A loop diuretic such as furosemide should be included to prevent volume overload and also to inhibit renal resorption of calcium.

Zoledronic acid, which is a bisphosphonate, has a longer onset of action and would be used in chronic management of the hypercalcemic state. Calcitonin, which has a rapid onset of action in lowering calcium levels, can also be added but is only efficacious for 24 to 48 hours. Steroid therapy and mithramycin are less commonly used. Steroids have a more valuable role if the cause of hypercalcemic crisis is sarcoidosis or other forms of granulomatous disease. Hemodialysis can also be used in treatment to lower calcium levels.

Reference:
Lal G, Clark OH. Thyroid, parathyroid, and adrenal. In: Brunicardi FC, Andersen DK, Billiar TR, Dunn DL, Hunter JG, Matthews JB, Pollock RE, eds. *Schwartz's Principles of Surgery.* 9th ed. Columbus, OH: The McGraw-Hill Companies; 2010.

2E26

Key word: Blood Supply of Latissimus Dorsi Myocutaneous Flap

Author: Raja Mohan, MD
Editor: Anthony P. Tufaro, DDS, MD, FACS

A thin 55-year-old female underwent a right mastectomy for ductal carcinoma 2 months ago followed by immediate tissue expander based reconstruction. After receiving a short course of radiation therapy, the tissue expander became exposed and had to be removed. In order to provide more robust coverage, a latissimus dorsi myocutaneous flap was chosen since other flap options were not possible due to the patient's body habitus. What is the blood supply for this flap?

(A) Axillary artery
(B) Dorsal scapular artery
(C) Lateral thoracic artery
(D) Subscapular artery
(E) Thoracodorsal artery

Answer: (E) Thoracodorsal artery

Rationale:
The latissimus dorsi musculocutaneous flap is based on the thoracodorsal artery and is a reliable source of muscle and fat that can even be used with tissue expanders or implants for breast reconstruction. The thoracodorsal artery is a branch of the subscapular artery, which comes off the axillary artery. The lateral thoracic artery is one of the branches of the axillary artery.

Reference:
Hammond DC. Latissimus dorsi flap breast reconstruction. *Clin Plast Surg.* 2007;34(1):75–82.

۰۲۱-۶۶۱۹۸۵۱۴ www.myuptodate.com دریافت آخرین نسخه آپتودیت آفلاین

2E27

Key word: Etiology of Impaired Glucose in Type II Diabetes

Author: Joshua C. Grimm, MD
Editor: Andrew M. Cameron, MD, PhD

Which of the follow is true concerning glucose intolerance in type II diabetes mellitus?

(A) An increase in endogenous glucose production is by itself the causative factor of hyperglycemia in type II diabetes mellitus

(B) Global control of gluconeogenesis is mediated by a cyclic AMP regulated kinase

(C) Gluconeogenesis occurs solely in the bone marrow

(D) Gluconeogenesis occurs solely in the liver

(E) Glucose-6-phosphate can easily diffuse into and out of cells involved in glucose metabolism

Answer: (B) Global control of gluconeogenesis is mediated by a cyclic AMP regulated kinase

Rationale:
Type II diabetes mellitus is characterized by both defects in insulin secretion and function. It has been hypothesized that a defect in suppression of gluconeogenesis results in hyperglycemia, insulin resistance, and decreased glucose-mediated insulin secretion. Although most of this glucose production takes place in the liver, approximately 40% occurs in the kidney.

It is important to remember that several rate-limiting enzymes (phosphoenolpyruvate carboxykinase, fructose-1,6-bisphosphatase, and glucose-6-phosphatase) are controlled by insulin, and thus any defect in suppression of this pathway can lead to hyperglycemia. These enzymes are phosphorylated and therefore, activated by the key regulatory enzyme Protein kinase A. One of the final steps in both gluconeogenesis as well as glycogenolysis is activation of glucose-6-phosphatase, which cleaves a phosphate group to release a free glucose molecule. This glucose molecule can then traverse the cellular membrane, whereas movement of glucose-6-phosphate is restricted.

Reference:
Mangiafico SP, Lim SH, Neoh S, et al. A primary defect in glucose production alone cannot induce glucose intolerance without defects in insulin secretion. *J Endocrinol.* 2011; 210:335–347.

2E28

Key word: Impairment of PTH Production

Author: Seth D. Goldstein, MD
Editor: Alan P.B. Dackiw, MD, PhD, BSc, BSc(Med), FACS, FRCSC

A 73-year-old man who underwent a right thyroid lobectomy for a subcentimeter nodule 1 year ago now has persistent hypocalcemia refractory to increasing levels of vitamin D and calcium supplementation. He admits to having little appetite, a poor diet, and heavy alcohol use. On review of his hospital records, his serum calcium immediately postoperatively was normal. Treatment consideration should include:

(A) An appetite stimulant

(B) Diagnostic workup for malabsorption

(C) Magnesium supplementation

(D) Neck exploration to locate residual parathyroid glands

(E) Phosphorus supplementation

Answer: (C) Magnesium supplementation

Rationale:
Devascularization of the parathyroid glands with resultant hypocalcemia is a concern following thyroid surgery, but should not be as great a consideration after lobectomy, as the contralateral neck is untouched. Furthermore, this patient's hypocalcemia is refractory to supplementation and was noted to be normal postoperatively. The question stem does not mention any diarrhea or significant resection of bowel, making malabsorption also highly unlikely. In patients who are heavy alcohol users with overall poor nutritional status, low magnesium levels are common. Magnesium is a necessary cofactor for parathyroid hormone (PTH) production by the parathyroid gland. In this case the low magnesium levels are causing the hypocalcemia and only by first giving magnesium supplementation can the calcium levels be normalized.

Reference:
Lal G, Clark OH. Thyroid, parathyroid, and adrenal. In: Brunicardi FC, Andersen DK, Billiar TR, Dunn DL, Hunter JG, Matthews JB, Pollock RE, eds. *Schwartz's Principles of Surgery.* 9th ed. Columbus, OH: The McGraw-Hill Companies; 2010.

۰۲۱-۶۶۱۹۸۵۱۴ www.myuptodate.com دریافت آخرین نسخه آپتودیت آفلاین

2E29

Key word: Phosphorus Level in Hyperparathyroidism

Author: Seth D. Goldstein, MD
Editor: Alan P.B. Dackiw, MD, PhD, BSc, BSc(Med), FACS, FRCSC

A 49-year-old woman with diabetes and chronic renal insufficiency (creatinine 1.5 mg/dL) presents with a serum calcium of 11.4 mg/dL. Parathyroid hormone (PTH) is 70 pg/mL, phosphorus is 1.8 mg/dL, and vitamin D is 35 ng/mL. The next best step is to prescribe:

(A) Calcimimetic
(B) Oral magnesium
(C) Oral phosphate binder
(D) Sestamibi localization scan
(E) Vitamin D supplement

Answer: (D) Sestamibi localization scan

Rationale:
Primary hyperparathyroidism is unregulated secretion of PTH from one or more parathyroid glands. 80% of cases are caused by solitary parathyroid adenomas. PTH leads to an increase in serum calcium by stimulating bone breakdown with the release of calcium and phosphorous, increasing intestinal absorption of calcium via increasing levels of calcitriol from the kidney, and increasing renal reabsorption of calcium. Phosphorus reabsorption in the kidney is decreased leading to lower serum levels. Secondary hyperparathyroidism may be due to vitamin D deficiency, but the level described above is normal. Secondary hyperparathyroidism can also be secondary to chronic renal failure in which long-standing hypocalcemia and hyperphosphatemia are stimuli for parathyroid gland enlargement. Despite her history of renal insufficiency, the values presented in this question are consistent with primary hyperparathyroidism with an elevated PTH, elevated calcium, and low phosphorus level, making surgical resection the indicated treatment. In order to perform minimally invasive parathyroidectomy, the next step prior to surgery would be localization with a sestamibi scan.

Reference:
Fitzgerald P. Endocrine disorders. In: Doherty GM, ed. *Current Medical Diagnosis & Treatment.* 51st ed. Columbus, OH: The McGraw-Hill Companies; 2012.

2E30

Key word: Components of ACTH Stimulation Test

Author: Seth D. Goldstein, MD
Editor: Pamela A. Lipsett, MD, MHPE, FACS, FCCM

A 45-year-old man on high-dose oral steroids for ulcerative colitis presents for colectomy due to toxic megacolon. Postoperatively, he is lethargic and suffering from hypotension refractory to fluids and is begun on vasopressors. You wish to perform a diagnostic test for adrenal insufficiency. What is the correct test to evaluate this diagnosis?

(A) 1-mg dexamethasone administration at 11 pm with 8 am cortisol level
(B) 2-mg dexamethasone administration at 11 pm with 8 am cortisol level
(C) Serum adrenocorticotropic hormone (ACTH), 250-mcg cosyntropin administration, and repeat serum ACTH at 30 and 60 minutes
(D) Serum cortisol, 1-mg dexamethasone administration, and repeat serum cortisol at 30 and 60 minutes
(E) Serum cortisol, 250-mcg cosyntropin administration, and repeat serum cortisol at 30 and 60 minutes

Answer: (E) Serum cortisol, 250-mcg cosyntropin administration, and repeat serum cortisol at 30 and 60 minutes

Rationale:
Primary adrenal insufficiency results directly from adrenal gland disease secondary to such entities as autoimmune disease, hemorrhage/infarction, drug side effects, neoplasm, or infections such as tuberculosis, HIV or disseminated fungemia. In these cases, ACTH levels will be elevated, and cortisol levels will be low. Adrenal insufficiency of critical illness can also be included in this category. Secondary adrenal insufficiency is due to low levels of ACTH due to pituitary disease, and tertiary adrenal insufficiency is due to low levels of CRH at the level of the hypothalamus and is seen following resolution of Cushing syndrome or rapid withdrawal of exogenous glucocorticoids.

Acute adrenal insufficiency causes marked hypotension and can be rapidly diagnosed with cosyntropin stimulation test. The cortisol stimulation test consists of serum cortisol measurement, administration of the ACTH analog cosyntropin, and repeat measurements of serum cortisol at 30 and 60 minutes. Interpretation of the stimulation test is controversial, but peak cortisol levels of less than 20 µg/dL suggest adrenal insufficiency. In cases of critical illness or sepsis, the interpretation of the cosyntropin test is also controversial, and an increase from baseline to stimulated cortisol release should be >9. Dexamethasone suppression tests (either low or high dose) are used to diagnose Cushing syndrome.

۰۲۱-۶۶۱۹۸۵۱۴ www.myuptodate.com دریافت آخرین نسخه آپتودیت آفلاین

References:

Lal G, Clark OH. Thyroid, parathyroid, and adrenal. In: Brunicardi FC, Andersen DK, Billiar TR, Dunn DL, Hunter JG, Matthews JB, Pollock RE, eds. *Schwartz's Principles of Surgery.* 9th ed. Columbus, OH: The McGraw-Hill Companies; 2010.

Marik PE, Pastores SM, Annane D, et al. Recommendations for the diagnosis and management of corticosteroid insufficiency in critically ill adult patients: consensus statements from an international task force by the American College of Critical Care Medicine. *Crit Care Med.* 2008;36:1937–1949.

2E31

Key word: Conditions Associated with the Zollinger–Ellison Syndrome

Author: Isaac Howley, MD
Editor: Richard D. Schulick, MD, MBA, FACS

A 37-year-old man has had persistent peptic ulcer disease despite appropriate medical therapy and biopsy-confirmed eradication of *Helicobacter pylori.* Serum gastrin level, measured off acid-suppressing therapy, is 378 pg/mL (normal <100 pg/mL). After a 2 unit/kg dose of intravenous secretin, his gastrin level increases by 452 pg/mL above baseline, confirming the diagnosis of gastrinoma. His past medical history is unremarkable, and his physical examination is noted only for gynecomastia. Which of the following is true with regards to the management of gastrinoma?

(A) If localization cannot be achieved with noninvasive testing, medical management with proton pump inhibitors and octreotide is indicated

(B) If preoperative imaging shows distant metastases, surgery is contraindicated and chemotherapy with streptozocin, 5-fluorouracil, and doxorubicin should be initiated

(C) If the tumor cannot be demonstrated by operative exploration, potential surgical interventions are limited only to partial vagotomy

(D) Preoperative biochemical testing should include measurement of serum calcium to rule out associated disorders

(E) Right upper quadrant ultrasound is the most sensitive localizing modality

Answer: (D) Preoperative biochemical testing should include measurement of serum calcium to rule out associated disorders

Rationale:

Approximately 75% of gastrinomas occur spontaneously, and 25% are related to the multiple endocrine neoplasia syndrome type I (MEN1). MEN1 is a clinical syndrome caused by mutations in the tumor suppressor gene MENIN. Its three major components are parathyroid hyperplasia, pituitary adenomas, and pancreatic endocrine neoplasms. Of these three diseases, parathyroid hyperplasia is the most likely to occur, with 90% of MEN1 patients affected. Islet cell neoplasms affect 30% to 80%, and pituitary neoplasms occur in 15% to 50%. Due to the risk of perioperative hypercalcemic crisis, patients with gastrinoma should be screened for parathyroid disease. If present, they should undergo subtotal parathyroidectomy or total parathyroidectomy with autotransplantation before their abdominal operation.

Gastrinomas associated with MEN1 are more likely to be small, multiple, and undetectable; as such, surgical therapy is less likely to be successful at achieving cure. Localization is the first step in surgical therapy; transabdominal ultrasound and cross sectional imaging are insensitive modalities due to the small size of most gastrinomas and their similar densities

۰۲۱-۶۶۱۹۸۵۱۴ www.myuptodate.com دریافت آخرین نسخه آپتودیت آفلاین

compared with surrounding pancreatic tissues. More sensitive modalities include endoscopic ultrasound, percutaneous transhepatic venous sampling, and somatostatin receptor scintigraphy. When gastrinomas cannot be identified with preoperative imaging, operative exploration and intraoperative ultrasound of the "gastrinoma triangle" is indicated. If a tumor still cannot be identified either by palpation or ultrasound, operative options include partial vagotomy for symptomatic relief, empiric pancreaticoduodenectomy with distal gastrectomy, and total gastrectomy. Octreotide and proton pump inhibitor therapy may be of palliative benefit in patients whose tumors cannot be localized even after operation, or in patients with unresectable metastases. For patients with metastatic disease, debulking is still indicated for symptomatic relief. The standard chemotherapeutic regimen consists of streptozocin, 5-fluorouracil, and doxorubicin, although these are associated with a response rate of <50%.

References:

Doherty GM. Parathyroid glands. In: Mulholland MW, Lillemoe KD, Doherty GM, Maier RV, Upchurch GR, eds. *Wilkins Greenfield's Surgery: Scientific Principles & Practice.* 4th ed. Philadelphia, PA: Lippincott Williams & Wilkins; 2006: 880–891.

Riall TS, Yeo CJ. Neoplasms of the endocrine pancreas. In: Mulholland MW, Lillemoe KD, Doherty GM, Maier RV, Upchurch GR, eds. *Greenfield's Surgery: Scientific Principles & Practice.* 4th ed. Philadelphia, PA: Lippincott Williams & Wilkins; 2006: 880–891.

2E32

Key word: Hormone Excess in Male Breast Enlargement

Author: Emmanouil Pappou, MD
Editor: Lisa K. Jacobs, MD

Breast enlargement in men (gynecomastia) is caused by excess action of:

(A) Androgens
(B) Estrogens
(C) Follicle-stimulating hormone (FSH)
(D) Luteinizing hormone (LH)
(E) Oxytocin

Answer: **(B)** Estrogens

Rationale:

Gynecomastia is defined as a benign enlargement of male breast tissue due to proliferation of the glandular component and is the most common breast condition in men. It is thought to represent an imbalance between the stimulatory effect of estrogens and the inhibitory effect of androgens in the breast tissue. This usually results from an increased concentration of estrogen or its precursors. It may also result from decreased androgens levels, through either reduced secretion, increased metabolism, or increased binding to sex hormone-binding globulin (SHBG). It may also arise under normal physiologic hormonal levels when there is an abnormal tissue response due to an underlying defect at the receptor level.

Physiologic gynecomastia develops in 50% to 70% of healthy boys during puberty, most likely due to a relative imbalance in the androgen-to-estrogen ratio, and resolves spontaneously in most cases within 1 to 2 years, with less than 20% of men having gynecomastia by the age of 20 years. Numerous medications have been associated with gynecomastia, including hormones (androgens, anabolic steroids), antibiotics (metronidazole, ketoconazole), calcium channel blockers, spironolactone, H_2-receptor blockers, highly active antiretroviral therapy (HAART), and antipsychotic agents. Liver cirrhosis and hyperthyroidism can also lead to gynecomastia due to increased peripheral conversion of androgens to estrogens and increased serum SHBG levels, which subsequently lead to decreased free testosterone levels. Testicular neoplasms (e.g., Sertoli cell tumors), or feminizing adrenal tumors can also lead to gynecomastia, due to an excess production of estrogens. Primary hypogonadism of any cause (e.g., Klinefelter syndrome, testicular trauma, mumps orchitis) can result in gynecomastia. A deficiency of testosterone in these cases contributes to a relative estrogen excess. Chronic renal failure also predisposes to gynecomastia, due to Leydig cell dysfunction. Breast cancer is diagnosed in only about 1% of cases of gynecomastia.

Clinical evaluation of a man with gynecomastia includes a thorough history and physical examination, including examination of the testicles. Laboratory tests to evaluate liver, kidney, and thyroid function, as well as measurement of serum

۰۲۱-۶۶۱۹۸۵۱۴ www.myuptodate.com دریافت آخرین نسخه آپتودیت آفلاین

testosterone, LH, FSH, and prolactin should be performed. If a testicular tumor is suspected, an ultrasound examination may be helpful in identifying the neoplasm, along with serum tumor markers such as β-HCG or alpha-fetoprotein (AFP). Similarly, computed tomography of the adrenals may be helpful if an adrenal neoplasm is suspected on clinical grounds.

Management of gynecomastia depends on etiology, duration, and severity of disease. For asymptomatic adolescents, only observation with follow-up reevaluation is needed. For asymptomatic men with long-standing stable gynecomastia, no specific treatment may be necessary. Administration of tamoxifen is emerging as an effective therapy in many instances of asymptomatic gynecomastia when no identifiable cause is found. In men with persistent gynecomastia, surgery (liposuction, breast reduction) may be indicated.

References:

Braunstein GD. Clinical practice. Gynecomastia. *N Engl J Med.* 2007;357:1229–1237.

Cordova A, Moschella F. Algorithm for clinical evaluation and surgical treatment of gynaecomastia. *J Plast Reconstr Aesthet Surg.* 2008;61:41–49.

Johnson RE, Murad MH. Gynecomastia: pathophysiology, evaluation, and management. *Mayo Clin Proc.* 2009;84: 1010–1015.

۰۲۱-۶۶۱۹۸۵۱۴ www.myuptodate.com دریافت آخرین نسخه آپتودیت آفلاین

Index by Key Word

Key Word:	Number:	Exam Question Number:
Acid–Base Disturbances with Sulfamylon Treatment	2B80	2–223
Adaptive Immunotherapy for Tumors	1B47	1–199
Adjuncts to Improve Vascular Graft Patency	1C09	1–42
Adjuvant Chemotherapy for Sigmoid Carcinoma	1G40	1–183
Adjuvant Treatment of Colon Cancer	2B01	2–1
Adrenal Incidentaloma	1E20	1–87
Adult Caloric Supply for TPN	2B58	2–201
Advantage of Lytic Therapy for Lower-extremity Ischemia	1C03	1–12
Amino Acid which Enhances Immune Function	2B59	2–202
Anatomy of Replaced Right Hepatic Artery	1G44	1–194
Anatomy of Scalenus Anticus Muscle	1C25	1–152
Anatomy of the Cystic Duct	2G01	2–4
Anatomy of the Left Vertebral Artery	2C15	2–72
Anatomy of the Normal Upper Esophageal Sphincter	2G32	2–154
Anatomy of the Right Renal Artery	1M27	1–135
Anatomy of Thoracic Duct Drainage	2C16	2–77
Anesthetic Improving Outcomes after Rib Fractures	2C03	2–12
Angioplasty Site with Long Patency	1C01	1–2
Antibiotic Prophylaxis of Surgical Site Infection	2B02	2–6
Antibiotic Treatment of Emphysematous Cholecystitis	1B19	1–91
Antihypertensive Drug Associated with Chronic Cough	2M34	2–161
Arterial Supply for a Gastric Tube	1G13	1–64
Bacteriology of Human Bites	1B38	1–175
Best Test of Successful Treatment of H. Pylori	1G03	1–14
Best Treatment of Aortic Stenosis	2C04	2–17
Blood Supply of Latissimus Dorsi Myocutaneous Flap	2E26	2–128
Cell Type for Benign Gastric Ulcer	2G44	2–181
Changes in Cardiac Physiology during Pregnancy	2C05	2–22
Characteristics and Treatment of Multiple Endocrine Neoplasia	1E21	1–88
Characteristics of Addisonian Crisis	1E25	1–98
Characteristics of Confidence Intervals	1B52	1–209
Characteristics of Donor Nephrectomy	1M01	1–5
Characteristics of Early Excision of 40% Total Body Surface Area Burns	2B03	2–11
Characteristics of Epidural Analgesia	2B04	2–16
Characteristics of Extralobar Pulmonary Sequestration	1C36	1–188
Characteristics of Functional Residual Capacity	2C17	2–82
Characteristics of Gastrinomas	1E08	1–38
Characteristics of General Anesthesia	2B77	2–220
Characteristics of Glucagonoma	2E23	2–113
Characteristics of Hepatic Adenoma	2G36	2–165
Characteristics of Hypoaldosteronism	1E33	1–133
Characteristics of ITP Treatment	1E31	1–123

۰۲۱-۶۶۱۹۸۵۱۴ www.myuptodate.com دریافت آخرین نسخه آپتودیت آفلاین

Key Word:	Number:	Exam Question Number:
Characteristics of Left Ventricular Performance	2C18	2–87
Characteristics of Lipid Digestion and Absorption	1G52	1–210
Characteristics of Local Anesthetic Toxicity	1B07	1–31
Characteristics of Lymphatic Malformation of the Skin	1M03	1–15
Characteristics of Malignant Transformation of Nevi	2M01	2–5
Characteristics of Merkel Cell Cancer	1M02	1–10
Characteristics of Necrotizing Soft Tissue Infections	2B06	2–26
Characteristics of Normal Lower-extremity Venous Pressure Studies	1C30	1–170
Characteristics of NSQIP	1B04	1–16
Characteristics of Oncotic Pressure in Pulmonary Circulation	2C20	2–97
Characteristics of Parastomal Hernias	1G41	1–186
Characteristics of Primary Hyperaldosteronism	1G57	1–220
Characteristics of Primary Pulmonary Hypertension	2C19	2–92
Characteristics of Rest Pain	1C17	1–112
Characteristics of Sentinel Lymph Node Biopsy	1M25	1–125
Characteristics of Solid and Cystic Cancer of the Thyroid	1E02	1–8
Characteristics of Splenic Artery Aneurysms	1C23	1–142
Characteristics of Split-thickness Skin Grafts	1M09	1–45
Characteristics of T3 Colon Cancer	1G62	1–153
Characteristics of Thoracic Outlet Syndrome	1C10	1–47
Characterization of Process Measures	2B07	2–31
Classification of Endoleaks	1C07	1–32
Clinical Features of Pituitary Tumors	2M27	2–135
Common Complications of Popliteal Aneurysms	1C02	1–7
Common Effects of Benzodiazepines	2B81	2–224
Comparison of Somatic and Visceral Pain	2B60	2–203
Complication of Achalasia Operation	2G02	2–9
Complication of Late Reduction of Posterior Hip Dislocation	2M02	2–10
Complications after Nissen Fundoplication	1G25	1–124
Complications of Colonoscopic Polyp Removal	2G19	2–94
Complications of Hepatic Adenoma	1G35	1–168
Components Needed for Tacrolimus Absorption	2B76	2–219
Components of ACTH Stimulation Test	2E30	2–145
Concomitant Injury with Bilateral Calcaneal Fractures	2M03	2–15
Condition Associated with Family History of Cecal Cancer	1B02	1–6
Conditions Associated with Normal Anion Gap Acidosis	1B17	1–81
Conditions Associated with Persistent Fetal Circulation	2C21	2–102
Conditions Associated with Tertiary Hyperparathyroidism	1E03	1–13
Conditions Associated with the Zollinger–Ellison Syndrome	2E31	2–149
Contraindications to Laparoscopic Inguinal Hernia Repair	2B40	2–172
Contraindications to Pneumonectomy	1C34	1–182
Contraindications to TRAM Flap Reconstruction	1E32	1–128
Criteria for Liver Transplantation in Patients with Hepatocellular Carcinoma	2B41	2–174
Cytokine Treatment of Renal Cell Carcinoma	2B61	2–204
Definition of Active and Latent Error	2B08	2–36
Definition of Adverse Event	2B62	2–205

۰۲۱-۶۶۱۹۸۵۱۴ www.myuptodate.com دریافت آخرین نسخه آپتودیت آفلاین

Key Word:	Number:	Exam Question Number:
Definition of Vital Capacity	2C22	2–107
Design of T-tests	2B63	2–206
Determination of Cardiac Output and Systemic Vascular Resistance	1C26	1–157
Diagnosis and Treatment of Insulinomas	1E36	1–148
Diagnosis of Acute Gastric Dilation	1G21	1–104
Diagnosis of Afferent Limb Obstruction	1G26	1–129
Diagnosis of Alveolar Hypoventilation	2C06	2–27
Diagnosis of an Infected Burn Wound	1M29	1–145
Diagnosis of Appendicitis versus Acute Ileitis	1G01	1–4
Diagnosis of Biliary Dyskinesia	1G51	1–208
Diagnosis of Caustic Ingestion	1G08	1–39
Diagnosis of Colonic Pseudo-obstruction	1G14	1–69
Diagnosis of Common Bile Duct Stricture from Chronic Pancreatitis	1G22	1–109
Diagnosis of Division of Intercostobrachial Nerve	2E01	2–3
Diagnosis of Duodenal Stump Leak	2G03	2–14
Diagnosis of Ectopic Pregnancy	2M17	2–85
Diagnosis of Incarcerated Femoral Hernia	2B09	2–41
Diagnosis of Insulinoma	1E26	1–102
Diagnosis of Intraoperative Nerve Injury	2E02	2–8
Diagnosis of Lymphangiosarcoma	2E22	2–108
Diagnosis of Lymphocele in Deceased Donor Kidney Transplant	1B05	1–21
Diagnosis of Metabolic Alkalosis	1B28	1–136
Diagnosis of Paradoxic Aciduria	2B10	2–46
Diagnosis of Paralysis of the Common Peroneal Nerve	2M05	2–25
Diagnosis of Pelvic Inflammatory Disease/Tubo-ovarian Abscess	2M20	2–100
Diagnosis of Pericardial Tamponade after Stab Wounds to the Chest	2C01	2–2
Diagnosis of Primary Lung Cancer	1B31	1–151
Diagnosis of Refeeding Syndrome	2B11	2–51
Diagnosis of Staphylococcus Epidermidis Graft Infection	1C06	1–27
Diagnosis of Syndrome of Inappropriate Antidiuretic Hormone	2B12	2–56
Diagnosis of Thrombosis of Hepatic Artery after Liver Transplantation	1B15	1–71
Diagnosis of VIPoma	2G05	2–24
Diagnosis of Vitamin K Deficiency	2B13	2–61
Diagnostic Findings of Digital Paresthesias	2M04	2–20
Diagnostic Test for “Tearing” Chest Pain	1C21	1–132
Diagnostic Test for a Solitary Neck Mass	1M19	1–95
Diagnostic Test for a Tender Breast Mass	2E04	2–18
Diagnostic Test for Pituitary Tumor	2E24	2–118
Diagnostic Test for Recurrence of ITP	2E03	2–13
Diagnostic Test for Soft Tissue Sarcoma of the Thigh	1B16	1–76
Diagnostic Test for Suspected Boerhaave Syndrome	2G38	2–169
Diagnostic Test of Pleural Effusion after Laparoscopic Nissen Fundoplication	2G04	2–19
Diagnostic Test of Possible Abdominal Lymphoma	1E15	1–73
Diagnostic Testing of a Testicular Mass	2M06	2–30
Diagnostic Tests for the Etiology of Lower GI Bleeding	2G37	2–167
Difference in ARDS versus Ventilator-associated Pneumonia	1B10	1–46

۰۲۱-۶۶۱۹۸۵۱۴ www.myuptodate.com دریافت آخرین نسخه آپتودیت آفلاین

Key Word:	Number:	Exam Question Number:
Distribution of Insulinomas	1E34	1–138
Donor-site Healing in Split-thickness Skin Grafts	1M08	1–40
Earliest Symptom of Compartment Syndrome	1M31	1–155
Early Initiation of Enteral versus Parenteral Nutrition	2B44	2–180
Effect of AV Fistula on Cardiac Performance	1C32	1–176
Effect of Inhaled Nitric Oxide in Acute Respiratory Distress Syndrome Treatment	2C23	2–112
Effect of Inspiration Phase of Mechanical Ventilation on Cardiac Dynamics	1C37	1–191
Effect of Superior Laryngeal Nerve Injury	1E27	1–103
Effect of Use of Iodine Drapes	2B14	2–66
Effect of Use of Isolation Gowns	2B15	2–71
Effective Pain Control	2B24	2–116
Effects of Rapid Massive Transfusion	1B55	1–215
Electrolyte Abnormalities Associated with Pyloric Stenosis	2B82	2–225
Embryology of Indirect Hernias	2B45	2–182
Ethical Issues in Injury Prevention	2M07	2–35
Etiology of Arrhythmia in Torsade de Pointes	1B32	1–156
Etiology of Bleeding Pelvic Fractures	2M09	2–45
Etiology of Cushing Syndrome	1E05	1–23
Etiology of Grand Mal Seizure after Lidocaine Administration	2B16	2–76
Etiology of Hand Ischemia Following Arteriovenous Fistula Placement	2C24	2–117
Etiology of Hematogenous Metastases to the Small Bowel	1G09	1–44
Etiology of Hyponatremia in Pancreatitis	1B12	1–56
Etiology of Hypotension after Blunt Trauma	2B17	2–81
Etiology of Hypotension in Hemorrhagic versus Blunt Trauma	1B29	1–141
Etiology of Impaired Glucose in Type II Diabetes	2E27	2–133
Etiology of Increased Enzymes with Common Bile Duct Injury	2G06	2–29
Etiology of Late Death after Heart Transplant	1C08	1–37
Etiology of Late Hemorrhage of Vascular Grafts	1C05	1–22
Etiology of Paresthesias after Thyroid Surgery	2B18	2–86
Etiology of Post Femoral–Tibial Arterial Bypass Swelling	1E10	1–48
Etiology of Recurrence in Laparoscopic Hernia Repair	1B08	1–36
Etiology of Secondary Traumatic Brain Injury	2M08	2–40
Etiology of Shock after Aneurysm Repair	2B46	2–184
Etiology of Urinary Stones	2G45	2–183
Evaluation of Foregut Symptoms	2G07	2–34
Extrapyramidal Effects of Antiemetics	2B19	2–91
Findings Associated with Hepatorenal Syndrome	1G47	1–200
Findings Associated with Hypomagnesemia	1B37	1–172
Findings by Pulmonary Artery Catheter in a Patient with an Acute Myocardial Infarction	1C33	1–179
Findings in Vitamin D Deficiency	2E06	2–28
Findings of Acute Adrenal Insufficiency	2E05	2–23
Findings with Temporal Bone Fractures	2M10	2–50
Fluid Requirement with 30% TBSA Flame Burn	2B20	2–96
Fracture Associated with Major Vascular Compromise	2M11	2–55
Fracture Associated with Pain in the Anatomic Snuffbox	1M32	1–159
Function Recovery Postneuromuscular Block	2B64	2–207

۰۲۱-۶۶۱۹۸۵۱۴ www.myuptodate.com دریافت آخرین نسخه آپتودیت آفلاین

Key Word:	Number:	Exam Question Number:
GI Hemorrhage and Inhibition of Gastric Acid Secretion	2G42	2–177
Hair Removal in Contaminated Laceration Repair	2B21	2–101
Hemodynamic Effects of Tension Pneumothorax	2C25	2–122
Hemodynamic Findings in Septic Shock	1B34	1–163
Hemodynamic Findings in Septic Shock	2B22	2–106
Hemodynamics of Massive Pulmonary Embolism	2B34	2–159
Hormone Excess in Male Breast Enlargement	2E32	2–153
Human Factors in Injury Prevention	2M12	2–60
Hyperacute Rejection of Renal Transplants	1B39	1–178
Hypovolemic Shock	1C13	1–62
Immunosuppressant Side Effects	2B05	2–21
Impairment of PTH Production	2E28	2–137
Increased Bacterial Infection in Newborns versus Adults	1B43	1–190
Increased Cancer Incidence with Tamoxifen Therapy	1E07	1–33
Indication for Antibiotics with 40% TBSA Burns	2B23	2–111
Indication for CABG for Chronic Angina	2C07	2–32
Indication for Carotid Endarterectomy	1B44	1–193
Indications for Excisional Biopsy of Breast Mass	2E07	2–33
Indications for Liver Transplant in End-stage Liver Disease	1B23	1–111
Indications for Splenectomy	1E14	1–68
Indications for Surgery in Primary Hyperparathyroidism	1E22	1–92
Indications for Thoracotomy after Gunshot Wound to the Chest	1C20	1–127
Ineffective Injury Prevention Strategy	2M13	2–65
Inhibition of Keloid Formation	1M22	1–110
Initial IV Fluid in Treatment of Dehydration	1B14	1–66
Initial Treatment for Coagulopathy of Chronic Renal Failure	1B01	1–1
Initial Treatment for Respiratory Complications with Pancreatic Ascites	2G11	2–54
Initial Treatment of Adrenal Mass	2E08	2–38
Initial Treatment of Appendiceal Abscess	2G09	2–44
Initial Treatment of Diverticular Disease	2G08	2–39
Initial Treatment of Echinococcal Liver Cyst	2G10	2–49
Initial Treatment of Ischemic Orchitis after Hernia Repair	2B25	2–121
Initial Treatment of Vascular Steal Syndrome	2C08	2–37
Interpretation of Intraoperative Parathyroid Hormone Assay	1E23	1–93
Interpretation of Thyroid FNA	1E18	1–82
Laboratory Values Abnormal with von Willebrand Disease	1B42	1–187
Ligation of Artery in Bleeding Duodenal Ulcer	1G50	1–206
Likely Etiology of Acute Pulseless Leg	1C29	1–167
Lower Esophageal Sphincter Pressure during Swallowing	1G53	1–212
Lymphadenopathy in Thyroid Cancer	1E24	1–97
Maintenance of Core Temperature in the Operating Room	1B21	1–101
Major Limitations of Retrospective Clinical Studies	2B65	2–208
Major Modification of Tumor Cell Response	2B66	2–209
Mechanism of Action of Gastrin	1G48	1–202
Mechanism of Altered Immunity Postsplenectomy	1B40	1–181
Metabolic Condition Associated with Gastric Outlet Obstruction	1G56	1–218

۰۲۱-۶۶۱۹۸۵۱۴ www.myuptodate.com دریافت آخرین نسخه آپتودیت آفلاین

Key Word:	Number:	Exam Question Number:
Molecules which Mediate Leukocytosis in Inflammation	2B67	2–210
Monitoring Treatment of Low-molecular-weight Heparin	2B48	2–188
Most Abundant Fecal Bacterial Flora	1B41	1–184
Most Accurate Diagnostic Imaging in Meckel Diverticulum	1G54	1–214
Most Common Etiology of Common Bile Duct Injury in Laparoscopic Cholecystectomy	1G18	1–89
Most Common Etiology of Peptic Ulcer Disease	2G40	2–173
Most Common Hepatic Artery Variants	1B33	1–160
Most Common Hepatic Duct Aberration	2G50	2–193
Most Common Nerve Injured during Total Thyroidectomy	2E09	2–43
Most Common Reaction to Iodine Contrast	1B45	1–195
Most Common Side Effect of Mycophenolate	2B26	2–126
Most Common Side Effect of Pancuronium	1B49	1–203
Most Common Site of Lung Abscess	1C28	1–164
Most Effective Stimulant of Pancreatic Acinar Cells	1G46	1–198
Most Important Component in the Glasgow Coma Scale	1M13	1–65
Most Important Measure in Injury Outcome	2M14	2–70
Most Representative Descriptive Statistic	1B51	1–207
Most Representative Descriptive Statistic	2B68	2–211
Most Specific Diagnostic Imaging of Meckel Diverticulum	2G34	2–160
Narcotic with Greatest Potency	2B69	2–212
Nerve Injuries Associated with Lithotomy Positioning	2B50	2–192
Nerve Injury Associated with Anterior Dislocation of the Humerus	1M07	1–35
Nerve Injury During Laparoscopic Inguinal Hernia Repair	2B49	2–190
Nerve Injury Resulting from Calf Fasciotomy	1M05	1–25
Neurologic Findings Associated with Brain Death	2B51	2–194
Normal Cardiac Physiology in Infants	2C27	2–132
Operative Approach to Splenectomy	2E10	2–48
Optimal Cerebral Perfusion Pressure	1M15	1–75
Organism Associated with Multiple Liver Abscesses	1G55	1–216
Origin of Bilirubin	2G46	2–185
Pancreatic Enzyme Secretion	1G58	1–222
Pathologic Diagnosis of High-risk Breast Cancer	2E11	2–53
Patient at Highest Risk of Postsplenectomy Sepsis	1E35	1–143
Patient at Risk of Alloimmune Response Postabdominal Trauma	2B72	2–215
Patients with the Highest Rate of Breast Cancer	1G61	1–225
Perioperative Treatment of Hemophilia	1B53	1–211
Phosphorus Level in Hyperparathyroidism	2E29	2–141
Physiology of Truncal Vagotomy	1G30	1–149
Platelet Adherence after Tissue Injury	2B70	2–213
Poorest Prognosis in Cerebral Trauma	1M26	1–130
Preferred Route for Central Venous Access	1C18	1–117
Preoperative Measurement of Portal Venous Pressure	2G47	2–187
Preoperative Predictor of Perioperative Cardiac Complications	1B24	1–116
Preoperative Treatment of Increased INR from Warfarin	1B20	1–96
Prevention of Surgical Site Infections	1B35	1–166
Procedure with the Greatest Risk of Postoperative Small Bowel Obstruction	2G12	2–59

۰۲۱-۶۶۱۹۸۵۱۴ www.myuptodate.com دریافت آخرین نسخه آپتودیت آفلاین

Key Word:	Number:	Exam Question Number:
Process Measures of SCIP	2B52	2–195
Prognostic Factors for Thyroid Cancer	1E28	1–108
Prognostic Test of Liver Function Reserve	1G45	1–196
Prompt Formation of Platelet Plug	2B71	2–214
Prophylaxis against Venous Thrombosis	1M24	1–120
Radiation Associated with Thyroid Cancer	1E12	1–58
Rate of Nerve Regeneration	1E09	1–43
Rationale for Delayed Primary Wound Closure	1M28	1–140
Reduction of Nosocomial Infection on Ventilator	1B36	1–169
Renal Effects of PEEP	1C31	1–173
Repair of Extraperitoneal Bladder Rupture	2M29	2–143
Respiratory Quotient of Fat in TPN	1B25	1–121
Respiratory Quotient of Fatty Acid Synthesis	2B73	2–216
Response to Alveolar Hypoxia	2C26	2–127
Risk Factors for Abdominal Aortic Aneurysm	2C09	2–42
Risk of Rebleeding of Duodenal Ulcer	2G13	2–64
Risks of Infliximab Therapy	1B46	1–197
Risks of Long-term Immunosuppression	2B27	2–131
Sensitivity and Specificity of Screening Tests	2B78	2–221
Sentinel Lymph Node Biopsy for Melanoma	2B53	2–196
Sequence of Return of Bowel Motility	2G35	2–163
Sequence of Treatment in Multiple Endocrine Neoplasia	1E19	1–83
Significance of Actinic Keratosis	2M31	2–151
Site of Effect of Motilin	1G49	1–204
Site of Gastrointestinal Protein Absorption	2G41	2–175
Site of Intrinsic Factor Secretion	2G49	2–191
Site of Primary Tumor in Carcinoid Syndrome	1G39	1–180
Sources of Postoperative Intra-abdominal Infection	2B55	2–198
Staging of Hepatocellular Carcinoma	1B50	1–205
Staging of Soft Tissue Sarcoma	1B54	1–213
Staging of Soft Tissue Sarcoma	2B38	2–168
Staging of Testicular Germ Cell Tumors	2B56	2–199
Surgical Treatment of Clostridium difficile Colitis	2G29	2–142
Surgical Treatment of Rectal Prolapse	2G30	2–146
Surveillance for Recurrent Colorectal Cancer	2G43	2–179
Synergism of Ampicillin and Sulbactam	2B79	2–222
Technique of Component Separation for Ventral Hernia Repair	2B39	2–170
Tetanus Prophylaxis	1B09	1–41
Timing of Cholecystectomy after Myocardial Infarction	2G31	2–150
TPN Component Adjusted in Renal Insufficiency	2B57	2–200
Treatment of “Missing” Parathyroid	1E29	1–113
Treatment of 0.6-mm Melanoma of the Forearm	1B18	1–86
Treatment of 1.7-mm Melanoma of the Trunk	1M30	1–150
Treatment of a Dark Stoma Following Abdominoperineal Resection	1G20	1–99
Treatment of a Supracondylar Fracture of the Humerus in a Child	1M12	1–60
Treatment of Acute Paronychia	2B75	2–218

۰۲۱-۶۶۱۹۸۵۱۴ www.myuptodate.com دریافت آخرین نسخه آپتودیت آفلاین

Key Word:	Number:	Exam Question Number:
Treatment of Adenocarcinoma of the Appendix	2G14	2–69
Treatment of Adenocarcinoma of the Lung	1C35	1–185
Treatment of Air Embolus	1C12	1–57
Treatment of Amebic Liver Abscess	2G15	2–74
Treatment of an Incidental Adrenal Mass	2E13	2–63
Treatment of Anal Fissure with Rectal Bleeding	1G11	1–54
Treatment of Atypical Ductal Hyperplasia of the Breast	1E11	1–53
Treatment of Autoimmune Pancreatitis	2G16	2–79
Treatment of Barrett Esophagus with High-grade Dysplasia	1G33	1–162
Treatment of Bleeding Associated with Clopidogrel	2B28	2–136
Treatment of Breast Cancer with Negative Sentinel Lymph Node Biopsy	2E12	2–58
Treatment of Buccal Squamous Cell Carcinoma	1M18	1–90
Treatment of C. difficile in Pregnancy	1G10	1–49
Treatment of Cancer at the Hepatic Flexure	1G60	1–224
Treatment of Cardiac Tamponade	1C19	1–122
Treatment of Carotid Fibromuscular Dysplasia	1C27	1–161
Treatment of Choledochal Cyst	1G31	1–154
Treatment of Chronic Pancreatitis	1G36	1–171
Treatment of CO_2 Embolus during Laparoscopic Cholecystectomy	1B06	1–26
Treatment of Colon Cancer Metastases to the Liver	1G06	1–29
Treatment of Common Bile Duct Injury during Laparoscopic Cholecystectomy	2G22	2–109
Treatment of Complications of Femoral Nerve Block	2B29	2–140
Treatment of Compression Fractures at the Thoracolumbar Junction	2M15	2–75
Treatment of Depressed Skull Fracture	2M16	2–80
Treatment of Diverticulum of the Duodenum	1G43	1–192
Treatment of Duodenal Carcinoid	2G18	2–89
Treatment of Duodenal Obstruction in Crohn Disease	1G07	1–34
Treatment of Duodenojejunal Adenocarcinoma	1G19	1–94
Treatment of Embolus Post-myocardial Infarction	1C04	1–17
Treatment of Empyema	2C11	2–52
Treatment of Endovascular Graft Failure Types I to V	2C12	2–57
Treatment of Epidermoid Cancer of Neck Lymph Nodes	1M14	1–70
Treatment of Esophageal Leiomyoma	1G29	1–144
Treatment of Esophageal Perforation	1G12	1–59
Treatment of Focal Nodular Hyperplasia of the Liver	1G28	1–139
Treatment of Fournier Gangrene	1B22	1–106
Treatment of Fournier Gangrene	2B30	2–144
Treatment of Gallbladder Carcinoma	1G23	1–114
Treatment of Gallstone Ileus	1G15	1–74
Treatment of Gallstone Pancreatitis	2G20	2–99
Treatment of Gastric Adenocarcinoma of the Lesser Curvature	2G21	2–104
Treatment of Gastrinoma of the Duodenum	1G34	1–165
Treatment of Gastrointestinal Stromal Tumors	1G38	1–177
Treatment of Graft Infection after Abdominal Aortic Aneurysm Repair	2C13	2–62
Treatment of Head injury with Hypotension	2M18	2–90
Treatment of Heparin-induced Thrombocytopenia	2B31	2–148

۰۲۱-۶۶۱۹۸۵۱۴ www.myuptodate.com دریافت آخرین نسخه آپتودیت آفلاین

Key Word:	Number:	Exam Question Number:
Treatment of Hepatic Artery Aneurysm	1C22	1–137
Treatment of Hypercalcemic Crisis	2E25	2–123
Treatment of Hypochloremic Alkalosis	1B27	1–131
Treatment of Hyponatremia in Cirrhosis	2B32	2–152
Treatment of Hypotension after Removal of Pheochromocytoma	1B13	1–61
Treatment of Hypothermia	1B26	1–126
Treatment of Inadvertent Intraoperative Ureteral Injury	1M04	1–20
Treatment of Incarcerated Inguinal Hernia	1B11	1–51
Treatment of Incompletely Reduced Ileocolic Intussusception	1G24	1–119
Treatment of Increased Homocysteine Levels	2G48	2–189
Treatment of Infected IV Site	1B58	1–221
Treatment of Inflammatory Breast Cancer	1E13	1–63
Treatment of Insulinoma of the Pancreatic Head	1E30	1–118
Treatment of Intraductal Papilloma of the Breast	1E17	1–78
Treatment of Intraoperative Bradycardia	2B33	2–156
Treatment of Invasive Ductal Breast Cancer	2E14	2–68
Treatment of Liver Hemobilia	1G04	1–19
Treatment of Lobular Carcinoma In Situ of the Breast	1E06	1–28
Treatment of Lymphoma of the Small Bowel	2E18	2–88
Treatment of MALT Lymphoma	1G27	1–134
Treatment of Medullary Thyroid Cancer	2E15	2–73
Treatment of Metastatic Ovarian Cancer	1M10	1–50
Treatment of Metastatic VIPoma	1E01	1–3
Treatment of Myocardial Infarction	2B35	2–162
Treatment of Necrotizing Fasciitis	1M16	1–80
Treatment of Neurogenic Shock in a Quadriplegic	2B42	2–176
Treatment of Obstruction of the Ampulla during Laparoscopic Cholecystectomy	2G23	2–114
Treatment of Obturator Hernias	2B43	2–178
Treatment of Occlusion of the Common Iliac Artery in Patients with COPD	1C11	1–52
Treatment of Ovarian Cysts	2M19	2–95
Treatment of Oxycodone Toxicity	2B36	2–164
Treatment of Pancreatic Fistula	1G59	1–223
Treatment of Papillary Thyroid Cancer with Lymph Node Metastases	2E16	2–78
Treatment of Parathyroid Hyperplasia	2E17	2–83
Treatment of Parotid Mass	1M17	1–85
Treatment of Patient with AAA and Sigmoid Colon Cancer	2C10	2–47
Treatment of Pelvic Fractures	1M23	1–115
Treatment of Penetrating Renal Trauma	1M21	1–105
Treatment of Penile Cancer	2M26	2–130
Treatment of Persistent Fistula-in-ano	2G24	2–119
Treatment of Pharyngeal Diverticulum	2G25	2–124
Treatment of Phyllodes Tumor of the Breast	1E04	1–18
Treatment of Plantar Ulcer	1C14	1–67
Treatment of Pneumatosis Intestinalis and Inguinal Hernia	2G26	2–129
Treatment of Postoperative Arrhythmia	2C02	2–7
Treatment of Postoperative Parotitis	2M30	2–147

۰۲۱-۶۶۱۹۸۵۱۴ www.myuptodate.com دریافت آخرین نسخه آپتودیت آفلاین

Key Word:	Number:	Exam Question Number:
Treatment of Pulmonary Contusion	1C16	1–107
Treatment of Pyogenic Liver Abscess	2G27	2–134
Treatment of Recent 4-cm Pancreatic Pseudocyst	1G02	1–9
Treatment of Rectal Adenocarcinoma	1G42	1–189
Treatment of Rectal Bleeding after Hemorrhoid Banding	1G05	1–24
Treatment of Rectal Bleeding after Laminectomy	1M20	1–100
Treatment of Recurrent Laryngeal Nerve Injury	2M21	2–105
Treatment of Recurrent Sigmoid Volvulus	2G39	2–171
Treatment of Reflex Sympathetic Dystrophy	2B74	2–217
Treatment of Respiratory Burn	1B30	1–146
Treatment of Retained Common Bile Duct Stone after T-tube	1G16	1–79
Treatment of Spontaneous Pneumothorax	2C14	2–67
Treatment of Squamous Cell Carcinoma of the Anal Canal	1G17	1–84
Treatment of Squamous Cell Carcinoma of the Lower Lip	1M06	1–30
Treatment of Superior Vena Cava Syndrome	1C15	1–72
Treatment of Syndrome of Inappropriate ADH Secretion (SIADH)	1M11	1–55
Treatment of Tachyarrhythmias	1C24	1–147
Treatment of Testicular Torsion	2M22	2–110
Treatment of Thrombosed Ovarian Vein	2M25	2–125
Treatment of Thyroid Crisis	2E21	2–103
Treatment of Thyroiditis during Pregnancy	2E20	2–98
Treatment of Tongue Cancer	2M28	2–139
Treatment of Toxic Nodular Goiter	2E19	2–93
Treatment of Tracheo-neoesophageal Fistula after Esophagectomy	2G17	2–84
Treatment of Tracheoinnominate Fistula	2M23	2–115
Treatment of Tumor of the Bronchus	2B47	2–186
Treatment of Umbilical Hernia with Ascites	1B03	1–11
Treatment of Urokinase Overdose	1B56	1–217
Treatment of Villous Adenoma	2G28	2–138
Treatment of von Willebrand Disease	2B37	2–166
Treatment of Warfarin-induced Skin Necrosis	2B54	2–197
Treatment of Warthin Tumor	2M24	2–120
Treatment to Close Fistula Secondary to Crohn Disease	1G37	1–174
Unresectable Pancreatic Cancer	1G32	1–158
Urinary Retention Post-hemorrhoidectomy	1B57	1–219
Urinary Stones after Ileal Resection	2M32	2–155
Urine Concentrations with Aldosterone-secreting Tumors	2M33	2–158
Vitamin K-dependent Clotting Factors	2G33	2–157
Workup of Thyroid Nodule	1E16	1–77
Zinc Deficiency Secondary to TPN	1B48	1–201

۰۲۱-۶۶۱۹۸۵۱۴ www.myuptodate.com دریافت آخرین نسخه آپتودیت آفلاین

Index

Note: Page number followed by f and t indicates figure and table respectively.

A
Abdominal aortic aneurysm (AAA), 169
  repair of
    and aortic graft infection, 431
    shock after, 354
  risk factors for, 427
  and sigmoid colon cancer, 428
Abdominal lymphoma, 239
Abdominal suture rectopexy, 404, 405f
Abdominoperineal resection, 124
Accessory hepatic artery, 145
ACE inhibitor-induced cough, 472
Acetaminophen, in critically ill patients, 334
Acetazolamide, 77
Acetylcholine, 147
Achalasia, 153, 385
  surgical treatment of, 385
Acid–base disturbances, with sulfamylon treatment, 380
ACTH. *See* Adrenocorticotropic hormone (ACTH)
ACTH stimulation test, 493
Actinic keratosis, 469–470, 469f
Active errors, 323
Active external rewarming, 77
Acute adrenal insufficiency. *See* Addisonian crisis
Acute gastric dilatation, 124
Acute hemolytic transfusion reaction, 101
Acute ischemia of lower extremity, 190
Acute paronychia, 376, 377f
Acute respiratory distress syndrome (ARDS), 63–64, 64f, 440
  diagnostic criteria for, 64t
  inhaled nitric oxide in, effects of, 441
  and ventilator-associated pneumonia, 64
Acute tubular necrosis (ATN), 147, 192
Adaptive immunotherapy, for tumors, 95
Addisonian crisis, 247
Adenocarcinoma
  of appendix, 394
  gastric, 398
  of lung, 194–196, 197f
  rectal, 144
  small bowel, 123
Adenomatous polyps, 403
ADH. *See* Antidiuretic hormone (ADH)
Adjuvant therapy, for colon cancer, 316–317
Adrenalectomy, 242, 243
Adrenal incidentalomas, 243, 478, 478t
  diagnosis and management of, 482, 483f
Adrenal insufficiency
  acute, 476, 493
  secondary, 493
Adrenocorticotropic hormone (ACTH), 231, 478
Adverse event, 368
Advisory Committee on Immunization Practices (ACIP), 62
Afferent limb obstruction, 130
Afterdrop, 77
Air embolus, treatment of, 176–177
Airway obstruction, in inhalational burn injury victims, 80
Aldosterone, 156, 471, 471f, 471t
Aldosterone-secreting tumors, urine concentrations with, 471
Alemtuzumab, 370
Alpha fetoprotein (AFP), 364
Alveolar hypoventilation, 425–426
Alveolar hypoxia, response to, 443
Alveolar ventilation, 425
Amebic hepatic abscesses, 394, 395f
Amebic liver abscesses, 154–155, 155f
American College of Cardiology, 74
American College of Obstetricians and Gynecologists, 232
American Heart Association, 74
American Joint Committee on Cancer (AJCC), staging system
  anal canal cancer, 121t
  cervical lymph node metastases, 467t
  cutaneous melanoma, 223t, 224t
  gallbladder carcinoma, 127t
  hepatocellular carcinoma, 97t
  primary tumors of oropharynx, 467t
  soft tissue sarcomas, 100, 100t
  TNM staging classification of colorectal cancer, 163t
American Society of Clinical Oncology (ASCO), 414
American Society of Colon and Rectal Surgeons (ASCRS), 414
Aminocaproic acid, 102
Aminopyrine breath test, 146
Amiodarone, 422
Amphotericin B, 223
Ampicillin, 379
  and sulbactam, 379
Amsterdam criteria, for Lynch syndrome, 56
Anal canal, squamous cell carcinoma of, 121–122, 121t
Anal fissures, 114
Anaplastic carcinoma, 237
Aneurysm
  abdominal aortic, 169 (*see also* Abdominal aortic aneurysm (AAA))
  popliteal, 166
  splenic artery, 185
Angina, chronic, coronary artery bypass grafting and, 426
Angioplasty, percutaneous transluminal, 166, 175
Angiotensin-converting enzyme (ACE) inhibitors, 472
Anion gap metabolic acidosis, normal, 69
Ankle–brachial index (ABI), 181
Anterior dislocation shoulder, injury associated with, 448t
Antibiotic-associated diarrhea, 114
Antibiotics
  for burn wounds, 333
  for Fournier gangrene, 338
  for surgical site infection prevention, 318
Antidiuretic hormone (ADH), 326, 340
Antiemetics, extrapyramidal effects of, 331
Aortic arch, branch of, 433f
Aortic graft, infection of, after aneurysm repair, 431
Aortic stenosis
  grading of, 424
  treatment of, 424–425
Aortic valve replacement (AVR), 425
Aortobifemoral artery bypass, 175
APC gene, mutations in, 56
Apnea test, 358
Appendiceal abscess, 390
Appendiceal tumors, 394
Appendicitis, 107
  and acute ileitis, differentiation between, 107
ARDS. *See* Acute respiratory distress syndrome (ARDS)
Argatroban, 339
Arrhythmia in Torsade de pointes, etiology of, 81
Arterial gas embolism (AGE), 176, 177
Arterial supply, for gastric tube, 116, 117f
Arteriovenous fistula (AVF), 192, 441–442
  cardiovascular effects of, 192
Ascites, 58
Ascorbic acid, 327
Asherman syndrome, 460
Aspirin, 110, 342
  in graft patency, 173
Asplenic patients, sepsis and, 89–90, 254–255
Asymptomatic Carotid Atherosclerosis (ACAS) trial, 92
Atherosclerosis, accelerated, 173
ATN. *See* Acute tubular necrosis (ATN)
Atrial fibrillation, 186, 422–423
Atropine, 341, 422
Atypical ductal hyperplasia (ADH) of breast, 236, 481
Autoimmune pancreatitis, 395
Avascular necrosis of femoral head, 447
AVF. *See* Arteriovenous fistula (AVF)
Axillary lymph node dissection (ALND), 474
Axillary nerve, 205
Azathioprine, 320

۰۲۱-۶۶۱۹۸۵۱۴ www.myuptodate.com دریافت آخرین نسخه آپتودیت آفلاین

B
Bacteroides vulgatus, 90
Ballistic injuries, 234
Balloon kyphoplasty, 457
Barium swallow, 389
Barrett esophagus with high-grade dysplasia, 138
B-cells, 371
Beck triad, 182
Benign gastric ulcer, 415
Bennett fracture, 226
Benzodiazepines, effects of, 380
β-human chorionic gonadotropin (β-hCG), 364
Beta-hemolytic streptococcus, 89, 190
Beta-lactamases, 379
Bethesda criteria, 241
  for Lynch syndrome, 56
Bevacizumab, 368, 370
Bilateral prophylactic mastectomy, 232
Bile duct
  anatomy, 419–420, 420f
  injury, 389
Biliary dyskinesia, 152
Bilirubin, 416
Billroth II reconstruction, 130f
Bisacodyl, 216
Bivalirudin, 339
Bladder rupture, 468
Bleeding
  clopidogrel and, 336
  diathesis, 55
  rectal, 110
Blood transfusions, effects of, 101
Boerhaave syndrome, 411, 411f
Botulinum toxin, for anal fissures, 114
Bowel motility, sequence of return of, 409
Bowel obstruction, small, 392, 392t
BRAC gene, mutations in, 56, 162
Bradycardia, intraoperative, 341
Bradykinin-induced sensitization, of airway sensory nerves, 472
BRAF protein, 446
Brain death
  definition, 358
  neurologic findings with, 358–359
Branham–Nicoladoni sign, 192
Breast
  atypical ductal hyperplasia of, 236
  inflammatory carcinoma of, 238
  intraductal papillomas of, 240
Breast cancer, 56
  high-risk, pathologic diagnosis of, 481
  invasive ductal, 484
  lobular carcinoma in situ, 232
  negative sentinel lymph node biopsy for, 481–482, 481t
  phyllodes tumors, 230
  risk factors for development of, 162
Breast-conserving therapy, 484
Breast mass
  assessment of, 475
  excisional biopsy of, 477
Bromocriptine, 465
Bronchoscopy, for carcinoid tumors, 355
Buccal mucosa squamous cell carcinoma, 215
Bupivacaine, 60, 61t
Buprenorphine, 334
Burn injury, inhalational, 80
Burn wound excision, early, 319
Burn wound infection, 222
  bacterial infections, 222
  fungal infections, 223
Burn wounds, systemic antibiotics for, 333
Butorphanol, 334

C
Cabergoline, 465
CABG. *See* Coronary artery bypass grafting (CABG)
Calcaneal fractures, 447
  concomitant injuries with, 447–448
Calcitonin, 491
Calcium-based kidney stones, 416
Calcium oxalate stones, 416, 470
Calf fasciotomy, 204
Campylobacter jejuni, 107
Cancer
  colon, 316–317
  monoclonal antibody therapy of, 370
Cancer Antigen 19–9, 137
Cancer vaccines, 95
Candida glabrata, 363
Candida krusei, 363
Capsule endoscopy, 410
Carcinoembryonic antigen (CEA), 415
Carcinoid syndrome, 142
Carcinoid tumors, 142, 355, 394
Cardiac complications
  perioperative, estimation of, 74–75
  refeeding syndrome and, 325–326
Cardiac output (CO), calculation of, 188
Cardiac physiology, in infants, 443
Cardiac tamponade, 182
Cardiogenic shock, 193
Carinal pneumonectomy, 355
Carotid artery endarterectomy, 92–93
Carotid fibromuscular dysplasia, 189
Carpal tunnel syndrome, 449
Case-control studies, 370
CASS trial, 75
Catheter, epidural, 319
Caustic ingestion, 112–113
CCK. *See* Cholecystokinin (CCK)
Center for Disease Control, 62
Central venous catheterization, 182
Cerebral perfusion pressure (CPP), 211, 451
Cerebral trauma, 221
Cetuximab, 370
Chest pain, tearing, 183–184
Child–Pugh classification, 417t
Chlamydia trachomatis, 460
2-Chloroprocaine, 61t
Cholecystectomy, 60, 152
  after myocardial infarction, 406
Cholecystokinin (CCK), 147, 150
Cholecystokinin-cholescintigraphy (CCK-CS), 152
Choledochal cysts, 135
  classification of, 135–136, 136f
    type I cysts, 135
    type II cysts, 136
    type III cysts, 136
    type IV cysts, 136
  management of, 136
Chronic obstructive pulmonary disease (COPD), 175
Chronic pancreatitis, 139
  and common bile duct strictures, 125
Chronic renal failure (CRF), 55
Ciprofloxacin, 81
Cirrhosis, 58
Cisplatin, 121–122
Clindamycin, 114
Clopidogrel, 173
Clopidogrel-associated coagulopathy, 336
Clostridium difficile, 328
  colitis, surgical treatment of, 404
  infection in pregnancy, 114
Coagulopathy, 55
CO_2 embolus, 60
Colles fracture, 226
Colon cancer
  adjuvant therapy for, 316–317
  metastases to liver, 110
  staging of, 316t–317t
Colonic perforation, colonoscopy and, 397
Colonic pseudo-obstruction, 117–118, 118f
Colonoscopy, 397, 410
  lower gastrointestinal bleeding and, 410
Colorectal cancer, 159, 161f
  recurrence of, surveillance for, 414–415
  staging of, 160t
Colorectal polyps, 403
Colostomy, dark bowel in, 124
Common bile duct, 385
  exploration, 120
  injury to, laparoscopic cholecystectomy and, 122, 122f, 399
  strictures, 125, 125f
Common iliac artery, occlusion of, 175
Common peroneal nerve
  injury to, lithotomy positioning and, 358
  paralysis of, 449
Communicating hydrocele, 354
Compartment syndromes, 225, 235
Complex regional pain syndrome (CRPS), 375
  management of, 376
  stages of, 375–376
  type I, 375
  type II, 375
Component separation, for ventral hernia repair, 347–348, 348f
Compression fractures, thoracolumbar, 456–457
Computed tomography, for ovarian vein thrombosis, 464
Confidence intervals, 98
Conjugated estrogens, 55
Conn syndrome, 156
Constipation, 216
Contraction alkalosis, 79
Copper deficiency, 95
Cord hydrocele, 354

۰۲۱-۶۶۱۹۸۵۱۴ www.myuptodate.com دریافت آخرین نسخه آپتودیت آفلاین

Core-needle biopsy, for intraductal papilloma, 240
Core temperature in operating room, maintenance of, 72
Coronary artery bypass grafting (CABG), 75, 426
Corpus luteum cysts, 459
CPP. *See* Cerebral perfusion pressure (CPP)
Critically ill patients
  daily caloric requirements in, 366
  enteral nutrition *vs.* parenteral nutrition in, 353
Critically ill surgical patients, invasive fungal infection in, 363
Crohn disease, 111
Cross-sectional surveys, 370
CRPS. *See* Complex regional pain syndrome (CRPS)
Cryoprecipitate, 55, 102, 336
Crystalloid solutions, intravenous, 78t
Cushing syndrome, 231
  ACTH-dependent, 490
  ACTH-independent, 490
Cyclosporine, 335
Cystic duct, anatomy of, 385
Cystine stones, 416
Cytochrome P450 enzyme CYP3A, 377
Cytokine therapy, for renal cell carcinoma, 368

D
Dark Stoma, 124
DDAVP. *See* Desmopressin (DDAVP)
Deep peroneal nerve, 204, 449
Deep venous thrombosis (DVT), 219–220
Delayed hemolytic transfusion reaction, 101
Delayed primary wound closure, 222
Depressed skull fractures, 457–458, 458t
Dermoid tumors, 460
Descriptive statistics, 97, 371
Desmopressin (DDAVP), 55, 91, 336, 343
Dexamethasone suppression tests, 493
Dezocine, 334
Diabetes
  as contraindication to kidney donation, 202
  plantar ulcers in, 178
Diabetes mellitus, type II, 492
Dialysis, 55
Diarrhea, and mycophenolate mofetil, 335
Digital paresthesias, 449
Direct thrombin inhibitors, 339
Direct venous cannulation, 191
Distal radius fracture, associated injury with, 448t
Distal revascularization–interval ligation (DRIL) procedure, for ischemic steal syndrome, 441–442, 442f
Diverticular disease, initial management of, 390
Dopamine, 351
Doxacurium, 96
Ductal carcinoma in situ (DCIS), 236
Duodenal carcinoid, 397
Duodenal diverticula, 144
Duodenal gastrinomas, 138
Duodenal obstruction, in Crohn disease, 111
Duodenal stump insufficiency, 386
Duodenal stump leakage, 130
Duodenal ulcers
  bleeding, 151, 151f
  risk of rebleeding of, 393
Duodenojejunal adenocarcinoma, 123
Duodenojejunostomy, 123
Duplex Doppler ultrasonography, for venous valvular competency, 191
Duplex ultrasonography, 427
Dutch Bypass Oral Anticoagulants or Aspirin (BOA) trial, 173
Dysphagia, 129, 389
Dyspnea on exertion, 437

E
Early Breast Cancer Trialists' Collaborative Group, 233
Ebstein anomaly, 198
Echinococcal liver cyst, 391
Echinococcus, 155
Echinococcus multilocularis, 391
Ectopic pregnancy, 458
  ruptured, 458
Electrolyte abnormalities, with pyloric stenosis, 381
Electrolyte disturbances, refeeding syndrome and, 325–326
Embolectomy, percutaneous, 168
Embolic disease, 190
Embolus
  CO_2, 60
  postmyocardial infarction, 168
Emphysematous cholecystitis, 71
  antibiotic treatment of, 71
Empyema, 429
Endoleaks, 171, 430, 430f
  classification, 171
  definition, 171
Endometrial adenocarcinoma, 232
Endoscopic retrograde cholangiopancreatography (ERCP), 120, 391
Endoscopic staple diverticulectomy, 401
Endoscopic ultrasound, 255, 389, 397
Endoscopy, 389
Endovascular aneurysm repair (EVAR), 171, 428
Endovascular stenting, of superior vena cava, 179
End-stage liver disease, liver transplant in, 74
Energy requirements calculations of, 366
Engineering, 455
Entamoeba histolytica, 154, 394
Enteral nutrition, 353
Enterobacter, 169, 170
Enterococcus faecalis, 90
Enterokinase, 158
Epidermoid cancer of neck lymph nodes, 211
Epididymitis, 462
Epidural analgesia, characteristics of, 319
Epidural anesthesia, 423–424
Errors, in health care, 323. *See also* Human errors
Escherichia coli, 90, 338, 379
Esophageal leiomyomas, 133–134, 133f
Esophageal manometry, 389
Esophageal perforation
  causes of, 115
  clinical presentation of, 115
  treatment of, 115–116
Esophagectomy, 138, 385
Esophagogastroduodenoscopy, 389
Esophagoscopy, in esophageal leiomyomas, 133
Ethical issues, in injury prevention, 450–451
European Carotid Stenosis Trail (ECST), 92
Excisional biopsy
  of breast mass, 477
  with wire localization, 236
Expanded polytetrafluroethylene (ePTFE), 169
Expiratory reserve volume (ERV), 435t
Exploratory laparotomy, for stone removal, 118
Extended left hepatectomy, 110
External branch of superior laryngeal nerve (EBSLN), 479, 479f
Extralobar sequestration of lung, 198
Extraperitoneal bladder rupture, repair of, 468

F
Facial nerve injury, 453
Factor IX deficiency, 372
Factor VIII deficiency, 372
Fall, hyperflexion and axial loading injury after, 448f
Familial adenomatous polyposis (FAP), 56
Fasciotomy, calf, 204
FAST. *See* Focused abdominal sonography for trauma (FAST)
Fecal bacterial flora, 90
Femoral hernia, incarcerated, 323–324
Femoral nerve block, complications and treatment, 337
Fentanyl, in critically ill patients, 334
Fetomaternal hemorrhage (FMH), 374
FFP. *See* Fresh frozen plasma (FFP)
Fiber supplementation, 110
Fibromuscular dysplasia (FMD), 189
Fick equation, 188
Fine-needle aspiration (FNA)
  for salivary gland neoplasms, 213
  for solitary thyroid masses, 216
  of thyroid nodule, 241
Fistula-in-ano, 400, 401f
Fistulotomy, 400
Fitz-Hugh–Curtis syndrome, 460
Fluconazole, 363
Flumazenil, 380
5-fluorouracil, 121, 228
FNA. *See* Fine-needle aspiration (FNA)
Focal nodular hyperplasia (FNH), of liver, 132, 132f, 409
Focused abdominal sonography for trauma (FAST), 218, 459
Follicular carcinoma, 228, 237
Follicular cysts, 459
Football injuries, 205

۰۲۱-۶۶۱۹۸۵۱۴ www.myuptodate.com دریافت آخرین نسخه آپتودیت آفلاین

Forced-air warming devices, 72
Foregut symptoms, evaluation of, 389
Fournier gangrene, 73, 338
Fractures, supracondylar, 209
Frank–Starling relationship, 436
Fresh frozen plasma (FFP), 72, 102, 336
Full-thickness skin grafts (FTSGs), 207
Functional residual capacity (FRC), 435, 435t
Fungal infection, invasive, 363
Furosemide, 491

G
Gallbladder carcinoma, 127t
Gallstone ileus, 118
Gallstone pancreatitis, 398
Gartland classification, for supracondylar fractures, 209
Gas bloat syndrome, 129
Gas embolism, 60
Gastric adenocarcinoma, 398, 415
Gastric outlet obstruction, 156
Gastric stasis, 129
Gastric tube, arterial supply for, 116, 117f
Gastric ulcers, 414
Gastrin, 147, 150, 228, 418
  mechanism of action of, 148
Gastrinomas, 138, 233, 234f
  duodenal, 138
  MEN1 and, 494–495
Gastrinoma triangle, 233, 234f
Gastroduodenal artery (GDA), 151
Gastroepiploic artery, right, 116
Gastrointestinal protein absorption, site of, 413
Gastrointestinal stromal tumors (GISTs), 141
GCS. *See* Glasgow Coma Scale (GCS)
General anesthesia, 378
Genitofemoral nerve (GFN), 357
Gingival hyperplasia, 335
Glasgow Coma Scale (GCS), 210, 221, 378, 455–456, 455t
Glossitis, 327
Glucagonomas, 489, 489t
Gluconeogenesis, 492
Glutamine, 367
Glycopyrrolate, 341, 378
Graft failure, 169
Graft infection, 169
  Staphylococcus epidermidis and, 170
Graft patency, 173
Grand mal seizures, lidocaine and, 329
Gunshot wounds, 234–235
Gynecomastia, 495–496

H
Haemophilus influenzae, 254, 379
Haemophilus influenzae type B, 251
Hair removal, in contaminated laceration repair, 332
Hallucinations, 60
Hamartomatous polyps, 403
Hamman sign, Boerhaave syndrome, 411
Hand infections, 376, 377f
Head and neck cancers, cancer staging system for, 25t
Head injury with hypotension, treatment of, 459
Head trauma, abusive, 450–451
Heart transplantation, late death after, 173
Heat and moisture exchangers, 86
Heineke–Mikulicz strictureplasty, 111, 111f
Helicobacter pylori, 108, 131, 398, 413, 415
Heller esophagomyotomy, 385
Hematogenous metastases, to small bowel, 113
Hemobilia, 109
Hemodialysis, 55
Hemophilia, perioperative treatment of, 98–99, 99t
Hemorrhage of vascular grafts, 169
Hemorrhoid banding, 110
Heparin-induced thrombocytopenia (HIT), 339
Hepatic abscesses, 154–155
Hepatic abscesss, 403
Hepatic adenoma, 139, 409
Hepatic artery
  aneurysms, 184
  repetitive embolization of, 228
  thrombosis, 68
  variants of, 82–83, 82f
Hepatic duct aberration, common, 419–420
Hepatic encephalopathy, 69
Hepatocellular carcinoma (HCC), 96–97, 97t, 350, 417
Hepatorenal syndrome, 147–148
Hereditary nonpolyposis colorectal cancer (HNPCC), 56
Hernias
  femoral, 323–324
  incarcerated inguinal, 65
  inguinal, 402
  ischemic orchitis after repair of, 334
  laparoscopic repair, 62
  obturator, 352
  parastomal, 143
Hip arthritis, 447
Hip dislocation, complications with, 447
HIV-associated nephropathy, 202
Homocysteine levels, increased, 418
HOPE2 trial, 418
Hospital-acquired fungal infections, 363
Howell–Jolly bodies, 475
Howship–Romberg sign, 352
Human errors
  active errors, 323
  latent errors, 323
Human factors, in injury prevention, 454
Humerus, dislocation of, 205
Humerus fracture, associated injury with, 448t
Hürthle cell carcinoma, 237
Hydatid cysts, of liver, 391
Hydrocele, 462
Hydrocortisone, 488
Hydromorphone, in critically ill patients, 334
Hyperaldosteronism, 156, 157f, 471, 471f
Hyperbaric oxygen therapy, for Fournier gangrene, 338
Hypercalcemic crisis, 491
Hyperoxaluria, 470
Hyperparathyroidism, 229
  primary, 493
  secondary, 493
Hyperplastic polyps, 403
Hyperprolactinemia, diagnostic tests and treatment for, 466f
Hypertrophic pyloric stenosis (HPS), 67
Hypertrophic scars, 217–218
Hyperuricosuria, 470
Hypervolemic hyponatremia, 340
Hypoaldosteronism, characteristics of, 253
Hypochloremic alkalosis, treatment of, 77
Hyponatremia, 326–327
  in cirrhosis, 340
  in pancreatitis, 66
Hypoparathyroidism, after neck procedures, 330
Hypophosphatemia, refeeding syndrome and, 325–326
Hypophyseal–pituitary–adrenal axis, suppression of, 476
Hypotension
  after blunt trauma, 329
  after insufflation for laparoscopy, 60
  after pheochromocytoma removal, 66
  in hemorrhagic *versus* blunt trauma, 79
Hypothermia, 72, 77
Hypovolemic shock, 177–178

I
Idiopathic pulmonary fibrosis, 440
Ileitis, infectious, 107
Ileocolic intussusception, 128, 128f
Ileus, postoperative, 409
Iliac arterial occlusion, 175
Iliac occlusive disease, angioplasty for, 166
Imatinib, 141
Immune system, 95
Immune thrombocytopenic purpura (ITP), 238, 251
  acute, 475
  chronic, 475
  recurrence of, 475
Immunization, tetanus, 62–63, 63t
Immunosuppression, long-term, risks of, 336
Immunosuppressive agents, side effects of, 320
Impedance plethysmography, 191
Incarcerated femoral hernia, 323–324
Incarcerated inguinal hernia, 65
Incisional abdominal hernias, 62
Indirect hernias, embryology of, 354
Indirect inguinal hernias, 354
Infants, cardiac physiology in, 443
Infections
  burn wound, 222–223
  necrotizing soft tissue, 321
Inferior mesenteric artery, 354
Inferior petrosal sinus sampling, 490
Inferior vena cava (IVC), 221
  filter, 356
Inflammatory carcinoma of breast, 238
Infliximab, 94

۰۲۱-۶۶۱۹۸۵۱۴ www.myuptodate.com دریافت آخرین نسخه آپتودیت آفلاین

Infrainguinal bypass graft surgery, 173
Inguinal hernias, 349, 402, 462
  incarcerated, 65
  laparoscopic repair of, 357
Inhalational burn injury, 80
Injury prevention
  human factors in, 454
  strategy for, 455
Injury prevention, ethical issues in, 450–451
Inspiratory capacity (IC), 435t
Inspiratory reserve volume (IRV), 435t
Insulinoma, 248, 254, 255, 256t
  of pancreatic head, 251
Intercostobrachial nerve, 474
Interferon-alpha, 228
International normalized ratio (INR), 72
Interquartile range, 371
Intraabdominal infection, postoperative, 363
Intra-arterial site-directed thrombolysis, 167
Intracerebral pressure (ICP), 211
  brain injury and, 451
Intraductal papillomas of breast, 240
Intralesional corticosteroid injection, for keloids, 217
Intraoperative parathyroid hormone assay, 246
Intravenous immunoglobulin (IVIG), 251–252
Intrinsic factor secretion, site of, 418–419
Intussusception, 128, 128f
Intussusception of small bowel, 113
Invasive ductal breast cancer, treatment of, 484
Iodine contrast, adverse reactions to, 93
Iodine-impregnated drapes, 328
Ipsilateral cord paralysis, 479
Iron deficiency, 95
Ischemia, 166
  lower-extremity, 167
Ischemic orchitis, after inguinal hernia repair, 334
Ischemic steal syndrome (ISS), 441–442
Isolation gowns, 328
ISS. *See* Ischemic steal syndrome (ISS)
ITP. *See* Immune thrombocytopenic purpura (ITP)
IVC. *See* Inferior vena cava (IVC)
IVIG. *See* Intravenous immunoglobulin (IVIG)

K

Keloids, 217
  first-line therapy for, 217–218
Ketorolac, in critically ill patients, 334
Kidney donation, live, 202
  contraindications to, 202
Kidney transplant, 59
Killian triangle, 407
Klebsiella, 169, 170
Klebsiella pneumoniae, 90, 154, 190
Kleihauer-Betke test, 374
Knife wounds, 234
K-Ras oncogene, mutations in, 56
Kupffer cells, 409
Kyphoplasty, 457

L

Laceration repair, hair removal in, 332
Lactate dehydrogenase (LDH), 80, 364
Lactated Ringer, in thermal burns, 332
Lactulose, 69, 216
Laminectomy, rectal bleeding after, 216
Laparoscopic adrenalectomy, for adrenal mass, 482
Laparoscopic cholecystectomy
  common bile duct injury during, 122, 122f, 399
  obstruction of ampulla during, 399, 400f
Laparoscopic inguinal hernia repairs, contraindications to, 349
Laparoscopic Nissen fundoplication, pleural effusion after, 387
Laparoscopic splenectomy, 238, 480
Laparoscopy
  cholecystectomy, 60
  hernia repair, 62
Latent errors, 323
Lateral femoral cutaneous nerve, 204
  injury to, 357
Latissimus dorsi musculocutaneous flap, 491
Left vertebral artery, 432
Lidocaine, 61t, 329
  toxicity, 60, 329
Limb ischemia, 168
Lipid metabolism, 152
Lisinopril, 472
Lithotomy positioning, 358
Live kidney donors, 202
Liver cirrhosis, 417
Liver function reserve, prognostic test of, 146
Liver, metastases to, 110
Liver transplantation
  in end-stage liver disease, 74
  hepatic artery thrombosis after, 68
  in patients with hepatocellular carcinoma, 350
Lobular carcinoma in situ (LCIS), 232
Local anesthetics, 60–61, 319
  toxicity of, 60
Longitudinal pancreaticojejunostomy, 139, 140f
Loop diuretic, 208
Low anterior resection (LAR), for rectal cancer, 144
Lower esophageal sphincter (LES), 153
Lower-extremity ischemia, 167
Lower extremity occlusive disease, acute, 235
Lower gastrointestinal bleeding (LGIB), 410
Low-molecular-weight heparin (LMWH), 356
Lugol solution, 488
Lung abscesses, 190
Lung cancer, 194–196, 197f
  diagnosis of, 80, 81f
  non–small-cell lung cancer (NSCLC), 194–195
  risk factor for, 194
  small-cell lung cancer (SCLC), 194
  TNM descriptors and staging for NSCLC, 195t–196t
Lymphadenopathy, in thyroid cancer, 246
Lymphangiosarcoma, 489
Lymphatic malformations, cutaneous, 203
Lymph nodes, epidermoid cancer of, 211
Lymphocele, 59
Lymphomas
  gastric, 239
  small bowel, 486
Lymphoscintigraphy, 387
Lynch syndrome. *See* Hereditary nonpolyposis colorectal cancer (HNPCC)
Lytic therapy, 167
  contraindications to, 102

M

Mafenide acetate. *See* Sulfamylon
Magnesium citrate, 216
Magnesium deficits, manifestations of, 87
Magnesium supplementation, 492
Magnetic resonance imaging (MRI), for soft tissue sarcoma, 68
Malignant mixed müllerian tumors (MMMT), 232
Malignant transformation of nevi, 446
MALT lymphomas, treatment of, 131
Maxillofacial fracture, associated injury with, 448t
Maze procedure, 186
Mean, 97, 371
Mean arterial pressure (MAP), 188, 211, 451
Mechanical ventilation, effect of inspiration phase of, 199, 199f
Meckel diverticulum, 154, 408
Median, 97, 371
Medullary carcinoma, 228, 237, 249
Medullary thyroid cancer (MTC), 242, 244, 484
Megaloblastic anemia, 327
Meigs syndrome, 460
Melanoma, 446
  sentinel lymph node biopsy for, 360–361, 361f
Melanoma metastatic, to gastrointestinal tract, 113
Melanoma of forearm, treatment of, 70
Melanoma of trunk, 223–224
MELD score, 74, 417
Merkel cell carcinoma, 202
Mesenteric angiography, 410
Metabolic acidosis, 69
  sulfamylon treatment and, 380
Metabolic alkalosis, 79, 324–325
  in infants (*see* Pyloric stenosis)
Metastases
  colon cancer, 110
  to liver, 110
  ovarian cancer, 207–208
  renal cell carcinoma, 368
Methicillin-resistant *Staphylococcus aureus,* 318
Methimazole, 487, 488
Metoclopramide, 331
Metoprolol, 422
Metronidazole, 114, 394
Microadenomas, 465
Microwave ablation, 350
Midazolam, 380

۰۲۱-۶۶۱۹۸۵۱۴ www.myuptodate.com دریافت آخرین نسخه آپتودیت آفلاین

Migrating motor complex (MMC), 150
Milan criteria, 350
Mirizzi syndrome, 460
Mitomycin C, 121–122
Mivacurium, 369
Mode, 97, 371
Monoclonal antibodies (mAbs), 370
Monro–Kellie doctrine, 451
Morphine, 342
MOSAIC trial, 143
Motilin, site of effect of, 150
Moxifloxacin, 81
MTC. *See* Medullary thyroid cancer (MTC)
Mucinous tumors, 460
Multiple endocrine neoplasia, 242, 242t
  type 1 (MEN1), 494
  type 2 (MEN 2), 244
Mycophenolate mofetil (MMF), 320
  side effects of, 335
Myocardial infarction
  acute, 193
  cholecystectomy after, 406
  embolus after, 168
  treatment of, 342

N
Nalbuphine, 334
Naloxone, 343
Naltrexone, 343
Narcotics, potency of, 372
National Cancer Comprehensive Network (NCCN), 414
National Surgical Adjuvant Breast and Bowel Project (NSABP) P-1, 233
National Surgical Quality Improvement Program (NSQIP), 58
Necrolytic migratory erythema, 489
Necrotizing fasciitis, treatment of, 212
Necrotizing soft tissue infections, characteristics of, 321
Needle biopsy, for breast mass, 477
Neisseria meningitidis, 251, 254
Neostigmine, 117, 378
Nerve conduction velocity (NCV) studies, 174
Nerve injury, 204
  intraoperative, 474
  laparoscopic inguinal hernia repair and, 357, 357f
  lithotomy positioning and, 358
  regeneration after, 235
  surgical timing after, 234
  types of, 234
Nerve regeneration, rate of, 234–235
Neurectomy, 334
Neurogenic shock, 351
Neuromuscular blocking drugs, 369
  and reversal agents, 378, 378t
Neuromuscular relaxants, 96
Newborns, bacterial infection in, 92
Nifedipine ointment, 110
Nipple discharge, 240
Nissen fundoplication, complications after, 129
Nitroglycerin, 342
Nonaccidental injury, in children, 450–451
Nonseminomatous germ cell tumors (NSGCTs), 364, 450
Normal anion gap metabolic acidosis, 69
Normal saline, for dehydration in HPS patients, 67
North American Symptomatic Carotid Endarterectomy Trial (NASCET), 92
NORVIT trial, 418
NSGCTs. *See* Nonseminomatous germ cell tumors (NSGCTs)
Nutrition, in critically ill patients, 353

O
Obstructive shock, 342
Obturator hernias, 351
Octreotide, 489, 495
Ogilvie syndrome. *See* Colonic pseudo-obstruction
Oncotic pressure in pulmonary circulation, 438, 438f
Ondansetron, 331
Opioids, for critically ill patients, 334
OPSI. *See* Overwhelming postsplenectomy infection (OPSI)
Oral cavity tumors, staging of, 204
Orphan Annie eye, tumor cells, 228
Orthotopic liver transplantation, 228
Osmotic demyelination syndrome, 340
Outcome measures, in health care, 322
Ovarian cancer, 207–208
Ovarian cysts, 459–460
Ovarian torsion, 460
Ovarian vein thrombosis, 464
Overfeeding syndrome, 76
Overwhelming postsplenectomy infection (OPSI), 89–90, 254–255
Oxycodone toxicity, 343

P
Packed red blood cells (PRBC) transfusion, 55, 72
Paget–Schroetter syndrome, 174
Paired t-test, 369
Pancreas-protocol computed tomography, for glucagonoma, 489
Pancreatic acinar cells, stimulant of, 147
Pancreatic ascites, 391
  respiratory complications with, 391
Pancreatic cancer, 56
  unresectable, 137
Pancreatic enzyme secretion, 158
Pancreatic fistulas, 158–159
Pancreatic polypeptide, 228
Pancreatic pseudocysts, 107–108
Pancreatitis, 66
Pancuronium, 369, 378
  side effect of, 96
Papillary thyroid carcinoma, 228, 237, 239, 249, 485
  with lymph node metastases, 485, 485f
Paradoxic aciduria, diagnosis of, 324–325
Paralysis of common peroneal nerve, 449
Parapneumonic effusion, 429
Parastomal hernias, 143
Parathyroid glands, 250, 492
Parathyroid hormone (PTH), 229, 491
  assay, 246
  and primary hyperparathyroidism, 493
  production, impairment of, 492
Parathyroid hyperplasia, 486
Paresthesias, after thyroid surgery, 330
Parietal bone fracture, associated injury with, 448t
Parietal cells, 418
Parietal cell vagotomy, 134
Parietal peritoneum, 367
Parkland formula, for fluid resuscitation in burns, 332
Paromomycin, 394
Parotidectomy, 213, 464
Parotid gland tumors, 213
Parotitis, postoperative, 468
Partial penectomy, for penile cancer, 465
Passive external rewarming, 77
PE. *See* Pulmonary embolism (PE)
Pelvic fractures
  associated injury, 448t
  bleeding, 452–453, 452f
  treatment of, 218–219
Pelvic inflammatory disease (PID), 460
Penile cancer, 465
Pentazocine, 334
Peptic ulcers, 108, 413
Peptide hormones in gastrointestinal tract, distribution of, 150, 150f
Peptide YY, 147
Percutaneous balloon valvotomy, 424
Percutaneous embolectomy, 168
Percutaneous transluminal angioplasty (PTA), 166, 175
Perforated appendicitis, 390
Pericardial tamponade, after stab wounds to chest, 422
Pericardiocentesis, 182
Perilunate dislocations, 226
Peripheral arterial embolization, 168
Peripheral IV catheter site, infected, treatment of, 103
Peripheral nerve blocks, 337
Peritoneal warming, 72
Persistent fetal circulation, conditions with, 439
P-glycoprotein, 377
Pharyngeal diverticulum, treatment of, 401
Phenylephrine, 351
Phenytoin, 377
Pheochromocytomas, 242, 244
  hypotension after removal of, 66
Phyllodes tumors of breast, 230
Physical abuse, in children, 450
Physostigmine, 341
Ping-pong fracture, 458
Pipecuronium, 96
Piperacillin/tazobactam, for emphysematous cholecystitis, 71
Pituitary adenomas, 231
Pituitary tumors, 465
  diagnostic test for, 490
Plantar ulcers, 178

۰۲۱-۶۶۱۹۸۵۱۴ www.myuptodate.com دریافت آخرین نسخه آپتودیت آفلاین

Platelet plug formation, von Willebrand factor for, 373
Plethysmography, 191
Pleural effusion, after laparoscopic Nissen fundoplication, 387
Pneumatosis intestinalis, 402
Pneumonectomy, contraindications to, 194
Polypropylene, 169
Popliteal aneurysms, 166
Porcelain gallbladder, 126
Portal hypertension, 417
Portal vein thrombosis, 68
Portal venous pressure, 417
Positive end-expiratory pressure (PEEP), renal effects of, 192
Posterior dislocation of knee, associated injury with, 448t
Posterior hip dislocation, 447
  injury associated with, 448t
Post femoral–tibial arterial bypass swelling, 235
Postmyocardial infarction, embolus, 168
Postoperative intraabdominal infection, 363
Postoperative nausea and vomiting, 331
Postoperative parotitis, 468
Post-transplant lymphoproliferative disease (PTLD), 336
Povidone-iodine, 328
Praziquantel, 394
Precipitated withdrawal, in opioid-dependent patients, 334
Prednisone, 320
Pregnancy
  changes in cardiac physiology in, 425
  rupture of splenic artery aneurysms in, 185
  thyroiditis in, 488
  trauma in, 374
Prerenal azotemia, 148
Primary hyperaldosteronism, 156, 157f, 471
Primary hyperparathyroidism, 229, 245, 246, 250, 491
  indications for surgery in, 245
Primary wound healing, 222
Process measure, in health care, 322
Processus vaginalis, 354
Promethazine, 331
Propranolol, 488
Propylthiouracil (PTU), 488
Prospective cohort study, 370
Protamine, 72, 336
Protein C, 362, 408
Protein kinase A, 492
Proteins S, 362, 408
Proteus, 169, 170
Prothrombin time (PT), vitamin K deficiency and, 327
Proton pump inhibitor, 495
Psammoma bodies, 249
Pseudoangina, 174
Pseudocysts, pancreatic, 107–108
Pseudohyponatremia, in pancreatitis, 66
Pseudomonas, 169, 170, 190
PTA. *See* Percutaneous transluminal angioplasty (PTA)
PTH. *See* Parathyroid hormone (PTH)
Puestow procedure. *See* Longitudinal pancreaticojejunostomy
Pulmonary artery pressure (PAP), 193
Pulmonary capillary wedge pressure (PCWP), 193
Pulmonary circulation, oncotic pressure in, 438, 438f
Pulmonary contusion, 180
Pulmonary embolism (PE), 342, 356
Pulmonary hypertension, 437
Pulmonary sequestration (PS), of lung, 198
Pulmonary ventilation, 435, 435f, 435t
Pulseless leg, acute, 190
Pyloric stenosis, 381
Pyogenic hepatic abscess, 403

Q
Quinolones, 81

R
Radiation exposure, and thyroid cancer, 237
Radiation therapy
  for breast cancer, 481–482
  for low-stage gastric lymphoma, 131
  Merkel cell carcinoma, 202
  squamous cell carcinoma of lower lip, 204
Radical inguinal orchiectomy, 450
Radical neck dissection, 474
Radical orchiectomy, 364
Radiofrequency ablation (RFA), 350
Randomized clinical trials, 370
Rectal adenocarcinoma, 144
Rectal bleeding, 110
  after laminectomy, 216
Rectal prolapse, surgical approaches to, 404
Recurrent laryngeal nerve (RLN) injury, treatment of, 461
Refeeding syndrome (RFS), 325–326
Renal cell carcinoma (RCC), 368
Renal transplantation, 229
  hyperacute rejection, 88
Renal trauma, 217
Renal tubular acidosis (RTA), 148
  type 4, 253
Reperfusion injury, 235
Replaced right hepatic artery, 145
Residual volume (GV), 435t
Respiratory quotient (RQ), 76, 375
  of fatty acid synthesis, 375
Rest pain, 181
RET gene mutation testing, 244
Retrospective case-control study, 370
Retrospective observational study, 370
Rh immune globulin (RhoGAM), 374
Rib fractures, 423
  injury associated with, 448t
Rickets, 327
Right recurrent laryngeal nerve (RLN), injury to, 479, 479f
Right renal artery, 221
Rituximab, 370
Rocuronium, 369
Ropivacaine, 61t
Roux-en-Y hepaticojejunostomy, 399
Ruptured ectopic pregnancy, 458

S
Salivary gland tumors, 213, 213t
Salmonella enteritidis, 107
Saphenous nerve, 204
Scalenus anticus muscle, 187, 187f
Scaphoid fracture, 226
Scapula fracture, associated injury with, 448t
SCC. *See* Squamous cell carcinoma (SCC)
Schistosomiasis, 403
SCIP. *See* Surgical Care Improvement Project (SCIP)
Screening for breast cancer, 238
Screening tests, sensitivity and specificity of, 379
Scrotal hydrocele, 354
Scrotal ultrasound, 450
Scurvy, 327
Secondary hyperparathyroidism, 229
Secretin, 147, 150
Secretin stimulation test, 233
Selective estrogen receptor modulator (SERM), 232
Selenium deficiency, 95
Seminomas, 364, 450
Senna, 216
Sensitivity, 379
  high, 379
Sentinel lymph node biopsy, 211, 220
  for melanoma, 360–361, 361f
Sepsis
  B-cells level in, 371
  postsplenectomy, 89–90, 254–255
Septic shock, 83–84
  hemodynamic findings in, 333
Serous tumors, 460
Serum tumor markers, testicular cancer, 364
Sestamibi scan, 246, 493
Sex cord stromal tumors, 364
Sheehan syndrome, 460
Shock, 83, 83t, 193t
  after aneurysm repair, 354
  cardiogenic, 193
  hypovolemic, 177–178
  neurogenic, 351
  obstructive, 342
  septic, 83–84, 333
Short gut syndrome, 470
Shoulder shrug, 474
SIADH. *See* Syndrome of inappropriate antidiuretic hormone secretion (SIADH)
Sigmoid carcinoma, adjuvant chemotherapy for, 143
Sigmoid volvulus, 412
  recurrent, 412
Signet ring cells, 415
Silicone gel, for hypertrophic scars prevention, 217–218
Sirolimus, 320
Sitz baths, 110
Skin necrosis, warfarin and, 362
Skull fractures, depressed, 457–458, 458t

۰۲۱-۶۶۱۹۸۵۱۴ www.myuptodate.com دریافت آخرین نسخه آپتودیت آفلاین

Small bowel
hematogenous metastases to, 113
lymphomas, 486
obstruction, 392, 392t
Smith fracture, 226
Soft tissue sarcomas (STS), 100, 344–346
diagnosis of, 345
genetic predisposition to, 344
prevalence and mortality rate, 344
staging system, 100, 100t, 345t–346t
of thigh, 68
treatment, 345t–346t
Solitary anterior neck mass, diagnostic test for, 216
Somatostatin, 150
Sorafenib, 368
Sorbitol, 216
Specificity, 379
high, 379
Spinal accessory nerve, 474
Spinal cord injuries, 79
Spironolactone, 69
Splenectomy, 475
indications for, 238
laparoscopic, 480
Splenic artery aneurysms, 185
Split-thickness skin grafts (STSGs), 206
characteristics of, 207
donor-site healing in, 206
Spontaneous pneumothorax (SP)
definition, 431
presentation, 431
treatment, 431–432
Squamous cell carcinoma (SCC)
actinic keratosis and, 469
of anal canal, 121–122, 121t
of buccal mucosa, 215
of lower lip, 204
of penis, 465
of tongue, 467
SSIs. *See* Surgical site infection (SSIs)
Staging
of colorectal cancer, 316t–317t
of testicular germ cell tumors, 364
Staphylococcus aureus, 169, 170, 190
acute paronychia and, 376
Staphylococcus epidermidis, 169, 170
Statins, in graft patency, 173
Sternal fracture, associated injury with, 448t
Stewart–Treves syndrome, 489
Stomach, vascular supply of, 116, 117f
Stoma, dark, 124
Stool softeners, for anal fissures, 114
Streptococcus pneumoniae, 251, 254, 379
Streptococcus pyogenes, 379
Streptokinase, 102
Strictures of common bile duct, 125, 125f
Stroke volume, 436
Structure measures, in health care, 322
Struvite stones, 416
STS. *See* Soft tissue sarcomas (STS)
ST-segment elevation myocardial infarction (STEMI), 342
STSGs. *See* Split-thickness skin grafts (STSGs)
Subclavian approach, for central catheterization, 182
Subclavian steal syndrome, 427
Succinylcholine, 369
Sulbactam, 379
Sulfamylon, 380
Sunitinib, 368
Superficial peroneal nerve, 204, 449
Superior laryngeal nerve injury, 248
Superior mesenteric artery (SMA), 145
Superior rectal artery, 354
Superior vena cava (SVC) syndrome, 179
Supracondylar femur fracture, associated injury with, 448t
Supracondylar fractures, 209
in children, 454
treatment of, 209
Supracondylar humerus fracture, associated injury with, 448t
Supraomohyoid neck dissection, 211, 215
Surgical Care Improvement Project (SCIP), 318, 322
process measures of, 359, 359t
Surgical debridements
Fournier gangrene and, 73, 338
for necrotizing soft tissue infection, 321
Surgical site infection (SSIs)
antibiotic prophylaxis, perioperative, 318
definition, 318
iodine-impregnated drapes, use of, 328
prevention of, 84
Surveillance Epidemiology and End Results (SEER), 232
Suture failure, 169
Swallowing, lower esophageal sphincter pressure during, 153
Synchronized cardioversion, 422
Syndrome of inappropriate antidiuretic hormone secretion (SIADH), 208–209
diagnosis of, 326–327
Systemic vascular resistance (SVR), calculation of, 189

T

Tachyarrhythmias, treatment of, 186
Tachycardia, 96
after insufflation for laparoscopy, 60
Tacrolimus, 320, 335, 377
absorption and metabolism, 377
Tagged red blood cell scan, 410
Tamoxifen, 232–233, 496
Tardive dyskinesia, 331
T3 colon cancer, 163–164
Technetium sestamibi scintigraphy, 246, 408
Temporal bone fracture, 453
associated injury with, 448t
Tension pneumothorax, 442
Tertiary hyperparathyroidism, 229
Testicular cancer, 450
staging of, 364
Testicular torsion, 462
Tetanus/diphtheria/acellular pertussis vaccines (Tdap), 62
Tetanus prophylaxis, 62–63, 63t
Tetracaine, 61t
Theca lutein cysts, 459
Thoracic duct, 434, 434f
Thoracic outlet, musculoskeletal anatomy of, 187f
Thoracic outlet syndrome (TOS), 174–175, 449
Thoracodorsal artery, 491
Thoracolumbar compression fractures, 456–457
Thoracotomy, after gunshot wound to chest, 183
Thromboembolism, 166
Thrombolysis, intra-arterial site-directed, 167
Thromboxane A2, 373
Thyroid cancer, 228
lymphadenopathy in, 246
prognostic factors for, 249
radiation exposure and, 237
Thyroid crisis, 488
Thyroiditis during pregnancy, treatment of, 488
Thyroid lobectomy, 487
Thyroid nodule
FNA of, 241
workup of, 239
Thyroid-stimulating hormone (TSH), 488
Thyroid surgery, and paresthesias, 330
Tibial nerve, 204
Tidal volume (TV), 435
Tissue plasminogen activator (t-PA), 102
Tocopherol, 218
Tongue cancer, 467
Torsade de pointes, 81
TOS. *See* Thoracic outlet syndrome (TOS)
Total body surface area (TBSA), estimation of, in burns, 332
Total lung capacity (TLC), 435t
Total parenteral nutrition (TPN), 76
adult caloric supply for, 366
in renal insufficiency, 365
Total thyroidectomy
and RLN injury, 479, 479f
for toxic nodular goiter, 487
Toxic nodular goiter, 487
TPN. *See* Total parenteral nutrition (TPN)
Tracheal stent, 396
Tracheoinnominate artery fistula (TIF), 462, 463f
Tracheo-neoesophageal fistulas, 396
Transarterial embolization, for hemobilia, 109
Transcatheter AVR, 424
Transfusion
fresh frozen plasma, 72
packed red blood cells, 55
Transfusion-related acute lung injury (TRALI), 101
Transhiatal esophagectomy, 116, 117f
Transjugular intrahepatic portosystemic shunt (TIPS), 58
Transplantation
heart, 173
and immunosuppressive regimen, 320
renal, 88, 229
Transposition of the great arteries (TGA), 439

۰۲۱-۶۶۱۹۸۵۱۴ www.myuptodate.com دریافت آخرین نسخه آپتودیت آفلاین

Transverse rectus abdominus myocutaneous (TRAM) flap reconstruction, 252–253
Trastuzumab, 370
Trauma
  abdominal, 329
  in pregnancy, 374
Traumatic brain injury
  outcome after, 455–456
  primary injury, 451
  secondary injury, 451–452
Traumatic head injury, skull fracture after, 457–458, 458t
Trendelenburg position, 176–177
Tretinoin, 218
"Triangle of pain," 357, 357f
Tricarboxylic acid cycle, 152
Truncal vagotomy, 134–135
Trypsin, 158
Trypsinogen, 147, 158
t-tests, design of, 369
T-tube placement, 120
Tuberculosis, after infliximab therapy, 94
Tubular adenomas, 403
Tumor of bronchus, treatment of, 355
Tumors, adaptive immunotherapy for, 95
Type II diabetes mellitus, 492
Type I von Willebrand disease (vWD), 372
Type 4 renal tubular acidosis (RTA), 253

U
UES. *See* Upper esophageal sphincter (UES)
Ulcers, plantar, 178
Ultrasound
  for ovarian vein thrombosis, 464
  for tender breast mass, 475
Umbilical hernias, with ascites, 58
United Network from Organ Sharing (UNOS), 350
Unpaired Student t-test, 369
Upper airway obstruction, in inhalational burn injury victims, 80
Upper esophageal sphincter (UES), 153, 407, 407f
Urea breath test, 108
Urease test, 108
Ureteral injuries, intraoperative, 203
Ureterocystostomy, 203
Ureteroneocystostomy stenosis, 59
Ureteroureterostomy, 203
Uric acid stones, 416
Urinary retention, after surgery for anorectal disease, 102
Urinary stones
  after ileal resection, 470
  etiology of, 416
Urinary tract infection (UTI), 81
Urinoma, 203
Urokinase overdose, 102
Urosepsis, 203
Uterine sarcomas, 232

V
Vancomycin, 114, 318
Varicoceles, 462
Vascular compromise, 59
Vascular grafts, 169
  patency, 173
Vascular injury, in pediatric supracondylar fractures, 454
Vascular steal syndrome, 427
Vasoactive intestinal peptide (VIP), 147, 228, 388
Vasopressin. *See* Antidiuretic hormone (ADH)
Vecuronium, 369, 378
Venography, 191
Venous competency, assessment of, 191
Venous gas embolism (VGE), 176–177
Venous pump, 191
Venous thromboembolism (VTE), 219–220, 356, 362
Ventilator-associated pneumonia (VAP), 64, 86
Ventral hernias, component separation for repair of, 347–348, 348f
Verner–Morrison syndrome. *See* VIPomas
Vertebral artery, 432
Vertebroplasty, 456–457
Veterans Affairs Cooperative trial, 173
Veterans Health Administration (VA), 58
Video-assisted thoracoscopic surgery (VATS), 431–432
Villous adenoma, treatment of, 403
VIP. *See* Vasoactive intestinal peptide (VIP)
VIPomas, 228, 388, 388t
Visceral pain, 367
  vs. somatic pain, 367
Visceral peritoneum, 367
Vital capacity (VC), 435t, 440
Vitamin B_2 deficiency, 327
Vitamin B_{12} deficiency, 327, 419
Vitamin C deficiency, 327
Vitamin D deficiency, 327, 476
Vitamin K, 72, 327
  deficiency, 327
Vitamin K-dependent clotting factors, 408
von Willebrand disease (vWD), 91, 343, 373
  type I, 343–344
von Willebrand Factor (vWF), 55, 373
VTE. *See* Venous thromboembolism (VTE)

W
Waddell's triad, 329
Warfarin, 72, 173, 327, 408
Warfarin-induced skin necrosis, treatment of, 362
Warthin tumors, 464
Whipple procedure, 344
Whipple triad, 248
Wilcoxon rank-sum test, 369
Wound, acute, tetanus prophylaxis of, 62–63, 63t
Wound healing, 222

Y
Yersinia enterocolitica, 107

Z
Zenker diverticulum, 401, 407, 407f
Zinc deficiency, 95
Zoledronic acid, 491
Zollinger–Ellison syndrome, 138

۰۲۱-۶۶۱۹۸۵۱۴ www.myuptodate.com دریافت آخرین نسخه آپتودیت آفلاین

دریافت آخرین نسخه آپتودیت آفلاین www.myuptodate.com ۰۲۱-۶۶۱۹۸۵۱۴

PRACTICE EXAMINATION 2 ANSWER SHEET 1

2-1 Ⓐ Ⓑ Ⓒ Ⓓ Ⓔ	2-26 Ⓐ Ⓑ Ⓒ Ⓓ Ⓔ	2-51 Ⓐ Ⓑ Ⓒ Ⓓ Ⓔ
2-2 Ⓐ Ⓑ Ⓒ Ⓓ Ⓔ	2-27 Ⓐ Ⓑ Ⓒ Ⓓ Ⓔ	2-52 Ⓐ Ⓑ Ⓒ Ⓓ Ⓔ
2-3 Ⓐ Ⓑ Ⓒ Ⓓ Ⓔ	2-28 Ⓐ Ⓑ Ⓒ Ⓓ Ⓔ	2-53 Ⓐ Ⓑ Ⓒ Ⓓ Ⓔ
2-4 Ⓐ Ⓑ Ⓒ Ⓓ Ⓔ	2-29 Ⓐ Ⓑ Ⓒ Ⓓ Ⓔ	2-54 Ⓐ Ⓑ Ⓒ Ⓓ Ⓔ
2-5 Ⓐ Ⓑ Ⓒ Ⓓ Ⓔ	2-30 Ⓐ Ⓑ Ⓒ Ⓓ Ⓔ	2-55 Ⓐ Ⓑ Ⓒ Ⓓ Ⓔ
2-6 Ⓐ Ⓑ Ⓒ Ⓓ Ⓔ	2-31 Ⓐ Ⓑ Ⓒ Ⓓ Ⓔ	2-56 Ⓐ Ⓑ Ⓒ Ⓓ Ⓔ
2-7 Ⓐ Ⓑ Ⓒ Ⓓ Ⓔ	2-32 Ⓐ Ⓑ Ⓒ Ⓓ Ⓔ	2-57 Ⓐ Ⓑ Ⓒ Ⓓ Ⓔ
2-8 Ⓐ Ⓑ Ⓒ Ⓓ Ⓔ	2-33 Ⓐ Ⓑ Ⓒ Ⓓ Ⓔ	2-58 Ⓐ Ⓑ Ⓒ Ⓓ Ⓔ
2-9 Ⓐ Ⓑ Ⓒ Ⓓ Ⓔ	2-34 Ⓐ Ⓑ Ⓒ Ⓓ Ⓔ	2-59 Ⓐ Ⓑ Ⓒ Ⓓ Ⓔ
2-10 Ⓐ Ⓑ Ⓒ Ⓓ Ⓔ	2-35 Ⓐ Ⓑ Ⓒ Ⓓ Ⓔ	2-60 Ⓐ Ⓑ Ⓒ Ⓓ Ⓔ
2-11 Ⓐ Ⓑ Ⓒ Ⓓ Ⓔ	2-36 Ⓐ Ⓑ Ⓒ Ⓓ Ⓔ	2-61 Ⓐ Ⓑ Ⓒ Ⓓ Ⓔ
2-12 Ⓐ Ⓑ Ⓒ Ⓓ Ⓔ	2-37 Ⓐ Ⓑ Ⓒ Ⓓ Ⓔ	2-62 Ⓐ Ⓑ Ⓒ Ⓓ Ⓔ
2-13 Ⓐ Ⓑ Ⓒ Ⓓ Ⓔ	2-38 Ⓐ Ⓑ Ⓒ Ⓓ Ⓔ	2-63 Ⓐ Ⓑ Ⓒ Ⓓ Ⓔ
2-14 Ⓐ Ⓑ Ⓒ Ⓓ Ⓔ	2-39 Ⓐ Ⓑ Ⓒ Ⓓ Ⓔ	2-64 Ⓐ Ⓑ Ⓒ Ⓓ Ⓔ
2-15 Ⓐ Ⓑ Ⓒ Ⓓ Ⓔ	2-40 Ⓐ Ⓑ Ⓒ Ⓓ Ⓔ	2-65 Ⓐ Ⓑ Ⓒ Ⓓ Ⓔ
2-16 Ⓐ Ⓑ Ⓒ Ⓓ Ⓔ	2-41 Ⓐ Ⓑ Ⓒ Ⓓ Ⓔ	2-66 Ⓐ Ⓑ Ⓒ Ⓓ Ⓔ
2-17 Ⓐ Ⓑ Ⓒ Ⓓ Ⓔ	2-42 Ⓐ Ⓑ Ⓒ Ⓓ Ⓔ	2-67 Ⓐ Ⓑ Ⓒ Ⓓ Ⓔ
2-18 Ⓐ Ⓑ Ⓒ Ⓓ Ⓔ	2-43 Ⓐ Ⓑ Ⓒ Ⓓ Ⓔ	2-68 Ⓐ Ⓑ Ⓒ Ⓓ Ⓔ
2-19 Ⓐ Ⓑ Ⓒ Ⓓ Ⓔ	2-44 Ⓐ Ⓑ Ⓒ Ⓓ Ⓔ	2-69 Ⓐ Ⓑ Ⓒ Ⓓ Ⓔ
2-20 Ⓐ Ⓑ Ⓒ Ⓓ Ⓔ	2-45 Ⓐ Ⓑ Ⓒ Ⓓ Ⓔ	2-70 Ⓐ Ⓑ Ⓒ Ⓓ Ⓔ
2-21 Ⓐ Ⓑ Ⓒ Ⓓ Ⓔ	2-46 Ⓐ Ⓑ Ⓒ Ⓓ Ⓔ	2-71 Ⓐ Ⓑ Ⓒ Ⓓ Ⓔ
2-22 Ⓐ Ⓑ Ⓒ Ⓓ Ⓔ	2-47 Ⓐ Ⓑ Ⓒ Ⓓ Ⓔ	2-72 Ⓐ Ⓑ Ⓒ Ⓓ Ⓔ
2-23 Ⓐ Ⓑ Ⓒ Ⓓ Ⓔ	2-48 Ⓐ Ⓑ Ⓒ Ⓓ Ⓔ	2-73 Ⓐ Ⓑ Ⓒ Ⓓ Ⓔ
2-24 Ⓐ Ⓑ Ⓒ Ⓓ Ⓔ	2-49 Ⓐ Ⓑ Ⓒ Ⓓ Ⓔ	2-74 Ⓐ Ⓑ Ⓒ Ⓓ Ⓔ
2-25 Ⓐ Ⓑ Ⓒ Ⓓ Ⓔ	2-50 Ⓐ Ⓑ Ⓒ Ⓓ Ⓔ	2-75 Ⓐ Ⓑ Ⓒ Ⓓ Ⓔ

۰۲۱-۶۶۱۹۸۵۱۴ www.myuptodate.com دریافت آخرین نسخه آپتودیت آفلاین

2-76 Ⓐ Ⓑ Ⓒ Ⓓ Ⓔ	2-101 Ⓐ Ⓑ Ⓒ Ⓓ Ⓔ	2-126 Ⓐ Ⓑ Ⓒ Ⓓ Ⓔ
2-77 Ⓐ Ⓑ Ⓒ Ⓓ Ⓔ	2-102 Ⓐ Ⓑ Ⓒ Ⓓ Ⓔ	2-127 Ⓐ Ⓑ Ⓒ Ⓓ Ⓔ
2-78 Ⓐ Ⓑ Ⓒ Ⓓ Ⓔ	2-103 Ⓐ Ⓑ Ⓒ Ⓓ Ⓔ	2-128 Ⓐ Ⓑ Ⓒ Ⓓ Ⓔ
2-79 Ⓐ Ⓑ Ⓒ Ⓓ Ⓔ	2-104 Ⓐ Ⓑ Ⓒ Ⓓ Ⓔ	2-129 Ⓐ Ⓑ Ⓒ Ⓓ Ⓔ
2-80 Ⓐ Ⓑ Ⓒ Ⓓ Ⓔ	2-105 Ⓐ Ⓑ Ⓒ Ⓓ Ⓔ	2-130 Ⓐ Ⓑ Ⓒ Ⓓ Ⓔ
2-81 Ⓐ Ⓑ Ⓒ Ⓓ Ⓔ	2-106 Ⓐ Ⓑ Ⓒ Ⓓ Ⓔ	2-131 Ⓐ Ⓑ Ⓒ Ⓓ Ⓔ
2-82 Ⓐ Ⓑ Ⓒ Ⓓ Ⓔ	2-107 Ⓐ Ⓑ Ⓒ Ⓓ Ⓔ	2-132 Ⓐ Ⓑ Ⓒ Ⓓ Ⓔ
2-83 Ⓐ Ⓑ Ⓒ Ⓓ Ⓔ	2-108 Ⓐ Ⓑ Ⓒ Ⓓ Ⓔ	2-133 Ⓐ Ⓑ Ⓒ Ⓓ Ⓔ
2-84 Ⓐ Ⓑ Ⓒ Ⓓ Ⓔ	2-109 Ⓐ Ⓑ Ⓒ Ⓓ Ⓔ	2-134 Ⓐ Ⓑ Ⓒ Ⓓ Ⓔ
2-85 Ⓐ Ⓑ Ⓒ Ⓓ Ⓔ	2-110 Ⓐ Ⓑ Ⓒ Ⓓ Ⓔ	2-135 Ⓐ Ⓑ Ⓒ Ⓓ Ⓔ
2-86 Ⓐ Ⓑ Ⓒ Ⓓ Ⓔ	2-111 Ⓐ Ⓑ Ⓒ Ⓓ Ⓔ	2-136 Ⓐ Ⓑ Ⓒ Ⓓ Ⓔ
2-87 Ⓐ Ⓑ Ⓒ Ⓓ Ⓔ	2-112 Ⓐ Ⓑ Ⓒ Ⓓ Ⓔ	2-137 Ⓐ Ⓑ Ⓒ Ⓓ Ⓔ
2-88 Ⓐ Ⓑ Ⓒ Ⓓ Ⓔ	2-113 Ⓐ Ⓑ Ⓒ Ⓓ Ⓔ	2-138 Ⓐ Ⓑ Ⓒ Ⓓ Ⓔ
2-89 Ⓐ Ⓑ Ⓒ Ⓓ Ⓔ	2-114 Ⓐ Ⓑ Ⓒ Ⓓ Ⓔ	2-139 Ⓐ Ⓑ Ⓒ Ⓓ Ⓔ
2-90 Ⓐ Ⓑ Ⓒ Ⓓ Ⓔ	2-115 Ⓐ Ⓑ Ⓒ Ⓓ Ⓔ	2-140 Ⓐ Ⓑ Ⓒ Ⓓ Ⓔ
2-91 Ⓐ Ⓑ Ⓒ Ⓓ Ⓔ	2-116 Ⓐ Ⓑ Ⓒ Ⓓ Ⓔ	2-141 Ⓐ Ⓑ Ⓒ Ⓓ Ⓔ
2-92 Ⓐ Ⓑ Ⓒ Ⓓ Ⓔ	2-117 Ⓐ Ⓑ Ⓒ Ⓓ Ⓔ	2-142 Ⓐ Ⓑ Ⓒ Ⓓ Ⓔ
2-93 Ⓐ Ⓑ Ⓒ Ⓓ Ⓔ	2-118 Ⓐ Ⓑ Ⓒ Ⓓ Ⓔ	2-143 Ⓐ Ⓑ Ⓒ Ⓓ Ⓔ
2-94 Ⓐ Ⓑ Ⓒ Ⓓ Ⓔ	2-119 Ⓐ Ⓑ Ⓒ Ⓓ Ⓔ	2-144 Ⓐ Ⓑ Ⓒ Ⓓ Ⓔ
2-95 Ⓐ Ⓑ Ⓒ Ⓓ Ⓔ	2-120 Ⓐ Ⓑ Ⓒ Ⓓ Ⓔ	2-145 Ⓐ Ⓑ Ⓒ Ⓓ Ⓔ
2-96 Ⓐ Ⓑ Ⓒ Ⓓ Ⓔ	2-121 Ⓐ Ⓑ Ⓒ Ⓓ Ⓔ	2-146 Ⓐ Ⓑ Ⓒ Ⓓ Ⓔ
2-97 Ⓐ Ⓑ Ⓒ Ⓓ Ⓔ	2-122 Ⓐ Ⓑ Ⓒ Ⓓ Ⓔ	2-147 Ⓐ Ⓑ Ⓒ Ⓓ Ⓔ
2-98 Ⓐ Ⓑ Ⓒ Ⓓ Ⓔ	2-123 Ⓐ Ⓑ Ⓒ Ⓓ Ⓔ	2-148 Ⓐ Ⓑ Ⓒ Ⓓ Ⓔ
2-99 Ⓐ Ⓑ Ⓒ Ⓓ Ⓔ	2-124 Ⓐ Ⓑ Ⓒ Ⓓ Ⓔ	2-149 Ⓐ Ⓑ Ⓒ Ⓓ Ⓔ
2-100 Ⓐ Ⓑ Ⓒ Ⓓ Ⓔ	2-125 Ⓐ Ⓑ Ⓒ Ⓓ Ⓔ	2-150 Ⓐ Ⓑ Ⓒ Ⓓ Ⓔ

۰۲۱-۶۶۱۹۸۵۱۴ www.myuptodate.com دریافت آخرین نسخه آپتودیت آفلاین

2-151 Ⓐ Ⓑ Ⓒ Ⓓ Ⓔ
2-152 Ⓐ Ⓑ Ⓒ Ⓓ Ⓔ
2-153 Ⓐ Ⓑ Ⓒ Ⓓ Ⓔ
2-154 Ⓐ Ⓑ Ⓒ Ⓓ Ⓔ
2-155 Ⓐ Ⓑ Ⓒ Ⓓ Ⓔ
2-156 Ⓐ Ⓑ Ⓒ Ⓓ Ⓔ
2-157 Ⓐ Ⓑ Ⓒ Ⓓ Ⓔ
2-158 Ⓐ Ⓑ Ⓒ Ⓓ Ⓔ
2-159 Ⓐ Ⓑ Ⓒ Ⓓ Ⓔ
2-160 Ⓐ Ⓑ Ⓒ Ⓓ Ⓔ
2-161 Ⓐ Ⓑ Ⓒ Ⓓ Ⓔ
2-162 Ⓐ Ⓑ Ⓒ Ⓓ Ⓔ
2-163 Ⓐ Ⓑ Ⓒ Ⓓ Ⓔ
2-164 Ⓐ Ⓑ Ⓒ Ⓓ Ⓔ
2-165 Ⓐ Ⓑ Ⓒ Ⓓ Ⓔ
2-166 Ⓐ Ⓑ Ⓒ Ⓓ Ⓔ
2-167 Ⓐ Ⓑ Ⓒ Ⓓ Ⓔ
2-168 Ⓐ Ⓑ Ⓒ Ⓓ Ⓔ
2-169 Ⓐ Ⓑ Ⓒ Ⓓ Ⓔ
2-170 Ⓐ Ⓑ Ⓒ Ⓓ Ⓔ
2-171 Ⓐ Ⓑ Ⓒ Ⓓ Ⓔ
2-172 Ⓐ Ⓑ Ⓒ Ⓓ Ⓔ
2-173 Ⓐ Ⓑ Ⓒ Ⓓ Ⓔ
2-174 Ⓐ Ⓑ Ⓒ Ⓓ Ⓔ
2-175 Ⓐ Ⓑ Ⓒ Ⓓ Ⓔ
2-176 Ⓐ Ⓑ Ⓒ Ⓓ Ⓔ
2-177 Ⓐ Ⓑ Ⓒ Ⓓ Ⓔ
2-178 Ⓐ Ⓑ Ⓒ Ⓓ Ⓔ
2-179 Ⓐ Ⓑ Ⓒ Ⓓ Ⓔ
2-180 Ⓐ Ⓑ Ⓒ Ⓓ Ⓔ
2-181 Ⓐ Ⓑ Ⓒ Ⓓ Ⓔ
2-182 Ⓐ Ⓑ Ⓒ Ⓓ Ⓔ
2-183 Ⓐ Ⓑ Ⓒ Ⓓ Ⓔ
2-184 Ⓐ Ⓑ Ⓒ Ⓓ Ⓔ
2-185 Ⓐ Ⓑ Ⓒ Ⓓ Ⓔ
2-186 Ⓐ Ⓑ Ⓒ Ⓓ Ⓔ
2-187 Ⓐ Ⓑ Ⓒ Ⓓ Ⓔ
2-188 Ⓐ Ⓑ Ⓒ Ⓓ Ⓔ
2-189 Ⓐ Ⓑ Ⓒ Ⓓ Ⓔ
2-190 Ⓐ Ⓑ Ⓒ Ⓓ Ⓔ
2-191 Ⓐ Ⓑ Ⓒ Ⓓ Ⓔ
2-192 Ⓐ Ⓑ Ⓒ Ⓓ Ⓔ
2-193 Ⓐ Ⓑ Ⓒ Ⓓ Ⓔ
2-194 Ⓐ Ⓑ Ⓒ Ⓓ Ⓔ
2-195 Ⓐ Ⓑ Ⓒ Ⓓ Ⓔ
2-196 Ⓐ Ⓑ Ⓒ Ⓓ Ⓔ
2-197 Ⓐ Ⓑ Ⓒ Ⓓ Ⓔ
2-198 Ⓐ Ⓑ Ⓒ Ⓓ Ⓔ
2-199 Ⓐ Ⓑ Ⓒ Ⓓ Ⓔ
2-200 Ⓐ Ⓑ Ⓒ Ⓓ Ⓔ
2-201 Ⓐ Ⓑ Ⓒ Ⓓ Ⓔ
2-202 Ⓐ Ⓑ Ⓒ Ⓓ Ⓔ
2-203 Ⓐ Ⓑ Ⓒ Ⓓ Ⓔ
2-204 Ⓐ Ⓑ Ⓒ Ⓓ Ⓔ
2-205 Ⓐ Ⓑ Ⓒ Ⓓ Ⓔ
2-206 Ⓐ Ⓑ Ⓒ Ⓓ Ⓔ
2-207 Ⓐ Ⓑ Ⓒ Ⓓ Ⓔ
2-208 Ⓐ Ⓑ Ⓒ Ⓓ Ⓔ
2-209 Ⓐ Ⓑ Ⓒ Ⓓ Ⓔ
2-210 Ⓐ Ⓑ Ⓒ Ⓓ Ⓔ
2-211 Ⓐ Ⓑ Ⓒ Ⓓ Ⓔ
2-212 Ⓐ Ⓑ Ⓒ Ⓓ Ⓔ
2-213 Ⓐ Ⓑ Ⓒ Ⓓ Ⓔ
2-214 Ⓐ Ⓑ Ⓒ Ⓓ Ⓔ
2-215 Ⓐ Ⓑ Ⓒ Ⓓ Ⓔ
2-216 Ⓐ Ⓑ Ⓒ Ⓓ Ⓔ
2-217 Ⓐ Ⓑ Ⓒ Ⓓ Ⓔ
2-218 Ⓐ Ⓑ Ⓒ Ⓓ Ⓔ
2-219 Ⓐ Ⓑ Ⓒ Ⓓ Ⓔ
2-220 Ⓐ Ⓑ Ⓒ Ⓓ Ⓔ
2-221 Ⓐ Ⓑ Ⓒ Ⓓ Ⓔ
2-222 Ⓐ Ⓑ Ⓒ Ⓓ Ⓔ
2-223 Ⓐ Ⓑ Ⓒ Ⓓ Ⓔ
2-224 Ⓐ Ⓑ Ⓒ Ⓓ Ⓔ
2-225 Ⓐ Ⓑ Ⓒ Ⓓ Ⓔ

۰۲۱-۶۶۱۹۸۵۱۴ www.myuptodate.com دریافت آخرین نسخه آپتودیت آفلاین

دریافت آخرین نسخه آپتودیت آفلاین www.myuptodate.com ۰۲۱-۶۶۱۹۸۵۱۴

PRACTICE EXAMINATION 1 ANSWER SHEET 2

1-1 Ⓐ Ⓑ Ⓒ Ⓓ Ⓔ	1-26 Ⓐ Ⓑ Ⓒ Ⓓ Ⓔ	1-51 Ⓐ Ⓑ Ⓒ Ⓓ Ⓔ
1-2 Ⓐ Ⓑ Ⓒ Ⓓ Ⓔ	1-27 Ⓐ Ⓑ Ⓒ Ⓓ Ⓔ	1-52 Ⓐ Ⓑ Ⓒ Ⓓ Ⓔ
1-3 Ⓐ Ⓑ Ⓒ Ⓓ Ⓔ	1-28 Ⓐ Ⓑ Ⓒ Ⓓ Ⓔ	1-53 Ⓐ Ⓑ Ⓒ Ⓓ Ⓔ
1-4 Ⓐ Ⓑ Ⓒ Ⓓ Ⓔ	1-29 Ⓐ Ⓑ Ⓒ Ⓓ Ⓔ	1-54 Ⓐ Ⓑ Ⓒ Ⓓ Ⓔ
1-5 Ⓐ Ⓑ Ⓒ Ⓓ Ⓔ	1-30 Ⓐ Ⓑ Ⓒ Ⓓ Ⓔ	1-55 Ⓐ Ⓑ Ⓒ Ⓓ Ⓔ
1-6 Ⓐ Ⓑ Ⓒ Ⓓ Ⓔ	1-31 Ⓐ Ⓑ Ⓒ Ⓓ Ⓔ	1-56 Ⓐ Ⓑ Ⓒ Ⓓ Ⓔ
1-7 Ⓐ Ⓑ Ⓒ Ⓓ Ⓔ	1-32 Ⓐ Ⓑ Ⓒ Ⓓ Ⓔ	1-57 Ⓐ Ⓑ Ⓒ Ⓓ Ⓔ
1-8 Ⓐ Ⓑ Ⓒ Ⓓ Ⓔ	1-33 Ⓐ Ⓑ Ⓒ Ⓓ Ⓔ	1-58 Ⓐ Ⓑ Ⓒ Ⓓ Ⓔ
1-9 Ⓐ Ⓑ Ⓒ Ⓓ Ⓔ	1-34 Ⓐ Ⓑ Ⓒ Ⓓ Ⓔ	1-59 Ⓐ Ⓑ Ⓒ Ⓓ Ⓔ
1-10 Ⓐ Ⓑ Ⓒ Ⓓ Ⓔ	1-35 Ⓐ Ⓑ Ⓒ Ⓓ Ⓔ	1-60 Ⓐ Ⓑ Ⓒ Ⓓ Ⓔ
1-11 Ⓐ Ⓑ Ⓒ Ⓓ Ⓔ	1-36 Ⓐ Ⓑ Ⓒ Ⓓ Ⓔ	1-61 Ⓐ Ⓑ Ⓒ Ⓓ Ⓔ
1-12 Ⓐ Ⓑ Ⓒ Ⓓ Ⓔ	1-37 Ⓐ Ⓑ Ⓒ Ⓓ Ⓔ	1-62 Ⓐ Ⓑ Ⓒ Ⓓ Ⓔ
1-13 Ⓐ Ⓑ Ⓒ Ⓓ Ⓔ	1-38 Ⓐ Ⓑ Ⓒ Ⓓ Ⓔ	1-63 Ⓐ Ⓑ Ⓒ Ⓓ Ⓔ
1-14 Ⓐ Ⓑ Ⓒ Ⓓ Ⓔ	1-39 Ⓐ Ⓑ Ⓒ Ⓓ Ⓔ	1-64 Ⓐ Ⓑ Ⓒ Ⓓ Ⓔ
1-15 Ⓐ Ⓑ Ⓒ Ⓓ Ⓔ	1-40 Ⓐ Ⓑ Ⓒ Ⓓ Ⓔ	1-65 Ⓐ Ⓑ Ⓒ Ⓓ Ⓔ
1-16 Ⓐ Ⓑ Ⓒ Ⓓ Ⓔ	1-41 Ⓐ Ⓑ Ⓒ Ⓓ Ⓔ	1-66 Ⓐ Ⓑ Ⓒ Ⓓ Ⓔ
1-17 Ⓐ Ⓑ Ⓒ Ⓓ Ⓔ	1-42 Ⓐ Ⓑ Ⓒ Ⓓ Ⓔ	1-67 Ⓐ Ⓑ Ⓒ Ⓓ Ⓔ
1-18 Ⓐ Ⓑ Ⓒ Ⓓ Ⓔ	1-43 Ⓐ Ⓑ Ⓒ Ⓓ Ⓔ	1-68 Ⓐ Ⓑ Ⓒ Ⓓ Ⓔ
1-19 Ⓐ Ⓑ Ⓒ Ⓓ Ⓔ	1-44 Ⓐ Ⓑ Ⓒ Ⓓ Ⓔ	1-69 Ⓐ Ⓑ Ⓒ Ⓓ Ⓔ
1-20 Ⓐ Ⓑ Ⓒ Ⓓ Ⓔ	1-45 Ⓐ Ⓑ Ⓒ Ⓓ Ⓔ	1-70 Ⓐ Ⓑ Ⓒ Ⓓ Ⓔ
1-21 Ⓐ Ⓑ Ⓒ Ⓓ Ⓔ	1-46 Ⓐ Ⓑ Ⓒ Ⓓ Ⓔ	1-71 Ⓐ Ⓑ Ⓒ Ⓓ Ⓔ
1-22 Ⓐ Ⓑ Ⓒ Ⓓ Ⓔ	1-47 Ⓐ Ⓑ Ⓒ Ⓓ Ⓔ	1-72 Ⓐ Ⓑ Ⓒ Ⓓ Ⓔ
1-23 Ⓐ Ⓑ Ⓒ Ⓓ Ⓔ	1-48 Ⓐ Ⓑ Ⓒ Ⓓ Ⓔ	1-73 Ⓐ Ⓑ Ⓒ Ⓓ Ⓔ
1-24 Ⓐ Ⓑ Ⓒ Ⓓ Ⓔ	1-49 Ⓐ Ⓑ Ⓒ Ⓓ Ⓔ	1-74 Ⓐ Ⓑ Ⓒ Ⓓ Ⓔ
1-25 Ⓐ Ⓑ Ⓒ Ⓓ Ⓔ	1-50 Ⓐ Ⓑ Ⓒ Ⓓ Ⓔ	1-75 Ⓐ Ⓑ Ⓒ Ⓓ Ⓔ

۰۲۱-۶۶۱۹۸۵۱۴ www.myuptodate.com دریافت آخرین نسخه آپتودیت آفلاین

1-76 Ⓐ Ⓑ Ⓒ Ⓓ Ⓔ	1-101 Ⓐ Ⓑ Ⓒ Ⓓ Ⓔ	1-126 Ⓐ Ⓑ Ⓒ Ⓓ Ⓔ
1-77 Ⓐ Ⓑ Ⓒ Ⓓ Ⓔ	1-102 Ⓐ Ⓑ Ⓒ Ⓓ Ⓔ	1-127 Ⓐ Ⓑ Ⓒ Ⓓ Ⓔ
1-78 Ⓐ Ⓑ Ⓒ Ⓓ Ⓔ	1-103 Ⓐ Ⓑ Ⓒ Ⓓ Ⓔ	1-128 Ⓐ Ⓑ Ⓒ Ⓓ Ⓔ
1-79 Ⓐ Ⓑ Ⓒ Ⓓ Ⓔ	1-104 Ⓐ Ⓑ Ⓒ Ⓓ Ⓔ	1-129 Ⓐ Ⓑ Ⓒ Ⓓ Ⓔ
1-80 Ⓐ Ⓑ Ⓒ Ⓓ Ⓔ	1-105 Ⓐ Ⓑ Ⓒ Ⓓ Ⓔ	1-130 Ⓐ Ⓑ Ⓒ Ⓓ Ⓔ
1-81 Ⓐ Ⓑ Ⓒ Ⓓ Ⓔ	1-106 Ⓐ Ⓑ Ⓒ Ⓓ Ⓔ	1-131 Ⓐ Ⓑ Ⓒ Ⓓ Ⓔ
1-82 Ⓐ Ⓑ Ⓒ Ⓓ Ⓔ	1-107 Ⓐ Ⓑ Ⓒ Ⓓ Ⓔ	1-132 Ⓐ Ⓑ Ⓒ Ⓓ Ⓔ
1-83 Ⓐ Ⓑ Ⓒ Ⓓ Ⓔ	1-108 Ⓐ Ⓑ Ⓒ Ⓓ Ⓔ	1-133 Ⓐ Ⓑ Ⓒ Ⓓ Ⓔ
1-84 Ⓐ Ⓑ Ⓒ Ⓓ Ⓔ	1-109 Ⓐ Ⓑ Ⓒ Ⓓ Ⓔ	1-134 Ⓐ Ⓑ Ⓒ Ⓓ Ⓔ
1-85 Ⓐ Ⓑ Ⓒ Ⓓ Ⓔ	1-110 Ⓐ Ⓑ Ⓒ Ⓓ Ⓔ	1-135 Ⓐ Ⓑ Ⓒ Ⓓ Ⓔ
1-86 Ⓐ Ⓑ Ⓒ Ⓓ Ⓔ	1-111 Ⓐ Ⓑ Ⓒ Ⓓ Ⓔ	1-136 Ⓐ Ⓑ Ⓒ Ⓓ Ⓔ
1-87 Ⓐ Ⓑ Ⓒ Ⓓ Ⓔ	1-112 Ⓐ Ⓑ Ⓒ Ⓓ Ⓔ	1-137 Ⓐ Ⓑ Ⓒ Ⓓ Ⓔ
1-88 Ⓐ Ⓑ Ⓒ Ⓓ Ⓔ	1-113 Ⓐ Ⓑ Ⓒ Ⓓ Ⓔ	1-138 Ⓐ Ⓑ Ⓒ Ⓓ Ⓔ
1-89 Ⓐ Ⓑ Ⓒ Ⓓ Ⓔ	1-114 Ⓐ Ⓑ Ⓒ Ⓓ Ⓔ	1-139 Ⓐ Ⓑ Ⓒ Ⓓ Ⓔ
1-90 Ⓐ Ⓑ Ⓒ Ⓓ Ⓔ	1-115 Ⓐ Ⓑ Ⓒ Ⓓ Ⓔ	1-140 Ⓐ Ⓑ Ⓒ Ⓓ Ⓔ
1-91 Ⓐ Ⓑ Ⓒ Ⓓ Ⓔ	1-116 Ⓐ Ⓑ Ⓒ Ⓓ Ⓔ	1-141 Ⓐ Ⓑ Ⓒ Ⓓ Ⓔ
1-92 Ⓐ Ⓑ Ⓒ Ⓓ Ⓔ	1-117 Ⓐ Ⓑ Ⓒ Ⓓ Ⓔ	1-142 Ⓐ Ⓑ Ⓒ Ⓓ Ⓔ
1-93 Ⓐ Ⓑ Ⓒ Ⓓ Ⓔ	1-118 Ⓐ Ⓑ Ⓒ Ⓓ Ⓔ	1-143 Ⓐ Ⓑ Ⓒ Ⓓ Ⓔ
1-94 Ⓐ Ⓑ Ⓒ Ⓓ Ⓔ	1-119 Ⓐ Ⓑ Ⓒ Ⓓ Ⓔ	1-144 Ⓐ Ⓑ Ⓒ Ⓓ Ⓔ
1-95 Ⓐ Ⓑ Ⓒ Ⓓ Ⓔ	1-120 Ⓐ Ⓑ Ⓒ Ⓓ Ⓔ	1-145 Ⓐ Ⓑ Ⓒ Ⓓ Ⓔ
1-96 Ⓐ Ⓑ Ⓒ Ⓓ Ⓔ	1-121 Ⓐ Ⓑ Ⓒ Ⓓ Ⓔ	1-146 Ⓐ Ⓑ Ⓒ Ⓓ Ⓔ
1-97 Ⓐ Ⓑ Ⓒ Ⓓ Ⓔ	1-122 Ⓐ Ⓑ Ⓒ Ⓓ Ⓔ	1-147 Ⓐ Ⓑ Ⓒ Ⓓ Ⓔ
1-98 Ⓐ Ⓑ Ⓒ Ⓓ Ⓔ	1-123 Ⓐ Ⓑ Ⓒ Ⓓ Ⓔ	1-148 Ⓐ Ⓑ Ⓒ Ⓓ Ⓔ
1-99 Ⓐ Ⓑ Ⓒ Ⓓ Ⓔ	1-124 Ⓐ Ⓑ Ⓒ Ⓓ Ⓔ	1-149 Ⓐ Ⓑ Ⓒ Ⓓ Ⓔ
1-100 Ⓐ Ⓑ Ⓒ Ⓓ Ⓔ	1-125 Ⓐ Ⓑ Ⓒ Ⓓ Ⓔ	1-150 Ⓐ Ⓑ Ⓒ Ⓓ Ⓔ

۰۲۱-۶۶۱۹۸۵۱۴ www.myuptodate.com دریافت آخرین نسخه آپتودیت آفلاین

1-151 Ⓐ Ⓑ Ⓒ Ⓓ Ⓔ	1-176 Ⓐ Ⓑ Ⓒ Ⓓ Ⓔ	1-201 Ⓐ Ⓑ Ⓒ Ⓓ Ⓔ
1-152 Ⓐ Ⓑ Ⓒ Ⓓ Ⓔ	1-177 Ⓐ Ⓑ Ⓒ Ⓓ Ⓔ	1-202 Ⓐ Ⓑ Ⓒ Ⓓ Ⓔ
1-153 Ⓐ Ⓑ Ⓒ Ⓓ Ⓔ	1-178 Ⓐ Ⓑ Ⓒ Ⓓ Ⓔ	1-203 Ⓐ Ⓑ Ⓒ Ⓓ Ⓔ
1-154 Ⓐ Ⓑ Ⓒ Ⓓ Ⓔ	1-179 Ⓐ Ⓑ Ⓒ Ⓓ Ⓔ	1-204 Ⓐ Ⓑ Ⓒ Ⓓ Ⓔ
1-155 Ⓐ Ⓑ Ⓒ Ⓓ Ⓔ	1-180 Ⓐ Ⓑ Ⓒ Ⓓ Ⓔ	1-205 Ⓐ Ⓑ Ⓒ Ⓓ Ⓔ
1-156 Ⓐ Ⓑ Ⓒ Ⓓ Ⓔ	1-181 Ⓐ Ⓑ Ⓒ Ⓓ Ⓔ	1-206 Ⓐ Ⓑ Ⓒ Ⓓ Ⓔ
1-157 Ⓐ Ⓑ Ⓒ Ⓓ Ⓔ	1-182 Ⓐ Ⓑ Ⓒ Ⓓ Ⓔ	1-207 Ⓐ Ⓑ Ⓒ Ⓓ Ⓔ
1-158 Ⓐ Ⓑ Ⓒ Ⓓ Ⓔ	1-183 Ⓐ Ⓑ Ⓒ Ⓓ Ⓔ	1-208 Ⓐ Ⓑ Ⓒ Ⓓ Ⓔ
1-159 Ⓐ Ⓑ Ⓒ Ⓓ Ⓔ	1-184 Ⓐ Ⓑ Ⓒ Ⓓ Ⓔ	1-209 Ⓐ Ⓑ Ⓒ Ⓓ Ⓔ
1-160 Ⓐ Ⓑ Ⓒ Ⓓ Ⓔ	1-185 Ⓐ Ⓑ Ⓒ Ⓓ Ⓔ	1-210 Ⓐ Ⓑ Ⓒ Ⓓ Ⓔ
1-161 Ⓐ Ⓑ Ⓒ Ⓓ Ⓔ	1-186 Ⓐ Ⓑ Ⓒ Ⓓ Ⓔ	1-211 Ⓐ Ⓑ Ⓒ Ⓓ Ⓔ
1-162 Ⓐ Ⓑ Ⓒ Ⓓ Ⓔ	1-187 Ⓐ Ⓑ Ⓒ Ⓓ Ⓔ	1-212 Ⓐ Ⓑ Ⓒ Ⓓ Ⓔ
1-163 Ⓐ Ⓑ Ⓒ Ⓓ Ⓔ	1-188 Ⓐ Ⓑ Ⓒ Ⓓ Ⓔ	1-213 Ⓐ Ⓑ Ⓒ Ⓓ Ⓔ
1-164 Ⓐ Ⓑ Ⓒ Ⓓ Ⓔ	1-189 Ⓐ Ⓑ Ⓒ Ⓓ Ⓔ	1-214 Ⓐ Ⓑ Ⓒ Ⓓ Ⓔ
1-165 Ⓐ Ⓑ Ⓒ Ⓓ Ⓔ	1-190 Ⓐ Ⓑ Ⓒ Ⓓ Ⓔ	1-215 Ⓐ Ⓑ Ⓒ Ⓓ Ⓔ
1-166 Ⓐ Ⓑ Ⓒ Ⓓ Ⓔ	1-191 Ⓐ Ⓑ Ⓒ Ⓓ Ⓔ	1-216 Ⓐ Ⓑ Ⓒ Ⓓ Ⓔ
1-167 Ⓐ Ⓑ Ⓒ Ⓓ Ⓔ	1-192 Ⓐ Ⓑ Ⓒ Ⓓ Ⓔ	1-217 Ⓐ Ⓑ Ⓒ Ⓓ Ⓔ
1-168 Ⓐ Ⓑ Ⓒ Ⓓ Ⓔ	1-193 Ⓐ Ⓑ Ⓒ Ⓓ Ⓔ	1-218 Ⓐ Ⓑ Ⓒ Ⓓ Ⓔ
1-169 Ⓐ Ⓑ Ⓒ Ⓓ Ⓔ	1-194 Ⓐ Ⓑ Ⓒ Ⓓ Ⓔ	1-219 Ⓐ Ⓑ Ⓒ Ⓓ Ⓔ
1-170 Ⓐ Ⓑ Ⓒ Ⓓ Ⓔ	1-195 Ⓐ Ⓑ Ⓒ Ⓓ Ⓔ	1-220 Ⓐ Ⓑ Ⓒ Ⓓ Ⓔ
1-171 Ⓐ Ⓑ Ⓒ Ⓓ Ⓔ	1-196 Ⓐ Ⓑ Ⓒ Ⓓ Ⓔ	1-221 Ⓐ Ⓑ Ⓒ Ⓓ Ⓔ
1-172 Ⓐ Ⓑ Ⓒ Ⓓ Ⓔ	1-197 Ⓐ Ⓑ Ⓒ Ⓓ Ⓔ	1-222 Ⓐ Ⓑ Ⓒ Ⓓ Ⓔ
1-173 Ⓐ Ⓑ Ⓒ Ⓓ Ⓔ	1-198 Ⓐ Ⓑ Ⓒ Ⓓ Ⓔ	1-223 Ⓐ Ⓑ Ⓒ Ⓓ Ⓔ
1-174 Ⓐ Ⓑ Ⓒ Ⓓ Ⓔ	1-199 Ⓐ Ⓑ Ⓒ Ⓓ Ⓔ	1-224 Ⓐ Ⓑ Ⓒ Ⓓ Ⓔ
1-175 Ⓐ Ⓑ Ⓒ Ⓓ Ⓔ	1-200 Ⓐ Ⓑ Ⓒ Ⓓ Ⓔ	1-225 Ⓐ Ⓑ Ⓒ Ⓓ Ⓔ

۰۲۱-۶۶۱۹۸۵۱۴ www.myuptodate.com دریافت آخرین نسخه آپتودیت آفلاین

دریافت آخرین نسخه آپتودیت آفلاین www.myuptodate.com ۰۲۱-۶۶۱۹۸۵۱۴

PRACTICE EXAMINATION 1 ANSWER SHEET 1

1-1 Ⓐ Ⓑ Ⓒ Ⓓ Ⓔ	1-26 Ⓐ Ⓑ Ⓒ Ⓓ Ⓔ	1-51 Ⓐ Ⓑ Ⓒ Ⓓ Ⓔ
1-2 Ⓐ Ⓑ Ⓒ Ⓓ Ⓔ	1-27 Ⓐ Ⓑ Ⓒ Ⓓ Ⓔ	1-52 Ⓐ Ⓑ Ⓒ Ⓓ Ⓔ
1-3 Ⓐ Ⓑ Ⓒ Ⓓ Ⓔ	1-28 Ⓐ Ⓑ Ⓒ Ⓓ Ⓔ	1-53 Ⓐ Ⓑ Ⓒ Ⓓ Ⓔ
1-4 Ⓐ Ⓑ Ⓒ Ⓓ Ⓔ	1-29 Ⓐ Ⓑ Ⓒ Ⓓ Ⓔ	1-54 Ⓐ Ⓑ Ⓒ Ⓓ Ⓔ
1-5 Ⓐ Ⓑ Ⓒ Ⓓ Ⓔ	1-30 Ⓐ Ⓑ Ⓒ Ⓓ Ⓔ	1-55 Ⓐ Ⓑ Ⓒ Ⓓ Ⓔ
1-6 Ⓐ Ⓑ Ⓒ Ⓓ Ⓔ	1-31 Ⓐ Ⓑ Ⓒ Ⓓ Ⓔ	1-56 Ⓐ Ⓑ Ⓒ Ⓓ Ⓔ
1-7 Ⓐ Ⓑ Ⓒ Ⓓ Ⓔ	1-32 Ⓐ Ⓑ Ⓒ Ⓓ Ⓔ	1-57 Ⓐ Ⓑ Ⓒ Ⓓ Ⓔ
1-8 Ⓐ Ⓑ Ⓒ Ⓓ Ⓔ	1-33 Ⓐ Ⓑ Ⓒ Ⓓ Ⓔ	1-58 Ⓐ Ⓑ Ⓒ Ⓓ Ⓔ
1-9 Ⓐ Ⓑ Ⓒ Ⓓ Ⓔ	1-34 Ⓐ Ⓑ Ⓒ Ⓓ Ⓔ	1-59 Ⓐ Ⓑ Ⓒ Ⓓ Ⓔ
1-10 Ⓐ Ⓑ Ⓒ Ⓓ Ⓔ	1-35 Ⓐ Ⓑ Ⓒ Ⓓ Ⓔ	1-60 Ⓐ Ⓑ Ⓒ Ⓓ Ⓔ
1-11 Ⓐ Ⓑ Ⓒ Ⓓ Ⓔ	1-36 Ⓐ Ⓑ Ⓒ Ⓓ Ⓔ	1-61 Ⓐ Ⓑ Ⓒ Ⓓ Ⓔ
1-12 Ⓐ Ⓑ Ⓒ Ⓓ Ⓔ	1-37 Ⓐ Ⓑ Ⓒ Ⓓ Ⓔ	1-62 Ⓐ Ⓑ Ⓒ Ⓓ Ⓔ
1-13 Ⓐ Ⓑ Ⓒ Ⓓ Ⓔ	1-38 Ⓐ Ⓑ Ⓒ Ⓓ Ⓔ	1-63 Ⓐ Ⓑ Ⓒ Ⓓ Ⓔ
1-14 Ⓐ Ⓑ Ⓒ Ⓓ Ⓔ	1-39 Ⓐ Ⓑ Ⓒ Ⓓ Ⓔ	1-64 Ⓐ Ⓑ Ⓒ Ⓓ Ⓔ
1-15 Ⓐ Ⓑ Ⓒ Ⓓ Ⓔ	1-40 Ⓐ Ⓑ Ⓒ Ⓓ Ⓔ	1-65 Ⓐ Ⓑ Ⓒ Ⓓ Ⓔ
1-16 Ⓐ Ⓑ Ⓒ Ⓓ Ⓔ	1-41 Ⓐ Ⓑ Ⓒ Ⓓ Ⓔ	1-66 Ⓐ Ⓑ Ⓒ Ⓓ Ⓔ
1-17 Ⓐ Ⓑ Ⓒ Ⓓ Ⓔ	1-42 Ⓐ Ⓑ Ⓒ Ⓓ Ⓔ	1-67 Ⓐ Ⓑ Ⓒ Ⓓ Ⓔ
1-18 Ⓐ Ⓑ Ⓒ Ⓓ Ⓔ	1-43 Ⓐ Ⓑ Ⓒ Ⓓ Ⓔ	1-68 Ⓐ Ⓑ Ⓒ Ⓓ Ⓔ
1-19 Ⓐ Ⓑ Ⓒ Ⓓ Ⓔ	1-44 Ⓐ Ⓑ Ⓒ Ⓓ Ⓔ	1-69 Ⓐ Ⓑ Ⓒ Ⓓ Ⓔ
1-20 Ⓐ Ⓑ Ⓒ Ⓓ Ⓔ	1-45 Ⓐ Ⓑ Ⓒ Ⓓ Ⓔ	1-70 Ⓐ Ⓑ Ⓒ Ⓓ Ⓔ
1-21 Ⓐ Ⓑ Ⓒ Ⓓ Ⓔ	1-46 Ⓐ Ⓑ Ⓒ Ⓓ Ⓔ	1-71 Ⓐ Ⓑ Ⓒ Ⓓ Ⓔ
1-22 Ⓐ Ⓑ Ⓒ Ⓓ Ⓔ	1-47 Ⓐ Ⓑ Ⓒ Ⓓ Ⓔ	1-72 Ⓐ Ⓑ Ⓒ Ⓓ Ⓔ
1-23 Ⓐ Ⓑ Ⓒ Ⓓ Ⓔ	1-48 Ⓐ Ⓑ Ⓒ Ⓓ Ⓔ	1-73 Ⓐ Ⓑ Ⓒ Ⓓ Ⓔ
1-24 Ⓐ Ⓑ Ⓒ Ⓓ Ⓔ	1-49 Ⓐ Ⓑ Ⓒ Ⓓ Ⓔ	1-74 Ⓐ Ⓑ Ⓒ Ⓓ Ⓔ
1-25 Ⓐ Ⓑ Ⓒ Ⓓ Ⓔ	1-50 Ⓐ Ⓑ Ⓒ Ⓓ Ⓔ	1-75 Ⓐ Ⓑ Ⓒ Ⓓ Ⓔ

۰۲۱-۶۶۱۹۸۵۱۴ www.myuptodate.com دریافت آخرین نسخه آپتودیت آفلاین

1-76 Ⓐ Ⓑ Ⓒ Ⓓ Ⓔ	1-101 Ⓐ Ⓑ Ⓒ Ⓓ Ⓔ	1-126 Ⓐ Ⓑ Ⓒ Ⓓ Ⓔ
1-77 Ⓐ Ⓑ Ⓒ Ⓓ Ⓔ	1-102 Ⓐ Ⓑ Ⓒ Ⓓ Ⓔ	1-127 Ⓐ Ⓑ Ⓒ Ⓓ Ⓔ
1-78 Ⓐ Ⓑ Ⓒ Ⓓ Ⓔ	1-103 Ⓐ Ⓑ Ⓒ Ⓓ Ⓔ	1-128 Ⓐ Ⓑ Ⓒ Ⓓ Ⓔ
1-79 Ⓐ Ⓑ Ⓒ Ⓓ Ⓔ	1-104 Ⓐ Ⓑ Ⓒ Ⓓ Ⓔ	1-129 Ⓐ Ⓑ Ⓒ Ⓓ Ⓔ
1-80 Ⓐ Ⓑ Ⓒ Ⓓ Ⓔ	1-105 Ⓐ Ⓑ Ⓒ Ⓓ Ⓔ	1-130 Ⓐ Ⓑ Ⓒ Ⓓ Ⓔ
1-81 Ⓐ Ⓑ Ⓒ Ⓓ Ⓔ	1-106 Ⓐ Ⓑ Ⓒ Ⓓ Ⓔ	1-131 Ⓐ Ⓑ Ⓒ Ⓓ Ⓔ
1-82 Ⓐ Ⓑ Ⓒ Ⓓ Ⓔ	1-107 Ⓐ Ⓑ Ⓒ Ⓓ Ⓔ	1-132 Ⓐ Ⓑ Ⓒ Ⓓ Ⓔ
1-83 Ⓐ Ⓑ Ⓒ Ⓓ Ⓔ	1-108 Ⓐ Ⓑ Ⓒ Ⓓ Ⓔ	1-133 Ⓐ Ⓑ Ⓒ Ⓓ Ⓔ
1-84 Ⓐ Ⓑ Ⓒ Ⓓ Ⓔ	1-109 Ⓐ Ⓑ Ⓒ Ⓓ Ⓔ	1-134 Ⓐ Ⓑ Ⓒ Ⓓ Ⓔ
1-85 Ⓐ Ⓑ Ⓒ Ⓓ Ⓔ	1-110 Ⓐ Ⓑ Ⓒ Ⓓ Ⓔ	1-135 Ⓐ Ⓑ Ⓒ Ⓓ Ⓔ
1-86 Ⓐ Ⓑ Ⓒ Ⓓ Ⓔ	1-111 Ⓐ Ⓑ Ⓒ Ⓓ Ⓔ	1-136 Ⓐ Ⓑ Ⓒ Ⓓ Ⓔ
1-87 Ⓐ Ⓑ Ⓒ Ⓓ Ⓔ	1-112 Ⓐ Ⓑ Ⓒ Ⓓ Ⓔ	1-137 Ⓐ Ⓑ Ⓒ Ⓓ Ⓔ
1-88 Ⓐ Ⓑ Ⓒ Ⓓ Ⓔ	1-113 Ⓐ Ⓑ Ⓒ Ⓓ Ⓔ	1-138 Ⓐ Ⓑ Ⓒ Ⓓ Ⓔ
1-89 Ⓐ Ⓑ Ⓒ Ⓓ Ⓔ	1-114 Ⓐ Ⓑ Ⓒ Ⓓ Ⓔ	1-139 Ⓐ Ⓑ Ⓒ Ⓓ Ⓔ
1-90 Ⓐ Ⓑ Ⓒ Ⓓ Ⓔ	1-115 Ⓐ Ⓑ Ⓒ Ⓓ Ⓔ	1-140 Ⓐ Ⓑ Ⓒ Ⓓ Ⓔ
1-91 Ⓐ Ⓑ Ⓒ Ⓓ Ⓔ	1-116 Ⓐ Ⓑ Ⓒ Ⓓ Ⓔ	1-141 Ⓐ Ⓑ Ⓒ Ⓓ Ⓔ
1-92 Ⓐ Ⓑ Ⓒ Ⓓ Ⓔ	1-117 Ⓐ Ⓑ Ⓒ Ⓓ Ⓔ	1-142 Ⓐ Ⓑ Ⓒ Ⓓ Ⓔ
1-93 Ⓐ Ⓑ Ⓒ Ⓓ Ⓔ	1-118 Ⓐ Ⓑ Ⓒ Ⓓ Ⓔ	1-143 Ⓐ Ⓑ Ⓒ Ⓓ Ⓔ
1-94 Ⓐ Ⓑ Ⓒ Ⓓ Ⓔ	1-119 Ⓐ Ⓑ Ⓒ Ⓓ Ⓔ	1-144 Ⓐ Ⓑ Ⓒ Ⓓ Ⓔ
1-95 Ⓐ Ⓑ Ⓒ Ⓓ Ⓔ	1-120 Ⓐ Ⓑ Ⓒ Ⓓ Ⓔ	1-145 Ⓐ Ⓑ Ⓒ Ⓓ Ⓔ
1-96 Ⓐ Ⓑ Ⓒ Ⓓ Ⓔ	1-121 Ⓐ Ⓑ Ⓒ Ⓓ Ⓔ	1-146 Ⓐ Ⓑ Ⓒ Ⓓ Ⓔ
1-97 Ⓐ Ⓑ Ⓒ Ⓓ Ⓔ	1-122 Ⓐ Ⓑ Ⓒ Ⓓ Ⓔ	1-147 Ⓐ Ⓑ Ⓒ Ⓓ Ⓔ
1-98 Ⓐ Ⓑ Ⓒ Ⓓ Ⓔ	1-123 Ⓐ Ⓑ Ⓒ Ⓓ Ⓔ	1-148 Ⓐ Ⓑ Ⓒ Ⓓ Ⓔ
1-99 Ⓐ Ⓑ Ⓒ Ⓓ Ⓔ	1-124 Ⓐ Ⓑ Ⓒ Ⓓ Ⓔ	1-149 Ⓐ Ⓑ Ⓒ Ⓓ Ⓔ
1-100 Ⓐ Ⓑ Ⓒ Ⓓ Ⓔ	1-125 Ⓐ Ⓑ Ⓒ Ⓓ Ⓔ	1-150 Ⓐ Ⓑ Ⓒ Ⓓ Ⓔ

۰۲۱-۶۶۱۹۸۵۱۴ www.myuptodate.com دریافت آخرین نسخه آپتودیت آفلاین

1-151 Ⓐ Ⓑ Ⓒ Ⓓ Ⓔ	1-176 Ⓐ Ⓑ Ⓒ Ⓓ Ⓔ	1-201 Ⓐ Ⓑ Ⓒ Ⓓ Ⓔ
1-152 Ⓐ Ⓑ Ⓒ Ⓓ Ⓔ	1-177 Ⓐ Ⓑ Ⓒ Ⓓ Ⓔ	1-202 Ⓐ Ⓑ Ⓒ Ⓓ Ⓔ
1-153 Ⓐ Ⓑ Ⓒ Ⓓ Ⓔ	1-178 Ⓐ Ⓑ Ⓒ Ⓓ Ⓔ	1-203 Ⓐ Ⓑ Ⓒ Ⓓ Ⓔ
1-154 Ⓐ Ⓑ Ⓒ Ⓓ Ⓔ	1-179 Ⓐ Ⓑ Ⓒ Ⓓ Ⓔ	1-204 Ⓐ Ⓑ Ⓒ Ⓓ Ⓔ
1-155 Ⓐ Ⓑ Ⓒ Ⓓ Ⓔ	1-180 Ⓐ Ⓑ Ⓒ Ⓓ Ⓔ	1-205 Ⓐ Ⓑ Ⓒ Ⓓ Ⓔ
1-156 Ⓐ Ⓑ Ⓒ Ⓓ Ⓔ	1-181 Ⓐ Ⓑ Ⓒ Ⓓ Ⓔ	1-206 Ⓐ Ⓑ Ⓒ Ⓓ Ⓔ
1-157 Ⓐ Ⓑ Ⓒ Ⓓ Ⓔ	1-182 Ⓐ Ⓑ Ⓒ Ⓓ Ⓔ	1-207 Ⓐ Ⓑ Ⓒ Ⓓ Ⓔ
1-158 Ⓐ Ⓑ Ⓒ Ⓓ Ⓔ	1-183 Ⓐ Ⓑ Ⓒ Ⓓ Ⓔ	1-208 Ⓐ Ⓑ Ⓒ Ⓓ Ⓔ
1-159 Ⓐ Ⓑ Ⓒ Ⓓ Ⓔ	1-184 Ⓐ Ⓑ Ⓒ Ⓓ Ⓔ	1-209 Ⓐ Ⓑ Ⓒ Ⓓ Ⓔ
1-160 Ⓐ Ⓑ Ⓒ Ⓓ Ⓔ	1-185 Ⓐ Ⓑ Ⓒ Ⓓ Ⓔ	1-210 Ⓐ Ⓑ Ⓒ Ⓓ Ⓔ
1-161 Ⓐ Ⓑ Ⓒ Ⓓ Ⓔ	1-186 Ⓐ Ⓑ Ⓒ Ⓓ Ⓔ	1-211 Ⓐ Ⓑ Ⓒ Ⓓ Ⓔ
1-162 Ⓐ Ⓑ Ⓒ Ⓓ Ⓔ	1-187 Ⓐ Ⓑ Ⓒ Ⓓ Ⓔ	1-212 Ⓐ Ⓑ Ⓒ Ⓓ Ⓔ
1-163 Ⓐ Ⓑ Ⓒ Ⓓ Ⓔ	1-188 Ⓐ Ⓑ Ⓒ Ⓓ Ⓔ	1-213 Ⓐ Ⓑ Ⓒ Ⓓ Ⓔ
1-164 Ⓐ Ⓑ Ⓒ Ⓓ Ⓔ	1-189 Ⓐ Ⓑ Ⓒ Ⓓ Ⓔ	1-214 Ⓐ Ⓑ Ⓒ Ⓓ Ⓔ
1-165 Ⓐ Ⓑ Ⓒ Ⓓ Ⓔ	1-190 Ⓐ Ⓑ Ⓒ Ⓓ Ⓔ	1-215 Ⓐ Ⓑ Ⓒ Ⓓ Ⓔ
1-166 Ⓐ Ⓑ Ⓒ Ⓓ Ⓔ	1-191 Ⓐ Ⓑ Ⓒ Ⓓ Ⓔ	1-216 Ⓐ Ⓑ Ⓒ Ⓓ Ⓔ
1-167 Ⓐ Ⓑ Ⓒ Ⓓ Ⓔ	1-192 Ⓐ Ⓑ Ⓒ Ⓓ Ⓔ	1-217 Ⓐ Ⓑ Ⓒ Ⓓ Ⓔ
1-168 Ⓐ Ⓑ Ⓒ Ⓓ Ⓔ	1-193 Ⓐ Ⓑ Ⓒ Ⓓ Ⓔ	1-218 Ⓐ Ⓑ Ⓒ Ⓓ Ⓔ
1-169 Ⓐ Ⓑ Ⓒ Ⓓ Ⓔ	1-194 Ⓐ Ⓑ Ⓒ Ⓓ Ⓔ	1-219 Ⓐ Ⓑ Ⓒ Ⓓ Ⓔ
1-170 Ⓐ Ⓑ Ⓒ Ⓓ Ⓔ	1-195 Ⓐ Ⓑ Ⓒ Ⓓ Ⓔ	1-220 Ⓐ Ⓑ Ⓒ Ⓓ Ⓔ
1-171 Ⓐ Ⓑ Ⓒ Ⓓ Ⓔ	1-196 Ⓐ Ⓑ Ⓒ Ⓓ Ⓔ	1-221 Ⓐ Ⓑ Ⓒ Ⓓ Ⓔ
1-172 Ⓐ Ⓑ Ⓒ Ⓓ Ⓔ	1-197 Ⓐ Ⓑ Ⓒ Ⓓ Ⓔ	1-222 Ⓐ Ⓑ Ⓒ Ⓓ Ⓔ
1-173 Ⓐ Ⓑ Ⓒ Ⓓ Ⓔ	1-198 Ⓐ Ⓑ Ⓒ Ⓓ Ⓔ	1-223 Ⓐ Ⓑ Ⓒ Ⓓ Ⓔ
1-174 Ⓐ Ⓑ Ⓒ Ⓓ Ⓔ	1-199 Ⓐ Ⓑ Ⓒ Ⓓ Ⓔ	1-224 Ⓐ Ⓑ Ⓒ Ⓓ Ⓔ
1-175 Ⓐ Ⓑ Ⓒ Ⓓ Ⓔ	1-200 Ⓐ Ⓑ Ⓒ Ⓓ Ⓔ	1-225 Ⓐ Ⓑ Ⓒ Ⓓ Ⓔ

۰۲۱-۶۶۱۹۸۵۱۴ www.myuptodate.com دریافت آخرین نسخه آپتودیت آفلاین

دریافت آخرین نسخه آپتودیت آفلاین www.myuptodate.com ۰۲۱-۶۶۱۹۸۵۱۴

PRACTICE EXAMINATION 2 ANSWER SHEET 2

2-1 Ⓐ Ⓑ Ⓒ Ⓓ Ⓔ	2-26 Ⓐ Ⓑ Ⓒ Ⓓ Ⓔ	2-51 Ⓐ Ⓑ Ⓒ Ⓓ Ⓔ
2-2 Ⓐ Ⓑ Ⓒ Ⓓ Ⓔ	2-27 Ⓐ Ⓑ Ⓒ Ⓓ Ⓔ	2-52 Ⓐ Ⓑ Ⓒ Ⓓ Ⓔ
2-3 Ⓐ Ⓑ Ⓒ Ⓓ Ⓔ	2-28 Ⓐ Ⓑ Ⓒ Ⓓ Ⓔ	2-53 Ⓐ Ⓑ Ⓒ Ⓓ Ⓔ
2-4 Ⓐ Ⓑ Ⓒ Ⓓ Ⓔ	2-29 Ⓐ Ⓑ Ⓒ Ⓓ Ⓔ	2-54 Ⓐ Ⓑ Ⓒ Ⓓ Ⓔ
2-5 Ⓐ Ⓑ Ⓒ Ⓓ Ⓔ	2-30 Ⓐ Ⓑ Ⓒ Ⓓ Ⓔ	2-55 Ⓐ Ⓑ Ⓒ Ⓓ Ⓔ
2-6 Ⓐ Ⓑ Ⓒ Ⓓ Ⓔ	2-31 Ⓐ Ⓑ Ⓒ Ⓓ Ⓔ	2-56 Ⓐ Ⓑ Ⓒ Ⓓ Ⓔ
2-7 Ⓐ Ⓑ Ⓒ Ⓓ Ⓔ	2-32 Ⓐ Ⓑ Ⓒ Ⓓ Ⓔ	2-57 Ⓐ Ⓑ Ⓒ Ⓓ Ⓔ
2-8 Ⓐ Ⓑ Ⓒ Ⓓ Ⓔ	2-33 Ⓐ Ⓑ Ⓒ Ⓓ Ⓔ	2-58 Ⓐ Ⓑ Ⓒ Ⓓ Ⓔ
2-9 Ⓐ Ⓑ Ⓒ Ⓓ Ⓔ	2-34 Ⓐ Ⓑ Ⓒ Ⓓ Ⓔ	2-59 Ⓐ Ⓑ Ⓒ Ⓓ Ⓔ
2-10 Ⓐ Ⓑ Ⓒ Ⓓ Ⓔ	2-35 Ⓐ Ⓑ Ⓒ Ⓓ Ⓔ	2-60 Ⓐ Ⓑ Ⓒ Ⓓ Ⓔ
2-11 Ⓐ Ⓑ Ⓒ Ⓓ Ⓔ	2-36 Ⓐ Ⓑ Ⓒ Ⓓ Ⓔ	2-61 Ⓐ Ⓑ Ⓒ Ⓓ Ⓔ
2-12 Ⓐ Ⓑ Ⓒ Ⓓ Ⓔ	2-37 Ⓐ Ⓑ Ⓒ Ⓓ Ⓔ	2-62 Ⓐ Ⓑ Ⓒ Ⓓ Ⓔ
2-13 Ⓐ Ⓑ Ⓒ Ⓓ Ⓔ	2-38 Ⓐ Ⓑ Ⓒ Ⓓ Ⓔ	2-63 Ⓐ Ⓑ Ⓒ Ⓓ Ⓔ
2-14 Ⓐ Ⓑ Ⓒ Ⓓ Ⓔ	2-39 Ⓐ Ⓑ Ⓒ Ⓓ Ⓔ	2-64 Ⓐ Ⓑ Ⓒ Ⓓ Ⓔ
2-15 Ⓐ Ⓑ Ⓒ Ⓓ Ⓔ	2-40 Ⓐ Ⓑ Ⓒ Ⓓ Ⓔ	2-65 Ⓐ Ⓑ Ⓒ Ⓓ Ⓔ
2-16 Ⓐ Ⓑ Ⓒ Ⓓ Ⓔ	2-41 Ⓐ Ⓑ Ⓒ Ⓓ Ⓔ	2-66 Ⓐ Ⓑ Ⓒ Ⓓ Ⓔ
2-17 Ⓐ Ⓑ Ⓒ Ⓓ Ⓔ	2-42 Ⓐ Ⓑ Ⓒ Ⓓ Ⓔ	2-67 Ⓐ Ⓑ Ⓒ Ⓓ Ⓔ
2-18 Ⓐ Ⓑ Ⓒ Ⓓ Ⓔ	2-43 Ⓐ Ⓑ Ⓒ Ⓓ Ⓔ	2-68 Ⓐ Ⓑ Ⓒ Ⓓ Ⓔ
2-19 Ⓐ Ⓑ Ⓒ Ⓓ Ⓔ	2-44 Ⓐ Ⓑ Ⓒ Ⓓ Ⓔ	2-69 Ⓐ Ⓑ Ⓒ Ⓓ Ⓔ
2-20 Ⓐ Ⓑ Ⓒ Ⓓ Ⓔ	2-45 Ⓐ Ⓑ Ⓒ Ⓓ Ⓔ	2-70 Ⓐ Ⓑ Ⓒ Ⓓ Ⓔ
2-21 Ⓐ Ⓑ Ⓒ Ⓓ Ⓔ	2-46 Ⓐ Ⓑ Ⓒ Ⓓ Ⓔ	2-71 Ⓐ Ⓑ Ⓒ Ⓓ Ⓔ
2-22 Ⓐ Ⓑ Ⓒ Ⓓ Ⓔ	2-47 Ⓐ Ⓑ Ⓒ Ⓓ Ⓔ	2-72 Ⓐ Ⓑ Ⓒ Ⓓ Ⓔ
2-23 Ⓐ Ⓑ Ⓒ Ⓓ Ⓔ	2-48 Ⓐ Ⓑ Ⓒ Ⓓ Ⓔ	2-73 Ⓐ Ⓑ Ⓒ Ⓓ Ⓔ
2-24 Ⓐ Ⓑ Ⓒ Ⓓ Ⓔ	2-49 Ⓐ Ⓑ Ⓒ Ⓓ Ⓔ	2-74 Ⓐ Ⓑ Ⓒ Ⓓ Ⓔ
2-25 Ⓐ Ⓑ Ⓒ Ⓓ Ⓔ	2-50 Ⓐ Ⓑ Ⓒ Ⓓ Ⓔ	2-75 Ⓐ Ⓑ Ⓒ Ⓓ Ⓔ

۰۲۱-۶۶۱۹۸۵۱۴ www.myuptodate.com دریافت آخرین نسخه آپتودیت آفلاین

2-76 Ⓐ Ⓑ Ⓒ Ⓓ Ⓔ	2-101 Ⓐ Ⓑ Ⓒ Ⓓ Ⓔ	2-126 Ⓐ Ⓑ Ⓒ Ⓓ Ⓔ
2-77 Ⓐ Ⓑ Ⓒ Ⓓ Ⓔ	2-102 Ⓐ Ⓑ Ⓒ Ⓓ Ⓔ	2-127 Ⓐ Ⓑ Ⓒ Ⓓ Ⓔ
2-78 Ⓐ Ⓑ Ⓒ Ⓓ Ⓔ	2-103 Ⓐ Ⓑ Ⓒ Ⓓ Ⓔ	2-128 Ⓐ Ⓑ Ⓒ Ⓓ Ⓔ
2-79 Ⓐ Ⓑ Ⓒ Ⓓ Ⓔ	2-104 Ⓐ Ⓑ Ⓒ Ⓓ Ⓔ	2-129 Ⓐ Ⓑ Ⓒ Ⓓ Ⓔ
2-80 Ⓐ Ⓑ Ⓒ Ⓓ Ⓔ	2-105 Ⓐ Ⓑ Ⓒ Ⓓ Ⓔ	2-130 Ⓐ Ⓑ Ⓒ Ⓓ Ⓔ
2-81 Ⓐ Ⓑ Ⓒ Ⓓ Ⓔ	2-106 Ⓐ Ⓑ Ⓒ Ⓓ Ⓔ	2-131 Ⓐ Ⓑ Ⓒ Ⓓ Ⓔ
2-82 Ⓐ Ⓑ Ⓒ Ⓓ Ⓔ	2-107 Ⓐ Ⓑ Ⓒ Ⓓ Ⓔ	2-132 Ⓐ Ⓑ Ⓒ Ⓓ Ⓔ
2-83 Ⓐ Ⓑ Ⓒ Ⓓ Ⓔ	2-108 Ⓐ Ⓑ Ⓒ Ⓓ Ⓔ	2-133 Ⓐ Ⓑ Ⓒ Ⓓ Ⓔ
2-84 Ⓐ Ⓑ Ⓒ Ⓓ Ⓔ	2-109 Ⓐ Ⓑ Ⓒ Ⓓ Ⓔ	2-134 Ⓐ Ⓑ Ⓒ Ⓓ Ⓔ
2-85 Ⓐ Ⓑ Ⓒ Ⓓ Ⓔ	2-110 Ⓐ Ⓑ Ⓒ Ⓓ Ⓔ	2-135 Ⓐ Ⓑ Ⓒ Ⓓ Ⓔ
2-86 Ⓐ Ⓑ Ⓒ Ⓓ Ⓔ	2-111 Ⓐ Ⓑ Ⓒ Ⓓ Ⓔ	2-136 Ⓐ Ⓑ Ⓒ Ⓓ Ⓔ
2-87 Ⓐ Ⓑ Ⓒ Ⓓ Ⓔ	2-112 Ⓐ Ⓑ Ⓒ Ⓓ Ⓔ	2-137 Ⓐ Ⓑ Ⓒ Ⓓ Ⓔ
2-88 Ⓐ Ⓑ Ⓒ Ⓓ Ⓔ	2-113 Ⓐ Ⓑ Ⓒ Ⓓ Ⓔ	2-138 Ⓐ Ⓑ Ⓒ Ⓓ Ⓔ
2-89 Ⓐ Ⓑ Ⓒ Ⓓ Ⓔ	2-114 Ⓐ Ⓑ Ⓒ Ⓓ Ⓔ	2-139 Ⓐ Ⓑ Ⓒ Ⓓ Ⓔ
2-90 Ⓐ Ⓑ Ⓒ Ⓓ Ⓔ	2-115 Ⓐ Ⓑ Ⓒ Ⓓ Ⓔ	2-140 Ⓐ Ⓑ Ⓒ Ⓓ Ⓔ
2-91 Ⓐ Ⓑ Ⓒ Ⓓ Ⓔ	2-116 Ⓐ Ⓑ Ⓒ Ⓓ Ⓔ	2-141 Ⓐ Ⓑ Ⓒ Ⓓ Ⓔ
2-92 Ⓐ Ⓑ Ⓒ Ⓓ Ⓔ	2-117 Ⓐ Ⓑ Ⓒ Ⓓ Ⓔ	2-142 Ⓐ Ⓑ Ⓒ Ⓓ Ⓔ
2-93 Ⓐ Ⓑ Ⓒ Ⓓ Ⓔ	2-118 Ⓐ Ⓑ Ⓒ Ⓓ Ⓔ	2-143 Ⓐ Ⓑ Ⓒ Ⓓ Ⓔ
2-94 Ⓐ Ⓑ Ⓒ Ⓓ Ⓔ	2-119 Ⓐ Ⓑ Ⓒ Ⓓ Ⓔ	2-144 Ⓐ Ⓑ Ⓒ Ⓓ Ⓔ
2-95 Ⓐ Ⓑ Ⓒ Ⓓ Ⓔ	2-120 Ⓐ Ⓑ Ⓒ Ⓓ Ⓔ	2-145 Ⓐ Ⓑ Ⓒ Ⓓ Ⓔ
2-96 Ⓐ Ⓑ Ⓒ Ⓓ Ⓔ	2-121 Ⓐ Ⓑ Ⓒ Ⓓ Ⓔ	2-146 Ⓐ Ⓑ Ⓒ Ⓓ Ⓔ
2-97 Ⓐ Ⓑ Ⓒ Ⓓ Ⓔ	2-122 Ⓐ Ⓑ Ⓒ Ⓓ Ⓔ	2-147 Ⓐ Ⓑ Ⓒ Ⓓ Ⓔ
2-98 Ⓐ Ⓑ Ⓒ Ⓓ Ⓔ	2-123 Ⓐ Ⓑ Ⓒ Ⓓ Ⓔ	2-148 Ⓐ Ⓑ Ⓒ Ⓓ Ⓔ
2-99 Ⓐ Ⓑ Ⓒ Ⓓ Ⓔ	2-124 Ⓐ Ⓑ Ⓒ Ⓓ Ⓔ	2-149 Ⓐ Ⓑ Ⓒ Ⓓ Ⓔ
2-100 Ⓐ Ⓑ Ⓒ Ⓓ Ⓔ	2-125 Ⓐ Ⓑ Ⓒ Ⓓ Ⓔ	2-150 Ⓐ Ⓑ Ⓒ Ⓓ Ⓔ

۰۲۱-۶۶۱۹۸۵۱۴ www.myuptodate.com دریافت آخرین نسخه آپتودیت آفلاین

2-151 Ⓐ Ⓑ Ⓒ Ⓓ Ⓔ
2-152 Ⓐ Ⓑ Ⓒ Ⓓ Ⓔ
2-153 Ⓐ Ⓑ Ⓒ Ⓓ Ⓔ
2-154 Ⓐ Ⓑ Ⓒ Ⓓ Ⓔ
2-155 Ⓐ Ⓑ Ⓒ Ⓓ Ⓔ
2-156 Ⓐ Ⓑ Ⓒ Ⓓ Ⓔ
2-157 Ⓐ Ⓑ Ⓒ Ⓓ Ⓔ
2-158 Ⓐ Ⓑ Ⓒ Ⓓ Ⓔ
2-159 Ⓐ Ⓑ Ⓒ Ⓓ Ⓔ
2-160 Ⓐ Ⓑ Ⓒ Ⓓ Ⓔ
2-161 Ⓐ Ⓑ Ⓒ Ⓓ Ⓔ
2-162 Ⓐ Ⓑ Ⓒ Ⓓ Ⓔ
2-163 Ⓐ Ⓑ Ⓒ Ⓓ Ⓔ
2-164 Ⓐ Ⓑ Ⓒ Ⓓ Ⓔ
2-165 Ⓐ Ⓑ Ⓒ Ⓓ Ⓔ
2-166 Ⓐ Ⓑ Ⓒ Ⓓ Ⓔ
2-167 Ⓐ Ⓑ Ⓒ Ⓓ Ⓔ
2-168 Ⓐ Ⓑ Ⓒ Ⓓ Ⓔ
2-169 Ⓐ Ⓑ Ⓒ Ⓓ Ⓔ
2-170 Ⓐ Ⓑ Ⓒ Ⓓ Ⓔ
2-171 Ⓐ Ⓑ Ⓒ Ⓓ Ⓔ
2-172 Ⓐ Ⓑ Ⓒ Ⓓ Ⓔ
2-173 Ⓐ Ⓑ Ⓒ Ⓓ Ⓔ
2-174 Ⓐ Ⓑ Ⓒ Ⓓ Ⓔ
2-175 Ⓐ Ⓑ Ⓒ Ⓓ Ⓔ
2-176 Ⓐ Ⓑ Ⓒ Ⓓ Ⓔ
2-177 Ⓐ Ⓑ Ⓒ Ⓓ Ⓔ
2-178 Ⓐ Ⓑ Ⓒ Ⓓ Ⓔ
2-179 Ⓐ Ⓑ Ⓒ Ⓓ Ⓔ
2-180 Ⓐ Ⓑ Ⓒ Ⓓ Ⓔ
2-181 Ⓐ Ⓑ Ⓒ Ⓓ Ⓔ
2-182 Ⓐ Ⓑ Ⓒ Ⓓ Ⓔ
2-183 Ⓐ Ⓑ Ⓒ Ⓓ Ⓔ
2-184 Ⓐ Ⓑ Ⓒ Ⓓ Ⓔ
2-185 Ⓐ Ⓑ Ⓒ Ⓓ Ⓔ
2-186 Ⓐ Ⓑ Ⓒ Ⓓ Ⓔ
2-187 Ⓐ Ⓑ Ⓒ Ⓓ Ⓔ
2-188 Ⓐ Ⓑ Ⓒ Ⓓ Ⓔ
2-189 Ⓐ Ⓑ Ⓒ Ⓓ Ⓔ
2-190 Ⓐ Ⓑ Ⓒ Ⓓ Ⓔ
2-191 Ⓐ Ⓑ Ⓒ Ⓓ Ⓔ
2-192 Ⓐ Ⓑ Ⓒ Ⓓ Ⓔ
2-193 Ⓐ Ⓑ Ⓒ Ⓓ Ⓔ
2-194 Ⓐ Ⓑ Ⓒ Ⓓ Ⓔ
2-195 Ⓐ Ⓑ Ⓒ Ⓓ Ⓔ
2-196 Ⓐ Ⓑ Ⓒ Ⓓ Ⓔ
2-197 Ⓐ Ⓑ Ⓒ Ⓓ Ⓔ
2-198 Ⓐ Ⓑ Ⓒ Ⓓ Ⓔ
2-199 Ⓐ Ⓑ Ⓒ Ⓓ Ⓔ
2-200 Ⓐ Ⓑ Ⓒ Ⓓ Ⓔ
2-201 Ⓐ Ⓑ Ⓒ Ⓓ Ⓔ
2-202 Ⓐ Ⓑ Ⓒ Ⓓ Ⓔ
2-203 Ⓐ Ⓑ Ⓒ Ⓓ Ⓔ
2-204 Ⓐ Ⓑ Ⓒ Ⓓ Ⓔ
2-205 Ⓐ Ⓑ Ⓒ Ⓓ Ⓔ
2-206 Ⓐ Ⓑ Ⓒ Ⓓ Ⓔ
2-207 Ⓐ Ⓑ Ⓒ Ⓓ Ⓔ
2-208 Ⓐ Ⓑ Ⓒ Ⓓ Ⓔ
2-209 Ⓐ Ⓑ Ⓒ Ⓓ Ⓔ
2-210 Ⓐ Ⓑ Ⓒ Ⓓ Ⓔ
2-211 Ⓐ Ⓑ Ⓒ Ⓓ Ⓔ
2-212 Ⓐ Ⓑ Ⓒ Ⓓ Ⓔ
2-213 Ⓐ Ⓑ Ⓒ Ⓓ Ⓔ
2-214 Ⓐ Ⓑ Ⓒ Ⓓ Ⓔ
2-215 Ⓐ Ⓑ Ⓒ Ⓓ Ⓔ
2-216 Ⓐ Ⓑ Ⓒ Ⓓ Ⓔ
2-217 Ⓐ Ⓑ Ⓒ Ⓓ Ⓔ
2-218 Ⓐ Ⓑ Ⓒ Ⓓ Ⓔ
2-219 Ⓐ Ⓑ Ⓒ Ⓓ Ⓔ
2-220 Ⓐ Ⓑ Ⓒ Ⓓ Ⓔ
2-221 Ⓐ Ⓑ Ⓒ Ⓓ Ⓔ
2-222 Ⓐ Ⓑ Ⓒ Ⓓ Ⓔ
2-223 Ⓐ Ⓑ Ⓒ Ⓓ Ⓔ
2-224 Ⓐ Ⓑ Ⓒ Ⓓ Ⓔ
2-225 Ⓐ Ⓑ Ⓒ Ⓓ Ⓔ

۰۲۱-۶۶۱۹۸۵۱۴ www.myuptodate.com دریافت آخرین نسخه آپتودیت آفلاین

دریافت آخرین نسخه آپتودیت آفلاین www.myuptodate.com ۰۲۱-۶۶۱۹۸۵۱۴